



Contents lists available at ScienceDirect

International Journal of Surgery Case Reports

journal homepage: www.casereports.com

Transient epiphyseal lesion of the femoral head after traumatic hip dislocation: A case report[☆]



Yusuke Kubo^a, Takuaki Yamamoto^{b,*}, Goro Motomura^a, Satoshi Kido^c,
Kazuyuki Karasuyama^a, Kazuhiko Sonoda^a, Yukihide Iwamoto^d

^a Department of Orthopaedic Surgery, Graduate School of Medical Sciences, Kyushu University, 3-1-1 Maidashi, Higashi-ku, Fukuoka 812-8582, Japan

^b Department of Orthopaedic Surgery, Faculty of Medicine, Fukuoka University, 7-45-1 Nanakuma, Jonan-ku, Fukuoka 814-0180, Japan

^c Department of Orthopaedic Surgery, Yamaguchi Red Cross Hospital, 53-1 Yahatababa, Yamaguchi 753-8519, Japan

^d Department of Orthopaedic Surgery, Kyushu Rosai Hospital, 1-3-1, Kuzuharatakamatsu, Kokuraminami-ku, Kitakyushu 800-0296, Japan

ARTICLE INFO

Article history:

Received 28 February 2016

Received in revised form 2 April 2016

Accepted 3 May 2016

Available online 9 May 2016

Keywords:

Hip dislocation

Bone marrow edema

Insufficiency fracture

ABSTRACT

INTRODUCTION: We experienced a rare case in which magnetic resonance imaging (MRI) showed a transient epiphyseal lesion of the femoral head four months after traumatic hip dislocation. To our knowledge, there have been no previously published reports on the development of such transient lesions after traumatic hip dislocation involving no abnormalities just after dislocation.

PRESENTATION OF CASE: We report a 22-year-old man who showed a transient epiphyseal lesion of the femoral head after traumatic hip dislocation. On MRI performed two days after dislocation, no bony injuries were observed around the hip joint. Four months after dislocation, the patient suddenly experienced right hip pain without any new trauma or injury. A low-intensity band convex to the articular surface was apparent above the epiphyseal scar on T1-weighted imaging, and bone marrow edema was observed around the band lesion on short-tau inversion recovery imaging. Following a two-month period of non-surgical conservative therapy, the patient's hip pain resolved and the low-intensity band was no longer observed on follow-up MRI.

DISCUSSION: Although the detailed pathogenesis of this transient changes was unclear, we speculate that prolonged rest after traumatic hip dislocation may contribute to bone insufficiency, resulting in an insufficiency fracture of the femoral head.

CONCLUSION: This study suggests that transient epiphyseal lesions of the femoral head may occur in patients with a history of traumatic hip dislocation associated with an adapted long-term rest.

© 2016 The Author(s). Published by Elsevier Ltd on behalf of IJS Publishing Group Ltd. This is an open access article under the CC BY-NC-ND license (<http://creativecommons.org/licenses/by-nc-nd/4.0/>).

1. Introduction

Traumatic hip dislocation may have a number of sequelae, one of which is osteonecrosis of the femoral head (ONFH) [1–4]. The incidence of ONFH after traumatic dislocation has been reported to range from 10 to 40%, and this complication generally causes hip pain between 12 and 24 months after traumatic dislocation [5–10]. Magnetic resonance imaging (MRI) is commonly used to diagnose ONFH, demonstrating characteristic low-intensity bands on T1-weighted imaging [11,12]. It has been reported that the diagnosis of ONFH may be confidently made if an abnormal signal is observed on MRI performed three months after the injury [8].

On the other hand, a previous study reported the appearance of transient bone marrow changes in the femoral head on MRI early after traumatic hip dislocation [8]. Although the cause of these transient changes was unclear, the authors postulated that the early changes reflected bone bruises or microfractures due to the injury itself. However, to our knowledge, there have been no published reports of transient lesions of the femoral head after traumatic hip dislocation showing no abnormalities just after dislocation. We herein report a rare case in which MRI showed a transient epiphyseal lesion four months after traumatic hip dislocation.

2. Presentation of case

A 22-year-old Japanese man dislocated his right hip joint posteriorly while snowboarding and was treated with closed reduction within three hours. He had no history of hip disease or no other risk factors contributing to bone fragility, including steroids, alcohol abuse, smoking, renal and liver transplant or systemic lupus erythematosus. On MRI performed two days after dislocation, no

[☆] Investigation performed at the Department of Orthopaedic Surgery, Graduate School of Medical Sciences, Kyushu University, 3-1-1 Maidashi, Higashi-ku, Fukuoka 812-8582, Japan.

* Corresponding author.

E-mail address: yamataku@ortho.med.kyushu-u.ac.jp (T. Yamamoto).

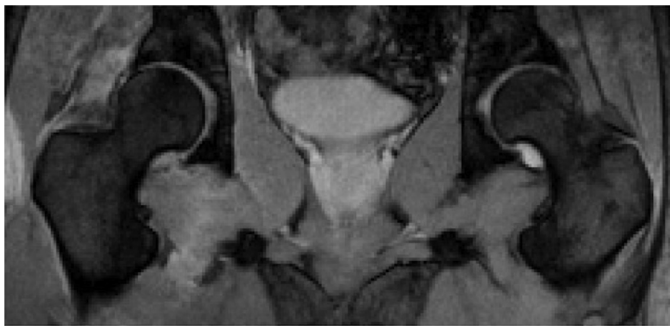


Fig. 1. Short-tau inversion recovery (STIR) sequence image 2 days after the traumatic dislocation of the hip joint. Coronal STIR sequence image obtained 2 days after dislocation shows no bony injuries or bone marrow edema around the hip joint.

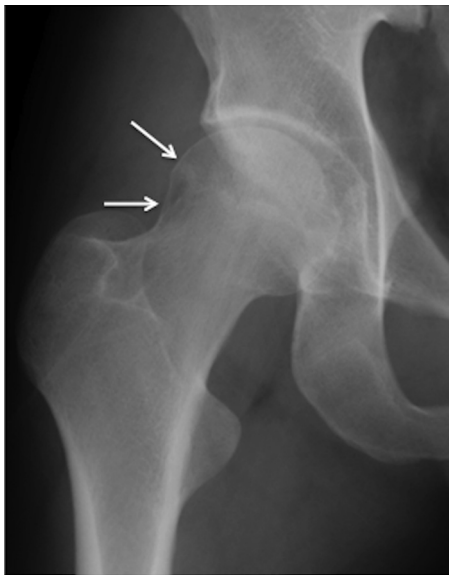


Fig. 2. Anteroposterior radiograph after the onset of right hip pain. An anteroposterior radiograph obtained after the onset of right hip pain shows an irregular contour at the outside of the femoral head, around which focal bone loss is observed (white arrows).

bony injuries or bone marrow edema were observed around the hip joint (Fig. 1). For one week after the injury, the patient was encouraged to avoid weight-bearing activities. Two weeks later, he was discharged from the hospital. He subsequently stayed home for two months without leaving his home, using crutches while indoors. Three months after the injury, he returned to work at a laundry, where he was required to lift heavy laundry loads and stand all day.

Four months after the injury, the patient suddenly experienced right hip pain without any new trauma or injury. On examination, the range of motion of the right hip was slightly limited (110° of flexion, 0° of extension, 40° of external rotation and 20° of internal rotation). An anteroposterior radiograph obtained four months after the injury showed an irregular contour along the outside of the femoral head, around which focal bone loss was observed (Fig. 2). A low-intensity band convex to the articular surface was apparent above the epiphyseal scar on T1-weighted imaging (Fig. 3a), and bone marrow edema changes were observed around the band lesion on short-tau inversion recovery (STIR) imaging (Fig. 3b). Moreover, gadolinium-enhanced MRI showed the band and surrounding area to be enhanced, accompanied by diffuse bone marrow edema (Fig. 3c), and single-photon emission computed tomography/computed tomography (SPECT/CT) with Tc-99 m hydroxymethylene diphosphonate demonstrated the presence of increased uptake involving the entire femoral head (Fig. 4). Based on these findings, the patient was suspected to have an insufficiency fracture of the femoral head. After a two-month period of non-surgical conservative therapy, including the avoidance of weight-bearing activities, the patient's hip pain resolved and the low-intensity band previously seen on T1-weighted imaging was no longer observed on follow-up MRI performed two months after the onset of pain (Fig. 5).

3. Discussion

To our knowledge, only one previous study has shown the occurrence of transient bone marrow signal changes on MRI after hip dislocation. Poggi et al. performed MRI examinations of 14 hips following traumatic dislocation and found transient bone marrow changes in the femoral head in five cases (36%) [8]. However, since

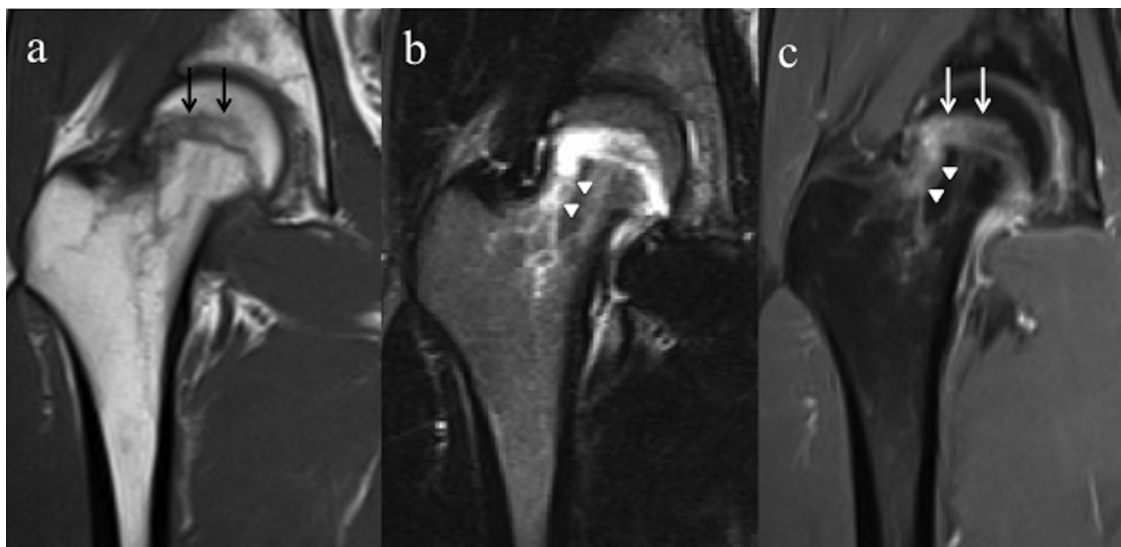


Fig. 3. a–c Magnetic resonance images (MRI) performed 4 months after the injury following the onset of right hip pain. (a) A coronal T1-weighted image shows a low-intensity band convex to the articular surface above the epiphyseal scar (black arrows). (b) A coronal short-tau inversion recovery (STIR) sequence image shows bone marrow edema changes around the band (white arrowheads). (c) On gadolinium-enhanced magnetic resonance image MRI, the band and surrounding area were enhanced (white arrows), accompanied by diffuse bone marrow edema (white arrowheads).

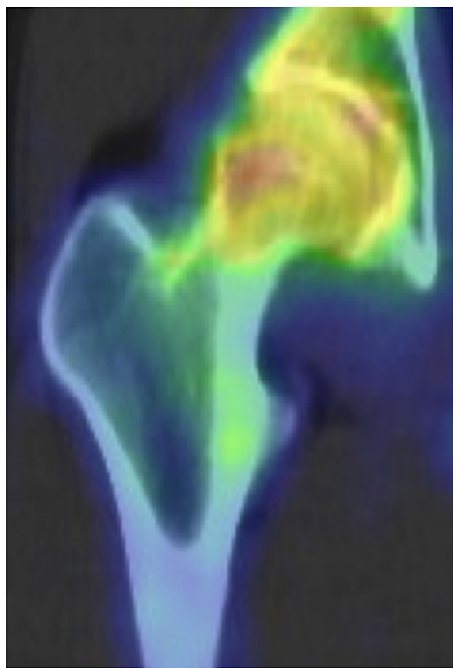


Fig. 4. Single-photon emission computed tomography/computed tomography (SPECT/CT) after the onset of right hip pain. SPECT/CT with Tc-99m hydroxymethylene diphosphonate shows the presence of an increased uptake involving the entire femoral head.

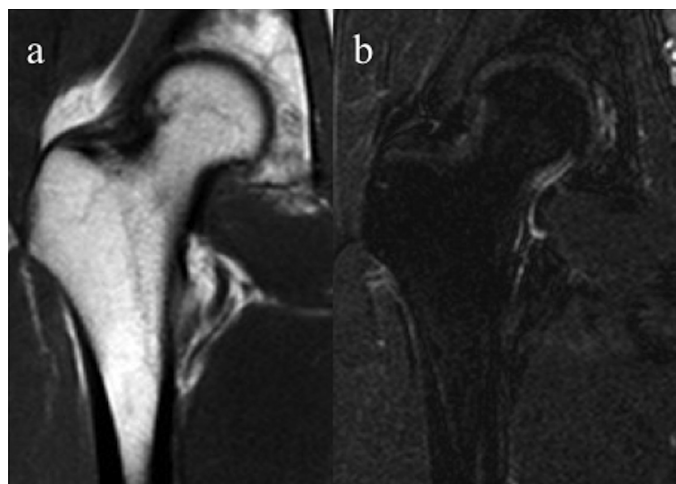


Fig. 5. a,b Magnetic resonance images (MRI) performed at the end of a 2-month period of conservative therapy. (a) Coronal T1-weighted image. The band previously seen on MRI is no longer evident. (b) Coronal short-tau inversion recovery (STIR) sequence image. The band previously seen on MRI is no longer evident.

the bone marrow signal changes were already observed on the initial MRI assessments performed two to 17 days after injury in all five patients, the authors concluded that the transient changes reflected bone bruises or microfractures. On the other hand, MRI performed in the present case two days after dislocation demonstrated no apparent bony injuries around the hip joint, indicating that the subsequent epiphyseal lesion was not directly caused by the dislocation itself.

In the current case, the shape of the low-intensity band was convex to the articular surface, which is a characteristic feature of subchondral insufficiency fractures of the femoral head (SIF) [13,14]. SIF has recently been proposed to be a differential diagno-

sis of ONFH [14]. Initial radiographs are often normal or may show collapse of the femoral head [15]. Some cases of SIF have reportedly healed after conservative therapy, while others have resulted in progressive collapse necessitating surgical treatment. Ikemura et al. described a case of SIF following renal transplantation in which the previously noted low-intensity band was no longer evident on follow-up T1-weighted MRI performed 10 months after the onset of pain [16]. Although the low-intensity band in the current case was located at the epiphysis of the femoral head, the disappearance of this band on follow-up MRI suggested a diagnosis of an insufficiency fracture of the femoral head due to the shape of the low-intensity band [16–18].

Although SIF generally occurs in osteoporotic elderly individuals, several reports have confirmed the diagnosis in young adults [13,14,19]. Iwasaki et al. reported the presence of SIF in young patients (<30 years of age) with normal blood and hormone levels and no history of overexertion [20]. In the current case, the patient stayed at home for two months before returning to work. Although he did not undergo DEXA or examinations of bone metabolic markers, we speculate that the prolonged rest after the traumatic dislocation may have contributed to bone insufficiency, thus resulting in the insufficiency fracture of the femoral head.

4. Conclusion

In conclusion, transient epiphyseal lesions of the femoral head may occur in patients with a history of traumatic hip dislocation associated with adapted long-term rest. Therefore, considering the treatment options for traumatic hip dislocation, it is important to prevent bone loss caused by long periods of avoidance of weight-bearing activities.

Conflict of interest statement

None.

Ethical approval

The present case report was approved by our institutional review board.

Consent

Written informed consent was obtained from the patient for publication of this case report and accompanying images. A copy of the written consent is available for review by the Editor-in-Chief of this journal on request.

Author contribution

Dr. Kubo, Dr. Motomura and Dr. Kido were involved in the care of the patient. Dr. Yamamoto and Dr. Iwamoto supervised the writing. Dr. Karasuyama and Dr. Sonoda were contributors in writing the manuscript. All authors read and approved the final manuscript.

Guarantor

Dr. Yamamoto.

Acknowledgements

This work was supported in part by a Research Grant for Intractable Diseases from the Japan Agency for Medical Research and Development (AMED) (H26-Itaku(Nan)-Ippan-031), and a research grant from Japan Society for the Promotion of Science (15K10479).

References

- [1] J.P. Stannard, H.W. Harris, D.A. Volgas, J.E. Alonso, Functional outcome of patients with femoral head fractures associated with hip dislocations, *Clin. Orthop. Relat. Res.* 377 (2000) 44–56, submitted for publication.
- [2] K.E. Dreinhofer, S.R. Schwarzkopf, N.P. Haas, H. Tscherne, Isolated traumatic dislocation of the hip: long-term results in 50 patients, *J. Bone Joint Surg. Br.* 76 (1994) 6–12.
- [3] E.C. Rodríguez-Merchán, Osteonecrosis of the femoral head after traumatic hip dislocation in the adult, *Clin. Orthop. Relat. Res.* 377 (2000) 68–77, submitted for publication.
- [4] A.R. Sulaiman, I. Munajat, F.E. Mohd, Outcome of traumatic hip dislocation in children, *J. Pediatr. Orthop. B* 22 (2013) 557–562.
- [5] S.S. Upadhyay, A. Moulton, The long-term results of traumatic posterior dislocation of the hip, *J. Bone Joint Surg. Br.* 63 (1981) 548–551.
- [6] H.C. Epstein, Traumatic dislocations of the hip, *Clin. Orthop. Relat. Res.* 92 (1973) 116–142.
- [7] A.J. Dwyer, B. John, S.A. Singh, M.K. Mam, Complications after posterior dislocation of the hip, *Int. Orthop.* 30 (2006) 224–227.
- [8] J.J. Poggi, J.J. Callaghan, C.E. Spritzer, T. Roark, R.D. Goldner, Changes on magnetic resonance images after traumatic hip dislocation, *Clin. Orthop. Relat. Res.* 319 (1995) 249–259.
- [9] S. Sanders, N. Tejwani, K.A. Egol, Traumatic hip dislocation—a review, *Bull. NYU Hosp. Joint Dis.* 68 (2010) 91–96.
- [10] P. Kellam, R.F. Ostrum, Systematic review and meta-analysis of avascular necrosis and posttraumatic arthritis after traumatic hip dislocation, *J. Orthop. Trauma* 30 (2016) 10–16.
- [11] K. Shimizu, H. Moriya, T. Akita, M. Sakamoto, T. Suguro, Prediction of collapse with magnetic resonance imaging of avascular necrosis of the femoral head, *J. Bone Joint Surg. Am.* 76 (1994) 215–223.
- [12] T. Yamamoto, E.F. DiCarlo, P.G. Bullough, The prevalence and clinicopathological appearance of extension of osteonecrosis in the femoral head, *J. Bone Joint Surg. Br.* 81 (1999) 328–332.
- [13] T. Yamamoto, P.G. Bullough, Subchondral insufficiency fracture of the femoral head: a differential diagnosis in acute onset of coxarthrosis in the elderly, *Arthritis Rheum.* 42 (1999) 2719–2723.
- [14] S. Ikemura, T. Yamamoto, G. Motomura, Y. Nakashima, T. Mawatari, Y. Iwamoto, MRI evaluation of collapsed femoral heads in patients 60 years old or older: differentiation of subchondral insufficiency fracture from osteonecrosis of the femoral head, *AJR Am. J. Roentgenol.* 195 (2010) W63–8.
- [15] G. Motomura, T. Yamamoto, K. Miyanishi, K. Shirasawa, Y. Noguchi, Y. Iwamoto, Subchondral insufficiency fracture of the femoral head and acetabulum: a case report, *J. Bone Joint Surg. Am.* 84 (2002) 1205–1209.
- [16] S. Ikemura, T. Yamamoto, Y. Nakashima, T. Shuto, S. Jingushi, Y. Iwamoto, Bilateral subchondral insufficiency fracture of the femoral head after renal transplantation: a case report, *Arthritis Rheum.* 52 (2005) 1293–1296.
- [17] B. Vande, J. Malghem, E. Goffin, T. Duprez, B. Maldague, Transient epiphyseal lesions in renal transplant recipients: presumed insufficiency stress fractures, *Radiology* 191 (1994) 403–407.
- [18] K. Iwasaki, T. Yamamoto, Y. Nakashima, T. Mawatari, G. Motomura, S. Ikemura, et al., Subchondral insufficiency fracture of the femoral head after liver transplantation, *Skeletal Radiol.* 38 (2009) 925–928.
- [19] M. Bangil, M. Soubrier, J.J. Dubost, S. Rami, Y. Carcanagues, J.M. Ristori, et al., Subchondral insufficiency fracture of the femoral head, *Rev. Rhum. Engl. Ed.* 63 (1996) 859–861.
- [20] K. Iwasaki, T. Yamamoto, G. Motomura, T. Mawatari, Y. Nakashima, Y. Iwamoto, Subchondral insufficiency fracture of the femoral head in young adults, *Clin. Imaging* 35 (2011) 208–213.

Open Access

This article is published Open Access at sciedirect.com. It is distributed under the [IJSCR Supplemental terms and conditions](#), which permits unrestricted non commercial use, distribution, and reproduction in any medium, provided the original authors and source are credited.