



BRIEF REPORT

Use of endoscopic vacuum (E-Vac) therapy for the treatment of a cervical oesophagoileostomy leakage after a right-colon interposition for oesophageal replacement

Sonia Fernández-Ananín^{1,*}, Eulalia Ballester,¹ Carlos Guarner Argente,^{1,2} Carmen Balague¹ and Eduard M. Targarona¹

¹Department of General and Digestive Surgery, Hospital de la Santa Creu i Sant Pau, Barcelona, Spain;

²Gastroenterology and Hepatology Department, Hospital de la Santa Creu i Sant Pau, Universidad Autónoma de Barcelona, Barcelona

*Corresponding author. Department of General and Digestive Surgery, Hospital de la Santa Creu i Sant Pau, 87 Barcelona, Barcelona 08025, Spain. Tel: +34630116640; Email: sfernandez@ santpau.cat

Introduction

Anastomotic leakage is considered the Achilles heel after oesophago-gastric resection and its therapeutic management remains a challenge. Different endoscopic options, such as clips, stents, internal drainage, fibrin glue instillation, or suturing devices, have been suggested as minimally endoscopic therapies to treat these complications. Recently, the use of endoscopic vacuum (E-Vac) therapy has proven to be useful for the healing of these adverse events and some studies have even reported its superiority to other endoscopic devices [1]. The E-Vac promotes the growth of granulation tissue and increases microcirculation while providing debridement of the cavity leak in each sponge replacement by continuous negative pressure. We describe an exceptional clinical scenario in which the use of the E-Vac allows the successful closure of a cervical oesophagoileostomy leakage and the resolution of a mediastinal abscess after an ileum and right-colon interposition for oesophageal replacement.

Case presentation

A 62-year-old man diagnosed in 2017 with a cT2N0M0 adenocarcinoma of the oesophago-gastric junction underwent neoadjuvant

treatment with chemotherapy and posterior laparoscopic gastrectomy and D2 lymphadenectomy. Post-operative evolution was successful. An upper endoscopy examination 5 months later revealed a neoplastic anastomotic recurrence. An extension study showed no metastatic lesions. A resection of the oesophagojejunal anastomosis with a new oesophagojejunal anastomosis was performed without further complications.

In September 2018, a follow-up PET-CT detected a new anastomotic recurrence. The case was discussed by the Esophagogastric Tumours Committee, who decided to perform chemoradiotherapy prior to the following surgery. A total oesophagectomy with right-colon interposition with a cervical end-to-end hand-sewn oesophago-ileal anastomosis was performed 4 months later. On the fifth post-operative day, a cervical fistula appeared (Figure 1A) and a thoracic CT scan identified a 7-cm mediastinal abscess (Figure 1B). The clinical stability of the patient allowed conservative treatment with intravenous antibiotics and nutritional support by a jejunostomy tube.

Despite these measures, the anastomotic leak persisted for the next 2 months with a daily output of >500 mL. As the leakage persisted with a large cavity and high-output, in April 2019, E-Vac therapy with the Endo-SPONGE system (B. Braun

Submitted: 7 December 2019; Revised: 29 January 2020; Accepted: 12 June 2020

© The Author(s) 2020. Published by Oxford University Press and Sixth Affiliated Hospital of Sun Yat-sen University

This is an Open Access article distributed under the terms of the Creative Commons Attribution Non-Commercial License (<http://creativecommons.org/licenses/by-nc/4.0/>), which permits non-commercial re-use, distribution, and reproduction in any medium, provided the original work is properly cited. For commercial re-use, please contact journals.permissions@oup.com

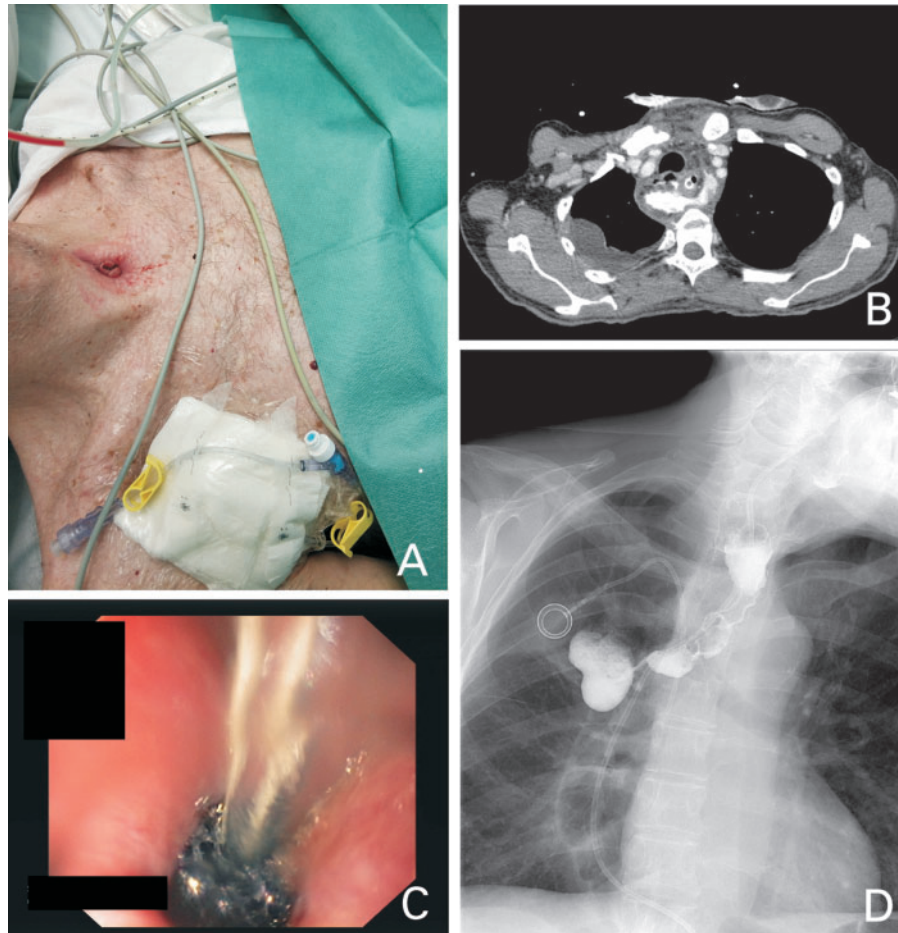


Figure 1. A cervical anastomotic leakage cured with endoscopic vacuum device. (A) Cervical oesophagoileostomy fistula after total oesophagectomy with right-colon interposition. (B) Thoracic CT scan showing mediastinal collection with extra-luminal contrast leakage. (C) Endoscopic vacuum (E-Vac) device placement. (D) Post E-Vac therapy swallow test showing correct downstream flow through the cervical anastomosis, without leakage or other complications.

Melsungen AG, Melsungen, Germany) was proposed. The sponge was placed in the cavity with a regular gastroscope under general endotracheal anaesthesia (Figure 1C). It was connected to a continuous negative pressure of 80–100 mmHg. Initially, the endosponge was replaced every 3 days, then every 10 days and every 15 days, until the complete sealing of the fistula. The total number of different E-Vac therapy exchanges required was seven.

On the 18th day after the E-Vac therapy was applied, an upper endoscopy showed the apparition of granulation tissue and an 80% decrease in cavity size. Two weeks later, a barium swallow demonstrated correct downstream flow without stenosis or evidence of leaks (Figure 1D). Oral liquid diet was started with good toleration and no further complications occurred.

Discussion

Colon interposition as an oesophageal reconstruction after oesophageal resection is a complex surgical technique that is associated with major complications. In high-volume centres, the rate of cervical anastomotic leakage, reported as a consequence of colon interposition, achieves 46%, with an operative mortality that reaches $\leq 17\%$ [2, 3].

Traditionally, if conduit necrosis is ruled out and the patient is clinically stable, conservative medical management is the usual

treatment for these complications. However, open drainage of the wound, intravenous antibiotic therapy, and *nil per oral* is sometimes ineffective and substantially prolongs hospital stay.

The case reported shows an exceptional clinical situation. While experience with E-Vac therapy in upper-gastrointestinal disorders is increasing, the majority of the published studies focus on the use of this device for the treatment of iatrogenic or spontaneous oesophageal perforations. Nevertheless, the E-Vac has also demonstrated efficacy in anastomotic leaks after surgery, especially in intrathoracic anastomosis leaks after Ivor-Lewis oesophagectomy [3–9].

Evidence published on the management of cervical fistulas after oesophageal surgery is scarce. Recently, Min et al. [10] reported the first seven cases of cervical anastomosis leaks successfully managed with E-Vac therapy. However, none of them occurred after a cervical oesophagoileostomy for oesophageal reconstruction using the terminal ileum and right colon.

Limitations that have been attributed to this endoscopic treatment are the need for hospitalization to perform the procedure, the repeated endoscopic examinations, and the cost of the material required. On the other hand, the achievement of several endoscopies during the process allowed us to assess the evolution of the defect, to irrigate, and to debride the cavity until its complete closure.

In our case, the use of E-Vac therapy shortened the hospital stay compared to conservative treatment, allowing the

successfully closure of the cervical fistula at Day 21 after the beginning of the E-Vac therapy, with optimal functional results. The duration of treatment until the closure of the fistula in our case was similar to that published in other series.

Although the nature of the series published to date is retrospective and heterogeneous due to different types of anastomosis and localization, E-Vac therapy is positioning itself as a good therapeutic option for the management of anastomotic leakages in upper-gastrointestinal surgery. Further randomized studies are needed to include this device in the multidisciplinary algorithm and standardize treatment guidelines of these major complications.

Authors' contributions

All authors have participated in the preparation and revision of this paper.

Funding

None.

Conflicts of interest

None declared.

References

1. Brangewitz M, Voigtlander T, Helfritz FA et al. Endoscopic closure of esophageal intrathoracic leaks: stent versus endoscopic vacuum-assisted closure, a retrospective analysis. *Endoscopy* 2013;**45**:433–8.
2. Hamai Y, Hihara J, Emi M et al. Esophageal reconstruction using the terminal ileum and right colon in esophageal cancer surgery. *Surg Today* 2012;**42**:342–50.
3. Davis PA, Law S, Wong J. Colonic interposition after esophagectomy for cancer. *Arch Surg* 2003;**138**:303–8.
4. Mencio M, Ontiveros E, Burdick J et al. Use of a novel technique to manage gastrointestinal leaks with endoluminal negative pressure: a single institution experience. *Surg Endosc* 2018;**32**:3349–56.
5. Goenka M, Goenka U. Endotherapy of leaks and fistula. *World J Gastrointest Endosc* AU
6. Still S, Mencio M, Ontiveros E et al. Primary and rescue endoluminal vacuum therapy in the management of esophageal perforations and leaks. *Ann Thorac Cardiovasc Surg* 2018;**24**:173–9.
7. Laukoetter MG, Mennigen R, Neumann PA et al. Successful closure of defects in the upper gastrointestinal tract by endoscopic vacuum therapy (EVT): a prospective cohort study. *Surg Endosc* 2017;**31**:2687–96.
8. Smallwood NR, Fleshman JW, Leeds SG et al. The use of endoluminal vacuum (E-Vac) therapy in the management of upper gastrointestinal leaks and perforations. *Surg Endosc* 2016;**30**:2473–80.
9. Bludau M, Hölscher AH, Herbold T et al. Management of upper intestinal leaks using an endoscopic vacuum-assisted closure system (E-VAC). *Surg Endosc* 2014;**28**:896–901.
10. Min YW, Kim T, Lee H et al. Endoscopic vacuum therapy for postoperative esophageal leak. *BMC Surg* 2019;**19**:37.