




Contents lists available at ScienceDirect

JPRAS Open

journal homepage: [www.elsevier.com/locate/jpra](http://www.elsevier.com/locate/jpra)



# Peripheral histological clearance of cutaneous BCC and SCC excised using the wet blotting technique

Mamoona Khalid-Raja<sup>1,\*</sup>, Nina Mistry<sup>1</sup>, Shahram Anari<sup>1</sup>

Department of Otolaryngology, Heartlands Hospital, Birmingham, UK

## ARTICLE INFO

### Article history:

Received 24 August 2017

Revised 22 March 2018

Accepted 15 April 2018

Available online 5 May 2018

### Keywords:

Basal cell carcinoma  
Squamous cell carcinoma  
Skin neoplasms  
Margins of excision

## ABSTRACT

**Introduction:** Accurate identification of the peripheral margin of cutaneous basal cell and squamous cell carcinomas plays a crucial role in ensuring complete excision of the skin cancer. The recommended margin of excision for cutaneous malignancies varies in the current guidelines. The aim of this study was to assess the success rate of peripheral margin clearance with a 4 mm peripheral margin of excision when the clinical margin of the lesion has been identified using the wet blotting technique.

**Methods:** The peripheral margin of each skin cancer was marked using the wet blotting technique and a 4-mm margin of excision rule was applied to all skin cancers regardless of their type and other clinical features. Data collection was performed from patients who were operated on over a period of 34 months (2011 to 2014). Information gathered included patient demographics, clinical details of the lesion and histopathological data.

**Results:** The total number of patients identified were 456. The case notes were reviewed and eventually 276 patients were included and 180 patients were excluded. The histology report showed 95–97% clearance of the peripheral margin in all BCCs and SCCs regardless of their clinical features and their location.

\* Corresponding author.

E-mail address: [m.raja@hotmail.co.uk](mailto:m.raja@hotmail.co.uk) (M. Khalid-Raja).

<sup>1</sup> Institution where work done: Department of Otolaryngology, Heartlands Hospital, Birmingham, UK (Hospital R&D number 4347).

**Conclusions:** Our study has shown that a standard rule of maintaining a 4 mm margin around all head and neck skin BCCs and SCCs, measured after the visible margin of the lesion had been accurately identified by the wet-blotting technique, can successfully achieve 95–97% peripheral clearance of all lesions, irrespective of the subtype, size and location.

© 2018 Published by Elsevier Ltd on behalf of British Association of Plastic, Reconstructive and Aesthetic Surgeons.  
This is an open access article under the CC BY-NC-ND license.  
(<http://creativecommons.org/licenses/by-nc-nd/4.0/>)

## Introduction

Basal cell carcinoma (BCC) and Squamous cell carcinoma (SCC) of the skin are common cancers in the Caucasian population and their incidence is on the rise worldwide. The most significant risk factors are exposure to sunlight, advancing age and skin type.<sup>1</sup> Cutaneous skin cancers have a predilection for sun-exposed areas, affecting the head and neck and the dorsum of the hands.<sup>1</sup> Dermatoscopy can aid in the diagnosis of cutaneous skin cancers however a biopsy of the lesion is usually required for definitive diagnosis.

Although it is important to maintain normal tissue function and satisfactory cosmetic results in sensitive areas, it is important to obtain complete histologically confirmed tumour resection in order to achieve local control and preserve patient survival.<sup>1</sup> Current guidance has shown that a 4 mm margin is sufficient to remove 95% of clinically well-defined low risk tumours measuring less than 2 cm diameter.<sup>1</sup> In tumours greater than 2 cm diameter or tumours measuring more than 6 mm thickness or tumours with high risk prognostic features, a margin of at least 6–10mm is recommended.<sup>1</sup> The European Dermatology Forum (EDF), the European Association of Dermato-Oncology (EADO) and the European Organization for Research and Treatment of Cancer (EORTC) advises a standardised minimum margin of 5 mm for low risk tumours while an extended margin of 10 mm is advised for high risk lesions. The depth of the excision should involve the hypodermis.<sup>1</sup>

Mohs micrographic surgery (MMS) utilises peri-operative histological margin control and is considered the most accurate technique for ensuring complete removal of the lesion with minimal removal of surrounding healthy tissue; it is the technique of choice in cosmetically sensitive areas especially with infiltrating variants of BCC. However MMS has limitations including a high cost, it is time consuming and requires specialised staff.<sup>2</sup>

Determination of the precise clinical margin can be difficult with some cutaneous cancers, notably infiltrative and morpheoic BCCs and therefore various methods have been proposed to overcome this. These include reflectance confocal microscopy (RCM)<sup>3</sup> and Multiphoton Multispectral Fluorescence (MMF).<sup>4</sup>

There is conflicting evidence regarding the role of loupe magnification in achieving complete excision of cutaneous cancers.<sup>5–7</sup>

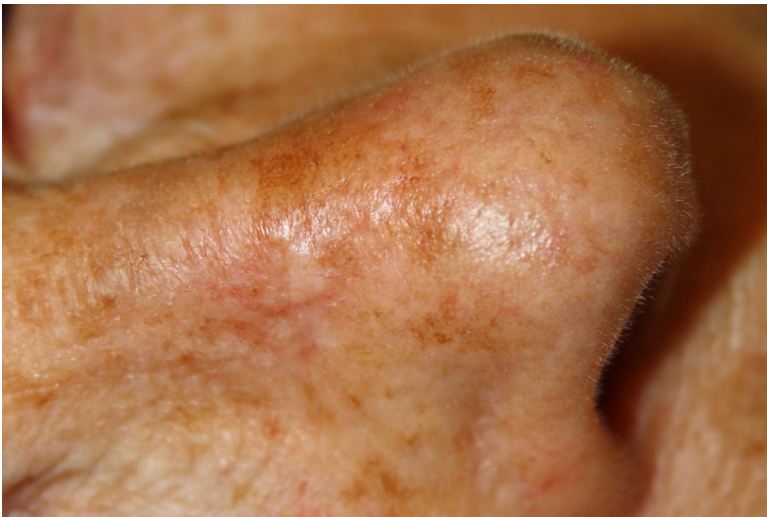The main aim of this study was to illustrate that a 4mm peripheral excision margin is sufficient for any type, size or location of cutaneous BCC and SCC skin cancers providing that the initial peripheral margin of the lesion has been accurately identified by the wet-blotting technique.

## Materials and methods

Data collection was performed from patients who were operated on between 24/05/2011 and 23/12/2014 which spanned a time period of 34 months. These patients were referred by the dermatology team and the lesions were excised using the wet-blotting technique.

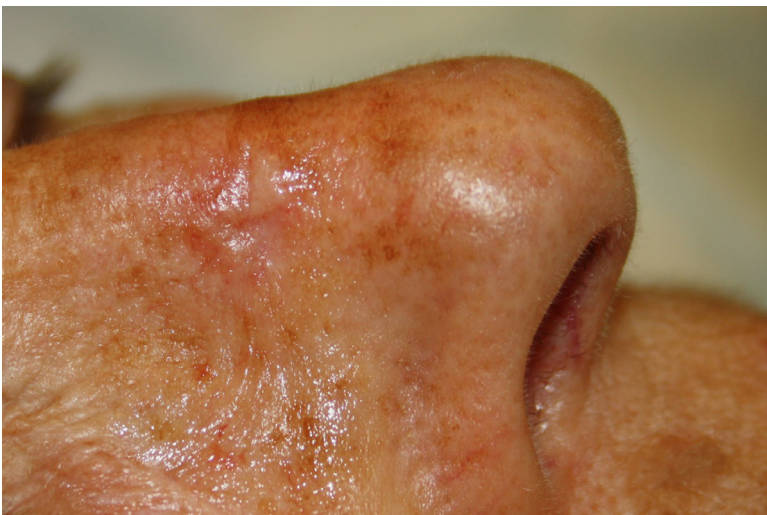The senior author (SA) uses a technique whereby the skin surrounding the cancer lesion is dabbed with a damp swab and examined using a headlight. This allows better identification of the borders of the lesion with the naked eyes; any irregularity of the skin texture is considered as the extension

of the lesion. This margin is marked as the clinical visible margin and then a further 4 mm safety margin is measured which represents the margin of excision (Figure 1). Local anaesthetic infiltration follows and the dissection technique involves adhering close to these margins and keeping the scalpel perpendicular to the skin. The specimen is handled carefully with skin hooks to avoid potential tearing through which would affect margin assessment during the histological assessment. The depth of excision is down to the first fascial layer or periosteum or perichondrium (in pinna lesions, the cartilage is removed with the specimen). The specimen has a marker suture applied and is immediately



**Figure 1.** Wet blotting technique to delineate the peripheral margin of the skin lesion; (a): The photo taken from the skin lesion on the right nasal sidewall (prior to wet blotting), (b): The lesion has been wet blotted and the peripheral margin is more visible to the naked eye, (c): The peripheral margin visible to the eye has been marked, (d): The 4 mm safety margin has been drawn around the peripheral margin.

The histology result for this particular case showed the lesion to be an infiltrative basal cell carcinoma and the peripheral clearance margins for 12 o'clock, 3 o'clock, 6 o'clock and 9 o'clock were 4 mm, 3.5 mm, 4 mm and 3.5 mm, respectively.



**Figure 1.** Continued

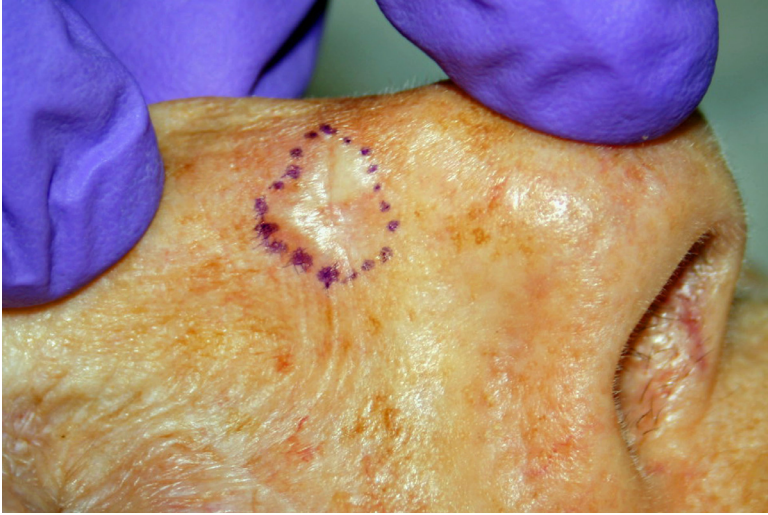

Figure 1. Continued

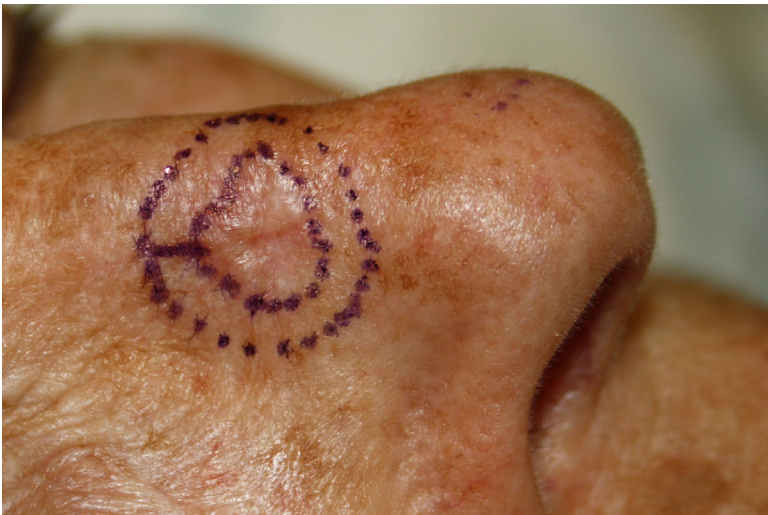

Figure 1. Continued

placed in formalin and sent for assessment. The patient is consented for photos peri-operatively to provide accurate images of the lesion before surgery, once the lesion margins are outlined, once the lesion is excised and finally following closure and reconstruction. The senior author keeps a database record of the lesions excised with photographs as a means of audit and quality assurance.

All SCC cases, complicated BCC cases or cases with close margin of excision (i.e. less than 1 mm) were discussed at the Skin MDT and the specimens were considered completely excised if agreed by the panel. The multidisciplinary panel reviewed factors including the actual margin size, along with the size and location of the lesion, the histological subtype and characteristics of the lesion in order to decide if close margin specimens can be considered as completely excised or if they require re-excision.

The results were tabulated and analysed using Microsoft Excel.

**Table 1**

The number of BCCs excised completely, incompletely and those with a peripheral or deep margin of less than 1 mm.

	BCC	Number (Total <i>n</i> =187) (Total <i>n</i> =187)	%	
BCCs considered as incompletely excised	Incompletely excised peripheral	6	3.21	
	Incompletely excised deep	2	1.07	
	Incompletely excised peripheral and deep	1	0.53	
	Total incompletely excised	9	4.81	
BCCs considered as completely excised	<b>Completely excised peripheral (including the close-margin cases)</b>	<b>180</b>	<b>96.26</b>	
	<b>Completely excised peripheral (excluding the close-margin cases)</b>	<b>177</b>	<b>94.65</b>	
	Completely excised deep (including the close margin cases)	184	98.40	
	Completely excised deep (excluding the close margin cases)	178	95.18	
	Total complete excision (peripheral and deep margins)	178	95.19	
	Cases with close margin (i.e. <1mm)	Peripheral <1 mm	3	1.69
		Deep <1 mm	6	3.37
		Total excised with close margins	9	5.06

The inclusion criteria was adult patients with a cutaneous BCC or SCC requiring primary surgery using the “wet blotting technique” which has been described above.

The exclusion criteria were cases with benign pathology, malignant pathology different to BCC or SCC, cases carried out using MMS and re-excision cases.

Audit department approval was sought prior to conducting this study. Consent for all photographs were obtained from the patients in accordance with the local departmental policy.

## Results

The total number of patients who had a skin lesion excised between 24/05/2011 and 23/12/2014 was 456 patients. The case notes were reviewed and eventually 276 patients were included and 180 patients were excluded according to the exclusion criteria.

In this group of 276 patients, there were 227 males and 49 females with an average age of 77.7 years (range: 28 years to 99 years old).

The skin cancers were classified into BCCs and SCCs in order to be analysed separately.

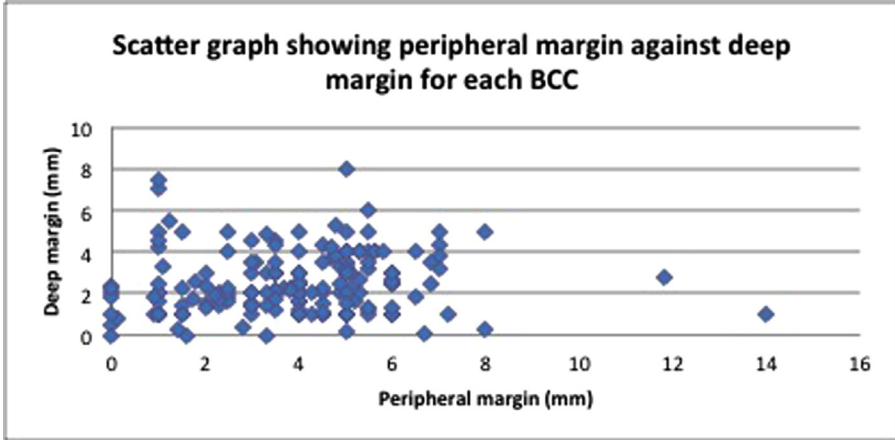
The result of analysis for BCC lesions are demonstrated in [Table 1](#). Our results show that the BCC lesions were fully excised in at least 95% of the cases. However nine lesions had an incomplete excision that required re-excision. Also, nine cases with close excision margins were discussed at skin MDT and did not require re-excisions. If we consider the cases with close peripheral margins as incompletely excised, the successful excision rate stands at 95% (177 peripheral clearances out of the total of 187 cases). This supports the acceptable outcome for peripheral margin clearance of BCCs employing a 4 mm excision margin with the help of the wet-blotting technique.

The peripheral clearance margin for BCC ranged from 0.1 to 14 mm and the mean peripheral margin was 3.73 mm (median 4 mm) ([Table 2](#), [Figure 2](#)). This essentially indicates that the wet-blotting technique identifies the true margin of the lesion with an acceptable accuracy. Two lesions had a peripheral margin greater than 10 mm: one was an infiltrative BCC on the pinna which was treated

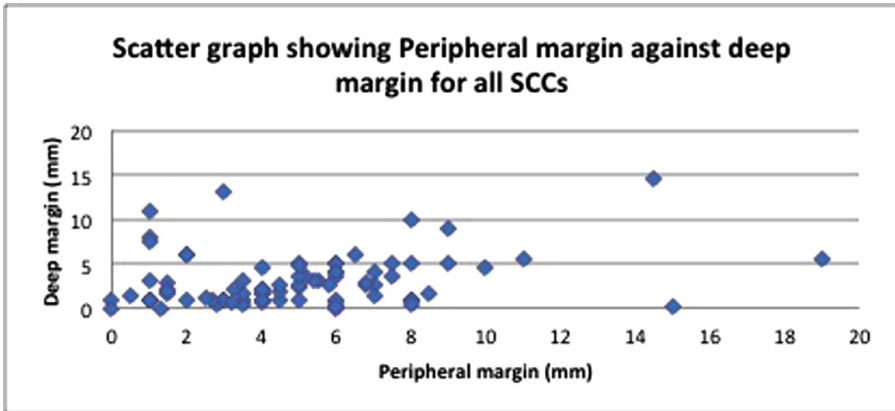
**Table 2**

The variation in margin size for both peripheral and deep margin for all basal cell carcinoma excisions.

Margin size	<1 mm	1.0–4.9	5.0–9.9	>10.0	Total
Peripheral	10	113	62	2	187
Deep	10	163	14	0	187



**Figure 2.** A scatter graph showing the peripheral margin against deep margin for all BCCs.



**Figure 3.** A scatter graph showing peripheral margin against deep margin for all excised SCCs.

with a wedge excision; the second was a nodular and infiltrative BCC on the helix of the ear that was excised along the length of the helix and the wound was closed side-by-side directly.

The data on the SCC specimens show the peripheral clearance of the specimens in excess of 96% of the cases (Table 3). The peripheral clearance margin for SCC ranged from 0.5 mm to 19.0 mm and the mean peripheral clearance was 4.86 mm (median 4.5 mm) (Table 4, Figure 3). Five lesions had a peripheral margin greater than 10 mm, three of these were lesions on the scalp and the other two lesions affected the pinna (one was a wedge excision and the second was a partial pinna amputation). If we consider the cases with close peripheral margins as incompletely excised, the successful excision rate stands at 97% (86 peripheral clearance of more than 1 mm out of the total of 89 cases). This

**Table 3**

The number of SCCs excised completely, incompletely and those with a peripheral or deep margin of less than 1 mm.

	SCC	Number (Total n=89)	%	
SCCs considered as incompletely excised	Incompletely excised peripheral	1	1.12	
	Incompletely excised deep	2	2.25	
	Incompletely excised peripheral and deep	1	1.12	
	Total incomplete excisions	4	4.49	
SCCs considered as completely excised	<b>Completely excised peripheral (including the close margin cases)</b>	<b>87</b>	<b>97.75</b>	
	<b>Completely excised peripheral (excluding the close margin cases)</b>	<b>86</b>	<b>96.62</b>	
	Completely excised deep (including the close margin cases)	86	96.63	
	Completely excised deep (excluding the close margin cases)	75	84.26	
	Total complete excisions	83	93.26	
	Cases with close margin (i.e. <1 mm)	Peripheral <1 mm	1	1.20
		Deep <1 mm	11	13.25
		Total excised with close margins	12	14.46

**Table 4**

Variation in margin size for both peripheral and deep margin for all squamous cell carcinoma excisions.

Margin size	<1 mm	1.0–4.9	5.0–9.9	>10.0	Total
Peripheral	3	43	38	5	89
Deep	15	56	14	4	89

supports the acceptable outcome for peripheral margin clearance for SCCs with the help of the wet-blotting technique and a 4 mm clinical safety margin of excision.

#### Positive margin specimens

In total, 13 (4.71%) of the excision biopsies had positive margins, in this group nine were BCCs and four were SCCs (Table 5). From these 13 positive margin specimens, three showed the lesion to be over 2 cm, one had no diameter documented on the histology form and nine lesions measured 2 cm or less.

#### Close margin specimens (<1 mm)

Twenty specimens had close margins (8 BCCs and 12 SCCs). Seven of the lesions measured over 2 cm while 13 measured 2 cm or less.

One SCC was close at the peripheral margin and 3 BCCs were close at the peripheral margin; the rest were close at the deep margin.

These lesions were discussed at the Skin MDT and a recommendation was made whether any further surgical excision was required. Our data on Tables 1 and 3 show the rate of complete excision whether the close-margin cases were incorporated with the completely-excised group or not.

**Table 5**

The details of the 9 BCCs and 4 SCCs with positive margins.

Basal Cell Carcinoma	Location	Histopathology	Peripheral margin (mm)	Deep margin(mm)
BCC 1	Dorsum of nose	Infiltrative	Positive	Positive
BCC 2	Pre-auricular	Infiltrative	Positive	0.5
BCC 3	Tip of nose	Nodular and superficial	Positive	2
BCC 4	Helix of ear	Nodular and micro nodular	Positive	2.4
BCC 5	Nostril	Nodular	3.3	Positive
BCC 6	Ear	Nodular	Positive	1.8
BCC 7	Ear	Nodular and infiltrative	Positive	1
BCC 8	Forehead	Superficial	Positive	2.3
BCC 9	Left nasal alar	Nodular	1.6	Positive
SCC 1	Ear(conchal bowl)	Moderately differentiated	Positive	1
SCC 2	Pre-auricular	Moderately differentiated	Positive	Positive
SCC 3	Nose (alar)	Moderately differentiated	1.3	Positive
SCC 4	Temple	Poorly differentiated	6	Positive

### Lesions over 2 cm

Thirty four lesions measured over 2 cm in maximum diameter (22 SCCs and 12 BCCs). Of these lesions, three had positive margins at either peripheral, deep or both margins and required re-excision and 31 lesions were fully excised. This meant 91.2% of lesions measuring over 2 cm were completely excised with a 4 mm margin while using the technique described in this paper.

### Infiltrative and micronodular BCC

In our group of patients, 53 had infiltrative BCC, 52 had mixed type histology with an infiltrative component and two were micronodular, which gave a total of 107 cases. The complete excision rate was 101/107 (94.3%) cases. Out of these 101 cases, one case had both peripheral and deep margins of less than 1 mm and three other cases were close on peripheral or deep margin (i.e. <1 mm). The incomplete excision rate was 5.6% and is generally in keeping with the rest of the data showing that this technique can be successfully used for infiltrative and micronodular BCC too.

## Discussions

### Margin of excision

Our results show that using a technique of excising all head and neck BCCs and SCCs with a standard margin of 4 mm irrespective of size or histological subtype, will achieve at least 95% peripheral margin clearance. This technique avoids excessive margins which may lead to large defects requiring complex reconstruction and possible unfavourable cosmetic outcomes yet results in acceptable clearance rate.

The Head and Neck Cancer Multidisciplinary Management Guidelines (HNCMMG) published in September 2011<sup>8</sup> and the British Association of Dermatology (BAD) guidelines document 95% complete excision rates with a 4-5mm margin<sup>8,9</sup> and the deep margin should include fat.<sup>8</sup> However morphoeic and large BCCs have a propensity for sub-clinical tumour extension<sup>8</sup> therefore these lesions require wider surgical margins.<sup>9</sup> The BAD guidelines outline that for morphoeic lesions a margin of 5mm leads to an 82% clearance while a 13–15 mm is associated with an over 95% complete excision rate, and lesions over 2 cm should be considered for MMS.<sup>9</sup>

The HNCMMG advises a 4 mm margin for low risk SCC and MMS is recommended for SCC with adverse histological features, especially in anatomically critical sites.

Motley et al. published the Management guidelines for SCC for the BAD in 2009. They advised that clinically well-defined, low risk tumours, less than 2 cm diameter should be excised with a minimum 4 mm margin. Tumours over 2 cm, high risk and extending into the subcutaneous tissue should be



excised with a minimum of 6 mm margin or MMS.<sup>10</sup> This was also supported by the work done by Brodland et al.<sup>11</sup>

Our study has shown that using the same technique of ensuring a 4 mm safety margin after accurately identifying the clinical margin of the lesion by the wet-blotting technique achieves at least 95% and 97% peripheral margin clearance of head and neck BCCs and SCCs, respectively irrespective of the size, site and differentiation.

#### *Excessive tissue sacrifice*

Griffiths et al published data where surgical loupes (x3.5 magnification) were used when marking around the visible lesion and then excising with a 2–3 mm margin or 5 mm around indistinct lesions.<sup>12</sup> They graded excision margins (depending on the site) as: (1) Not excessive: <5mm, (2) Probably acceptable: 5.0–9.9 mm, and (3) Excessive: >10 mm.<sup>12</sup> They found that peri-auricular and peri-orbital lesions had a higher percentage of incomplete excision. The overall incomplete excision rate for BCC was 8.4%.<sup>12</sup>

Our study showed that for BCCs 60.4% (113/187) of surgical margins peripherally were in the 1.0–4.9 mm group, 33.1% (62/187) were in the 5.0–9.9 mm group and only 1.1% (2/187) measured over 10 mm. This shows that the majority of lesions were excised without excessive normal tissue sacrifice. There were two cases with excision margins of over 10 mm: one was a mixed type nodular and infiltrative BCC on the helix of the ear which the skin was closed directly side to side; the second was an infiltrative BCC from the pinna which was removed with a wedge; hence the larger margins.

Similarly for the SCC, our study showed that 48.3% (43/89) had surgical excision margins within the 1.0–4.9 mm group (not excessive), 42.7% (38/89) had excision margins within the 5.0–9.9 mm group (acceptable) and 5.6% (5/89) had excision margin of over 10 mm considered excessive depending on the site. Three of these cases were on the scalp with surrounding actinic damage making it difficult to accurately identify the margins<sup>13</sup> and two cases were pinna lesions, one requiring a wedge excision and the second requiring a partial pinnectomy.

#### *Mixed histology subtype*

Betti et al. found in general that mixed histological types were more aggressive than single type BCCs.<sup>14</sup> Our study did not show any significant correlation between mixed histological subtypes and increased aggressiveness. 128/187 were single type BCCs while 59/187 were mixed type histology. 4.68% (6/128) of the single type BCCs had peripheral margin involvement, while 5.08% (3/59) of the mixed histological subtype had peripheral margin involvement.

#### *Positive and close peripheral margin*

There were six cases of positive peripheral margin (3.2%, 6/187) and three cases of close peripheral margin (1.69%, 3/187) in the BCC group. Whereas in the SCC group, one case had a positive peripheral margin (1.1%, 1/89) and one case had a close peripheral margin (1.2%, 1/89).

We have produced our peripheral clearance margin data both with and without the close-margin specimens included (Tables 1 and 3); either way the clearance rate is within the acceptable range (95–98%).

The SCCs with close margins were all located in different parts of the head and neck with no pattern emerging to location. However they did appear to be more aggressive with 5 out of the 12 being poorly differentiated. The majority of the close margin cases in SCCs involved the deep margin. This was due to the nature, size and the locations of the lesions affecting the clearance of the deep margin.

#### *Limitations*

The main limitations of our study are that it is a single series conducted in one institution by a single surgeon. There was no comparison group or control group and the results may have been

affected by study bias. There was no data on long term follow up of these patients, in particular the cases of close margins and so there is no information regarding local or distant recurrence.

## Conclusions

Our study has shown that a standard rule of maintaining a 4mm margin around the head and neck skin BCCs and SCCs, measured after the visible clinical margin of the lesion has been accurately identified and marked by the wet-blotting technique, can successfully achieve a peripheral margin clearance of at least 95% and 97% respectively, irrespective of the subtype, size and location. This technique avoids excessive normal tissue sacrifice yet results in an acceptable peripheral margin clearance rate in excision of the head and neck skin BCCs and SCCs.

## Financial closure

None

## Conflict of interest

None

## References

1. Stratigos A, Garbe C, Lebbe C, et al. On behalf of the European Dermatology Forum (EDF), the European Association of Dermato-Oncology (EADO) and the European Organisation for Research and Treatment of Cancer (EORTC) Diagnosis and treatment of invasive squamous cell carcinoma of the skin: European consensus – based interdisciplinary guideline. *Eur J Cancer*. 2015;51:1989–2007.
2. Moncrieff MD, Shah AK, Igali L, et al. False-negative rate of intraoperative frozen section margin analysis for complex head and neck nonmelanoma skin cancer excisions. *Clin Exp Dermatol*. 2015;40:834–838.
3. Venturini M, Gualdi G, Zanca A, et al. A new approach for presurgical margin assessment by reflectance confocal microscopy of basal cell carcinoma. *Br J Dermatol*. 2016;174:380–385.
4. Patalay R, Talbot C, Alexandrov Y, et al. Multiphoton multispectral fluorescence lifetime tomography for the evaluation of basal cell carcinomas. *PLoS One*. 2012;7(9):e43460.
5. Webbstein R, Kalbermatten DF, Rieger U, et al. High magnification assessment improves complete resection of facial tumors. *Ann Plast Surg*. 2006;57(5):517–520.
7. Hoefkens MF, Fabre J, Kusters-Vandeveldt. Does Loupes magnification reduce the gap between the macroscopic and microscopic border of a basal cell carcinoma? A prospective clinical study. *Ann Plast Surg*. 2014;72(5):579–583.
8. ENT UK trading as British Academic Conference in Otolaryngology and British Association of Otorhinolaryngology Head and Neck Surgery. ENT UK. 4th ed., 2011.
9. NICE, Improving outcomes for people with skin tumours including melanoma. In: Cancer Service Guideline (CSG8), NICE, published February 2006 with a partial update May 2010. [www.nice.org.uk/guidance/csg8/resources/improving-outcomes-for-people-with-skin-tumours-including-melanoma-2010-partial-update-2010-773380189](http://www.nice.org.uk/guidance/csg8/resources/improving-outcomes-for-people-with-skin-tumours-including-melanoma-2010-partial-update-2010-773380189)
10. Motley RJ, Preston PW, Lawrence CM. Multi-professional guidelines for the management of the patient with primary cutaneous SCC, 2009. *Br J Dermatol*. 2002;146:18–25 Update of the original guideline which appeared in British Journal of Dermatology.
11. Brodland DG, Zitelli JA. Surgical margins for excision of primary cutaneous squamous cell carcinoma. *J Am Acad Dermatol*. 1992 Aug;27(2 pt 1):241–248.
12. Griffiths RW, Suvarna SK, Stone J. Basal cell carcinoma histological clearance margins: an analysis of 1539 conventionally excised tumours. Wider still and deeper? *J Plast Reconstruct Aesthet Surg*. 2007;60:41–47.
13. Apalla Z, Calzavara-Pinton P, Lallas A, et al. Histopathological study of perilesional skin in patients diagnosed with non-melanoma skin cancer. *Clin Exp Dermatol*. 2016;41:21–25.
14. Betti R, Radaelli G, Crosti C, et al. Margin involvement and clinical pattern of basal cell carcinoma with mixed histology. *J Eur Acad Dermatol Venereol*. 2012;26:483–487.