



# Gallbladder adenoma in a domestic shorthair cat

Catherine Broadbridge<sup>1</sup> , Samantha S Taylor<sup>1</sup>, Helen Renfrew<sup>1</sup>, Francesco Gemignani<sup>1</sup>, Veronique Livet<sup>1</sup>, Tom Vicek<sup>2</sup> and Melanie Dobromylskyj<sup>2</sup>

*Journal of Feline Medicine and Surgery Open Reports*  
1–7

© The Author(s) 2021

Article reuse guidelines:

sagepub.com/journals-permissions

DOI: 10.1177/2055116921997665

journals.sagepub.com/home/jfmsopenreports

This paper was handled and processed by the European Editorial Office (ISFM) for publication in *JFMS Open Reports*



## Abstract

**Case summary** A 13-year-old neutered female domestic shorthair rescue cat presented asymptotically with raised hepatic enzymes following a routine pre-anaesthetic blood test. Cholangitis was suspected, and supportive treatment with 2 weeks of amoxicillin–clavulanic acid and 4 weeks of ursodeoxycholic acid and S-adenosylmethionine was trialled, with no improvement in biochemistry parameters. Clinicopathological investigations also revealed a markedly raised total bilirubin and abnormal bile acid stimulation test. Abdominal ultrasonography revealed pathological changes in the gallbladder, hepatomegaly with increased echogenicity and markedly thickened common bile duct walls. An exploratory laparotomy was performed revealing a grossly abnormal gallbladder with a small rupture at the dorsal fundus, which was managed via cholecystectomy. Pancreatic and hepatic biopsies were collected concurrently. Histopathology from the submitted samples revealed a gallbladder adenoma, chronic neutrophilic cholangitis and nodular hyperplasia of the pancreas. Culture of the gallbladder bile was negative but may be attributable to the initial treatment with antibiotics. At the time of writing, 5 months postoperatively, the cat had recovered well and remained asymptomatic and clinically healthy, but hepatic enzymes and bilirubin were only mildly reduced from the preoperative levels, despite the cat remaining clinically normal.

**Relevance and novel information** To our knowledge, this is the first case of a gallbladder adenoma confirmed histopathologically in a feline patient. Our findings suggest that although gallbladder neoplasia is rare in cats, this benign tumour should be considered a differential diagnosis.

**Keywords:** Gallbladder; cholecystectomy; adenoma; neoplasia

**Accepted:** 30 January 2021

## Introduction

Gallbladder adenomas, which can also be classified as extrahepatic cholangiocellular adenomas, are a benign neoplasm originating from the epithelial mucosal layer. They consist of cuboidal-to-columnar epithelium lining fibrous stalks, and may often have papillary projections that invade into the lumen, which create a rugose surface.<sup>1</sup> They are a rare neoplasm in all species affected by this condition. Typically, they affect young cattle, but this may be due, in part, to the timing of slaughter at abattoirs.<sup>2</sup> Infrequent reports of cases exist in other species such as dogs, pigs, mice and chimpanzees,<sup>3–6</sup> but they have never been described in cats. In human medicine the incidence is reported at 4% of all gallbladder polypoid masses,<sup>7</sup> and controversy exists surrounding a possible malignant transformation between gallbladder

adenoma to adenocarcinoma.<sup>8,9</sup> Bile duct adenomas are also described in cats, documented in >50% of all feline hepatobiliary neoplasias.<sup>10,11</sup>

## Case description

A neutered female 13-year-old domestic shorthair cat presented to a referral centre for further investigations of elevated liver enzymes, following incidental identification at

<sup>1</sup>Lumbry Park Veterinary Specialists, Alton, UK

<sup>2</sup>Finn Pathologists, Harleston, UK

### Corresponding author:

Catherine Broadbridge BVSc, MRCVS, Lumbry Park Veterinary Specialists, Selborne Road, Alton, Hampshire GU34 3HL, UK  
Email: kbroadbridge@live.com



Creative Commons Non Commercial CC BY-NC: This article is distributed under the terms of the Creative Commons

Attribution-NonCommercial 4.0 License (<https://creativecommons.org/licenses/by-nc/4.0/>) which permits non-commercial use, reproduction and distribution of the work without further permission provided the original work is attributed as specified on the SAGE and Open Access pages (<https://us.sagepub.com/en-us/nam/open-access-at-sage>).

the referring veterinary practice during routine preoperative bloods. The cat had only been living with the current owners for 4 months but had been known to the owner for many years as a free-living cat, and no health problems had been noted. The referring veterinary practice had run in-house serum biochemistry, which revealed an alkaline phosphatase (ALP) 6.5 times higher than the upper limit of the reference interval (RI; 441 IU/l [RI 11–67 IU/l]). Additionally, alanine aminotransferase (ALT) was at almost 12 times the upper limit of the RI (>1000 IU/l; RI 18–84 IU/l); total bilirubin was not measured. Abdominal ultrasonography was performed during this visit, revealing changes consistent with cholangiohepatitis, dilated biliary tract and pancreatic fibrosis. A 2-week course of amoxicillin–clavulanic acid (15 mg/kg q12h PO [Synuclav; MiPet CVS]) and a 4-week course of ursodeoxycholic acid (10 mg/kg q24h PO [Destolit; Norgine]) and S-adenosylmethionine (90 mg S-adenosylmethionine and 9 mg silybin q24h PO [Denamarin; Protexin]) was prescribed.

At a follow-up appointment 4 weeks later, external serum biochemistry showed ongoing marked increases in liver enzymes but with some improvement: ALT 703 IU/l (RI 18–77 IU/l), ALP 330 IU/l (RI 11–67 IU/l), aspartate aminotransferase (AST) 240 IU/l (RI 0–69 IU/l) and total bilirubin (51.2 µmol/l; RI 0–10 µmol/l). Fasted serum cholesterol was moderately increased (18.1 mmol/l; RI 0.9–6.5 mmol/l) and albumin was within normal limits. A bile acid stimulation test was markedly abnormal; pre-prandial bile acids were 59.6 µmol/l (RI 0–15 µmol/l) and post-prandial bile acids were 404.3 µmol/l (RI 0–20 µmol/l). External haematology documented a very mild leukocytosis ( $15.8 \times 10^9/l$ ; RI  $4\text{--}15 \times 10^9/l$ ). Serology for feline leukaemia virus (FeLV) and feline immunodeficiency virus (FIV) was negative. The cat remained clinically normal, but ongoing liver enzyme elevations prompted referral.

On initial presentation to the referral centre the cat weighed 3.55 kg (body condition score 4/9) and other than a small, soft, mobile mass on the left abdominal flank and another at the base of the tail, the physical examination was unremarkable. In-house serum biochemistry (Table 1) demonstrated markedly elevated ALT (>1000 IU/l; RI 18–84 IU/l) and ALP (344 IU/l; RI 11–67 IU/l). A mild azotaemia was documented (urea 13.8 mmol/l [RI 6.10–12.50 mmol/l] and creatinine 155 µmol/l [RI 44–194 µmol/l]), which was a novel finding. Total bilirubin was markedly raised (45 µmol/l; RI 0–10 µmol/l), most likely of hepatic or post-hepatic origin. Prehepatic hyperbilirubinaemia had been considered unlikely as the patient was not anaemic and FeLV and FIV had been excluded. Ammonia and coagulation times were normal. Systolic blood pressure was within normal limits and urinalysis revealed concentrated urine.

Based on these findings an abdominal ultrasound was performed under sedation. The cat was sedated

**Table 1** Serum biochemistry

Parameter	Result	RI
Total protein (g/l)	88.0	56.0–81.0
Albumin (g/l)	29.0	26.0–42.0
Globulin (g/l)	59.0	15.0–57.0
A:G ratio	0.5	0.6–1.4
ALP (IU/l)	344.0	11.0–67.0*
ALT (IU/l)	>1000	18.0–84.0*
Total bilirubin (µmol/l)	45.0	0–10.0*
Urea (mmol/l)	13.8	6.1–12.5*
Creatinine (µmol/l)	155.0	45.0–194.0*
Glucose (mmol/l)	7.0	3.8–8.2

\*Notable finding

RI = reference interval; A:G = albumin to globulin ratio; ALP = alkaline phosphatase; ALT = alanine aminotransferase

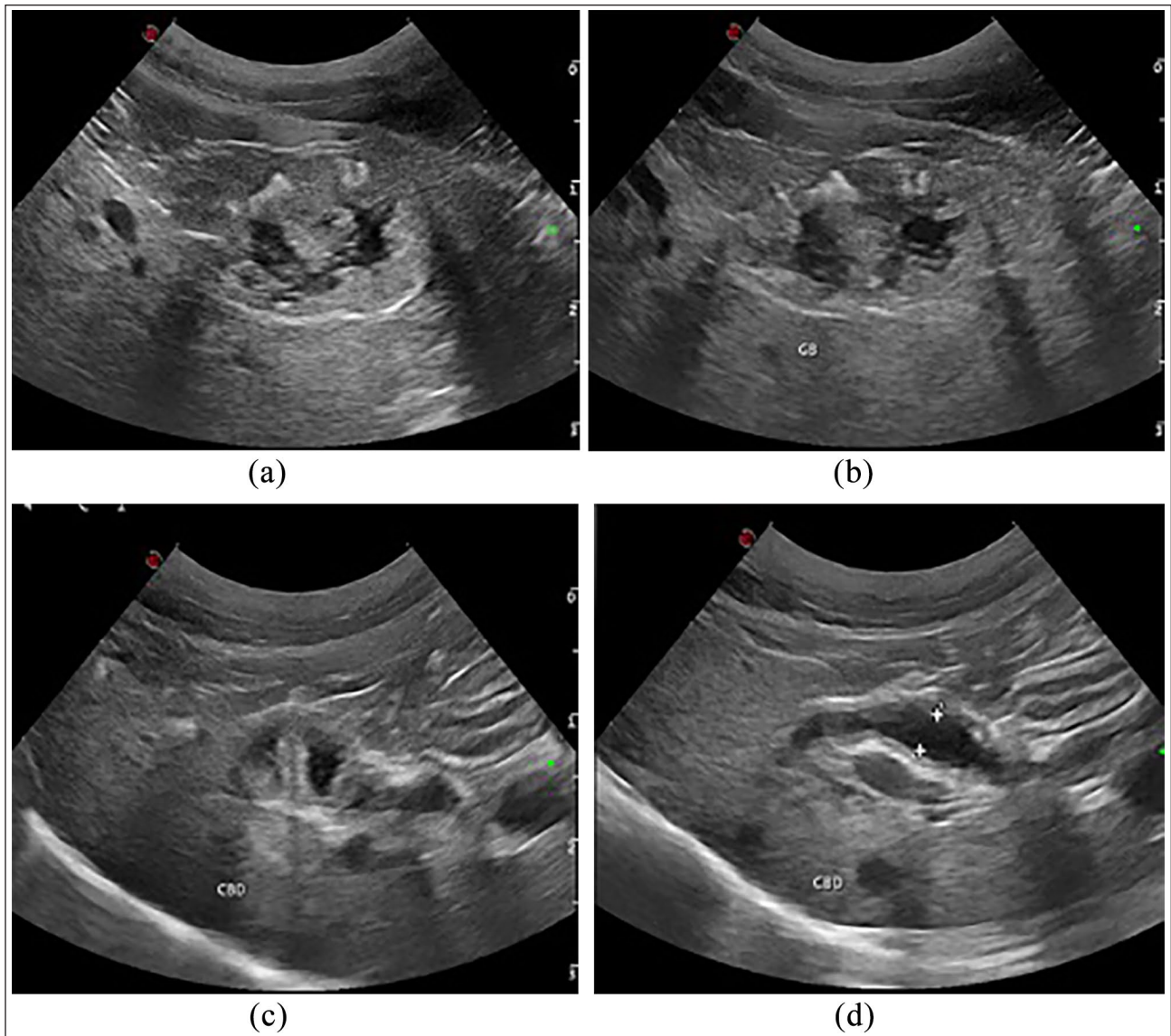
with 0.2 mg/kg butorphanol (Torbugesic; Zoetis) and 5 µg/kg dexmedetomidine (Dexdomitor; Zoetis) intravenously (IV).

#### Ultrasound findings

Ultrasonographically, the gallbladder had a very unusual appearance (Figure 1). While it was not enlarged, it had a very thickened wall that was isoechoic to the surrounding liver parenchyma, and whose luminal surface was irregular with small projections into the lumen. Between these projections and within the much reduced lumen was typical anechoic biliary fluid, and also occasional markedly hyperechoic hazy feather-like linear echoes, consistent with reverberation artefact, which lay between some of the projections, and conformed to the gallbladder wall. The common bile duct walls were thickened, with the lumen variably dilated throughout the duct's length to a maximum of 3 mm internal and 5 mm external diameter (Figure 1). The major pancreatic duct also had thickened walls where it approached the major duodenal papilla. The pancreas was increased in echogenicity and had dilated pancreatic ducts (1.8 and 1.6 mm, respectively).

#### Exploratory coeliotomy

The following day, elective cholecystectomy was performed owing to concerns associated with the ongoing viability of the gallbladder wall and reverberation artefacts possibly indicating gas in the lumen. The cat was premedicated with 0.2 mg/kg methadone (Methadyne; Jurox Animal Health) and 3 µg/kg dexmedetomidine (Dexdomitor; Zoetis) IV, and general anaesthesia was induced with 4 mg/kg propofol (Propoflo Plus; Zoetis) to effect. Lidocaine spray (Intubeaze; Dechra) was applied to the larynx 90 s prior to endotracheal intubation with a size 3.5 mm endotracheal tube. An epidural with 0.5% bupivacaine at 1 mg/kg and morphine at



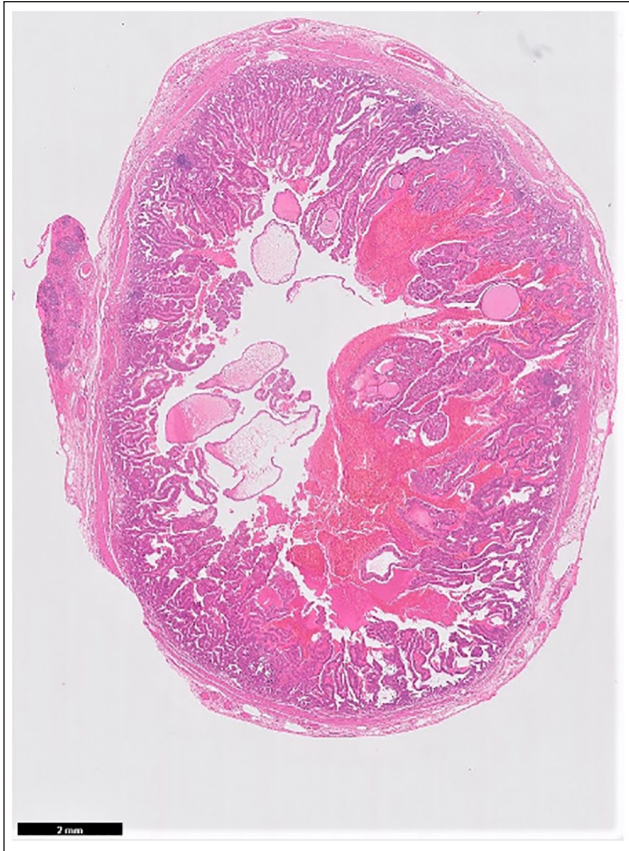**Figure 1** Ultrasonographic image of (a,b) the gallbladder with thickened irregular walls and intraluminal projections; and (c,d) the common bile duct with thickened walls and a variably dilated lumen

0.1 mg/kg was administered prior to surgery, as a method of pre-emptive and multimodal analgesia. An arterial line was placed prior to anaesthesia in the coccygeal artery. Anaesthesia was maintained on sevoflurane (1.5–2.5% in oxygen 11/min [SevoFlo; Zoetis]) via a paediatric circle system. Cefuroxime 20 mg/kg IV was administered approximately 30 mins preoperatively, and then continued q8h for the next 48 h. During the anaesthetic, lactated Ringer's solution was administered at 4 ml/kg/h (ie, 14 ml/h).

A median xiphoumbilical laparotomy was performed. The gallbladder was identified, and a stay suture was put in place at the apex. The common bile duct was visualised with a slight dilation. The thickness of its wall was gently palpated. The common bile duct was then squeezed and the dilation decreased at the same time. A

decision not to open the duodenum and not to stent the common bile duct was taken. The gallbladder was then dissected out of the hepatic fossa using fingers. A rupture of the gallbladder was discovered on the dorsal aspect of the fundus, despite no clinical signs of bile peritonitis. Dissection was continued down the cystic duct to its junction with the common bile duct. Double ligation of the cystic duct and artery was performed with 2-0 PDS using a transfixing and a circumferential ligature. The duct was clamped and transected between the clamp and the ligatures, and the gallbladder was removed. The stump was inspected for leakage of bile and residual haemorrhage, and the area was thoroughly lavaged before closure. A liver biopsy was taken by suture fracture technique on the medial right lobe. A pancreatic biopsy was taken by suture fracture technique on the





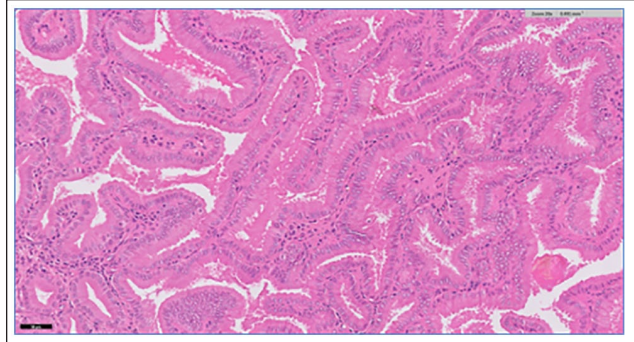
**Figure 2** Histopathological low-power image of the gallbladder mass in cross section. Scale bar = 2 mm

right lobe. The gallbladder was submitted for histopathological examination with the two biopsies, and bile plus liver for additional bacterial culture. Abdominal lavage and closure of the abdomen was completed.

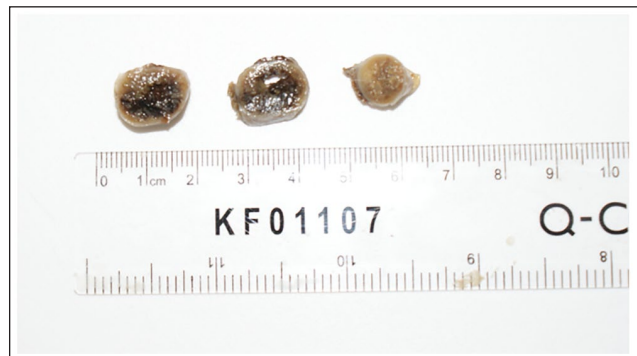
Postoperative analgesia consisted of methadone (0.1–0.2 mg/kg q2h–q4h based on pain score [Methadyne; Jurox]).<sup>12</sup> Thereafter, buprenorphine (Buprecare; Animalcare) was given 0.02 mg/IV q6h, before reducing the dose to 0.01 mg/kg at discharge. The patient started eating the following day and was discharged 2 days after surgery with ursodeoxycholic acid (10 mg/kg q24h PO [Destolit; Norgine]) for long-term use for its cholorectic, anti-inflammatory and potentially immunomodulatory effects.

### Histology findings

Histology of the gallbladder revealed that the mucosa was diffusely thickened, and formed papillary intraluminal proliferations (Figure 2). The epithelial cells were well-differentiated cuboidal-to-columnar cells lining central fibrous stalks (Figure 3). There was evidence of mild anisokaryosis but no mitoses. The stroma had a mild infiltrate of plasma cells and lymphocytes with few neutrophils and eosinophils. There was no invasion of



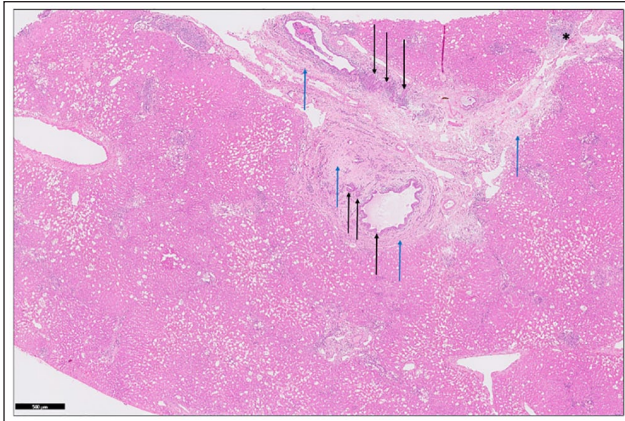
**Figure 3** Histopathological image of the gallbladder mass. Use of haematoxylin and eosin staining of the resected gallbladder mass revealed uniform epithelial cells, lining projections and tubules, with low numbers of inflammatory cells within the stroma. Scale bar = 50  $\mu$ m



**Figure 4** Macroscopic appearance of the gallbladder adenoma measuring approximately 1.3 cm  $\times$  1.2 cm

the underlying mural tissue and no emboli were seen. These features were consistent with benign papillary adenoma of the gallbladder mucosa (Figure 4).

In addition, biopsy of the medial right liver lobe showed evidence of portal areas expanded by oedematous and variably mucinous collagen, bridging adjacent portal tracts and associated with inflammation and biliary hyperplasia (Figure 5). There were moderate-to-large numbers of lymphocytes, plasma cells, neutrophils and a few macrophages and eosinophils, often located periductally. Laminar periductular fibrosis and mild hepatocellular lipidosis was also evident. As a result, based on these findings, a histopathological diagnosis of chronic cholangiohepatitis with a neutrophilic (acute) component, biliary hyperplasia and periportal fibrosis was reached. Based on the semi-quantitative grading system by Gagne et al,<sup>13</sup> mononuclear infiltrates were considered category 2, polymorphonuclear infiltrates as category 0–1, bile duct proliferation as category 1 and fibrosis as category 1–2. The gallbladder neoplasm was considered a likely contributing factor. Lastly, the histopathology of the pancreas identified small foci of lobular



**Figure 5** Histopathological image of the liver biopsy. This low-power ( $\times 20$ ) view shows the expansion of some portal areas by mixed inflammatory cell infiltrates, increased amounts of collagen (blue arrows), which is sometimes mucinous (asterisk), and biliary hyperplasia (black arrows). Haematoxylin and eosin stain;  $\times 20$

hyperplasia and other small foci of acinar atrophy, with very few interstitial mononuclear cells present. Therefore, a diagnosis of nodular hyperplasia was reached, given the lack of evidence of neoplasia or active inflammation. The intraluminal bile of the gallbladder was sampled for microbiological culture and found to be sterile.

### Outcome

Three weeks postoperatively, external biochemistry was repeated by the referring veterinary practice, to monitor for improvements in liver parameters and total bilirubin. ALP (356 U/l; RI 11–67 IU/l) and ALT (800 IU/l; RI 18–84 IU/l) had decreased but remained elevated. Similarly, total bilirubin had reduced substantially compared with admission level (20.4  $\mu\text{mol/l}$ ; RI 0–10  $\mu\text{mol/l}$ ). A mildly raised urea persisted (15.0 mmol/l [RI 6.10–12.50 mmol/l]), with further investigation of potential renal disease declined.

Two months postoperatively ALP (241 U/l; RI 11–67 U/l), ALT (765 U/l; RI 18–84 U/l) and total bilirubin (19  $\mu\text{mol/l}$ ; RI 0–10  $\mu\text{mol/l}$ ) remained elevated, but as the cat remained bright, and had maintained an excellent appetite, normal thirst levels and stable body weight, the owners declined further investigation of potential ongoing inflammatory or infectious liver disease.

### Discussion

This case report describes the successful management of a gallbladder adenoma via cholecystectomy in a senior feline patient. There are minimal studies in the current literature available regarding this type of neoplasm, especially in cats.

Feline hepatobiliary disease is common. Differential diagnoses can be classified based on morphological groupings, as per the World Small Animal Veterinary Association Liver Standardization Project.<sup>14</sup> They can be grouped into parenchymal, vascular, biliary, neoplastic and miscellaneous disorders. Most prominent diagnoses in cats include cholangitis (neutrophilic or lymphocytic), reversible hepatocellular injury, cholelithiasis, cholecystitis (neutrophilic or lymphoplasmacytic), reactive hepatitis, biliary cysts and acute hepatitis. A study investigating the frequency of feline hepatobiliary disease in the UK based on histopathology of 1217 samples, reported the most common disease entity was neutrophilic cholangitis.<sup>15</sup> Extrahepatic cholestasis comprises either intra- or extraluminal obstruction of the extrahepatic biliary system, and results in stasis of bile and dilatation of the bile ducts proximal to the obstruction. Aetiologies for extrahepatic cholestasis can be subdivided into intraluminal obstructions (biliary choleliths, gallbladder mucocoeles and neoplasia), or luminal compression or constriction (neoplasia or inflammation of the extrahepatic biliary tract). Cholestasis can be defined biochemically through elevations in ALP, gamma-glutamyl transferase, bilirubin and cholesterol, although these markers cannot be used to differentiate between intra- and extrahepatic cholestasis. As inflammation extends into the hepatic parenchyma, there can also be elevations in ALT, AST and bile acids. Ultrasonographic imaging alongside sampling of the liver and bile would then be useful in order to distinguish between intra- and extrahepatic causes of cholestasis.

In humans, gallbladder adenomas, as in cats, have a low incidence, constituting approximately 4% of all gallbladder polypoid masses.<sup>7</sup> Some studies suggest they are a precursory lesion to adenocarcinomas, although evidence for this is conflicting.<sup>8,9</sup> There appears to be pathways between pre-neoplastic lesions and gallbladder cancer in humans, although the carcinogenic pathway remains unclear. Some authors believe a progression between dysplasia to carcinoma,<sup>9</sup> while others believe an adenoma to carcinoma sequence is more likely.<sup>8</sup>

Often human patients are either asymptomatic at presentation and therefore neoplasia is only discovered incidentally during ultrasonography or cholecystectomy for other reasons, or they are symptomatic and have more advanced-stage disease and metastasis.<sup>16</sup> In one study by De Aretxabala et al,<sup>17</sup> 34.5% and 48.2% of patients underwent a cholecystectomy for suspected cholelithiasis and cholecystitis, respectively, and were found to have gallbladder neoplasia either intra- or postoperatively. Diagnosis primarily consists of abdominal ultrasonography. The sensitivity and specificity increase with severity and stage of the disease. Surgical resection is the recommended management and risk of malignancy increases with age<sup>18</sup> and gallbladder polyp diameter.<sup>19</sup>



In the veterinary literature, Glińska et al<sup>3</sup> reported a case of a 12-year-old male Scottish Terrier dog with a gallbladder mucinous cystadenoma, a benign neoplasm originating from the epithelial mucous layer. It presented with vomiting, hyporexia and abdominal distension. Ultrasonography revealed an enlarged gallbladder with increased wall thickness, filled with heterogenic amorphous material. Medical management with amoxicillin, ursodeoxycholic acid and S-adenosylmethionine was unsuccessful, and clinical signs progressed, so euthanasia was performed. This can be compared with the ultrasonographic findings in our patient; however, in the dog's case, surgical intervention was not sought and medical management was insufficient to control clinical signs. Interestingly, in this canine patient the ALP and ALT were significantly elevated, much like our patient; however, in contrast to our case clinical signs were manifested from the outset.

Gallbladder bile culture was sterile in our patient; however, 2 weeks of amoxicillin–clavulanic acid was given as a precautionary measure owing to increased suspicions of cholangitis. Ideally, medical management with antibiotics would have been avoided but the least invasive therapeutic options were preferred initially, given the suspected age of the cat.

In hindsight, investigations into infestation with *Platynosomum* species should have been explored, given the prior free-living nature of the cat and association with cholangiocellular carcinoma and cholangitis.<sup>20,21</sup> However, it is not a parasite endemic to the UK. *Platynosomum* species are trematode flukes, which can reside in the gallbladder and biliary and pancreatic ducts of the definitive feline host. Diagnosis is based on confirmation of eggs in bile, liver biopsies and faecal samples.

The reverberation artefacts that raised the possibility of luminal gas are reported in the human literature to be seen posterior to pseudopolyps (focal adenomyomatosis or cholesterol polyps) and, as such, differentiate them from true polyps. They were present in between and not posterior to the luminal projections in this case, suggesting the presence of focal adenomyomatosis, as well as the polypoid adenomas.<sup>22</sup>

## Conclusions

Gallbladder adenomas can arise in feline patients, albeit rarely, and can be difficult to diagnose without cholecystectomy and confirmatory histopathology. Ultrasonography can increase suspicions, but sensitivity can be poor when diagnosing gallbladder neoplasia, especially in the earlier stages of the lesion.<sup>23</sup> This case emphasises the importance of interdisciplinary communication between pathologists, ultrasonographers, surgeons and the primary clinician when deciding on the best management, with limited evidence available in the literature. Gallbladder adenomas should be considered a differential diagnosis for pathological

gallbladder changes on ultrasound, and cholecystectomy should be considered as a treatment option.

**Acknowledgements** The authors would like to thank Philippa Carr MRCVS and all colleagues at Pet Doctors Woking for keeping them updated about the cat's progress.

**Conflict of interest** The authors declared no potential conflicts of interest with respect to the research, authorship, and/or publication of this article.

**Funding** The authors received no financial support for the research, authorship, and/or publication of this article.

**Ethical approval** This work involved the use of non-experimental animals only (including owned or unowned animals and data from prospective or retrospective studies). Established internationally recognised high standards ('best practice') of individual veterinary clinical patient care were followed. Ethical approval from a committee was therefore not necessarily required.

**Informed consent** Informed consent (either verbal or written) was obtained from the owner or legal custodian of all animal(s) described in this work (either experimental or non-experimental animal(s) for the procedure(s) undertaken (either prospective or retrospective studies). No animals or humans are identifiable within this publication, and therefore additional informed consent for publication was not required.

**ORCID iD** Catherine Broadbridge  <https://orcid.org/0000-0002-2089-9215>

## References

- Meuten DJ. Tumors in domestic animals. 5th ed. Hoboken, NJ: John Wiley and Sons, 2017, pp 622–623.
- Anderson WA, Monlux AW and Davis CL. **Epithelial tumors of the bovine gallbladder; a report of eighteen cases.** *Am J Vet Res* 1958; 19: 58–65.
- Glińska K, Atamaniuk W, Halon A, et al. **Biliary cystadenoma mucinosum in a dog – case report.** *Med Weter* 2008; 64: 1314–1316.
- Ushio N, Chambers JK, Watanabe K, et al. **Chronic inflammatory and proliferative lesions of the gallbladder in aged pigs.** *Vet Pathol* 2019; 57: 122–131.
- Yoshitomi K, Alison RH and Boorman GA. **Adenoma and adenocarcinoma of the gallbladder in aged laboratory mice.** *Vet Pathol* 1986; 23: 523–527.
- Starost MF and Martino M. **Adenoma of the gallbladder in a chimpanzee (*Pan troglodytes*).** *J Zoo Wildl Med* 2002; 33: 176–177.
- Shaffer E and Hundal R. **Gallbladder cancer: epidemiology and outcome.** *J Clin Epidemiol* 2014; 6: 99–109.
- Kozuka S, Tsubone N, Yasui A, et al. **Relation of adenoma to carcinoma in the gallbladder.** *Cancer* 1982; 50: 2226–2234.
- Roa I, de Aretxabala X, Araya JC, et al. **Preneoplastic lesions in gallbladder cancer.** *J Surg Oncol* 2006; 93: 615–623.
- Withrow SJ, Vail DM and Page RL. **Cancer of the gastrointestinal tract: hepatobiliary tumors.** In: Withrow SJ, Vail DM and Page RL (eds). *Withrow & MacEwen's small ani-*

- mal clinical oncology. 5th ed. St Louis, MO: Elsevier, 2013, pp 405–411.
- 11 Lawrence HJ, Erb HN and Harvey HJ. **Nonlymphomatous hepatobiliary masses in cats: 41 cases (1972 to 1991).** *Vet Surg* 1994; 23: 365–368.
  - 12 Calvo G, Holden E, Reid J, et al. **Development of a behaviour-based measurement tool with defined intervention level for assessing acute pain in cats.** *J Small Anim Pract* 2014; 55: 622–629.
  - 13 Gagne JM, Weiss DJ and Armstrong PJ. **Histopathologic evaluation of feline inflammatory liver disease.** *Vet Pathol* 1996; 33: 521–526.
  - 14 Rothuizen J, Bunch SE, Charles JE, et al. **WSAVA standards for clinical and histological diagnosis of canine and feline liver diseases.** Philadelphia, PA: Saunders Elsevier, 2006.
  - 15 Bayton WA, Westgarth C, Scase T, et al. **Histopathological frequency of feline hepatobiliary disease in the UK.** *J Small Anim Pract* 2018; 59: 404–410.
  - 16 Konstantinidis IT. **Trends in presentation and survival for gallbladder cancer during a period of more than 4 decades.** *Arch Surg* 2009; 144: 441.
  - 17 De Aretxabala X, Roa I, Burgos L, et al. **Gallbladder cancer: an analysis of a series of 139 patients with invasion restricted to the subserosal layer.** *J Gastrointest Surg* 2006; 10: 186–192.
  - 18 Lazcano-Ponce EC, Miquel JF, Munoz N, et al. **Epidemiology and molecular pathology of gallbladder cancer.** *CA Cancer J Clin* 2001; 51: 349–364.
  - 19 Aloia TA, Járufe N, Javle M, et al. **Gallbladder cancer: expert consensus statement.** *HPB (Oxford)* 2015; 17: 681–690.
  - 20 Andrade RLFS, Dantas AFM, Pimentel LA, et al. **Platynosomum fastosum-induced cholangiocarcinomas in cats.** *Vet Parasitol* 2012; 190: 277–280.
  - 21 Santos JA, Lopes MAF, Schott AC, et al. **Colangiocarcinomas em gatos com parasitismo de ductos biliares por *Platynosomum fastosum*.** *Pesq Vet Bras* 1981; 1: 31–36.
  - 22 Wiles R, Theoni RF, Barbu ST, et al. **Management and follow-up of gallbladder polyps: joint guidelines between the European Society of Gastrointestinal and Abdominal Radiology (ESGAR), International Society of Digestive Surgery – European Federation (EFISDS) and European Society of Gastrointestinal Endoscopy (ESGE).** *Eur Radiol* 2017; 27: 3856–3866.
  - 23 Tsuchiya Y. **Early carcinoma of the gallbladder: macroscopic features and US findings.** *Radiology* 1991; 179: 171–175.