










Clinical Assessments and MRI Findings Suggesting Early Surgical Treatment for Patients with Medial Epicondylitis

내측상과염 환자의 임상항목과 자기공명영상
항목 중 조기 수술적 치료가 필요한 환자군이 갖는
인자에 관한 분석

Hyungin Park, MD¹ , Seok Hahn, MD^{1*} , Jisook Yi, MD¹ ,
Jin-Young Bang, MD² , Youngbok Kim, MD² ,
Hyung Kyung Jung, MD¹ , Jiyeon Baik, MD¹ 

Departments of ¹Radiology and ²Orthopaedic Surgery, Inje University College of Medicine, Haeundae Paik Hospital, Busan, Korea

Purpose To evaluate the MRI findings and clinical factors that are characteristic of patients who ultimately undergo surgery for medial epicondylitis.

Materials and Methods Fifty-two consecutive patients who were diagnosed with medial epicondylitis and underwent an elbow MRI between March 2010 and December 2018 were included in this retrospective study. The patients' demographic information, clinical data, and MRI findings were evaluated. All variables were compared between the conservative treatment and surgical treatment groups. Logistic regression analyses were conducted to identify which factors were associated with surgical treatment.

Results Common flexor tear (CFT) tear size showed a statistically significant difference in both the transverse and longitudinal planes ($p < 0.001$, $p = 0.013$). The CFT abnormality grade significantly differed in both the transverse and longitudinal planes ($p = 0.022$, $p = 0.003$). A significant difference was also found in the medial collateral ligament abnormality ($p = 0.025$). Logistic regression analyses showed that only the transverse diameter of the CFT tear size (odds ratio: 1.864; 95% confidence interval: 1.264–2.750) was correlated with surgical treatment.

Conclusion Of patients diagnosed with medial epicondylitis, patients with a larger transverse CFT tear size tend to undergo surgical treatment ultimately.

Index terms Elbow; Tendon; Magnetic Resonance Imaging

Received May 18, 2020
Accepted July 4, 2020

***Corresponding author**

Seok Hahn, MD
Department of Radiology,
Inje University,
College of Medicine,
Haeundae Paik Hospital,
875 Haeun-daero, Haeundae-gu,
Busan 48108, Korea.






Tel 82-51-797-0380

Fax 82-51-797-0379

E-mail andrew0668@hanmail.net

This is an Open Access article distributed under the terms of the Creative Commons Attribution Non-Commercial License (<https://creativecommons.org/licenses/by-nc/4.0>) which permits unrestricted non-commercial use, distribution, and reproduction in any medium, provided the original work is properly cited.

ORCID iDs

Hyungin Park 
<https://orcid.org/0000-0002-7283-4317>
Seok Hahn 
<https://orcid.org/0000-0002-4695-6118>
Jisook Yi 
<https://orcid.org/0000-0002-6633-0526>
Jin-Young Bang 
<https://orcid.org/0000-0002-8563-4402>
Youngbok Kim 
<https://orcid.org/0000-0002-7966-1092>
Hyung Kyung Jung 
<https://orcid.org/0000-0001-6086-7771>
Jiyeon Baik 
<https://orcid.org/0000-0003-3719-7559>

INTRODUCTION

Among the many pathologic changes that follow medial elbow pain, medial epicondylitis is one of the most commonly encountered painful pathologic conditions. It is caused by repetitive stress that leads to microtraumas of the common flexor tendon (CFT), causing chronic medial elbow pain at the medial epicondyle, usually affecting the fourth to sixth decades of life (1, 2).

While the specific causes of epicondylitis have not been elucidated, angiofibroblastic tendinosis is now thought to occur via a degenerative mechanism, which leads to calcification, fibrosis, vascular proliferation and hyaline degeneration of the affected muscles without inflammatory infiltration (3-5).

Although about 4-times less common than lateral epicondylitis, medial epicondylitis is especially more prevalent among athletes involved in overhead throwing or people with occupations associated with repetitive wrist flexion and pronation (carpentry, housekeeping, etc.) (3, 6-8). However, active use of the elbow along with the continuation of sports in the aging population has resulted in a more frequent diagnosis of this condition (3).

Imaging is not always needed in the diagnosis of medial epicondylitis. Diagnosis could be made with a thorough history and physical examination. However, due to the evolving imaging techniques, MRI and ultrasonography have been used in many cases, such as in confounding situations to exclude other possible pathologic causes, or when trying to evaluate the extent of the disease, or to quantify the degree of tendon injury (6, 9, 10).

There are many treatment options for medial epicondylitis, starting from conservative treatment including arm rest, oral non-steroidal anti-inflammatory drug (NSAID), splint or bracing, local injections, application of ultrasound waves, and platelet-rich plasma (1). Since the successful outcomes of nonsurgical treatment have been reported to be greater than 90%, surgical intervention should only be considered when several nonsurgical treatment options fail to relieve pain. To our knowledge, there is no literature regarding the best time to undergo surgical intervention following conservative treatment. Further, in the case of professional athletes, the treatment decision is even more difficult (11).

Prompt decisions regarding the surgical treatment of medial epicondylitis can help patients. Insufficiently applying nonsurgical treatment might prolong a patient's pain and discomfort (12, 13). Patients can save both time and money when avoiding unnecessary treatment. Recently, there has been research regarding the radiologic and clinical factors associated with the failure of conservative management and the indications for surgery in lateral epicondylitis (7). Since medial and lateral epicondylitis share similar pathologies described as tendinosis resulting from repetitive overuse with resultant microtears and progressive degeneration, we speculated if similar clinical factors and MRI findings could aid in deciding the treatment management plans for medial epicondylitis (6, 14). The purpose of our study was to determine which MRI findings combined with clinical factors are characteristic of patients who undergo surgery for medial epicondylitis.

MATERIAL AND METHODS

This retrospective study was approved by the Institutional Review Board. The requirement for informed consent was waived (IRB No. HPIRB 2019-04-002).

STUDY GROUP

This retrospective study included patients from March 2010 to Dec 2018, a total of 378 patients (mean age, 47.2 years; age range, 8–85 years; 201 male, 177 female) who had been identified with medial elbow pain and who had undergone elbow MRI examinations. Overall, 317 patients were excluded due to elbow pathology other than medial epicondylitis. We confirmed the diagnoses of the remaining 61 patients of medial epicondylitis from the medical records. A subsequent electronic medical record review was conducted to classify these patients as having received either conservative or surgical treatment for medial epicondylitis. During this process, an additional six patients were excluded because no information about the medical follow-up ($n = 5$) was available and because the patients refused to undergo surgical treatment ($n = 1$). Finally, a total of 52 patients (mean age, 53.7 years; age range, 27–77 years; 16 male, 36 female) were included (Fig. 1).

CLINICAL ASSESSMENT

The electronic medical records were reviewed retrospectively for the clinical assessments. In addition to age and sex, the following clinical information was evaluated; laterality and duration of pain, history of conservative management, duration of conservative management, and postoperative follow-up duration if the patient underwent surgical treatment.

The decision to undergo the surgical treatment was made by two orthopedic surgeons specialized in elbows with 9 and 8 years of experience, respectively. Initially, the patients were treated in a conservative manner. The conservative treatment was considered as a failure, if the medial elbow pain persisted or the movements of the elbow showed limitations.

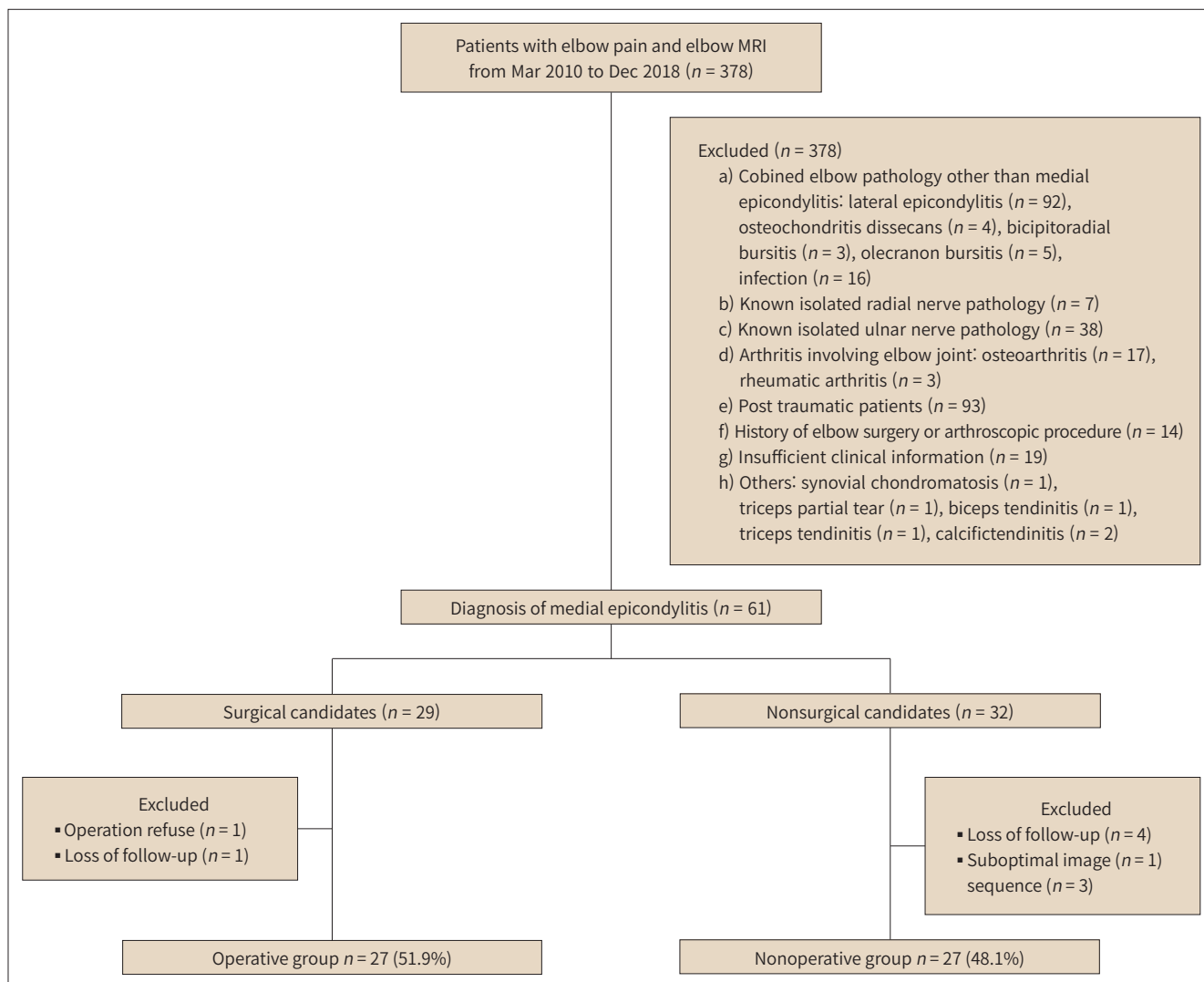
MR IMAGING EXAMINATIONS

In our institution, we used 3T MRI systems (Achieva Tx, Philips, Best, the Netherlands) with a 32-element channel coil for elbow imaging. The detailed parameters of elbow MRI sequences are summarized in Table 1. Of the 52 patients, 27 MRI examinations conducted in an external clinic were included in this study. They underwent elbow MRI using 1.5T MRI system (Signa HDxt, GE Healthcare, Chicago, IL, USA) with a 8-element channel coil. Despite some differences in the imaging protocols, similar imaging sequences and parameters were used for the evaluation (Table 1).

MR IMAGING ANALYSIS

All elbow MR images of all patients were retrospectively reviewed for consensus by two radiologists (one with 10 years of experience and another with 2 years of experience). Each radiologist was blinded to the demographic data and the patients' ultimate treatment. CFT and ligament abnormalities were evaluated on axial and coronal T2-weighted and/or proton density-weighted images (PDWI) with/without fat saturated MR images. Tendinosis was defined

Fig. 1. Flowchart of the patient selection process.



as increased signal intensity (SI) lower than that of the fluid signal on T2-weighted and/or PDWI with/without fat saturated images and/or an increased tendon thickness (Fig. 2). A partial thickness tear (PTT) was defined as a region with fluid SI extending partway across the tendon. A full thickness tear (FTT) appeared as a gap in the fluid SI across the entire substance of the tendon (Fig. 2) (6, 15). When a tear was present, the greatest extent of the tear was measured on the coronal and axial images. The area of the medial epicondyle attached to the CFT was determined using the length and width. The tear size was determined to be “0, zero” when the CFT was normal or in cases of “tendinosis.” Based on previous studies, PTTs were classified as low-, intermediate- or high-grade tears if < 20%, 20–80% or > 80%, respectively. Maximum CFT thickness was measured independently on the axial and coronal images (6). Next, CFT abnormalities were rated separately on the axial and coronal images using a four-point scale (1 = no abnormal SI or tear, 2 = tendinosis or low-grade PTT, 3 = intermediate PTT, 4 = high grade PTT or FTT). Ulnar neuropathy was evaluated on axial T2-weighted

Table 1. MRI Sequence and Parameters in Our Institution and the External Clinic

Sequence	Plane	TR (msec)	TE (msec)	Slice Thickness (mm)	Interslice Gap (mm)	FOV (cm)	ETL	Acquisition Matrix (mm)	Number of Acquisition
In our institution									
T2-weighted	Coronal	2500	80–100	3	0	14	15	256–280 × 252–280	1
	Axial	3280–3630	90–100	3	0.3	14	15	256–312 × 250–268	1
T2-weighted FS	Coronal	1670–1930	60–65	3	0	14	12	256–280 × 252–276	1
	Axial	2890–3100	60–70	3	0.3	14	12	256–260 × 226–252	1
3D PD-weighted FS	Sagittal	1300	30	1	0	14	65	248 × 248	2
In external clinic									
T2-weighted	Coronal	3270–3360	70–90	3.5	0.3	15	15	256–320 × 224	2
	Axial	4150–4630	70–75	3.5	1.0	14	14	320 × 224	2
PD-weighted FS	Coronal	2320–2550	40–45	3.5	0.3	15	9	256–320 × 224–256	3
	Axial	3740–4420	34–47	3.5	1.0	14	10	280–288 × 224	2
	Sagittal	2770–2830	31–44	4	0.4	16	9	320–256	3

ETL = echo train length, FOV = field of view, FS = fat saturated, PD = proton density, TE = echo time, TR = repetition time

and/or PDWI with/without fat saturated images with three-point scale as follows: 1 = isointense relative to normal muscles, 2 = mildly hyperintense relative to that of adjacent normal muscles and no increased cross sectional area ($< 10.0 \text{ mm}^2$), 3 = hyperintense compared to the adjacent normal muscles and increased cross sectional area ($> 10.0 \text{ mm}^2$) (16, 17). The medial collateral ligament (MCL) was also assessed on a three-point scale as follows: 1 = normal, 2 = partial tear, peri-ligamentous edema, thickening or thinning; and 3 = complete tear. Muscle edema was evaluated as present or absent on T2-weighted and/or PDWI with/without fat saturated images with the presence of high SI in one or more muscles. Joint effusion was scored on a three-point scale as follows: 1 = no effusion, 2 = effusion within the anterior or posterior joint recess, and 3 = effusion within both anterior and posterior joint recesses on sagittal images. Synovitis was scored using the following three-point scale: 1 = no synovial thickening, 2 = mild or equivocal synovial thickening, and 3 = definite synovial thickening (18, 19). Traction spurs and subchondral bone marrow edema were also evaluated as present or absent (20-22).

STATISTICAL ANALYSIS

An independent two-sample *t*-test was used to compare continuous variables and a Chi-square test and Fisher's exact test were used to compare categorical variables between the groups. *p* values < 0.05 were considered statistically significant. Multivariate backward stepwise logistic regression models were used to determine if correlations existed between the surgical treatment and variables that were significantly different between the groups. The diagnostic performances of variables which had the correlations were evaluated using the receiver-operating characteristic curve and the area under the curve (AUC). All statistical analyses were performed in MedCalc Statistical Software v.18.11 (MedCalc Software BVBA, Ostend, Belgium).

RESULTS

All of the included 52 patients initially underwent conservative treatment such as refraining from activities that initiated or exacerbated the symptoms ($n = 52$), injection ($n = 45$), and oral pain medication ($n = 10$). The mean duration of the conservative treatment was 15.1 months (range, 2 weeks to 60 months). Twenty-five patients showed improvements in pain, while the remaining patients experienced persistent or aggravated pain. Finally, 27 patients underwent surgical treatment (Fig. 3).

DEMOGRAPHIC AND CLINICAL CHARACTERISTICS

The demographic and clinical data of the patients who underwent conservative or surgical treatment are summarized in Table 2. No significant differences were observed in the obtained characteristics (all were $p > 0.05$).

MR IMAGING FINDINGS

Table 3 shows a comparison of the MRI findings between the conservative treatment group and the surgical treatment group. The CFT tear size showed statistical significance in both transverse and longitudinal planes between the two groups ($p < 0.001$, $p = 0.013$, respectively). The CFT abnormality grade on both the transverse and longitudinal planes also showed significant results between the two groups ($p = 0.022$ and $p = 0.003$, respectively). Interestingly, CFT abnormality itself showed no statistically significant differences ($p = 0.073$).

For MCL abnormality, a significant difference was found between the two groups ($p =$

Fig. 2. The size measurement of transverse and longitudinal tear.

A, B. Transverse (red line) and longitudinal measurement (blue line) of partial thickness tear.

C, D. Transverse (red line) and longitudinal measurement (blue line) of full thickness tear.

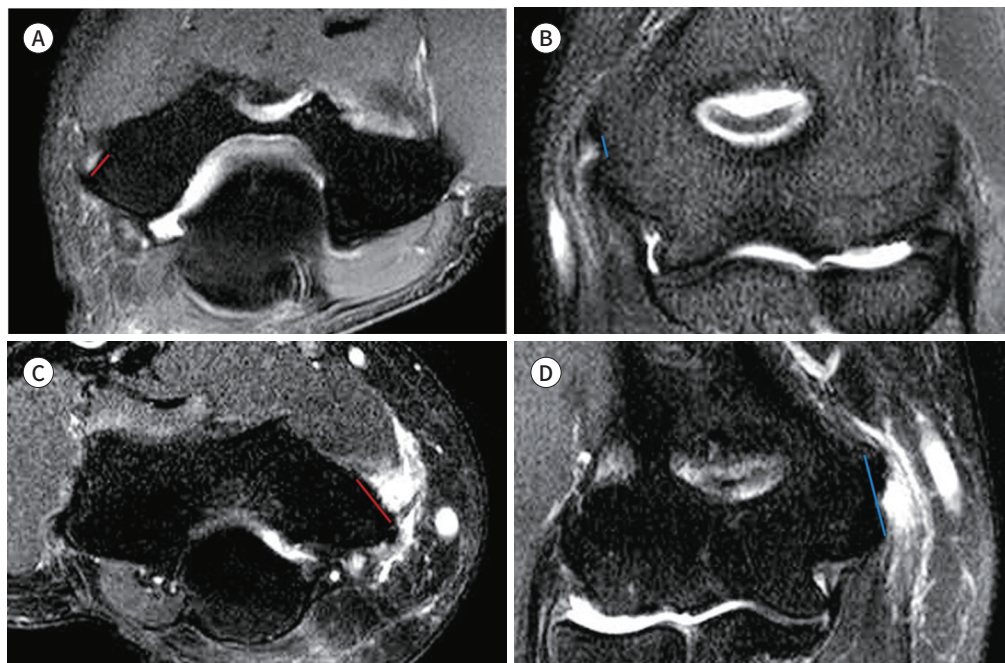


Table 2. Comparison of the Demographic and Clinical Data between the Conservative Treatment Group and Surgical Treatment Group

	Conservative Treatment Group (n = 25, %)	Surgical Treatment Group (n = 27, %)	p-Value
Age (years)	53.8 ± 11.1	53.7 ± 8.2	0.959
Sex			0.436
Male	9 (36)	7 (25.9)	
Female	16 (64)	20 (74.1)	
Side			0.957
Left	15 (60)	16 (59.3)	
Right	10 (40)	11 (40.7)	
Initial VAS	5.9	6.3	0.561
Duration of conservative treatment (months)	14.8 ± 2.7	16.1 ± 2.3	0.709
Injection therapy			0.769
Yes	22 (88.0)	23 (85.2)	
No	3 (12.0)	4 (14.8)	
Oral pain medication			0.569
Yes	4 (16.0)	6 (22.2)	
No	21 (84.0)	21 (77.8)	

VAS = visual analogue scale

0.025). However, there were no significant differences between the two groups for ulnar neuropathy ($p = 0.223$), joint effusion ($p = 0.118$), traction spur ($p = 0.898$), muscle edema ($p = 0.396$), and subchondral bone edema ($p = 0.511$) (Figs. 3, 4).

FACTORS RELATED TO THE TREATMENT OPTIONS

Among the abovementioned demographic and clinical characteristics of patients diagnosed with medial epicondylitis, statistically significant factors including the size of the CFT tear in the transverse and longitudinal dimensions and MCL tear grading were included in a logistic regression model. The analysis showed that only the transverse diameter of the CFT tear size [$p = 0.002$; odds ratio: 1.864; 95% confidence interval (CI): 1.264–2.750] was correlated with surgical treatment (Table 4). Additionally, the AUC of the CFT tear was 0.831 (95% CI: 0.720–0.942). The cutoff value of the transverse tear size of the CFT to decide surgical treatment was 2.7 mm with 77.8% sensitivity and 76.0% specificity.

POST-OPERATIVE CLINICAL ASSESSMENTS

Twenty-six of the 27 patients (96.3%) who underwent surgical treatment showed improved pain without aggravation (mean duration of follow up, 8.4 months; range, 1 to 54 months). Only one patient (3.7%) had sustained pain of the same intensity over the following 18 months.

DISCUSSION

In our study, we found significant differences between the conservative and surgical treat-

Table 3. Comparison of the MRI Findings between the Conservative Treatment Group and Surgical Treatment Group

	Conservative Treatment Group (n = 25, %)	Surgical Treatment Group (n = 27, %)	p-Value
CFT abnormality			0.073
Normal	4 (16)	0	
Tendinosis	11 (44)	9 (33.3)	
Partial thickness tear	10 (40)	17 (63.0)	
Full thickness tear	0	1 (3.7)	
Size of CFT tear*			
Transverse	1.40 ± 1.88	4.73 ± 2.84	<0.001
Longitudinal	2.85 ± 6.86	6.72 ± 2.67	0.013
CFT abnormality grade			
Transverse			0.022
Grade 1	4 (16)	0	
Grade 2	15 (60)	13 (48.1)	
Grade 3	6 (24)	9 (33.3)	
Grade 4	0	5 (18.5)	
Longitudinal			0.003
Grade 1	4 (16)	0	
Grade 2	16 (64)	11 (40)	
Grade 3	5 (20)	7 (25.9)	
Grade 4	0	9 (33.3)	
Ulnar neuropathy			0.223
Grade 1	14 (56)	16 (59.3)	
Grade 2	7 (28)	3 (11.1)	
Grade 3	4 (16)	8 (29.6)	
Joint effusion			0.118
Grade 1	5 (20)	12 (44.4)	
Grade 2	19 (76)	13 (48.1)	
Grade 3	1 (4)	2 (7.4)	
MCL abnormality			0.025
Grade 1	21 (84)	13 (48.1)	
Grade 2	3 (12)	10 (37.0)	
Grade 3	1 (4)	4 (14.8)	
Traction spur			0.898
Absence	18 (72)	19 (70.4)	
Presence	7 (28)	8 (29.6)	
Muscle edema			0.396
Absence	15 (60)	13 (48.1)	
Presence	10 (40)	14 (51.9)	
Subchondral bone edema			0.511
Absence	23 (92)	26 (96.3)	
Presence	2 (8)	1 (3.7)	

*Data are mean ± standard deviation.

CFT = common flexor tendon, MCL = medial collateral ligament

Fig. 3. A 53-year-old female with left elbow pain.

A, B. Fat-saturated T2-weighted coronal image (**A**) and fat-saturated T2-weighted axial image (**B**) show tearing of the proximal common flexor tendon (arrows). The longitudinal size of the tear is 11.0 mm, and the transverse size of the tear is 14.1 mm.

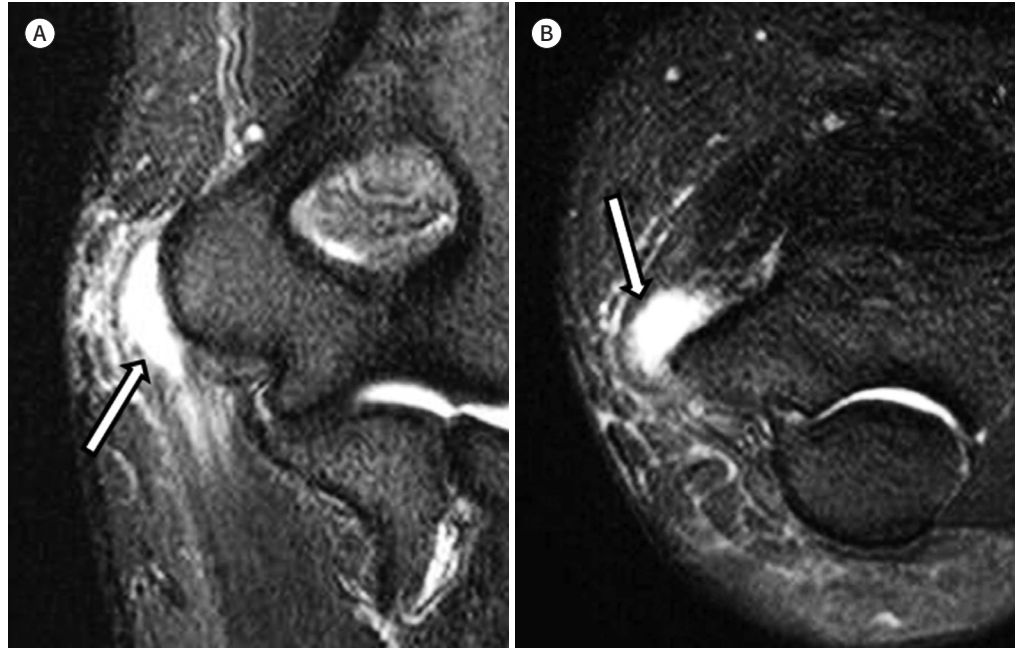

Fig. 4. A 62-year-old female with right elbow pain.

A, B. Fat-saturated proton density-weighted coronal image (**A**) and fat-saturated proton density-weighted axial image (**B**) show tearing of the proximal common flexor tendon (arrows). The longitudinal size of the tear is 2.7 mm, and the transverse size of the tear is 8.1 mm.

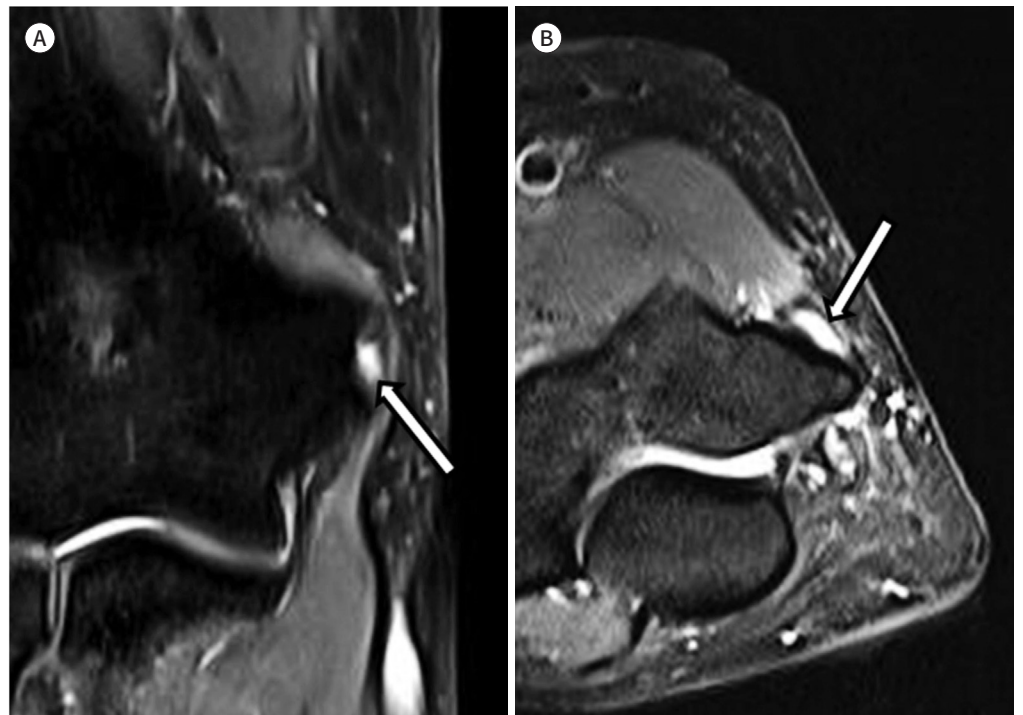


Table 4. Logistic Regression Analysis of the MR Findings and Surgical Treatment

	Odds Ratio (95% Confidence Interval)	p-Value
Transverse size of CFT tear	1.864 (1.264–2.750)	0.002
Longitudinal size of CFT tear	1.008 (0.889–1.144)	0.896
MCL abnormality		
Grade 1	1 (reference)	
Grade 2	2.602 (0.349–19.378)	0.351
Grade 3	2.669 (0.126–56.720)	0.529

CFT = common flexor tendon, MCL = medial collateral ligament

ment groups in the grade of CFT abnormality, size of the CFT tear, and grade of the MCL abnormality. The results of the logistic regression tests showed that only the transverse size of the CFT tear was correlated with surgical treatment. The results of our study showed that evaluation of MR imaging factors can help decide treatment plans for medial epicondylitis.

Nirschl and Ashman (23) proposed a staging system based on the observed histology at the time of surgery for lateral epicondylitis and derived from the patients' description of the duration and intensity of pain. The majority of patients visit a hospital when their conditions are in stage 2 or higher. As based on this staging system, common extensor tendon abnormality is a key factor of lateral epicondylitis, and can be more objectively estimated using elbow MRI.

This result could be possibly applied to medial epicondylitis because of the similarity of the pathophysiology between medial and lateral epicondylitis. CFT abnormalities have been considered to be the key anatomical factors in medial epicondylitis. The CFT at the medial epicondyle is normally broader and shorter than the common extensor tendon at the lateral epicondyle (24, 25). Therefore, we believe that the transverse plane of the tendon plays a bigger role in transmitting mechanical force in medial epicondylitis than in lateral epicondylitis. We also think that even though a similar tear size may be seen, a transverse tear is likely to have a greater impact on the disease progression of medial epicondylitis. On the contrary, it has been reported that common extensor tendon abnormalities on a longitudinal plane are associated with operative treatment in lateral epicondylitis (7).

If the cutoff value of 2.7 mm for transverse tear of the CFT had been considered as the deterministic factor for earlier surgical treatment on our study population, the result shows that 21 out of 27 ultimately surgically treated patients could have undergone earlier surgery with timely manner without need for unnecessary lingering conservative treatment.

MCL has been believed to be a key static stabilizer, functioning as an important resistance to valgus stress (26). Otoshi et al. (27) suggested that, owing to the characteristic morphology, the anterior common tendon of the elbow flexor and pronator muscles might support the anterior bundle of the MCL by sharing the static and dynamic traction forces applied to the medial elbow joint. Based on our assumption that a tear in the CFT would increase the load on the anterior bundle of the MCL, we believed that the abnormality of the MCL might be an important factor in determining the early decision for surgical intervention. However, the results of the logistic regression tests in this study were statistically insignificant.

The presence of ulnar neuropathy may have an intimate relationship with treatment plan-

ning and the prognosis of medial epicondylitis. Kurvers and Verhaar (28) suggested that medial epicondylitis with concomitant ulnar neuritis had poorer outcomes postoperatively. Gabel and Morrey (29) divided medial epicondylitis according to the presence and severity of ulnar neuropathy. They suggested that the progression of ulnar neuropathy is indicative of surgical treatment, but also emphasized that some patients with ulnar symptoms might not show objective test results such as in type 2A, which is medial epicondylitis with ulnar nerve symptoms with no objective deficit on a physical exam or in electromyography. This may also apply to the results of our study, which showed a non-significant difference in ulnar nerve signal change in the surgical group.

All the factors driven by the demographic and clinical data did not show any statistical significance. This is probably due to the pathogenesis of medial epicondylitis itself, which results from repetitive valgus stress, and is complexly combined with aging, trauma or inflammatory changes.

Since the number of people diagnosed with medial epicondylitis is increasing, the interest for treatment planning has become more intense. However, there are very few studies associated with treatment planning of this condition and only a few studies have dealt with medial epicondylitis. To date, surgical intervention has been applied clinically for patients with 'refractory' symptoms, typically after 6 months of conservative treatment, without additive help from the MRI findings. Medial epicondylitis can be diagnosed clinically with physical examination and clinical information, which may have been one of the causes for the limited number of papers having MRI measurements combined with demographic and clinical data.

The rapid technological development and the increased interest in quality of life enable easier access to MRI and an early decision for surgical intervention. A previous study reported that the long-term outcome of surgical treatment for medial epicondylitis was effective (11). These results imply a good prognosis for surgical treatments (3). Therefore, if an early decision is made to perform surgery, one can easily regain daily life activity. The present study suggests that early decision making is useful in relieving the patient of unnecessary pain and discomfort.

This study has some limitations. First, the study was retrospective, and there might have been a selection bias due to the inclusion and exclusion criteria. Nonetheless, this was reconciled by including consecutive patients during the determined period. Second, this study included a relatively small sample size, but we owe this to the low incidence of medial epicondylitis. Third, patients from a single center were included, but the diagnosis of medial epicondylitis and treatment planning was made by two orthopedic surgeons. Fourth, elbow MRIs were reviewed on consensus and inter-reader agreement was not obtained. Lastly, the number of elbow MRIs taken elsewhere was larger than the number of elbow MRIs taken at our hospital. We think that this difference was attributable to the receipt of referrals from primary medical institutions. Therefore, our patients might have had relatively more severe symptoms at baseline compared to the general population.

In conclusion, of patients diagnosed with medial epicondylitis, patients with a larger transverse CFT tear size tend to ultimately undergo surgical treatment. Radiologists should pay attention to transverse CFT tear size when interpreting elbow MRI findings for patient suspicious of medial epicondylitis, which might be the predictive factor for earlier surgical treatment.

Author Contributions

Conceptualization, H.S., Y.J.; data curation, B.J., K.Y.; formal analysis, P.H., H.S., Y.J.; investigation, P.H., H.S.; methodology, P.H., H.S.; project administration, B.J., K.Y.; resources, H.S., B.J., K.Y.; writing—original draft, P.H., H.S., B.J.; and writing—review & editing, J.H.K.

Conflicts of Interest

The authors have no potential conflicts of interest to disclose.

Funding

None

Acknowledgments

The author(s) received no financial support for the research, authorship, and/or publication of this article.

REFERENCES

1. Tarpada SP, Morris MT, Lian J, Rashidi S. Current advances in the treatment of medial and lateral epicondylitis. *J Orthop* 2018;15:107-110
2. Walker-Bone K, Palmer KT, Reading I, Coggon D, Cooper C. Occupation and epicondylitis: a population-based study. *Rheumatology (Oxford)* 2012;51:305-310
3. Vinod AV, Ross G. An effective approach to diagnosis and surgical repair of refractory medial epicondylitis. *J Shoulder Elbow Surg* 2015;24:1172-1177
4. Ellenbecker TS, Nirschl R, Renstrom P. Current concepts in examination and treatment of elbow tendon injury. *Sports Health* 2013;5:186-194
5. McMurtrie A, Watts AC. (vi) Tennis elbow and Golfer's elbow. *Orthop Trauma* 2012;26:337-344
6. Walz DM, Newman JS, Konin GP, Ross G. Epicondylitis: pathogenesis, imaging, and treatment. *Radiographics* 2010;30:167-184
7. Jeon JY, Lee MH, Jeon IH, Chung HW, Lee SH, Shin MJ. Lateral epicondylitis: associations of MR imaging and clinical assessments with treatment options in patients receiving conservative and arthroscopic managements. *Eur Radiol* 2018;28:972-981
8. Shiri R, Viikari-Juntura E, Varonen H, Heliövaara M. Prevalence and determinants of lateral and medial epicondylitis: a population study. *Am J Epidemiol* 2006;164:1065-1074
9. O'Dell MC, Urena J, Fursevich D, Sanchez E, LiMarzi G, Bancroft L. Imaging sports-related elbow injuries. *Appl Radiol* 2015;44:7-15
10. Konin GP, Nazarian LN, Walz DM. US of the elbow: indications, technique, normal anatomy, and pathologic conditions. *Radiographics* 2013;33:E125-E147
11. Han SH, Lee JK, Kim HJ, Lee SH, Kim JW, Kim TS. The result of surgical treatment of medial epicondylitis: analysis with more than a 5-year follow-up. *J Shoulder Elbow Surg* 2016;25:1704-1709
12. Do Nascimento AT, Claudio GK. Arthroscopic surgical treatment of medial epicondylitis. *J Shoulder Elbow Surg* 2017;26:2232-2235
13. Cho BK, Kim YM, Kim DS, Choi ES, Shon HC, Park KJ, et al. Mini-open muscle resection procedure under local anesthesia for lateral and medial epicondylitis. *Clin Orthop Surg* 2009;1:123-127
14. Donaldson O, Vannet N, Gosens T, Kulkarni R. Tendinopathies around the elbow part 2: medial elbow, distal biceps and triceps tendinopathies. *Shoulder Elbow* 2014;6:47-56
15. Bauer S, Wang A, Butler R, Fallon M, Nairn R, Budgeon C, et al. Reliability of a 3 T MRI protocol for objective grading of supraspinatus tendonosis and partial thickness tears. *J Orthop Surg Res* 2014;9:128
16. Schertz M, Mutschler C, Masmajejan E, Silvera J. High-resolution ultrasound in etiological evaluation of ulnar neuropathy at the elbow. *Eur J Radiol* 2017;95:111-117
17. Bäumer P, Dombert T, Staub F, Kaestel T, Bartsch AJ, Heiland S, et al. Ulnar neuropathy at the elbow: MR neurography--nerve T2 signal increase and caliber. *Radiology* 2011;260:199-206
18. Hayashi D, Roemer FW, Katur A, Felson DT, Yang SO, Alomran F, et al. Imaging of synovitis in osteoarthritis: current status and outlook. *Semin Arthritis Rheum* 2011;41:116-130

19. Roemer FW, Kassim Javaid M, Guermazi A, Thomas M, Kiran A, Keen R, et al. Anatomical distribution of synovitis in knee osteoarthritis and its association with joint effusion assessed on non-enhanced and contrast-enhanced MRI. *Osteoarthritis Cartilage* 2010;18:1269-1274
20. Bucknor MD, Stevens KJ, Steinbach LS. Elbow imaging in sport: sports imaging series. *Radiology* 2016;279:12-28
21. Patten RM. Overuse syndromes and injuries involving the elbow: MR imaging findings. *AJR Am J Roentgenol* 1995;164:1205-1211
22. Dlabach JA, Baker Jr CL. Lateral and medial epicondylitis in the overhead athlete. *Oper Tech Orthop* 2001;11:46-54
23. Nirschl RP, Ashman ES. Elbow tendinopathy: tennis elbow. *Clin Sports Med* 2003;22:813-836
24. Martinoli C, Bianchi S, Giovagnorio F, Pugliese F. Ultrasound of the elbow. *Skeletal Radiol* 2001;30:605-614
25. Finlay K, Ferri M, Friedman L. Ultrasound of the elbow. *Skeletal Radiol* 2004;33:63-79
26. Morrey BF, An KN. Functional anatomy of the ligaments of the elbow. *Clin Orthop Relat Res* 1985;201:84-90
27. Otoshi K, Kikuchi S, Shishido H, Konno S. The proximal origins of the flexor-pronator muscles and their role in the dynamic stabilization of the elbow joint: an anatomical study. *Surg Radiol Anat* 2014;36:289-294
28. Kurvers H, Verhaar J. The results of operative treatment of medial epicondylitis. *J Bone Joint Surg Am* 1995;77:1374-1379
29. Gabel GT, Morrey BF. Operative treatment of medial epicondylitis. Influence of concomitant ulnar neuropathy at the elbow. *J Bone Joint Surg Am* 1995;77:1065-1069

내측상과염 환자의 임상항목과 자기공명영상 항목 중 조기 수술적 치료가 필요한 환자군이 갖는 인자에 관한 분석

박형인¹ · 한 석^{1*} · 이지숙¹ · 방진영² · 김영복² · 정현경¹ · 백지연¹

목적 내측 상과염 환자들 중 최종적으로 수술적 치료를 받게 된 환자들의 임상 및 자기공명영상 인자들의 특징을 알아보고자 한다.

대상과 방법 2010년 3월부터 2018년 12월까지 내측 상과염으로 진단받은 환자들 중에서 주관절 자기공명영상을 촬영한 52명의 환자들을 역행적으로 조사하였다. 환자들의 인구통계학적 및 임상적 정보, 자기공명영상 소견들이 평가되었다. 모든 변수들은 보존적인 치료를 받은 환자군과 수술적 치료를 받은 환자군 사이에서 비교되었고, 로지스틱 회귀분석을 통해 어떤 인자가 수술적 치료를 받은 환자군과 연관 있는지 분석하였다.

결과 횡단면 및 관상면 공통 굴곡근 건의 파열 크기($p < 0.001$, $p = 0.013$), 횡단면 및 관상면 공통 굴곡근 건의 이상 정도($p = 0.022$, $p = 0.003$)가 유의미한 차이를 보였다. 또한 내측 측부 인대의 이상 정도($p = 0.025$) 또한 유의미한 차이를 보였다. 로지스틱 회귀분석에서는 오직 공통 굴곡근 건의 횡단면 파열 크기(오즈비: 1.864; 95% 신뢰구간: 1.264~2.750)가 수술적 치료와 관련이 있었다.

결론 내측 상과염으로 진단받은 환자들 중, 더 큰 횡단면 공통 굴곡근 건 파열을 동반한 환자들끼리 결과적으로 수술을 받게 되는 경향성이 보였다.

인제대학교 의과대학 해운대백병원 ¹영상의학과, ²정형외과