

Case report

Open Access

Ultrasound in evaluation of post-interventional femoral vein obstruction: a case report

Mai Tone Lønnebakken*^{1,2}, Eva Gerdts^{1,2}, Jan Wirsching³ and Ole Martin Pedersen¹

Address: ¹Department of Heart Disease, Haukeland University Hospital, Bergen, Norway, ²Institute of Medicine, University of Bergen, Bergen, Norway and ³Department of Radiology, Haukeland University Hospital, Bergen, Norway

Email: Mai Tone Lønnebakken* - mai.tone.lonnebakken@helse-bergen.no; Eva Gerdts - eva.gerdts@helse-bergen.no; Jan Wirsching - jan.wirsching@helse-bergen.no; Ole Martin Pedersen - ole.martin.pedersen@helse-bergen.no

* Corresponding author

Published: 26 March 2009

Received: 22 January 2009

Cardiovascular Ultrasound 2009, **7**:14 doi:10.1186/1476-7120-7-14

Accepted: 26 March 2009

This article is available from: <http://www.cardiovascularultrasound.com/content/7/1/14>

© 2009 Lønnebakken et al; licensee BioMed Central Ltd.

This is an Open Access article distributed under the terms of the Creative Commons Attribution License (<http://creativecommons.org/licenses/by/2.0>), which permits unrestricted use, distribution, and reproduction in any medium, provided the original work is properly cited.

Abstract

Ultrasound is the preferred imaging modality in diagnosis of vascular complications following cardiac catheterization and intervention. In some cases, however, bleeding surrounding the femoral vessels, may severely distort the color Doppler images, making detection of venous complications especially difficult. This report refers to such a case where post-catheterization haematoma was suspected to cause an obstruction of the femoral vein. Spectral Doppler recordings of blood flow in the common femoral vein, up-stream, distal to the hemorrhagic area, confirmed the diagnosis of obstruction by demonstrating changes in the venous flow pattern in the common femoral vein, consistent with venous hypertension. Due to the poor quality of the ultrasound images, the exact cause of the obstruction had to be established by another imaging modality, not affected by haemorrhages. CT showed that the common femoral vein was compressed at the puncture site by surrounding haemorrhages. Thus, when bleeding due to cardiac catheterization is associated with possible venous obstruction and findings by color Doppler are equivocal due to degradation of the color-Doppler image, detection of venous hypertension by spectral Doppler, performed distal to the bleeding area, strongly supports the presence of venous obstruction where the exact cause may be established by CT.

Background

Cardiac catheterization, using the femoral approach, is not infrequently associated with local vascular complications occurring in 1.5–9.0% of cases [1], especially arterial haemorrhage, but may also involve the common femoral vein (CFV), where venous obstruction may occur. Venous obstruction, which is often partial and relatively short, is rarely mentioned in the literature and most probably remains undiagnosed in many cases [2,3].

Color Doppler is the preferred imaging modality in detection and follow-up of venous obstruction. On plain ultrasound (US) images, major veins appear as oval, echo-free structures surrounded by echogenic subcutaneous tissue. Unobstructed veins are completely compressed when moderate pressure is applied to the skin above by the transducer. Unobstructed venous flow, detected by spectral Doppler, is characterized by velocity variations that are synchronous with respiration. When a vein becomes

obstructed by a thrombus it becomes incompressible. Simultaneously there is a rise in the vein pressure distal to the obstruction. When the pressure exceeds the peak pressure level in the abdominal veins the characteristic phasic variations in venous flow velocity disappear [4-6].

Post-interventional bleeding into the tissues surrounding the femoral vessels may cause increased scattering of the US echoes leading to distortion of the US images. In addition the bleeding tends to reduce echoes coming from the vein walls, causing the vein echo to blend in with surrounding hypoechoic haemorrhages and thus no longer be recognized as a separate entity. In these cases, therefore, color Doppler imaging alone may not be fully adequate in the assessment of a possible venous obstruction.

Case presentation

A 54-years-old man was admitted with a non-ST-elevation myocardial infarction. He was treated with standard combined antiplatelet therapy (aspirin and clopidogrel) and low-molecular weight heparin. Using a right femoral approach, he underwent percutaneous coronary intervention with stent implantation in a stenotic right coronary artery. During the first hours after the procedure, despite an apparent successful closure of the hole in the arterial wall by a collagen plug device (Angioseal, St Jude Medical) and standard compression according to department procedures, he developed pain in the right groin followed by a small haematoma and slight swelling of the right leg.

US examination of the proximal right CFV, the following day, showed signs of bleeding at the arterial puncture site, which caused considerable degradation of the color-Doppler image due to scattering of the ultrasound. Despite these problems color Doppler demonstrated a 5 cm long cylindrical hypo-echoic structure with a centrally located channel of venous blood flow medial to the CFV (Fig. 1). A possible venous obstruction, due to a partially occluding intraluminal thrombus or to extrinsic compression of the vein lumen by surrounding haematoma, could not be ruled out. Spectral Doppler recordings, obtained away from the puncture site at the distal part of the right CFV, demonstrated unilateral loss of the normal phasic variations in flow velocities, consistent with venous hypertension (Fig. 2, 3). Subsequent assessment of the proximal CFV by CT, being unaffected by haemorrhages, demonstrated partial compression of a 5 cm long vein segment of the CFV at the level of the arterial puncture site, caused by surrounding haematoma (Fig. 4).

Discussion

Local vascular complications following cardiac catheterizations are not uncommon, the incidence of which are dependent on procedural and patients characteristics [1]

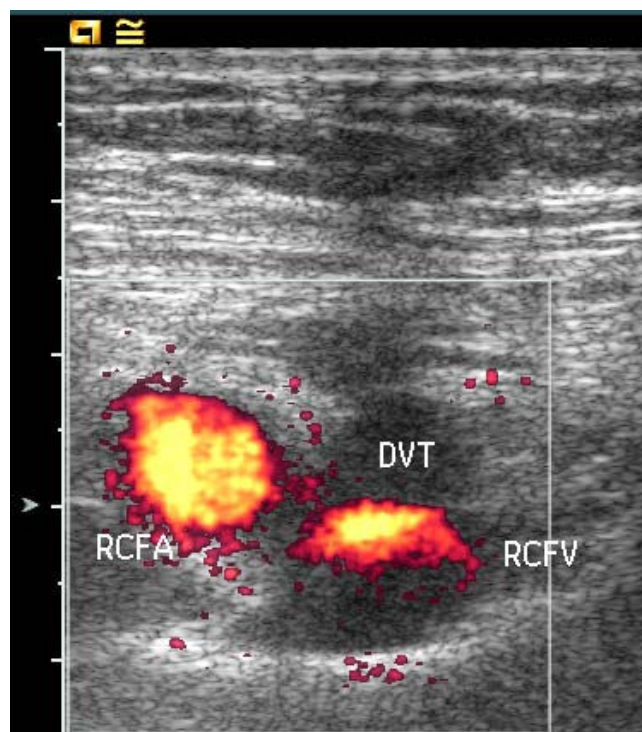


Figure 1
Short axis Power Doppler image showing the right common femoral artery (RCFA) and the non-compressible right femoral vein (RCFV), surrounded by hypoechoic tissue consisting of perivascular hematoma, at first suspected to represent deep vein thrombosis (DVT).

and may reach 1.5–9.0%. The arterial complications include hemorrhagic, haematomas, pseudoaneurysms, arteriovenous fistula, acute arterial occlusions, cholesterol emboli, and infections [1]. The incidence of venous com-

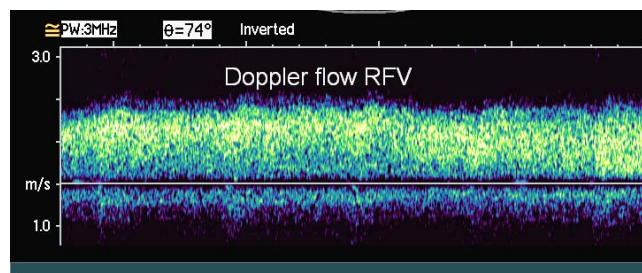


Figure 2
Spectral Doppler imaging of flow in the right common femoral vein showing persistent high velocity venous flow with loss of normal respiratory synchronous variation consistent with "down-stream" venous obstruction.

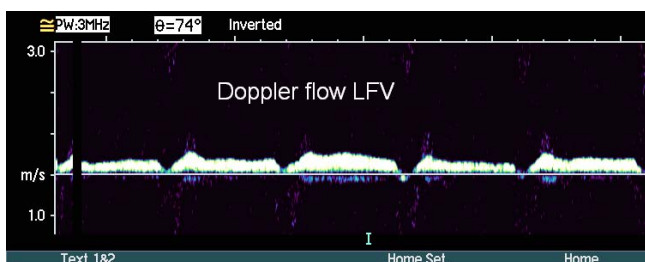


Figure 3
Spectral Doppler imaging of normal venous flow in the left common femoral vein (LCFV), characterized by normal velocities, that vary synchronous with respiration.

plications, especially obstructions where DVT can be potentially life threatening, is seldom mentioned.

This case report demonstrates that, although color Doppler imaging is the preferred modality in diagnosing venous obstruction following cardiac catheterization, bleeding into the surrounding tissues may in some cases cause severe degradation of the color Doppler images and thus may preclude adequate visualization of the CFV. Due to lack of distinct vein wall echoes, the CFV blends in with the surrounding hypoechogenic, thrombus-like haemorrhages, making differentiation between an intravenous

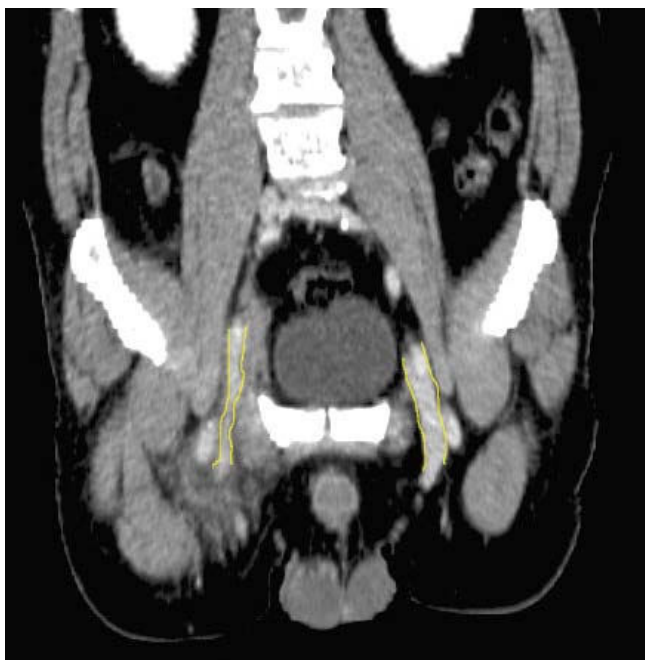

Figure 4
CT image demonstrating the external compression of the right common femoral vein compared by the normal left common femoral vein.

thrombus and a perivascular haematoma compressing the vein from the outside virtually impossible [4,7-9].

Our findings show that in these cases spectral-Doppler recordings, performed away from the bleeding area, at the distal end of the CFV, was able to demonstrate venous flow disturbances consistent with venous hypertension supporting the clinical suspicion of venous obstruction down-stream, at the groin.

The problem of inadequate US visualization of the CFV in connection with cardiac catheterizations has been discussed in a recent publication where it was warned against overlooking short partial obstructions of the CFV [10]. In another publication concerning DVT of the CFV following percutaneous cardiac intervention, the authors found DVT of the CFV to be quite common, occurring in as many as 2.4% of patients [3]. DVT was typically located at the arterial puncture site, the involvement of CFV was short, and the obstruction was often partial.

Therefore, in cases where the femoral vessels are insufficiently visualized by color-Doppler due to bleeding at the puncture site, the US operator should use spectral-Doppler recordings to assess venous flow up-stream, at the level of the distal CFV or the proximal part of the superficial femoral vein, looking for signs of venous hypertension secondary to venous obstruction at the groin. Due to inferior quality of color-Doppler images in these cases, CT, which is largely unaffected by bleeding, may be of considerable help in establishing an exact cause of the venous obstruction.

Consent

Written informed consent was obtained from the patient for publication of this case report and accompanying images.

Competing interests

The authors declare that they have no competing interests.

Authors' contributions

MTL carried out the US examination and drafted the manuscript. EG revised the manuscript. JW carried out the interpretation of the CT examination and revised the manuscript. OMP helped in the evaluation of the US examination and drafting of the manuscript.

References

1. Nasser TK, Mohler ER 3rd, Wilensky RL, Hathaway DR: **Phe-riph-eral vascular complications following coronary inter-ven-tional procedures.** *Clin Cardiol* 1995, **18(11)**:609-14.
2. Zahn R, Fromm E, Thoma S, Lotter R, Zander M, Wagner S, et al: **Local venous thrombosis after cardiac catheterization.** *Angi-ology* 1997, **48**:1-7.
3. Messina LM, Brothers TE, Wakefield TW, Zelenock GB, Lindenauer SM, Greenfield LJ, et al: **Clinical characteristics and surgical management of vascular complications in patients undergo-**

- ing cardiac catheterization: interventional versus diagnostic procedures.** *J Vasc Surg* 1991, **13**:593-600.
4. Hamper UM, Dejong MR, Scoutt LM: **Ultrasound evaluation of the lower extremity veins.** *Radiol Clin North Am* 2007, **45**:525-547.
 5. Bach AM, Hann LE: **When the common femoral vein is revealed as flattened on spectral Doppler sonography: is it a reliable sign for diagnosis of proximal venous obstruction?** *AJR Am J Roentgenol* 1997, **168**:733-736.
 6. Voci SL, Gottlieb RH: **Doppler respiratory patterns in the femoral veins with pelvic vein obstruction.** *Clin Imaging* 1999, **23**:172-176.
 7. Andrews EJ Jr, Fleischer AC: **Sonography for deep venous thrombosis: current and future applications.** *Ultrasound Q* 2005, **21**:213-225.
 8. Mihmanli I, Kantarci F, Ulus SO, Bozlar U, Kadioglu A, Yildirim D: **Lower extremity venous pathology mimicking deep vein thrombosis: 2 case reports.** *Ultraschall Med* 2007, **28**:421-425.
 9. Gauthier GM, Dieter RS: **Successful treatment of a femoral artery pseudoaneurysm mimicking a deep venous thrombosis following cardiac catheterization.** *Catheter Cardiovasc Interv* 2002, **57**:75-78.
 10. Subramanyam K, Suman Bhandari: **A Search for the Cause of a "Complication".** *Indian Heart J* 2006, **58**:274-275.

Publish with **BioMed Central** and every scientist can read your work free of charge

"BioMed Central will be the most significant development for disseminating the results of biomedical research in our lifetime."

Sir Paul Nurse, Cancer Research UK

Your research papers will be:

- available free of charge to the entire biomedical community
- peer reviewed and published immediately upon acceptance
- cited in PubMed and archived on PubMed Central
- yours — you keep the copyright

Submit your manuscript here:
http://www.biomedcentral.com/info/publishing_adv.asp

