

Available online at www.sciencedirect.com

ScienceDirect

journal homepage: www.elsevier.com/locate/radcr

Case Report

STEMI in an adolescent boy due to anomalous left main coronary artery arising from the right sinus of Valsalva: Case report and brief review of the literature ☆,☆☆

Changcheng Li, BS^{a,#}, Wenyan Zhang, BS^{b,#}, Litao Zhang, MD^a, Yuanzhong Xie, MD^a, Xiujuan Li, MD^{a,*}

^a Department of Radiology, Affiliated Taian City Central Hospital of Qingdao University, Taian 271099, Shandong, China

^b Medical Center, the 960th Hospital of the PLA Joint Logistics Support Force, Taian 271000, Shandong, China

ARTICLE INFO

Article history:

Received 25 August 2022

Revised 23 September 2022

Accepted 28 September 2022

Keywords:

Myocardial infarction

Anomalous origin of coronary artery

Coronary computed tomography

angiography

ABSTRACT

Congenital anomalous origin of coronary artery is a rare cardiovascular malformation and the most common anomaly is the left circumflex (LCX) arising from the right sinus of Valsalva (RSV). Other forms include both coronary arteries from RSV, the left anterior descending coronary artery from RSV, and a single coronary artery from the left sinus of Valsalva. Despite being rare, anomalous origin of left main coronary artery (LMCA) from RSV carries a high risk of sudden cardiac death. Here, we report a case of 13-year-old boy with chest pain and acute extensive anterior ST-segment elevation myocardial infarction (STEMI) who was initially diagnosed as acute myocarditis in the emergency department. A bedside echocardiogram showed severe global hypokinesia of left ventricle (LV) and normal right ventricle (RV) function. Coronary computed tomography angiography (CCTA) examination showed LMCA originated from the RSV. The patient underwent coronary artery bypass grafting surgery and was discharged without complications. A timely correct diagnosis of an anomalous coronary artery is critical in symptomatic patients, CCTA plays an important role in clinical decision making.

© 2022 The Authors. Published by Elsevier Inc. on behalf of University of Washington.

This is an open access article under the CC BY-NC-ND license

(<http://creativecommons.org/licenses/by-nc-nd/4.0/>)

☆ Funding: This study was funded by the [Science and Technology Development Plan of Shandong Province](#) (No. 2015WS0114).

☆☆ Competing Interests: None declared.

* Corresponding author.

E-mail address: lixujuan2022zxyy@163.com (X. Li).

Changcheng Li and Wenyan Zhang contributed equally to this manuscript and should be considered co-first authors.

<https://doi.org/10.1016/j.radcr.2022.09.102>

1930-0433/© 2022 The Authors. Published by Elsevier Inc. on behalf of University of Washington. This is an open access article under the CC BY-NC-ND license (<http://creativecommons.org/licenses/by-nc-nd/4.0/>)

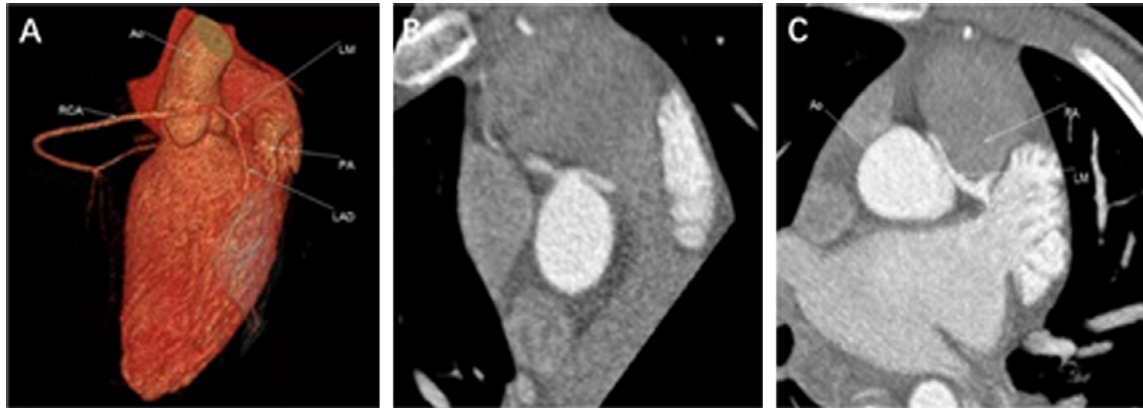


Fig. 1 – Anterior view of the 3-dimensional constructed computed tomography image of the heart (A) and axial view of the coronary computed tomography angiography (B) shows an anomalous origin of the left main coronary artery arising from the right coronary sinus; C (axial view) represents a malignant intra-arterial course between the aorta and main pulmonary artery with severe compression.

Introduction

Anomalous origin of coronary artery is rare, ranging from 0.24% to 1.3% [1,2]. The most common anomaly is left circumflex (LCX) arising from the right sinus of Valsalva (RSV). Other forms include both coronary arteries from RSV, the left anterior descending coronary artery from RSV, and a single coronary artery from the left sinus of Valsalva [3]. Among the different origins of coronary abnormalities, the origin of left main coronary artery (LMCA) from the RSV is the most critical, especially those walking between the ascending aorta and the pulmonary artery, which has a high-risk factor for sudden cardiac death [4]. Despite being rare, cases of abnormal coronary arteries can be fatal. Here we present a case of an anomalous LMCA originating from the RSV in a 13-year-old boy who presented with chest pain.

Case presentation

A 13-year-old boy who presented with chest pain, shortness of breath and syncope after exercise was transported to the emergency department by ambulance services on physical examination. His vital signs were as follows: weak pulse, blood pressure 75/48 mmHg, respiratory rates 18 times/min, resting heart rate 70 beats/min, right axillary temperature 36.9°C. Initial electrocardiogram (ECG) showed ST elevation in leads V1-V3. The patient was admitted with a provisional diagnosis of acute myocarditis by a pediatrician. On the night of admission, the patient developed Adams-Stokes syndrome. Endotracheal intubation and ventilator were immediately used to assist breathing. Repeat ECG demonstrated the sinus rhythm and acute extensive anterior ST-segment elevation myocardial infarction (STEMI). The bedside echocardiogram showed severe global hypokinesia of left ventricle (LV) and normal right ventricle (RV) function. The urgent coronary computed tomography angiography (CCTA) (Fig. 1) showed an anomalous origin

of the LMCA arising from the RSV. It went between the aorta and main pulmonary artery. Then the patient was immediately transferred to the cardiac catheterization lab and underwent coronary angiogram via right femoral artery approach. It showed a malignant intra-arterial course between the aorta and main pulmonary artery with severe compression (90% stenosis) (Fig. 2). There was no obvious stenosis in left anterior descending artery, circumflex artery and right coronary artery. After cardiothoracic surgery consultation, coronary artery bypass grafting (CABG) was recommended due to the malignant course of LMCA. The patient subsequently underwent CABG with the left internal mammary artery (LIMA) to left anterior descending coronary artery (LAD), saphenous vein graft (SVG) to aorta and obtuse marginal (OM). During his subsequent hospitalization, the patient recovered well following the procedure and was discharged without complications. At the one-month follow-up visit, the patient remained asymptomatic and a repeat echocardiography showed markedly improved LV systolic function.

Discussion

Coronary anomalies in adolescents represent a life-threatening form of congenital cardiac pathology. It can be classified by anomalies of origination and course of coronary arteries, anomalies of intrinsic coronary anatomy, anomalies of coronary artery termination, and anomalous collateral vessels [5,6]. Our case can be described as an anomalous origin of LMCA from the RSV. It has 4 sub-categories: pre-pulmonic, anterior to the right ventricular outflow tract; inter-arterial, between the aorta and the pulmonary artery; retroaortic, posterior to the aortic root; trans-septal, through the proximal interventricular septum, analogous to a right superior septal perforator [7]. This patient had a malignant intra-arterial course between the aorta and pulmonary artery, classified as the most dangerous, placing himself at the highest risk of sudden cardiac death.

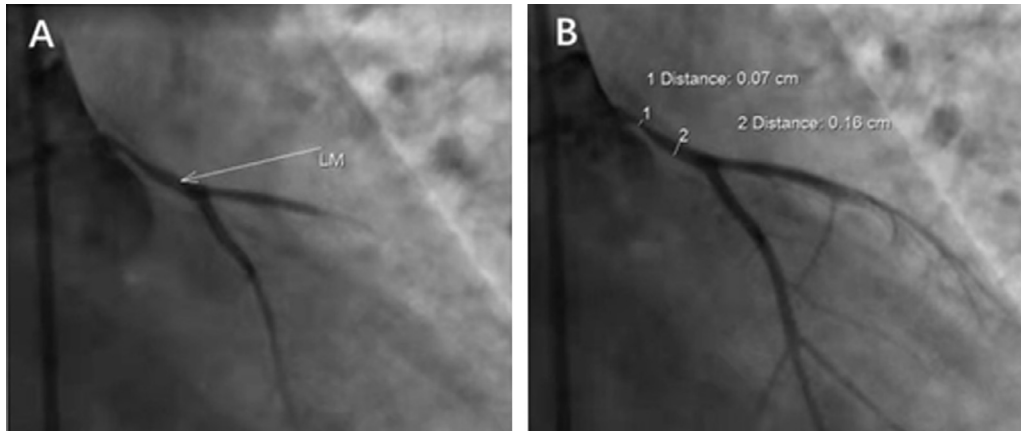


Fig. 2 – Selective coronary angiography of the left coronary artery revealing the 90% stenosis in left main coronary artery (A and B).

Review of the literatures, only 20% of patients with coronary anomalies present with symptoms of ischemic heart disease, mainly including angina, dyspnea, or syncope [8–10]. However, adolescents are often misdiagnosed as myocarditis. Therefore, coronary malformations should be considered when no risk factors for atherosclerosis or signs of myocardial inflammation were found on subsequent examination. Echocardiographic is commonly used to assess left ventricular systolic function but does not provide any additional diagnostic information. The electrocardiographic findings in symptomatic patients are nonspecific, vary from STEMI abnormalities suggestive of ischemia to ventricular tachycardia or atrial fibrillation [11,12]. Coronary computed tomography angiography is currently regarded as the diagnostic standard owing to its fast results and clear delineation of the origin and full path of coronary anomalies [13,14]. Besides, coronary angiography could evaluate high-risk anatomical features, such as proximal narrowing of anomalous coronary arteries [15,16].

In terms of treatment, it is individualized based on the patient's risk assessment and symptom burden. Brothers et al. suggested that symptomatic patients should be treated with beta-blockers and should be advised to avoid strenuous physical activity [17]. Besides, major society guidelines have recommended surgical intervention (class 1 recommendation) for patients with an established diagnosis [17]. Generally speaking, the following factors supported surgical intervention, including young patients <30 years, high-risk anatomical variants and a desire to pursue surgery. Hence, our patient underwent a successful surgery of standard CABG with a saphenous and internal mammary vein grafting.

Conclusions

The anomalous origin of the LMCA from the RSV is rare and can cause an anterior STEMI in young children. A timely correct diagnosis of an anomalous coronary artery is critical in symptomatic patients, and CCTA is a useful diagnostic tool to set the best therapy for the patient.

Patient consent

The written informed consents for publication of the cases were obtained from the patients.

REFERENCES

- [1] Tuncer C, Batyraliev T, Yilmaz R, Gokce M, Eryonucu B, Koroglu S. Origin and distribution anomalies of the left anterior descending artery in 70,850 adult patients: multicenter data collection. *Catheter Cardiovasc Interv* 2006;68:574–85. doi:10.1002/ccd.20858.
- [2] Yamanaka O, Hobbs RE. Coronary artery anomalies in 126,595 patients undergoing coronary arteriography. *Cathet Cardiovasc Diagn* 1990;21:28–40. doi:10.1002/ccd.1810210110.
- [3] Brothers J, Gaynor JW, Paridon S, Lorber R, Jacobs M. Anomalous aortic origin of a coronary artery with an interarterial course: understanding current management strategies in children and young adults. *Pediatr Cardiol* 2009;30:911–21. doi:10.1007/s00246-009-9461-y.
- [4] Young PM, Gerber TC, Williamson EE, Julsrud PR, Herfkens RJ. Cardiac imaging: part 2, normal, variant, and anomalous configurations of the coronary vasculature. *AJR Am J Roentgenol* 2011;197:816–26. doi:10.2214/AJR.10.7249.
- [5] Angelini P. Coronary artery anomalies: an entity in search of an identity. *Circulation* 2007;115:1296–305. doi:10.1161/CIRCULATIONAHA.106.618082.
- [6] Angelini P. Coronary artery anomalies—current clinical issues: definitions, classification, incidence, clinical relevance, treatment guidelines. *Tex Heart Inst J* 2002;29:271–8.
- [7] Hauser M. Congenital anomalies of the coronary arteries. *Heart* 2005;91:1240–5. doi:10.1136/hrt.2004.057299.
- [8] Angelini P. Coronary artery anomalies and sports activities. In: Lawless C, editor. *Sports cardiology essentials*. New York: Springer; 2011. p. 277–98. (ed):. doi:10.1007/978-0-387-92775-6_15.
- [9] Corrado D, Basso C, Rizzoli G, Schiavon M, Thiene G. Does sports activity enhance the risk of sudden death in adolescents and young adults? *J Am Coll Cardiol* 2003;42:1959–63. doi:10.1016/j.jacc.2003.03.002.

- [10] Maron BJ. Sudden death in young athletes. *N Engl J Med* 2003;11:1064–75. doi:[10.1056/NEJMra022783](https://doi.org/10.1056/NEJMra022783).
- [11] Hirachan A, Maskey A, Hirachan GP, Roka M. Anomalous origin of left main coronary artery from the right sinus of Valsalva presenting as non ST elevation acute coronary syndrome: a case report. *Egypt Heart J* 2017;69:215–18. doi:[10.1016/j.ehj.2017.02.002](https://doi.org/10.1016/j.ehj.2017.02.002).
- [12] Liberthson RR, Dinsmore RE, Bharati S, Rubenstein JJ, Caulfield J, Wheeler EO, et al. Aberrant coronary artery origin from the aorta: diagnosis and clinical significance. *Circulation* 1974;50:774–9. doi:[10.1161/01.CIR.50.4.774](https://doi.org/10.1161/01.CIR.50.4.774).
- [13] Hirachan A, Maskey A, Prasad Hirachan G, Roka M. Anomalous origin of left main coronary artery from the right sinus of Valsalva presenting as non ST elevation acute coronary syndrome: a case report. *Egypt Heart J* 2017;69(3):215–18. doi:[10.1016/j.ehj.2017.02.002](https://doi.org/10.1016/j.ehj.2017.02.002).
- [14] Fernandes F, Alam M, Smith S, Khaja F. The role of transesophageal echocardiography in identifying anomalous coronary arteries. *Circulation* 1993;88(6):2532–40. doi:[10.1161/01.cir.88.6.2532](https://doi.org/10.1161/01.cir.88.6.2532).
- [15] Harris MA, Whitehead KK, Shin DC, Keller MS, Weinberg PM, Fogel MA. Identifying abnormal ostial morphology in anomalous aortic origin of a coronary artery. *Ann Thorac Surg* 2015;100(1):174–9. doi:[10.1016/j.athoracsur.2015.02.031](https://doi.org/10.1016/j.athoracsur.2015.02.031).
- [16] Miller JA, Anavekar NS, El Yaman MM, Burkhart HM, Miller AJ, Julsrud PR. Computed tomographic angiography identification of intramural segments in anomalous coronary arteries with interarterial course. *Int J Cardiovasc Imaging* 2012;28(6):1525–32. doi:[10.1007/s10554-011-9936-9](https://doi.org/10.1007/s10554-011-9936-9).
- [17] Brothers J, Gaynor JW, Paridon S, Lorber R, Jacobs M. Anomalous aortic origin of a coronary artery with an interarterial course: understanding current management strategies in children and young adults. *Pediatr Cardiol* 2009;30:911–21. doi:[10.1007/s00246-009-9461-y](https://doi.org/10.1007/s00246-009-9461-y).