

Is Transient Takotsubo Syndrome Associated With Cancer? Why, and With What Implications for Oncocardiology?

Paolo Angelini, MD; Carlo Uribe, MD

The article by Cammann et al¹ in this issue of the *Journal of the American Heart Association (JAHA)* is a welcome addition to the literature on transient Takotsubo syndrome (TTS) and cancer and is especially relevant in the rising field of oncocardiology.² Now, almost 30 years since TTS was first described,² reevaluating the purported association between TTS and cancer, their joint prognosis, and the mechanisms of reciprocal influence seems appropriate.

The Cammann team used the InterTAK (International Takotsubo) Registry, a large, multicenter TTS population database, to update the issues at play. In this study of 1604 InterTAK Registry patients, 16.6% had both TTS and cancer (TTS-C), surely more than would be expected in the general population. Similarly, El-Sayed et al³ reported that of 24 701 TSS patients, 14.4% had cancer (versus 9% who had orthopedic joint injury). Joy et al⁴ found that 1.13% of 122 855 TTS hospital inpatients had cancer, whereas Brunetti et al⁵ found that 6.7% of TTS patients had “present or past malignancies.” Desai et al⁶ reported that the incidence of TTS was 56 per 100 000 chemotherapy-related hospital admissions (and that cancer was found in 4% to 29% of large TTS studies). Tornvall et al⁷ suggested that chemotherapy treatment is a more significant risk factor for TTS onset than the cancer itself.

The conflicting incidence reporting on patients with TTS-C may be because of multiple factors. First, cancer stage (initial and untreated, versus during chemotherapy or radiotherapy), and timing of diagnosis (at hospital admission, versus after treatment) could make a large difference. Second, the clinical diagnosis of TTS is neither simple nor consistent and requires

strict, clear, unified criteria (preferably assessed by a single central committee). As mentioned by Cammann et al,¹ the only specific, reliable test for TTS is acetylcholine spasm-reproduction testing, as we discuss below. In this regard, many TTS investigators and oncologists are concerned about endothelial dysfunction,^{3,6,7} typically focusing on vascular homeostasis as it relates to the effects of chemotherapy and radiotherapy on endothelial function,^{8,9} more than to coronary pathology.

Causes and Clinical Testing in TTS-C

Sudden onset of dramatic deterioration in left ventricle segmental function (usually involving 30–50% of the left ventricle, and shown by echocardiography or ventriculography as apical ballooning or dyskinesia) offers the classic and undisputable evidence of TTS, a potential manifestation of endothelial dysfunction. In fact, both chemotherapy and radiotherapy tend to cause what cardiologists call “coronary endothelial dysfunction,”^{8,9} which is an abnormal spastic tendency in the coronary tree that can manifest not only as angina,⁹ but also as TTS.^{8–11} Indeed, one of the most intriguing and potentially revealing theories in the field of TTS is that substantially increased coronary spasticity may lead to diffuse, transient spastic obliteration of coronary arteries and to critical ischemia, which can be reproduced by acetylcholine testing early after a TTS episode (Figures 1 and 2).

Normally, acetylcholine testing causes vasodilatation. Severe coronary spasm seen in the first days after a TTS episode (Figures 1 and 2) can quickly resolve after intracoronary infusion of nitroglycerine.⁸ Additionally, acetylcholine-induced spasm produces chest pain, ischemic changes on electrocardiographic images, and left ventricle dysfunction of the same type observed at TTS onset. To some, this behavior is evidence that spasm is the clue or natural effector in TTS.^{8,11}

To complicate the issue, clinical experience shows that increased spasticity is a transient event that usually disappears during the first 1 to 10 days and does not recur in 95% of cases, even when precipitating factors like stress or anxiety persist.¹² Results from the large GEIST (German Italian Stress Cardiomyopathy) Registry Study indicated a TTS recurrence rate of 4.0% during a median follow-up of

The opinions expressed in this article are not necessarily those of the editors or of the American Heart Association.

From the Department of Cardiology, Texas Heart Institute, Houston, TX.

Correspondence to: Paolo Angelini, MD, Department of Cardiology, Texas Heart Institute, 6624 Fannin St, Suite 2780, Houston, TX 77030. E-mail: pangellini@leachmancardiology.com

J Am Heart Assoc. 2019;8:e013201. DOI: 10.1161/JAHA.119.013201.

© 2019 The Authors. Published on behalf of the American Heart Association, Inc., by Wiley. This is an open access article under the terms of the Creative Commons Attribution-NonCommercial-NoDerivs License, which permits use and distribution in any medium, provided the original work is properly cited, the use is non-commercial and no modifications or adaptations are made.

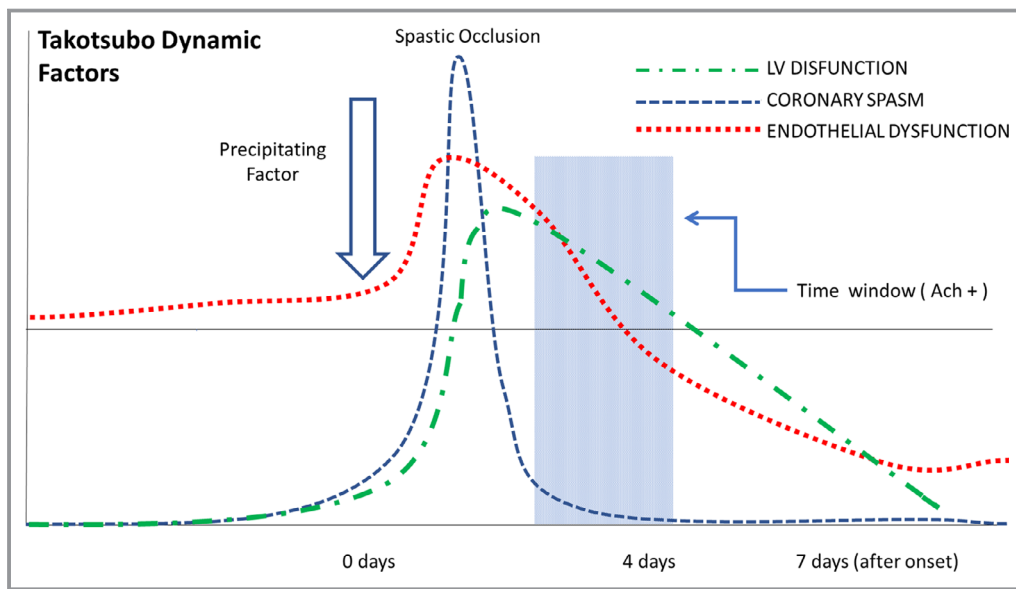


Figure 1. A diagrammatic depiction (according to authors' preliminary opinion based on their own experience, absent definitive accepted evidence) of the critical interplay between cancer, chemotherapy (the predisposing factor), endothelial dysfunction, and the biological history of a transient Takotsubo syndrome in cancer (TTS-C) episode. We believe that endothelial dysfunction is at the base of TTS-C, by way of a sudden spontaneous spasm of great extent and severity (previously unrecognized by most investigators). We also propose that endothelial dysfunction improves quickly after 1 TTS-C episode, as suggested also by the rarity of recurrence. "Time window" indicates the expected interval at which acetylcholine testing is positive. Ach+ indicates acetylcholine-positive testing; LV, left ventricle.

2.3 years.¹² It is critical to recognize the spontaneous disappearance of increased spasticity (positive acetylcholine testing), even if the reason for such resolution is yet unknown. Disappearance of unusual coronary spasticity cannot be taken as evidence that spasm is not involved in TTS; it is part of the process (Figure 1). Although death caused by recurrent TTS is rare, it is more likely to occur in critically ill cancer patients.¹²

We acknowledge that the preferred explanation for TTS is the catecholamine theory, which is responsible for the nomenclature "stress cardiomyopathy." The scientific basis for this theory has been greatly weakened by indirect evidence (serum catecholamine levels are rarely obtained in clinical settings,^{12,13} as their utility in understanding or treating TTS is generally considered trivial).¹⁴ Questionable experimental animal models notwithstanding,¹⁵ strong evidence against the catecholamine theory was directly supplied by a systematic review of detailed reports of pheochromocytoma patients who, despite having high catecholamine levels for years, had a low probability of clinical TTS presentation at each catecholamine surge, and typically have had only 1 episode of TTS, even before the "causative" tumors were removed.¹⁶

TTS-C may turn out to be similar to pheochromocytoma, in that both feature obvious, potential triggering factors and increased risk for spasm, because of endothelial dysfunction.

Cardiomyopathies in TTS-C

The present InterTAK registry presentation¹ did not clearly resolve 2 critical, potentially achievable TTS-C–related points: (1) What are early and late causes of death after a TTS-C episode? (Acute cardiac event? Cancer? Chronic cardiomyopathy?); and particularly (2) What are the causes of cardiomyopathy? It appears that reliable differentiation between TTS and diffuse (toxic) subacute/chronic chemotherapy-related cardiac dysfunction¹⁷ was not prospectively investigated by Cammann et al.¹ Knowing the difference between the 2 is critical for defining the clinical benefits or risks of chemotherapy in TTS-C and for gauging the value of similar registry studies on late prognosis after TTS-C. Recent estimates suggest that 10% of patients receiving chemotherapy have chronic cardiomyopathy, and 60% die within 2 years of diagnosis.^{17–19} Generally, segmental and reversible cardiomyopathy is more likely to be TTS-C related. Conversely, fixed or progressive diffuse cardiomyopathy is probably related not to coronary spasm, but to apoptosis, myocardiolysis, or interstitial fibrosis.^{17–19} When the presentation is borderline, acetylcholine testing is an especially useful method for differentiating the 2 forms.

Incidentally, the importance of establishing a TTS-C diagnosis is fundamental, as it can affect cardiological treatment decisions. Giza et al²⁰ recently published results

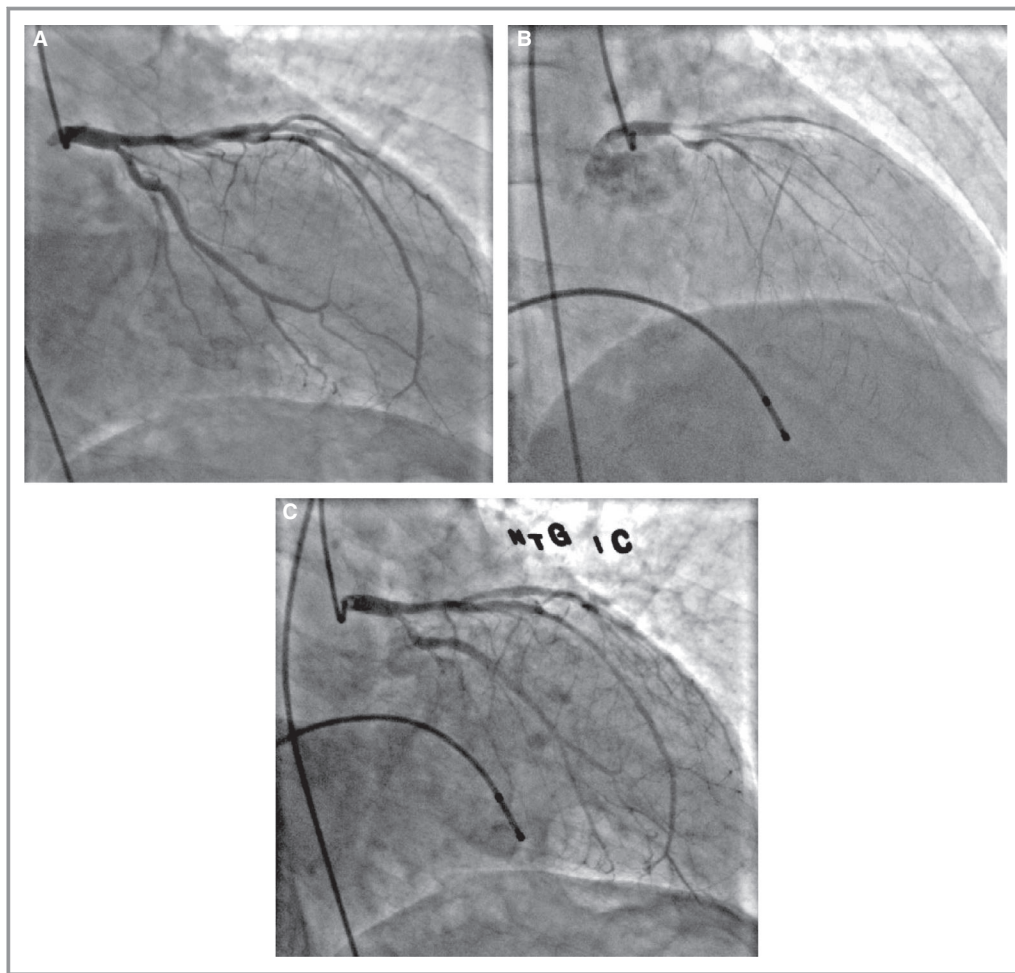


Figure 2. In a typical case of transient Takotsubo syndrome in a patient with cancer, a 68-year-old man with a recent diagnosis of abdominal lymphoma presented with severe chest pain and dyspnea. Electrocardiographic imaging indicated acute coronary syndrome (ST-T changes, mild troponin elevation). Coronary angiography (A) did not show significant coronary lesions, whereas left ventricular angiography showed severe inferior and anterolateral hypokinesia or akinesia (left ventricular ejection fraction [LVEF]=18%, not shown). Intracoronary acetylcholine test (50 μ g) provoked subtotal occlusion of all left coronary branches (B) and severe hemodynamic imbalance, followed by total resolution after intracoronary nitroglycerine infusion (C). Medical treatment (vasodilators) allowed quick recovery. LVEF returned to normal in <10 days.

from 275 patients admitted to a tertiary cancer center with an initial diagnosis of acute coronary syndrome; only 11% were diagnosed as probable TTS-C, when studied by coronary angiography and follow-up (no acetylcholine testing).

Conclusions

It has become increasingly clear in recent years that TTS is probably more frequent than expected in noncancer patients, but we especially need a solid basis for achieving specific TTS diagnoses. Acetylcholine testing could greatly aid the diagnosis of TTS and would doubtless clarify the treatment options for, and improve the safety of, critically ill cancer patients.

Disclosures

None.

References

1. Cammann VL, Sarcon A, Ding KJ, Seifert B, Kato K, Di Vece D, Szawan KA, Gili S, Jurisic S, Bacchi B, Micek J, Frangieh AH, Napp LC, Jaguszewski M, Bossone E, Citro R, D'Ascenzo F, Franke J, Noutsias M, Knorr M, Heiner S, Burgdorf C, Koenig W, Thiele H, Tschöpe C, Rajan L, Michels G, Pfister R, Cuneo A, Jacobshagen C, Karakas M, Banning A, Cuculi F, Kobza R, Fischer TA, Vasankari T, Juhani Airaksinen KE, Dworakowski R, Kaiser C, Osswald S, Galiuto L, Dichtl W, Delmas C, Lairez O, Horowitz JD, Kozel M, Widimský P, Tousek P, Winchester DE, Gilyarova E, Shilova A, Gilyarov M, El-Battrawy I, Akin I, Ukena C, Bauersachs J, Pieske BM, Hasenfuß G, Rottbauer W, Braun-Dullaeus RC, Opolski G, MacCarthy P, Felix SB, Borggrefe M, Di Mario C, Crea F, Katus HA, Schunkert H, Münzel T, Böhm M, Bax JJ, Prasad A, Shinbane S, Lüscher TF, Ruschitzka F, Ghadri JR, Templin C. Clinical features and outcomes of patients with malignancy and takotsubo syndrome: observations from the International Takotsubo Registry. *J Am Heart Assoc.* 2019;8:e010881. DOI: 10.1161/JAHA.118.010881.

2. Hayek SS, Ganatra S, Lenneman C, Scherrer-Crosbie M, Leja M, Lenihan DJ, Yang E, Ryan TD, Liu J, Carver J, Mousavi N, O'Quinn R, Arnold A, Banchs J, Barac A, Ky B. Preparing the cardiovascular workforce to care for oncology patients: JACC review topic of the week. *J Am Coll Cardiol*. 2019;73:2226–2235.
3. El-Sayed AM, Brinjikji W, Salka S. Demographic and co-morbid predictors of stress (takotsubo) cardiomyopathy. *Am J Cardiol*. 2012;110:1368–1372.
4. Joy PS, Guddati AK, Shapira I. Outcomes of takotsubo cardiomyopathy in hospitalized cancer patients. *J Cancer Res Clin Oncol*. 2018;144:1539–1545.
5. Brunetti ND, Tarantino N, Guastafierro F, De Gennaro L, Correale M, Stiermaier T, Möller C, Di Biase M, Eitel I, Santoro F. Malignancies and outcome in takotsubo syndrome: a meta-analysis study on cancer and stress cardiomyopathy. *Heart Fail Rev*. 2019;24:481–488.
6. Desai R, Abbas SA, Goyal H, Durairaj A, Fong HK, Hung O, Sachdeva R, Barac A, Yusuf SW, Kumar G. Frequency of takotsubo cardiomyopathy in adult patients receiving chemotherapy (from a 5-year nationwide inpatient study). *Am J Cardiol*. 2019;123:667–673.
7. Tornvall P, Collste O, Ehrenborg E, Järnbert-Pettersson H. A case-control study of risk markers and mortality in takotsubo stress cardiomyopathy. *J Am Coll Cardiol*. 2016;67:1931–1936.
8. Angelini P. Transient left ventricular apical ballooning: a unifying pathophysiologic theory at the edge of Prinzmetal angina. *Catheter Cardiovasc Interv*. 2008;71:342–352.
9. Ong P, Athanasiadis A, Borgulya G, Mahrholdt H, Kaski JC, Sechtem U. High prevalence of a pathological response to acetylcholine testing in patients with stable angina pectoris and unobstructed coronary arteries. The ACOVA Study (Abnormal COronary VAsomotion in patients with stable angina and unobstructed coronary arteries). *J Am Coll Cardiol*. 2012;59:655–662.
10. Tocchetti CG, Cadeddu C, Di Lisi D, Femminò S, Madonna R, Mele D, Monte I, Novo G, Penna C, Pepe A, Spallarossa P, Varricchi G, Zito C, Pagliaro P, Mercurio G. From molecular mechanisms to clinical management of antineoplastic drug-induced cardiovascular toxicity: a translational overview. *Antioxid Redox Signal*. 2019;30:2110–2153.
11. Verna E, Provasoli S, Ghiringhelli S, Morandi F, Salerno-Uriarte J. Abnormal coronary vasoreactivity in transient left ventricular apical ballooning (takotsubo) syndrome. *Int J Cardiol*. 2018;250:4–10.
12. El-Battrawy I, Santoro F, Stiermaier T, Möller C, Guastafierro F, Novo G, Novo S, Mariano E, Romeo F, Romeo F, Thiele H, Guerra F, Capucci A, Giannini I, Brunetti ND, Eitel I, Akin I. Incidence and clinical impact of recurrent takotsubo syndrome: results from the GEIST Registry. *J Am Heart Assoc*. 2019;8:e010753. DOI: 10.1161/JAHA.118.010753.
13. Templin C, Ghadri JR, Diekmann J, Napp LC, Bataiosu DR, Jaguszewski M, Cammann VL, Sarcon A, Geyer V, Neumann CA, Seifert B, Hellermann J, Schwyzer M, Eisenhardt K, Jenewein J, Franke J, Katus HA, Burgdorf C, Schunkert H, Moeller C, Thiele H, Bauersachs J, Tschöpe C, Schultheiss HP, Laney CA, Rajan L, Michels G, Pfister R, Ukena C, Böhm M, Erbel R, Cuneo A, Kuck KH, Jacobshagen C, Hasenfuss G, Karakas M, Koenig W, Rottbauer W, Said SM, Braun-Dullaeus RC, Cuculi F, Banning A, Fischer TA, Vasankari T, Airaksinen KE, Fijalkowski M, Rynkiewicz A, Pawlak M, Opolski G, Dworakowski R, McCarthy P, Kaiser C, Osswald S, Galiuto L, Crea F, Dichtl W, Franz WM, Empen K, Felix SB, Delmas C, Lairez O, Erne P, Bax JJ, Ford I, Ruschitzka F, Prasad A, Lüscher TF. Clinical features and outcomes of takotsubo (stress) cardiomyopathy. *N Engl J Med*. 2015;373:929–938.
14. Y-Hassan S. Plasma epinephrine levels and its causal link to takotsubo syndrome revisited: critical review with a diverse conclusion. *Cardiovasc Revasc Med*. 2018. Available at: <https://www.sciencedirect.com/science/article/pii/S1553838918304664?via%3Dihub>. Accessed June 15, 2019.
15. Angelini P, Tobis JM. Is high-dose catecholamine administration in small animals an appropriate model for takotsubo syndrome? *Circ J*. 2015;79:897.
16. Batisse-Lignier M, Pereira B, Motreff P, Pierrard R, Burnot C, Vorillon C, Maqdasy S, Roche B, Desbiez F, Clerfond G, Citron B, Lussan JR, Tauveron I, Eschalié R. Acute and chronic pheochromocytoma-induced cardiomyopathies: different prognoses? A systematic analytical review. *Medicine (Baltimore)*. 2015;94:e2198.
17. Plana JC, Galderisi M, Barac A, Ewer MS, Ky B, Scherrer-Crosbie M, Ganame J, Sebag IA, Agler DA, Badano LP, Banchs J, Cardinale D, Carver J, Cerqueira M, DeCara JM, Edvardsen T, Flamm SD, Force T, Griffin BP, Jerusalem G, Liu JE, Magalhães A, Marwick T, Sanchez LY, Sicari R, Villarraga HR, Lancellotti P. Expert consensus for multimodality imaging evaluation of adult patients during and after cancer therapy: a report from the American Society of Echocardiography and the European Association of Cardiovascular Imaging. *Eur Heart J Cardiovasc Imaging*. 2014;15:1063–1093.
18. Tanaka H. Echocardiography and cancer therapeutics-related cardiac dysfunction. *J Med Ultrason (2001)*. 2019. Available at: <https://link.springer.com/article/10.1007%2Fs10396-019-00947-1>. Accessed June 15, 2019.
19. Moslehi JJ. Cardiovascular toxic effects of targeted cancer therapies. *N Engl J Med*. 2016;375:1457–1467.
20. Giza DE, Lopez-Mattei J, Vejpongsa P, Munoz E, Iliescu G, Kitkungvan D, Hassan SA, Kim P, Ewer MS, Iliescu C. Stress-induced cardiomyopathy in cancer patients. *Am J Cardiol*. 2017;120:2284–2288.

Key Words: Editorials • cancer and stroke • cardiomyopathy • Takotsubo cardiomyopathy • Takotsubo syndrome