



Case report

# Use of hyaluronic acid gel filler to improve contact lens wear in patients with deep sunken superior sulcus

Mehryar Ray Taban<sup>a,b,\*</sup>, Neda Shamie<sup>c</sup>

<sup>a</sup> Private Practice, Beverly Hills, CA, USA

<sup>b</sup> Department of Orbital and Plastic Reconstructive Surgery, Jules Stein Eye Institute, David Geffen School of Medicine at UCLA, Los Angeles, CA, USA

<sup>c</sup> Advanced Vision Care, Los Angeles, CA, USA

Received 2 October 2017; revised 25 December 2017; accepted 10 January 2018

Available online 10 February 2018

## Abstract

**Purpose:** Deep sunken superior sulcus of the upper eyelid can result from aging, genetic, prostaglandin use, and prior aggressive upper blepharoplasty. If severe, it can cause exposure keratopathy, lagophthalmos, and giant fornix syndrome. We herein report on another milder manifestation of deep superior sulcus and its treatments.

**Methods:** Case report.

**Results:** Deep sunken superior sulcus syndrome caused to soft contact lens displacement and wear intolerance and was treated with upper eyelid sulcus hyaluronic acid gel injection.

**Conclusions:** Contact lens wear intolerance is likely more common in patients with deep sunken superior sulcus syndrome and can potentially be treated with superior sulcus hyaluronic acid gel injection.

Copyright © 2018, Iranian Society of Ophthalmology. Production and hosting by Elsevier B.V. This is an open access article under the CC BY-NC-ND license (<http://creativecommons.org/licenses/by-nc-nd/4.0/>).

**Keywords:** Eyelid filler; Sunken eye; Cosmetic eyelid surgery; Non-surgical; Contact lens; Hyaluronic acid gel

## Introduction

Aging, genetics, prostaglandin use and prior aggressive blepharoplasty are among the many causes which can lead to deep superior sulcus of the upper eyelid with fat atrophy and resultant retraction of the upper eyelid skin, orbicularis muscle, and orbital septum.<sup>1</sup> This can lead to sunken superior sulcus syndrome with exposure keratopathy and lagophthalmos from suboptimal orbicularis function and effective skin shortening.<sup>2</sup> Giant fornix syndrome is a related condition with recalcitrant conjunctivitis in elderly patients with deep

superior fornix with subsequent accumulation of mucopurulent secretions and persistent discharge.<sup>3</sup>

The authors herein report on another manifestation of deep superior sulcus, namely soft contact lens displacement and wear intolerance, and its successful management with upper eyelid sulcus hyaluronic acid gel injection.

## Case report

A-60-year old female, with previous history of blepharoplasty, presented with hollow sunken upper eyelids and dark circles around the eyes. She complained of skeletalized appearance of her eyes and incidentally was also complaining of difficulty with her soft contact lens use due to discomfort and frequent displacement of the contact lens deep under the upper eyelid. She requested a non-surgical aesthetic improvement of her eyes and was offered filler injection to help give her more youthful appearing eyes. She underwent

Proprietary interests and financial support: None.

Authors obtained informed consents from the patients to publish the photos.

\* Corresponding author. 9735 Wilshire Blvd, Suite 319, Beverly Hills, CA, 90212, USA.

E-mail address: [doctor@TabanMD.com](mailto:doctor@TabanMD.com) (M.R. Taban).

Peer review under responsibility of the Iranian Society of Ophthalmology.

<https://doi.org/10.1016/j.joco.2018.01.004>

2452-2325/Copyright © 2018, Iranian Society of Ophthalmology. Production and hosting by Elsevier B.V. This is an open access article under the CC BY-NC-ND license (<http://creativecommons.org/licenses/by-nc-nd/4.0/>).

hyaluronic acid gel filler injection (by M.R.T.) in superior upper eyelids (in area of superior sulcus/fornix, at and just deep to the superior orbital rim, above the eyelid crease) and tear trough (orbital rim hollowness) under eyes to reduce the sunken, hollow eye appearance. She received 0.7 cc hyaluronic acid gel injection in each upper eyelid and 0.5 cc in each lower eyelid area. The recovery was quick with expected bruising/swelling and temporary uneven contour of the upper eyelid sulcus. She was seen one month post-eyelid-filler injection as routine follow-up. In addition to gaining an improved aesthetic appearance of the eyelids, she stated that she can now wear her soft contact lens much more comfortably and the contact lenses do not ride up in her superior fornix any longer. She reported the benefits persisted even at her last follow-up at 9 months post-injection (Fig. 1).

A 77-year-old female presented with periorbital hollowness and deep superior sulcus. She complained of looking older and was seeking care to improve the cosmesis of her eyes. Further questioning revealed she had eye irritation OS > OD and also had difficulty tolerating her soft contact lenses with the contact sliding superiorly with difficulty retrieving the contact lens on multiple occasions. After discussion of cosmetic enhancement with hyaluronic acid gel filler injection in the eyelids and along orbital rim with possible added benefit of improved contact lens wear, she underwent treatment (by M.R.T.). She received 0.7 cc hyaluronic acid gel filler injection in right superior upper eyelid (at and just deep to the superior orbital rim, above the eyelid crease) and 0.9 cc on the left side. The recovery was quick with expected bruising/swelling and temporary uneven contour of

the upper eyelid sulcus. At one month post-treatment follow-up, she reported significant improvement in eye comfort and soft contact lens wear and overall aesthetic eye improvement. Improvement in contact lens wear remained stable up to her last follow-up 8 months post-treatment (Fig. 2).

## Discussion

Deep sunken superior sulcus of the upper eyelid can result from aging, genetic, prostaglandin use, and prior aggressive upper blepharoplasty.<sup>1</sup> It is usually merely a cosmetic issue with the patient complaining of looking older and tired with skeletalized eye appearance. In its extreme form, however, it can lead to sunken superior sulcus syndrome and/or giant fornix syndrome.<sup>2,3</sup> Its management has included medical therapy, volume augmentation (through fat or filler), and fornix shortening with conjunctival excision.<sup>2–4</sup>

In addition to its aesthetic use for eye enhancement,<sup>5</sup> hyaluronic acid gel as upper eyelid filler has been used for functional purposes in the past with good efficacy and safety profile. It has been used to treat paralytic upper eyelid lagophthalmos,<sup>6</sup> restrictive upper eyelid lagophthalmos,<sup>7,8</sup> sunken superior sulcus syndrome and giant fornix syndrome.

We reported on likely a more common, but not yet reported, manifestation of deep superior sulcus from upper eyelid hollowness, namely soft contact lens superior displacement and contact lens wear difficulty in such patients. This is due to mechanical eyelid/conjunctiva “misalignment” leading dead space in the superior fornix and poor eyelid-conjunctiva movement with resultant “friction” and eye irritation.<sup>2,3</sup>

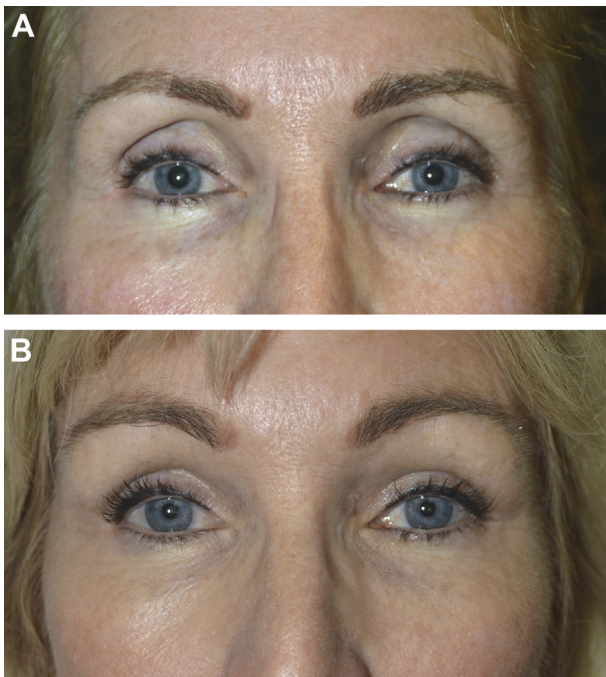


Fig. 1. 60-year-old female, with hollow sunken upper eyelids complained of looking old. She received hyaluronic acid gel filler injection in upper eyelids (0.7 cc each side) in the area of superior sulcus (at and just deep to the superior orbital rim, above the eyelid crease) plus additional 0.5 cc in the under eye area. A) Before and B) 1 month post-injection photos are shown.

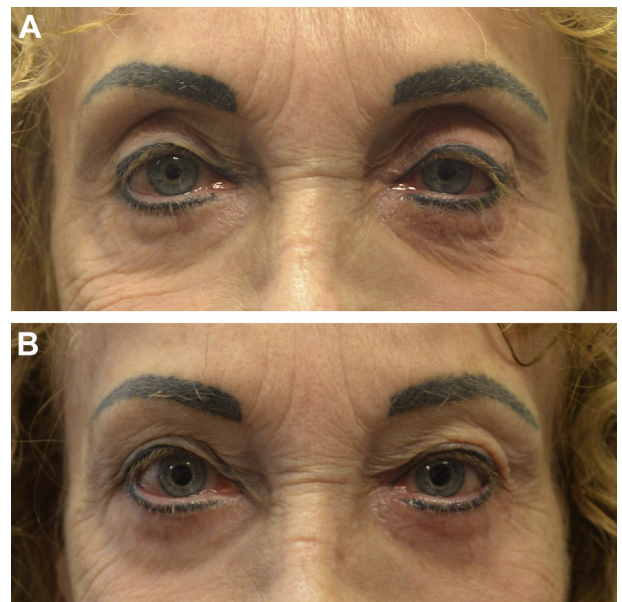


Fig. 2. 77-year-old female, with hollow sunken upper eyelids complained of looking old. She also complained of eye irritation OS > OD and contact lens wear difficulty. She received hyaluronic acid gel filler injection in upper eyelids (0.7 cc on right side, 0.9 cc on left side) in the area of superior sulcus (at and just deep to the superior orbital rim, above the eyelid crease). A) Before and B) 1 month post-injection photos are shown.

Additionally we report the successful treatment of this related contact lens intolerance with non-invasive superior upper eyelid hyaluronic acid filler injection. The necessary added volume likely resets more proper eyelid-conjunctiva alignment and surface gliding movement. The benefit of added volume should not be unexpected as the main culprit in superior sulcus syndrome is fat loss. Further studies, including corneal and conjunctival assessment before and after eyelid filler injection in such patients, would be useful. Given that the results of hyaluronic acid gel eyelid filler are expected to be temporary, long-term studies of such patients would also be beneficial.

## References

1. Rabinowitz MP, Katz L, Moster MR, et al. Unilateral prostaglandin-associated periorbitopathy: a syndrome involving upper eyelid retraction distinguishable from the aging sunken eyelid. *Ophthalmic Plast Reconstr Surg*. 2015;31(5):373–378.
2. Leyngold IM, Berbos ZJ, McCann JD, Pariseau B, Leyngold AR, Anderson RL. Use of hyaluronic acid gel in the treatment of lagophthalmos in sunken superior sulcus syndrome. *Ophthalmic Plast Reconstr Surg*. 2014;30(2):175–179.
3. Rose GE. The giant fornix syndrome: an unrecognized cause of chronic, relapsing, grossly purulent conjunctivitis. *Ophthalmology*. 2004;111(8):539–545.
4. Vahdani K, Lim LA, Thaller VT. Fornix reduction for treatment of giant fornix syndrome. *Ophthalmic Plast Reconstr Surg*. 2016;32:313–314.
5. Morely AM, Taban M, Malhotra R, Goldberg RA. Use of hyaluronic Acid gel for upper eyelid filling and contouring. *Ophthalmic Plast Reconstr Surg*. 2009;25(6):440–444.
6. Mancini R, Taban M, Lowinger A, et al. Use of hyaluronic Acid gel in the management of paralytic lagophthalmos: the hyaluronic Acid gel "gold weight". *Ophthalmic Plast Reconstr Surg*. 2009;25(1):23–26.
7. Taban M, Mancini R, Nakra T, et al. Nonsurgical management of congenital eyelid malpositions using hyaluronic Acid gel. *Ophthalmic Plast Reconstr Surg*. 2009;25(4):259–263.
8. Kwong Q, Malhotra R, Morely AM, Mohammed S, Norris JH. Use of dermal filler to improve exposure keratopathy in a patient with restrictive dermopathy. *Orbit*. 2013;32(1):70–72.