



# *Phthirus pubis* Infestation of the Scalp: A Case Report and Review of The Literature

Stefano Veraldi\*, Paolo Pontini, Gianluca Nazzaro

Department of Pathophysiology and Transplantation, Università degli Studi di Milano, I.R.C.C.S. Foundation,  
Cà Granda Ospedale Maggiore Policlinico, Milan, Italy

**Abstract:** *Phthirus pubis* usually infests the pubis, groin, buttocks and perianal region. It can sometimes infest the thighs, abdomen, chest, axillae and beard. Eyelashes and eyebrows may be involved in children. The involvement of the scalp is very rare. We describe a case of *P. pubis* infestation located exclusively on the scalp in an adult woman. Neither lice/nits nor skin lesions were observed elsewhere, including eyebrows, eyelashes, axillae, pubis, buttocks and perianal region (the patient was hairless in the axillae and pubis). A review of the literature is enclosed.

**Key words:** *Phthirus pubis*, pubis, scalp

## INTRODUCTION

*Phthirus pubis* Linnaeus, 1758 (Diptera: Anoplura), popularly known as crab louse, usually infests the pubis, groin, buttocks and perianal region. However, it can also infest, in particular in hairy males, the thighs, abdomen, chest, axillae and beard. Eyelashes and eyebrows are sometimes involved in children. The involvement of the scalp is very rare. We describe a case of *P. pubis* infestation located exclusively on the scalp in an adult woman.

## CASE RECORD

A 37-year-old Italian woman was admitted because of a rash on the nape, shoulders and upper portion of the back. The patient stated she was in good general health and that she was not in therapy with systemic drugs. She also declared that the rash had appeared approximately 2 months before, a few days after her return from a trip to Vietnam and China. The rash was diagnosed at other centers as allergic contact dermatitis and unsuccessfully treated with topical corticosteroids and oral antihistamines. The patient complained of severe itching

on the scalp, neck, shoulders and upper portion of the back.

Dermatological examination revealed several isolated or confluent, roundish, erythematous papules, covered by scales, on the nape, shoulders and upper portion of the back (Fig. 1). Furthermore, numerous nits and adults of *P. pubis* were observed on the scalp (Fig. 2). Microscopical examinations confirmed that the lice were *P. pubis*. Neither lice/nits nor skin lesions were observed elsewhere, including eyebrows, eyelashes, axillae, pubis, buttocks and perianal region (the patient was hairless in the axillae and pubis). Dermatological examination of the patient's husband and children (a 17-year-old girl and a 15-year-old boy) was negative. According to the patient's history, both children were never affected by scalp pediculosis. It was therefore impossible to trace the source of the infestation. Bacteriological and mycological examinations were negative.

The patient was successfully treated with a foam containing 0.165% pyrethrins and 1.65% piperonylbutoxide (1 application/day for 2 days; the treatment was repeated 10 days later). Follow up (10 months) was negative.

## DISCUSSION

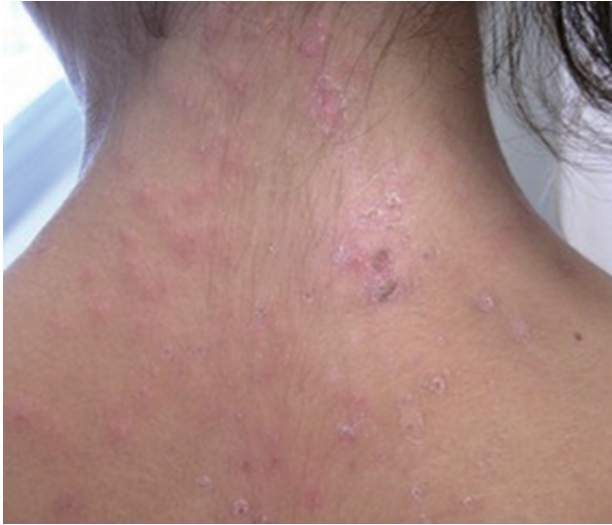The first case of scalp involvement by *P. pubis* was published in 1892 [1]. Since then, approximately 20 cases have been published [1-14]. The involvement of the scalp by this louse is therefore considered as very rare, although it is likely underestimated. However, this is the first case of scalp involvement by *P. pubis* we have observed in the last 35 years at our Dermatol-

•Received 19 April 2018, revised 27 August 2018, accepted 2 October 2018.

\*Corresponding author (stefano.veraldi@unimi.it)

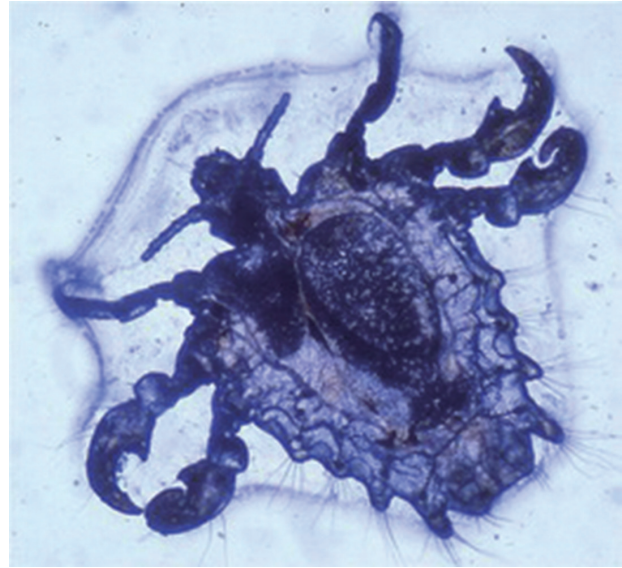
© 2018, Korean Society for Parasitology and Tropical Medicine

This is an Open Access article distributed under the terms of the Creative Commons Attribution Non-Commercial License (<http://creativecommons.org/licenses/by-nc/4.0>) which permits unrestricted non-commercial use, distribution, and reproduction in any medium, provided the original work is properly cited.



**Fig. 1.** Several isolated or confluent, roundish, erythematous papules, covered by scales, located on the nape, shoulders and upper portion of the back.

ogy Unit. The reason of the rarity of *P. pubis* infestation on the scalp is unknown. The hypothesis according to which this louse grows only in areas rich in apocrine glands is not convincing, because these glands are very rare on the scalp [1]. All cases reported so far have been Caucasians or Asians. According to the photographs reported in the articles, all patients had straight hair [2,4,9,12,13]. Cases have been observed in France [12], Turkey [14], Israel [7], India [1], China [11], Taiwan [9], Japan [8,13], Malaysia [10], Canada [6] and United States [2-5]. The infestation was diagnosed in children [1,3,6-8,10,11,14] as well as in adults [2-5,9,10,12,13]. Several authors observed on the scalp, in addition to nits, more or less numerous adults of *P. pubis* [2-5,11]: this is in contrast to infestations caused by *Pediculus humanus capitis* De Geer, 1767, where the lice are often difficult to observe [2]. As previously mentioned, we found on the scalp of our patient several adults of *P. pubis*. A co-infestation on the scalp by both *P. humanus capitis* and *P. pubis* was diagnosed in 2 siblings [1]. An additional important difference between the 2 infestations is pruritus: the latter is very common and severe in *P. pubis* infestation on the scalp [2,4,5,9,11]. This explains the frequent observation of excoriations due to scratching [2,5]. The occipital region, nape and upper portion of the back, as in our patient, are most involved [1-5]. It is interesting to observe that in some patients the infestation occurred only on the scalp: no involvement of other skin regions, such as the pubis, were observed [1,4,5]. Also, in our patient the infestation involved only the scalp.



**Fig. 2.** Adult of *Phthirus pubis*.

Although a very small number of patients with *P. pubis* infestation on the scalp has been reported in the literature, it is possible that it is misdiagnosed as pediculosis caused by *P. humanus capitis*. As suggested by some authors [5], microscopic examination of the lice observed on the scalp is helpful for a correct etiological diagnosis.

## CONFLICTS OF INTEREST

We have no conflict of interest.

## REFERENCES

1. Singh S, Singh N, Ray JC, Roy S, Garg SP. *Phthirus pubis* infestation of the scalp: report of three cases. *Rev Infect Dis* 1990; 12: 560.
2. Elgart ML, Higdon RS. Pediculosis pubis of the scalp. *Arch Dermatol* 1973; 107: 916-917.
3. Mueller JE. Pubic lice from the scalp hair; a report of two cases. *J Parasitol* 1973; 59: 943-944.
4. Witkowski JA, Parish LC. Pthiriasis capitis. *Int J Dermatol* 1979; 18: 559-560.
5. Signore RJ, Love J, Boucree MC. Scalp infestation with *Phthirus pubis*. *Arch Dermatol* 1989; 125: 133.
6. Silburt BS, Parsons WL. Scalp infestation by *Phthirus pubis* in a 6-week-old infant. *Pediatr Dermatol* 1990; 7: 205-207.
7. Klaus S, Shvil Y, Mumcuoglu KY. Generalized infestation of a 3 1/2-year-old girl with the pubic louse. *Pediatr Dermatol* 1994; 11: 26-28.

8. Ikeda N, Nomoto H, Hayasaka S, Nagaki Y. *Phthirus pubis* infestation of the eyelashes and scalp hairs in a girl. *Pediatr Dermatol* 2003; 20: 356-357.
9. Lai HH, Chuang SD, Hu CH, Lee WR. Phthiriasis capitis. *Int J Dermatol* 2005; 44: 771-773.
10. Pakeer O, Jeffery J, Abdullah AM, Ahmad F, Baharudin O. Four cases of pediculosis caused by *Pthirus pubis* Linnaeus 1758 (Diptera: Anoplura) from peninsular Malaysia. *Trop Biomed* 2007; 24: 101-103.
11. Zhang RZ, Zhu WY. Familial phthiriasis infesting the eyelashes, scalp hair and pubic hair. *Eur J Pediatr Dermatol* 2012; 22: 245-248.
12. Akhouni M, Cannel A, Arab MK, Marty P, Delaunay P. An old lady with *Pediculosis pubis* on the head hair. *J Eur Acad Dermatol Venereol* 2016; 30: 885-887.
13. Eto A, Nakamura M, Ito S, Tanaka M, Furue M. An outbreak of pubic louse infestation on the scalp hair of elderly women. *J Eur Acad Dermatol Venereol* 2017; 31: 79-80.
14. Senturk N. *Phthirus pubis* infestation of the eyelashes and scalp in a five year old girl. *Pediatr Dermatol* 2017; 34 (suppl): 155-156.

