

References

1. van Velzen E, de Coster E, van Binnendijk R, Hahné S. Measles outbreak in an anthroposophic community in The Hague, the Netherlands, June–July 2008. *Euro Surveill*. 2008;13(31):18945.
2. van den Hof S, Meffre CM, Conyn-van Spaendonck MA, Woonink F, de Melker HE, van Binnendijk RS. Measles outbreak in a community with very low vaccine coverage, the Netherlands. *Emerg Infect Dis*. 2001;7(Suppl):593–7. DOI: 10.3201/eid0703.010343
3. Schmid D, Holzmann H, Abele S, Kasper S, König S, Meusburger S et al. An ongoing multi-state outbreak of measles linked to non-immune anthroposophic communities in Austria, Germany, and Norway, March–April 2008. *Euro Surveill*. 2008;13:18838.
4. Glass K, Grenfell BT. Waning immunity and subclinical measles infections in England. *Vaccine*. 2004;22:4110–6. DOI: 10.1016/j.vaccine.2004.02.047
5. van den Hof S, Wallinga J, Widdowson MA, Conyn-van Spaendonck MA. Protecting the vaccinating population in the face of a measles epidemic: assessing the impact of adjusted vaccination schedules. *Epidemiol Infect*. 2002;128:47–57. DOI: 10.1017/S0950268801006409
6. Hahné S, Macey J, van Binnendijk R, Kohl R, Dolman S, van der Veen Y, et al. Rubella outbreak in the Netherlands, 2004–2005: high burden of congenital infection and spread to Canada. *Pediatr Infect Dis J*. 2009;28:795–800.
7. van Lier EA, van Oomen PJ, Oostenbrug MW, Zwakhals SL, Drijfhout IH, de Hoogh PA, et al. Immunization coverage National Immunization Programme in the Netherlands, year of report 2006–2008 [in Dutch]. RIVM report 2008;210021007 [cited 2009 June 8]. <http://www.rivm.nl/bibliotheek/rapporten/210021007.html>
8. World Health Organization EURO. Eliminating measles and rubella and preventing congenital rubella infection: WHO European Region strategic plan 2005–2010. 2005 [cited 2009 Jun 8]. <http://www.euro.who.int/Document/E87772.pdf>

Address for correspondence: Susan Hahné, RIVM, Centre for Infectious Disease Control, PO Box 1, 3720 BA Bilthoven, the Netherlands; email: susan.hahne@rivm.nl

All material published in *Emerging Infectious Diseases* is in the public domain and may be used and reprinted without special permission; proper citation, however, is required.

Neurologic Manifestations of Pandemic (H1N1) 2009 Virus Infection

To the Editor: In April 2009, the outbreak of influenza A pandemic (H1N1) 2009 virus was reported. Subsequently, the disease spread throughout the world, and the pandemic alert level was raised to level 6 in June by the World Health Organization. Pandemic (H1N1) 2009 virus infection spread to Thailand and is now found throughout Thailand. Similar to the effects of other viruses, pandemic (H1N1) 2009 virus may cause neurologic complications. Associated neurologic symptoms were first reported from Dallas, Texas, USA: 4 children experienced unexplained seizures or had an alteration of consciousness level that was associated with this virus (1). We report an adult patient with pandemic (H1N1) 2009 infection who had neurologic complications.

A 34-year-old man, previously healthy, was admitted to Chaiphaphum Hospital in Chaiphaphum, Thailand, on August 24, 2009, with influenza-like symptoms. Two days after admission, progressive quadriplegia with bilateral, symmetric paresthesia (glove-and-stock pattern), and areflexia developed. His motor weakness (grades III/V) began in both legs and then involved both arms and hands. Other neurologic examinations showed limitation of extraocular movement in all directions, normal pupil size and light reflex, and facial diplegia. A lumbar puncture was performed, and cerebrospinal fluid (CSF) contained neither leukocytes nor erythrocytes, with a protein level of 19.5 mg/dL.

On day 3 after the patient's admission, acute respiratory failure developed. A nasopharyngeal aspirate specimen was positive for pandemic (H1N1) 2009 virus by PCR. The patient received oseltamivir, zanamivir,

and ventilator support. His chest radiograph showed diffuse alveolar infiltration. On day 10, his motor weakness worsened to grade 0, and his consciousness level was diminished to a drowsy state.

A computed tomography scan of the brain showed diffuse white matter lesions (Figure). Repeated lumbar punctures continued to show CSF findings within the reference range. An electrophysiologic study, electromyogram, and nerve conduction study showed polyneuropathy, axonopathy type. Guillain-Barré syndrome was suspected, and intravenous immunoglobulin was given for 5 days. Tests for GQ1b and GM1 antibodies were carried out at Oxford University; results were negative.

Other laboratory tests showed mild transaminitis and negative results for syphilis testing and for serologic tests for HIV, hepatitis B virus, hepatitis C virus, Japanese encephalitis virus, herpes simplex virus, and *Mycoplasma pneumoniae*. A CSF antigen test was negative, and CSF culture was negative for bacteria. Meropenem was given to treat ventilator-associated pneumonia, which was caused by β -lactam-resistant *Klebsiella pneumoniae*. After a month of treatment, the patient regained consciousness, his motor strength improved considerably, and he was able to be gradually removed from the ventilator. After 3 months, he was discharged with self-assisted status.

Our report shows neurologic manifestations associated with pandemic (H1N1) 2009 virus infection in an adult. The manifestation of progressive quadriplegia with diffuse sensory loss is compatible with a polyneuropathy. The neurologic signs developed 2 days after the respiratory tract signs.

Although a diagnosis of Guillain-Barré syndrome was considered initially, according to the National Institute of Neurologic Disorders and Stroke criteria (2), some clinical features did not support this diagnosis.

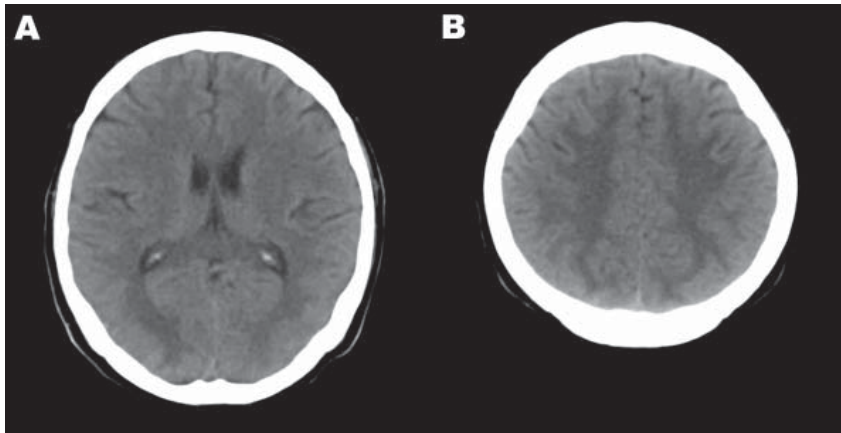


Figure. Computed tomography images of the brain of an adult patient with pandemic (H1N1) 2009 virus infection and neurologic signs. A noncontrast study showed hypodense lesions in both occipital lobes (A) and in both upper parietal lobes (B).

These included the lack of CSF albuminocytologic dissociation, the fact that the clinical signs occurred during the outbreak of pandemic (H1N1) 2009 virus infection rather than after it, and the fact that antibodies were not found in gangliosides. CSF albuminocytologic dissociation and serum ganglioside antibodies may be found in 85%–90% of Guillain-Barré syndrome patients (2).

Alternatively, the patient might have had central nervous system complication from pandemic (H1N1) 2009 virus infection. Acute disseminated encephalomyelitis is a condition that might occur within 30 days after an infectious process (3). It can lead to quadriplegia and diffuse white matter lesions. The clinical feature that makes acute disseminated encephalomyelitis less likely in this patient was the CSF findings in the reference range. In summary, however, we believe that pandemic (H1N1) 2009 virus infection can cause neurologic complications affecting both the peripheral and central nervous systems in adult patients.

This work was supported by the Office of the Higher Education Commission and Khon Kaen University, Thailand.

**Sarawut Kitcharoen,
Moragot Pattapongsin,
Kittisak Sawanyawisuth,
Vincent Angela,
and Somsak Tiamkao**

Authors affiliations: Khon Kaen University, Khon Kaen, Thailand (S. Kitcharoen, K. Sawanyawisuth, S. Tiamkao); Chaiyaphum Hospital, Chaiyaphum, Thailand (M. Pattapongsin); and University of Oxford, Oxford, UK (V. Angela)

DOI: 10.3201/eid1603.091699

References

- Centers for Disease Control and Prevention. Neurologic complications associated with novel influenza A (H1N1) virus infection in children—Dallas, Texas, May 2009. *MMWR Morb Mortal Wkly Rep.* 2009;58:773–8.
- National Institute of Neurological and Communicative Disorders and Stroke ad hoc Committee. Criteria for diagnosis of Guillain-Barré syndrome. *Ann Neurol.* 1978;3:565–6. DOI: 10.1002/ana.410030628
- Sonneville R, Klein I, de Broucker T, Wolff M. Post-infectious encephalitis in adults: diagnosis and management. *J Infect.* 2009;58:321–8. DOI: 10.1016/j.jinf.2009.02.011

Address for correspondence: Somsak Tiamkao, Department of Medicine, Faculty of Medicine, Khon Kaen University, 123 Mitraparp Rd, Khon Kaen, 40002, Thailand; email: somtia@kku.ac.th

Rickettsia felis,
West Indies

To the Editor: A spay–neuter (sterilization) program for feral cats from Basseterre, the capital of the Caribbean Island St. Kitts, found that most (45/58; 66%) cats had antibodies to spotted fever group rickettsiae (SFGR). The antibodies were detected with *Rickettsia rickettsii* antigen in a standard microimmunofluorescence assay (1). Titers for 13 (20%) cats were ≥ 320 .

Most SFGR are transmitted by ticks, but because of their grooming habits, cats seldom have many ticks (2), and we did not find any ticks on the cats we saw through the program. We did, however, commonly find cat fleas, *Ctenocephalides felis*, which are the main vector of *R. felis*, a recently described member of the SFGR. *R. felis* seems to be apathogenic in cats (3) but is the agent of flea-borne spotted fever in humans (4). Although *R. felis* has been reported from North and South America, Europe, Africa, the Middle-East, and Oceania (4), its presence in the Caribbean islands has not been established. To provide this information we tested DNA extracted with the QIAamp DNA Mini-Kit (QIAGEN, Valencia, CA, USA) from *C. felis* fleas preserved in 70% ethanol.

Of 57 (19%) *C. felis* fleas from St. Kitts, 11 were positive for *R. felis* DNA when tested by PCR using primers targeting SFGR *ompA* (5) or Taq-Man assay using primers targeting *gltA* and a probe specific for the organism (6,7). For a negative control we used distilled water; for a positive control we used DNA from *R. montanensis* cultures or recombinant control plasmids constructed by amplifying target fragments from *R. typhi* strain Wilmington and *R. felis* strain LSU (7). The sequences of the *ompA* and *gltA* amplicons obtained had 100% nucleotide sequence similarity with homologous fragments of the type reference isolate *R. felis* URRxCal2. We used the Na-