



## Case Report

## Unilateral abdominal clonic jerking as an epileptic phenomenon

Adam Patterson\*, Stephanie Woodroffe, R. Mark Sadler

Division of Neurology, Department of Medicine, Dalhousie University, 1796 Summer Street, Halifax, Nova Scotia B3H 3A, Canada



## ARTICLE INFO

## Article history:

Received 11 May 2021

Revised 29 August 2021

Accepted 31 August 2021

Available online 8 September 2021

## ABSTRACT

Unilateral abdominal wall clonic seizures are a rare manifestation of epilepsy. We report three cases of focal aware seizures manifesting as unilateral abdominal clonic motor movements. Standard EEG for patients with focal motor abdominal seizures is often unrevealing, which can make the diagnosis difficult. We report the first case of intracranial EEG in the diagnosis of a patients with this type of semiology during a focal seizure. In the absence of an electroclinical seizure verified by video-EEG monitoring, caution should be made with the diagnosis. A careful history should be obtained to help differentiate between unilateral abdominal clonic jerking and other abdominal complaints.

© 2021 The Author(s). Published by Elsevier Inc. This is an open access article under the CC BY-NC-ND license (<http://creativecommons.org/licenses/by-nc-nd/4.0/>).

## Introduction

Seizures presenting as unilateral abdominal wall clonic jerking have been reported infrequently in the literature. There are 20 cases published in the English literature, the majority of which were an expression of *epilepsia partialis continua* [1–15] (See Table 1).

The cortical representation of the abdominal wall and trunk is small compared to the face, hand, and limbs; This was initially demonstrated in Penfield's and Rasmussen's electrostimulation studies [16] (See Fig. 1 for a representation of the motor homunculus). Further evidence supporting that the abdominal area of the homunculus is smaller compared to other areas is provided by a recent intraoperative study that stimulated 608 sites in the precentral gyrus in 100 patients and did not identify the abdominal area of the homunculus [17] [February 2021 E-mail from author FE Roux; unreferenced]. The small size of the abdominal area of the homunculus has been hypothesized to be a reason for the rarity of this type of seizure [1].

Seizures involving abdominal symptoms can be difficult to diagnose, and a recent article published highlighted these diagnostic challenges [15]. Patients with subjective non-motor abdominal complaints have been diagnosed with "abdominal epilepsy" based solely on EEG abnormalities or response to anti-seizure medication, which has the potential of misdiagnosis. That publication recommends abandoning the use of the term "abdominal epilepsy" and instead using terminology recommended by the International League Against Epilepsy. Further adding to diagnostic difficulties, patients with seizures consisting of unilateral abdominal clonic

jerking often do not have epileptiform abnormalities on ictal or interictal EEG, likely because of the limited cortical representation described above. Of the 20 prior cases of seizures with abdominal wall clonic jerking in the English literature, only 11 of 15 with ictal EEG results published had ictal rhythms and 5 of 10 with interictal EEG results published had spikes or sharp waves. Notably, high-density EEG has been used to help detection of epileptiform abnormalities in these patients and these authors recommend video-EEG with ictal recording for diagnosis [15].

We report three additional cases of focal aware motor seizures with abdominal clonic jerking from our institution, including the first known case with intracranial electroencephalographic (EEG) recording. These cases highlight the diagnostic process and challenges with this type of seizure.

## Case 1

The patient was a 41-year-old right-handed female when she was admitted to the epilepsy monitoring unit (EMU). Epilepsy onset was at 12 years of age when she presented with three bilateral tonic-clonic seizures within 24 hours. This acute presentation was immediately followed by focal motor status epilepticus with seizures involving predominantly her abdomen, proximal left arm, and neck. She was admitted to hospital for three weeks and the status epilepticus was successfully treated with phenytoin, phenobarbital, and carbamazepine. She continued to have seizures into adulthood despite changes in her antiseizure medication with all seizures occurring in sleep at a frequency of 4 per month.

She had no risk factors for epilepsy and had a normal physical examination.

The patient's habitual seizures were captured during her EMU admission and consisted of clonic jerks of the left lower abdominal wall (below the costal margin, above the iliac crest) for thirty sec-

\* Corresponding author.

E-mail address: [ad322554@dal.ca](mailto:ad322554@dal.ca) (A. Patterson).

**Table 1**  
Review of prior cases of abdominal motor seizures in the English literature.

Reference (Year + First author)	Age and Sex	Seizure Type	Seizure Description	Neuroimaging Lesion Location	Ictal EEG	Interictal EEG	Etiology
Matsuo 1984	19-year-old-female	Focal Motor	Right abdominal wall spasms spreading occasionally to right thigh and rarely to right arm	Left parietal	–	“Slow waves over the left posterior quadrant. . .reactive to eye opening and closure.” No epileptiform activity	Aspergilloma
Matsuo 1984	66-year-old-female	Focal Motor	Left lower quadrant abdominal spasms with post-ictal hemiparesis	Right parietal	–	“Amplitude asymmetry of the alpha rhythm, right greater than left. . . in light sleep. . .low voltage slow waves, involving primarily the right hemisphere.” No epileptiform activity.	Meningioma
Matsuo 1984	42-year-old male	Focal Motor	Right abdominal wall contractions at times spreading to right shoulder and face	–	No epileptiform discharges but “postictally low voltage focal slow waves. . .over the left parietal area”	–	Unknown
Rosenbaum 1990	65-year-old-male	Focal Motor Status Epilepticus	Initially left hemiparesis followed by clonic left-sided abdominal jerking; recurrent seizures also involved left sided limbs and left face	Right frontoparietal	“Continuous quasiperiodic bursts of high-voltage delta- and sharp-wave complexes of 1.5 to 2.5 seconds originating from the right centroparietal area”	–	Brain Metastases
Chalk 1991	66-year-old male	Focal Motor Status Epilepticus	Short episodes of brief and rhythmic contractions of the left abdominal muscles occurring at 2 to 3 Hz	Right parasagittal	“Right parasagittal periodic sharp wave discharges”	–	Cryptococcal Meningitis
Lim 2004	31-year-old male	Focal Motor Status Epilepticus	Myoclonic jerking of the left proximal lower limb and abdomen occurring at approximately 1 Hz	Right cingulate	“Ictal focus over the right anterior temporal region”	–	Developmental venous abnormality
Fernandez-Torre 2004	77-year-old-female	Focal Motor Status Epilepticus	Bilateral clonic jerking of the abdominal muscles (more intense on the left) occurring almost rhythmically at a rate of 0.5 Hz. Associated with left hemiparesis, hemianesthesia, hemiasomatognosia, right sided gaze deviation and dysphagia	Right frontal, temporal pole, left parasagittal frontal	Periodic lateralized epileptiform discharges (PLEDs) in the right central, mid-temporal, and parietal areas and with occasional spread to the left parieto-occipital region.	–	Brain Metastasis
Dafotakis 2006	62-year-old-male	Focal Motor Status Epilepticus	Clonic twitching of the left sided abdominal muscles	Right precentral gyrus	–	–	Unknown
Tezer 2008	25-year-old male	Focal Motor Status Epilepticus	Myoclonic twitching of the right sided abdominal muscles with a frequency of approximately 1–2 Hz.	Left parieto-occipital	–	Periodic lateralized epileptiform discharges involving the left frontocentral and parietal areas	Focal Cortical Dysplasia
Oster 2011	59-year-old-male	Focal Motor	Clonic contractions of the right abdomen and torso with subsequent right arm and leg clonic contractions. Occasional spread to bilateral tonic-clonic	Left Precentral Gyrus	“Obscured by muscle and movement artifacts “	–	Unknown
Ribeiro2015	69-year-old-male	Focal Motor Status Epilepticus	Myoclonic jerks of the right abdominal wall. Associated with right hemiparesis and dysphagia	Left frontal	Periodic lateralized epileptiform discharges (PLEDs) maximum at the left occipital region and evolving into rhythmic fast activity in the same area	Sporadic left temporo-parieto-occipital spikes	Vascular
Ribeiro2015	75-year-old-male	Focal Motor Status Epilepticus	Arrhythmic myoclonic twitches of the left abdominal muscles. Associated with left hemiparesis, and left gaze deviation	Right occipital	“Slight asymmetry of the posterior background activity, with slower activity on the right side and some spikes over the right occipital area”	–	Vascular
Brigo 2018	91-year-old male	Focal Motor Status Epilepticus	Continuous rhythmic jerking of the right sided abdominal muscles	Left temporal	Rhythmic epileptiform discharges and polyspikes in the left hemisphere	–	Acute Infarction

Table 1 (continued)

Reference (Year + First author)	Age and Sex	Seizure Type	Seizure Description	Neuroimaging Lesion Location	Ictal EEG	Interictal EEG	Etiology
Aljaafari 2018	26-year-old male	Focal motor	Clonic jerking of the right side of the abdomen. Preceded by a pulling sensation of the right neck and shoulder. With or without right arm clonic jerking and head deviation to the right. Occasional spread to bilateral tonic-clonic	Left parietal and peri-insular region	“Sequential sharp waves recorded over the left mid parietal area . . . evolving into a rhythmic theta and later alpha frequency ictal pattern recorded over the left centroparietal . . . region”	“Spike and wave or sharp and slow wave discharges, recorded maximally over the left mid parietal region”	Brain malformation (not specified)
Asranna 2019	25-year-old male	Focal Motor Status Epilepticus	Arrhythmic myoclonic movements of the right abdominal muscles	Left frontal	“No focal abnormalities”	“No focal abnormalities”	Neuro-cysticercosis
Lizarraga 2019	77-year-old-male	Focal motor	Semicontinuous, right-greater-than-left, clonic-like abdominal contractions lasting for 10 to 20 seconds	Left parietal	“3.5- to 4-Hz, rhythmic, and sharply contoured activity in the mesial parietal region and left posterior quadrant . . . propagating anteriorly to mesial central and left frontocentral regions	“Epileptiform activity in the mesial parietal and left parieto-occipital regions. . . propagating to mesial central and left frontocentral regions”	Intracerebral hemorrhage
Casciatto 2019	61-year-old-male	Focal Motor Status Epilepticus	Irregular contractions of the abdominal wall, predominantly on the left side	Right parietal	“Rhythmic epileptiform activity involving all contacts over the right hemisphere”	“Interictal brief bursts of slow waves over the right temporal region.”	Brain Surgery
Tatum 2020	48-year-old-female	Focal Motor	Bilateral clonic jerking of the abdomen with rare involvement of the thighs, right more than left	-	Rhythmic myogenic artifact followed by postictal slowing in the left temporal region	Normal	Unknown
Tatum 2020	67-year-old-male	Focal Motor	Paresthesias in right foot spreading to the right abdomen followed by abdominal twitching. Occasional sensory symptoms in right face and arm	Left parietal	Standard EEG: Normal High Density EEG:Focal subclinical seizures from the left central parietal region	Standard EEG: Unrevealing High Density EEG:Frequent spikes in the left central parietal lobe	Encephalomalacia from prior tumor resection
Tatum 2020	55-year-old-female	Focal Motor	Paresthesias in right toe followed by contractions in right leg spreading up to hip and abdomen, rarely spreading to back	Left paramedian frontoparietal lobe and left frontal lobe	“Continuous left-hemispheric slowing, maximal in the left parietal-occipital region”	One of seizures with an “electrographic correlate”	Two tumors treated with surgical resection (with minimal residual) and radiotherapy

onds followed by abduction movements of the left shoulder for one to two minutes. Postictally, she described left hemibody “numbness” lasting for 2 minutes. Based on a nursing language and behavior assessment during and after the seizure, it was determined her seizures had preserved awareness. Interictal EEG was normal. Ictal EEG was uninterpretable due to movement artifact with no post ictal focal slowing. MRI was normal.

Her antiseizure treatment was changed from valproic acid to levetiracetam and her seizure frequency reduced significantly to one every several years.

Case 2

The patient was a 32-year-old male when he was admitted for implantation of subdural electrodes at our center for presurgical evaluation of drug-resistant epilepsy. He had a history of drug-resistant epilepsy since the age of 24 years. His habitual seizures were focal aware consisting of left face sensory changes followed by left arm and leg tonic posturing lasting 10 – 15 seconds. Awareness during his seizures was established by a nursing language and behavior assessment during and after a seizure while admitted to the epilepsy monitoring unit previously. Seizure frequency was one to three per day.

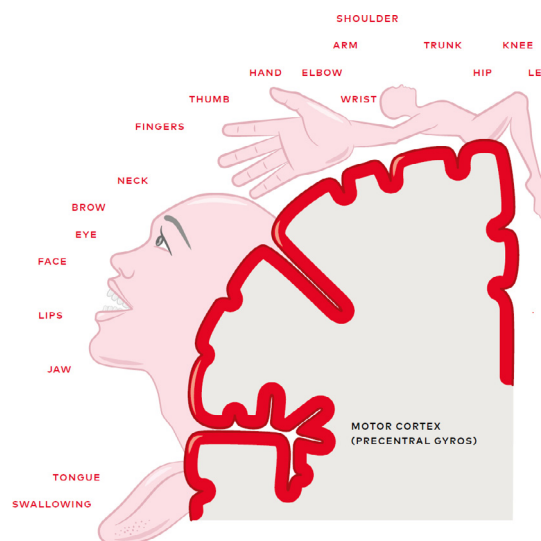
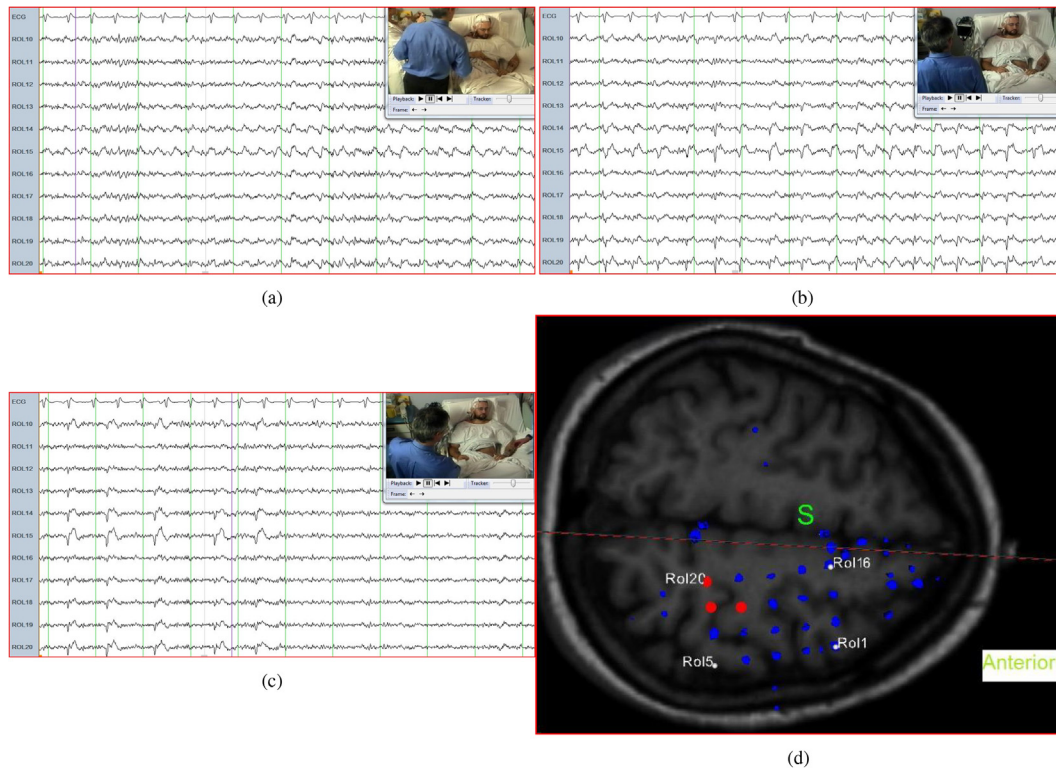
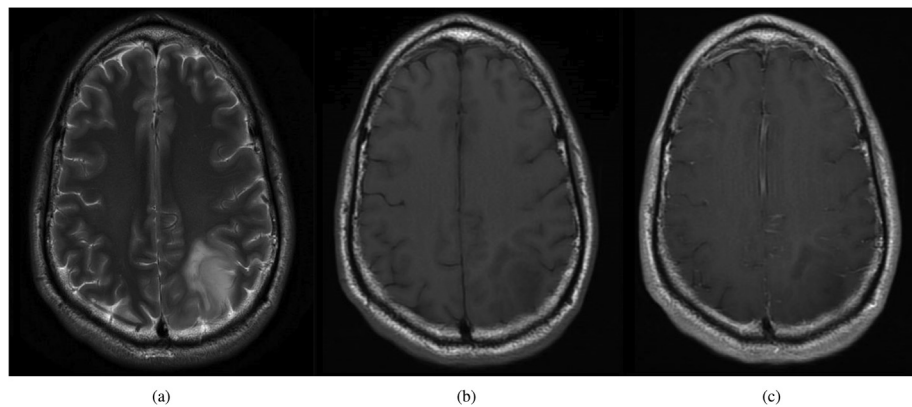


Fig. 1. The motor homunculus. Modified from Nicholas et al (2019), with the author’s permission.



**Fig. 2.** Case 2 a) Subdural EEG at onset of left abdominal wall seizure. Selected channels from 20 contact grid. Note new rhythm at contacts 20,15,14.(EEG channels: Sens = 20 microvolts/mm; LFF = 1; HLF = 100 Hz)b) Same seizure; 30 seconds after onset c) Same seizure; termination 80 sec after onset d) Axial MRI and position of subdural grid. Contacts 20, 15, 14 in red.



**Fig. 3.** Case 3 MRI Brain on initial presenting a) T2 Axial b) T1 Axial c) T1 Axial Post-Gadolinium Lesion in left parietal lobe abutting the left post-central gyrus. T2 Hyperintensity with T1 hypointensity is demonstrated with a lack of gadolinium enhancement, consistent with a low-grade glioma. The patient later underwent resection of this lesion and pathology disclosed a grade II oligodendroglioma.

He had no risk factors for epilepsy and his MRI brain was normal. Interictal scalp EEG demonstrated central (Cz, Fz) spikes. Ictal scalp EEG was contaminated by movement and muscle artifact and no clear ictal rhythms were identified.

Subdural EEG recording electrodes were implanted (a 4x5 contact grid over the right central region plus 6 additional right hemisphere 4–5 contact strip electrodes over the right mesial parietal, mesial frontal, and frontal convexity). On the first day following the subdural electrode implantation the patient developed an entirely new seizure type distinct from his habitual seizures: the new seizures were isolated left abdominal wall rhythmic contractions with a frequency of 2 Hz and a duration of 80 seconds. These

movements correlated with a very spatially restricted ictal intracranial EEG rhythm (see Fig. 2). These seizures did not evolve to his habitual seizure type and the new attacks ceased with the removal of the intracranial electrodes.

### Case 3

The patient was a 35-year-old right-handed male at the time of seizure onset. The frequency of events was initially every few months, but gradually increased in frequency to once every 1 – 2 weeks. Seizures were classified as focal aware. Awareness during the seizure was determined by the clinical history. Seizures

consisted of a distortion of sensory perception and motor control of the right arm and involuntary contractions of the right side of his abdomen lasting 15–20 seconds.

He did not have any known seizure risk factors. Neurological examination was normal. MRI demonstrated a left parietal lesion consistent with a low-grade glioma (see Fig. 3). He underwent partial resection of the tumor, with some residual adjacent to the motor cortex. The tumor pathology disclosed a WHO grade II oligodendroglioma.

The patient continued to have sporadic focal seizures after the resection, though these decreased in frequency to once every several weeks on a combination of levetiracetam and lamotrigine. Interictal EEG done after his resection demonstrated left central slowing and breach rhythm, but no epileptiform discharges. He did not have video-EEG monitoring.

## Discussion

We provide confirmatory evidence of abdominal clonic jerking as an epileptic phenomenon by video-EEG monitoring in two cases and detail localization in one case with intracranial EEG.

Case 1 highlights the importance of video-EEG in the diagnosis of seizures with abdominal clonic jerking. In this case her interictal and ictal EEG were unrevealing, and her neuroimaging was normal, but her semiology witnessed on video (unilateral clonic jerking of the abdomen following by abduction of the shoulder) was definitively epileptic. Case 1 also demonstrated the somatotopic organization of the motor cortex. Penfield found the trunk and abdomen area in the precentral gyrus medial to the shoulder region and lateral to the hip region. The proximity of the abdominal representation to the shoulder is demonstrated by our Case 1, with the patient's seizures consisting of left abdomen clonic jerking followed by abduction of the shoulder.

Case 2 is in particular notable as there have been no previous case reports of clonic abdominal seizures with simultaneous intracranial recording. Nonhabitual seizure types caused by implanted subdural electrodes, as occurred in this case, is a known phenomenon [18]. Though in this case nonhabitual seizures were captured, this demonstrates the ability of intracranial EEG to identify the epileptogenic zone in seizures with unilateral abdominal clonic jerking with high precision.

Of note, case 3 has not had video-EEG or ictal recording on EEG. In this case, we do not have the same degree of confidence as case 1 or case 2 proven by video-EEG monitoring. Our diagnostic confidence is high, however, based on the clear history of unilateral abdominal motor involvement (as opposed to subjective or bilateral complaints) and etiology with a structural lesion in the contralateral hemisphere. Depending on the clinician's practice setting and location, it may not be possible to obtain video-EEG monitoring on a timely basis. Epilepsy is a clinical diagnosis, and in cases like this, we think it is reasonable to make the diagnosis based on a careful history including distinguishing between subjective abdominal complaints and unilateral motor phenomenon. Video-EEG monitoring could then be pursued in the future if drug-resistant epilepsy were to develop. We agree with Tatum et al., it is important to use appropriate ILAE terminology in these cases, namely "focal aware motor seizures with clonic jerking" as opposed to "abdominal epilepsy". In case 2 the seizure was first detected in contacts next to the precentral and postcentral gyrus that correspond to the abdominal area of the homunculus. In case 3 the lesion is located in the left parietal lobe, with the lesion extending into the left abdominal sensory area of the postcentral gyrus. The semiology from case 3 contrasts with case 1, in case 3 the seizure evolving from a sensory distortion of the arm to clonic abdominal jerking, in contrast to case 1 with abdom-

inal clonic jerking evolving to abduction movements of the shoulder. This contrast highlights the variable ways seizure spread among the sensorimotor cortex can manifest. Our cases are consistent with most reports of seizures with abdominal clonic jerking in that they report the seizure onset zone, based on MRI or EEG, in the parietal or frontal lobe. There are some exceptions, including seizures with lesions or the most prominent epileptiform abnormality reported in occipital [6], parieto-occipital [11], temporo-parietal-occipital [1], and cingulate [14] lobes. In these cases, we suspect the symptomatogenic zone was likely in the abdominal motor area of the homunculus with spread to this area of seizure activity from the epileptogenic lesion.

## Conclusion

Focal aware seizures with clonic jerking of the abdomen as the main manifestation have been infrequently reported. The intracranial EEG recording and lesional location on neuroimaging in our cases adds to prior reports asserting that the symptomatogenic zone for these seizures is the abdominal area of the motor homunculus. The diagnosis can be difficult to make, as scalp EEG is often normal. Intracranial EEG is effective for diagnosis of seizures with abdominal clonic jerking. Ideally the diagnosis should be established by ictal video-EEG, though we argue a clear history of unilateral motor contractions of the abdomen can be used to make a clinical diagnosis.

## Declaration of Competing Interest

The authors declare that they have no known competing financial interests or personal relationships that could have appeared to influence the work reported in this paper.

## References

- [1] Brigo F, Bratti A, Tavernelli V, Nardone R. Epilepsia partialis continua of the abdominal musculature caused by acute ischemic stroke. *Can J Neurol Sci.* 2018;45(6):703–6.
- [2] Aljaafari D, Nascimento F, Abraham A, Andrade D, Wennberg R. Unilateral abdominal clonic seizures of parietal lobe origin: EEG findings. *Epileptic Disord.* 2018;20(2):158–63.
- [3] Asranna A, Sureshbabu S, Mittal G, Peter S, Chindripu S, Saini L. Abdominal epilepsy partialis continua in neurocysticercosis. *Epileptic Disord* 2019;21(3):302–6.
- [4] Chalk C, McManis P, Cascino G. Cryptococcal meningitis manifesting as epilepsy partialis continua of the abdomen. *Mayo Clin Proc.* 1991;66(9):926–9.
- [5] Fernández-Torre JL, Calleja J, Pascual J, Galdós P, De Pablos C, Berciano J. Epilepsia partialis continua of the abdominal muscles: a detailed electrophysiological study of a case. *Mov Disord.* 2004;19(11):1375–8.
- [6] Ribeiro J, Sousa M, Teotónio R, Bento C, Sales F. Epilepsia partialis continua of the abdominal muscles due to cerebrovascular disease. *Epileptic Disord* 2015;17(1):72–6.
- [7] Dafotakis M, Sparing R, Becker S, Fink G. Epilepsia partialis continua of the abdominal muscles with transient MRI abnormalities. *Neurology* 2006;66(7):1099.
- [8] Lizarraga KJ, Serrano EA, Tornos L, Kanner AM, Lang AE. Isolated abdominal motor seizures of mesial parietal origin: epileptic belly dancing? *Mov Disord Clin Pract* 2019;6(5):396–9.
- [9] Casciato S, Mascia A, D'Aniello A, Qurato P, Grammaldo L, Scopetta C, et al. A case of epilepsy partialis continua of abdominal muscles after brain tumor surgery. *Eur Rev Med Pharmacol Sci* 2019;23(7):3001–4.
- [10] Rosenbaum DH, Rowan AJ. Unilateral truncal seizures: frontal origin. *Epilepsia* 1990;31(1):37–40.
- [11] Tezer FI, Celebi O, Ozgen B, Saygi S. P041 A patient with two episodes of epilepsy partialis continua of the abdominal muscles caused by cortical dysplasia. *Clin Neurophysiol* 2008;119:S81. [https://doi.org/10.1016/S1388-2457\(08\)60312-0](https://doi.org/10.1016/S1388-2457(08)60312-0).
- [12] Matsuo F. Partial epileptic seizures beginning in the truncal muscles. *Acta Neurol Scand* 1984;69(5):264–9.
- [13] Oster JM, Aljumairi F, Cosgrove GR. Metabolic imaging correlate of truncal onset seizures. *Arch Neurol* 2011;68(2). <https://doi.org/10.1001/archneurol.2010.370>.
- [14] Lim ECH, Tan JH, Ong BKC, Wilder-Smith EPV. Generalised myoclonus evolving into epilepsy partialis continua due to a cingulate gyrus lesion:



- case report and review of the literature. *Parkinsonism Relat Disord* 2004;10(7):447–9.
- [15] Tatum K, Schuele S, Templer J, Becker T, Tatum W. True abdominal epilepsy is clonic jerking of the abdominal musculature. *Epileptic Disord* 2020;22(5):582–91.
- [16] Nicholas J, Johannessen A, Van Nunen T. Tactile working memory scale a professional manual. Nordic Welfare Centre 2019.
- [17] Roux F-E, Niare M, Charni S, Giussani C, Durand J-B. Functional architecture of the motor homunculus detected by electrostimulation. *J Physiol* 2020;598(23):5487–504.
- [18] Fountas K, King D, Jenkins P, Smith J. Nonhabitual seizures in patients with implanted subdural electrodes. *Stereotact Funct Neurosurg* 2004;82(4):165–8.