

ORIGINAL PAPER



Idiopathic tenosynovitis with rice bodies

MIHAELA PERȚEA¹⁾, BOGDAN VELICEASA²⁾, NATALIA VELENCIUC³⁾, CRISTINA TERINTE⁴⁾, MIHAELA MITREA⁵⁾, PETRU CIOBANU¹⁾, OVIDIU ALEXA²⁾, SORINEL LUNCĂ³⁾

¹⁾Department of Plastic Surgery and Reconstructive Microsurgery, Grigore T. Popa University of Medicine and Pharmacy, Iași, Romania

²⁾Department of Orthopedics and Traumatology, Grigore T. Popa University of Medicine and Pharmacy, Iași, Romania

³⁾Department of Surgery, Grigore T. Popa University of Medicine and Pharmacy, Iași, Romania

⁴⁾Department of Pathology, Regional Institute of Oncology, Iași, Romania

⁵⁾Department of Morphofunctional Sciences I, Grigore T. Popa University of Medicine and Pharmacy, Iași, Romania

Abstract

Purpose: Idiopathic tenosynovitis with rice bodies is a rare disease and its non-association with rheumatic diseases, tuberculosis infection or trauma is reported only in few cases in literature. **Patients, Materials and Methods:** Our study presents a series of five patients diagnosed with tenosynovitis with rice bodies at the flexor tendons of the upper limb. Medical history revealed no associated disease or trauma. Disease duration ranged between two months and four years, two patients presenting symptoms of acute carpal tunnel and three patients tumor mass. In one case, the tumor measured 210 mm in length and a tendon rupture was suspected. Laboratory and imaging investigations could not establish a specific associated pathology and a preoperative diagnosis. Surgical treatment consisting of synovectomy was performed in all patients. **Results:** In all five cases, intraoperative appearance could easily determine the presence of rice bodies. Histopathological examination revealed typical aspect for rice bodies and make the diagnosis possible without the need for other more laborious processing (immunohistochemistry). The amount of rice bodies was directly proportional to disease duration. In all cases, the recovery was complete. After a median 30.4-month follow-up, no recurrence was detected. Subsequently performed laboratory investigations and specific tests did not reveal tuberculosis infection, rheumatic disease, or other diseases. **Conclusions:** This is the largest series of patients with idiopathic tenosynovitis with rice bodies and the bigger tumor mass reported to date. Synovectomy with removal of all rice bodies represents the optimal treatment. A longer disease course may be associated with a larger number of rice bodies, which may be associated with tendon rupture. The etiopathogenesis remains unclear, further studies being necessary to establish it.

Keywords: tenosynovitis, rice bodies, idiopathic, synovectomy.

Introduction

Tumor masses resembling shiny rice grains, “rice bodies” were first described in the joints by Reise in 1895 and were associated with tuberculosis [1, 2]. Later on, the rice bodies were commonly reported in rheumatoid arthritis, erythematous lupus, seronegative arthritis, or tuberculous tenosynovitis, being generally located at the level of the bursae and the joints, the tendons being rarely affected [3, 4]. Their presence is reported in 72% of adult rheumatoid joints upon synovial lavage and in up to 50% of cases with tuberculous tenosynovitis. Rice bodies unrelated to these diseases (idiopathic tenosynovitis) were detected in few cases reported in the literature [2, 4]. Rice bodies were considered the result of a nonspecific articular inflammatory response. However, pathogenesis of rice body formation remains uncertain [3]. In cases of idiopathic tenosynovitis, some authors attribute the formations of “rice bodies” to synovial microinfarctizations [1]. Other authors suggest that “rice bodies” form in the synovial fluid without having any connection with the synovial component, their growth is generated by fibrin aggregation [5]. Histopathological examination of the resection specimens revealed in the examined fragments dense inflammatory infiltrate containing T-lymphocytes, plasma cells, macrophages, appearance

of proliferative synovitis with synovial cell hyperplasia and hypertrophy, and lymphoplasmacytic infiltrate [5, 6].

Aim

Our study was conducted on a group of five patients in wherein the presence of rice bodies in the flexor tendon sheaths of hands and forearms was confirmed intraoperatively. No associated condition in which the presence of rice bodies is usually described, such as chronic rheumatic inflammatory disease or tuberculous infection have been detected for the cases in our study group.

Patients, Materials and Methods

Our study involved a series of five patients with the diagnosis of tenosynovitis with rice bodies of unknown etiology treated in our institution between May 2011 and January 2018.

The study group included three men and two women aged between 35 and 70 years (average 54.6 years). After informed consent from all patients on admission, none of the patients has had a history of trauma or diseases known to be associated with the presence of rice bodies like tuberculosis or rheumatic diseases. At admission, a series of tests were performed routinely on all patients including

blood tests, such as complete blood count and biochemical tests, and imaging comprising radiographs of the chest. Forearm, wrist and hand radiography and ultrasonography was also performed upon all patients. Magnetic resonance imaging (MRI) was performed in three of five cases. Extensive medical history was recorded, two patients presenting arterial hypertension and were on specific medication.

All patients underwent surgery under loco-regional anesthesia. Surgery consisted in the complete excision of the tumors' masses and the removal of all "rice bodies". Histopathological examination was performed for the excised structures.

The excised tissues were fixed, in all cases, in 10% formalin. Its processing was performed with the Leica ASP300S fully enclosed tissue processor. The inclusion was performed with Leica EG1150H heated paraffin embedding module. Leica RM2235 microtome was used for sectioning at 4 μ m.

The assessment of etiology involved microbial and fungal cultures, Ziehl-Neelsen and Periodic Acid-Schiff (PAS) stainings for all patients.

In neither case did the two explorations have positive results, so that the etiology of tenosynovitis could not be specified histopathologically. Pathological findings were evaluated, and a closed follow-up was performed.

Three months after surgery, the laboratory tests for rheumatic and autoimmune diseases or tuberculosis infection were resumed and completed.

Results

In all cases, only flexor tendon synovitis was present and in four cases, tenosynovitis was localized in the left thoracic limb. Average time between symptom onset and

hospital admission was 1.5 years (ranged two months to four years). In two out of five cases, clinical symptoms were pain, paresthesia within fingers and hand, symptoms characteristic of carpal tunnel syndrome (Cases No. 1 and No. 2). Clinically, there was no evidence of any swelling mass at wrist level. In these two cases, the history was short, of two and four months, respectively (Table 1).

In the remaining three cases, the patients were asymptomatic, with a history of a one to four years course of a painless swelling mass: at the palmar flexion crest centered on ring finger, 20/20 mm in size (Case No. 3) (Figure 1A); at the forearm and wrist level, 50/30 mm in size (Case No. 4). In the case with the longest history (four years), the swelling mass was located on the forearm, wrist and palm and measured 210/50 mm (Case No. 5) (Figure 1B). For Case No. 5, impossibility of the fifth finger, flexion was noticed and suspicion of spontaneous fifth finger flexors rupture was raised. In this last case, considering the tumor size, the thumb-finger pinch was difficult but painless. In all these three cases, the detected swelling mass was relatively soft on palpation, painless, immobile on deep planes.

Patients' personal history, hematological, biochemical, and inflammatory tests, assessments for rheumatic diseases, tuberculin intradermal reaction, and chest X-ray were within normal ranges, none of the diseases known to be associated with the presence of rice bodies nor a history of trauma being found. X-ray examination did not reveal osteo-articular causes in the two cases with symptoms of carpal tunnel syndrome and the ultrasonography showed thickening of tendon sheaths in the carpal tunnel with the median nerve diminished in size at this level. In the other three cases, simple X-ray described a pseudotumoral mass not invading the osteoarticular system, located in the soft tissue.

Table 1 – Baseline characteristics of the patients

	Case No. 1	Case No. 2	Case No. 3	Case No. 4	Case No. 5
Age [years]	65	70	35	56	47
Gender	F	F	M	M	M
Course	2 months	4 months	1 year	2 years	4 years
Symptoms	pain, edema, paresthesias	pain, edema, paresthesias	edema	edema	edema
Swelling mass location	right wrist	left wrist	right hand	forearm + right wrist	forearm + wrist + right hand
Lesion size [mm]	no mass	no mass	20/20	50/30	210/50
Associated lesions	carpal tunnel syndrome	carpal tunnel syndrome	–	–	spontaneous rupture of the 5 th flexor tendons
Immunological manifestations (RF, ESR, CRP)	negative	negative	negative	negative	negative
MRI	–	–	+	+	+
AFB staining/culture	negative	negative	negative	negative	negative
Recurrence	no	no	no	no	no

AFB: Acid-fast bacilli; CRP: C-reactive protein; ESR: Erythrocyte sedimentation rate; F: Female; M: Male; MRI: Magnetic resonance imaging; RF: Rheumatoid factor.

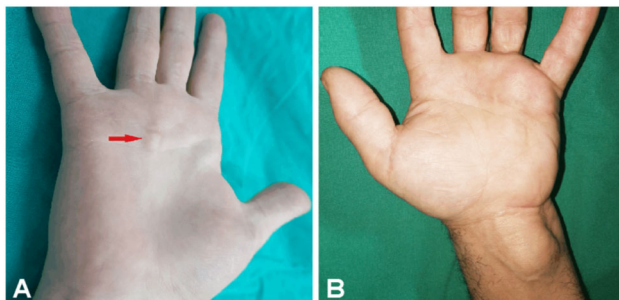


Figure 1 – Clinical appearance: (A) Case No. 3 – palm swelling mass of 20×20 mm; (B) Case No. 5 – large swelling mass extending from distal forearm to palm region measuring 210 mm in length.

Ultrasound exam showed well-defined masses that included the flexor tendons, with mixed (liquid and solid material) content, without providing further information. MRI scan was performed in the three asymptomatic patients who have been found with a swelling mass (the other two cases being treated as acute carpal tunnel syndrome). For the patient with largest lesion, MRI scan revealed a heterogeneous mass with hyposignal on T2-weighted sequence (Figure 2A) and iso and hypersignal on T1-weighted sequence relative to the muscle groups (Figure 2B). Countless tiny areas with hyposignal on T2-weighted sequence were described around the flexor tendons, with no tendency to confluence. The mass had a well-circumscribed contour and was well-defined, lobular, multiloculated, with parietal contrast uptake, located at midpalmar level, around the

superficial and deep flexor tendons, without modifying their signal, extending under the flexor *retinaculum* at the distal forearm extremity. It had a total length of 210 mm (craniocaudal diameter), approximately 21 mm transverse diameter at the level of the radiocarpal joint and about 52 mm at the level of the palm. The joint spaces were normal, without effusions. The same MRI appearance was described in the two other asymptomatic cases, but without the presence of tiny areas, the sizes of swelling masses being consistent with those described clinically. No hemosiderin deposits were detected in any of the examined cases. Our preoperative diagnosis deemed to villonodular synovitis in Cases No. 3 and No. 4, for Case No. 5 a tenosynovitis with rice body being considered (Figure 2, C and D).

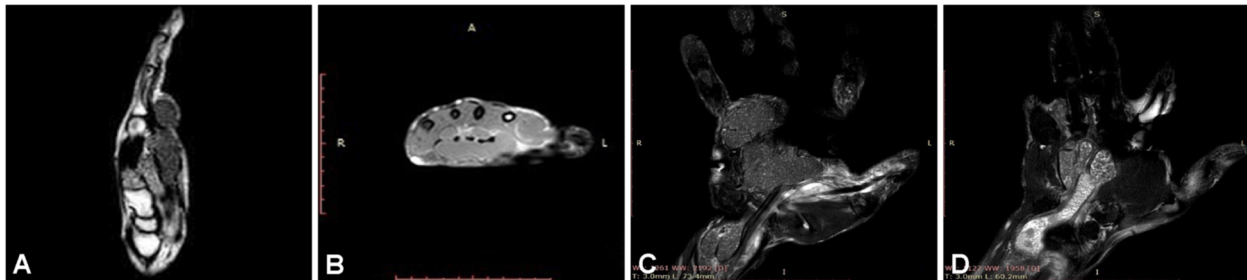


Figure 2 – MRI aspect of Case No. 5: (A) heterogeneous mass with hyposignal on T2-weighted sequence; (B) T1-weighted sequence showing a mass with low signal intensity surrounding the flexor tendons; (C and D) Lobular, multiloculated, well-circumscribed mass with parietal contrast uptake harboring countless tiny areas with hyposignal on T2-weighted sequence around the flexor tendons, located at midpalmar level, around the superficial and deep flexor tendons, without modifying their signal, extending under the flexor *retinaculum* at the distal forearm extremity with a total length of 210 mm. MRI: Magnetic resonance imaging.

Intraoperatively, synovial sheaths showed thickening and pseudotumoral appearance, their content consisting of a large number of small-size masses in the form of shiny white rice grain-like soft tissue nodules under some pressure inside it (Figure 3, A and B). The number of rice bodies was directly proportional to the size of swelling mass and disease duration. In the case, five the rupture of the fifth finger superficial and profound flexor tendons and fourth superficial flexor tendon was confirmed intraoperatively (Figure 3, B and C). Synovectomy was performed

throughout the length of the flexor tendons (depending on involvement) with the removal of all rice bodies (Figure 3D). The opening of the carpal anterior annular ligament was required in the two symptomatic cases, as well in other two cases in which the swelling masses extended to the wrist (Cases No. 4 and No. 5). In three of the five cases (where dissection involved a larger territory – Cases No. 3, No. 4, and No. 5), the postoperative drainage was maintained for a four-day interval.

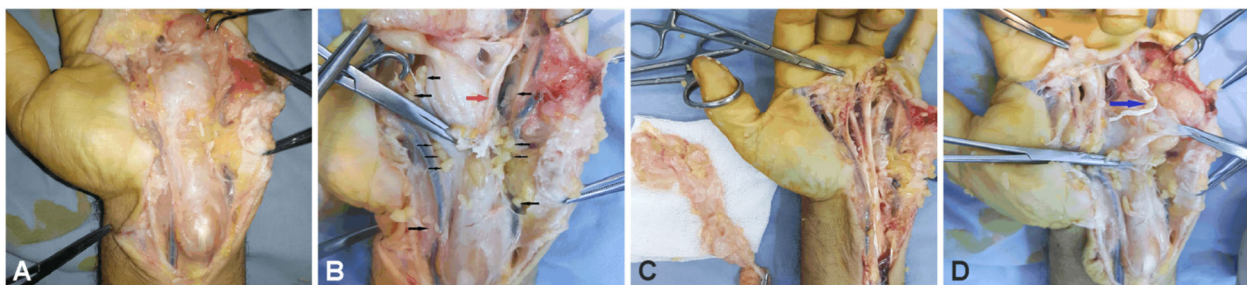


Figure 3 – (A) Distended and under tension synovial sac; (B) Multiple rice bodies all over the surgical field (black arrows) and ruptured superficial fifth finger flexor tendons (red arrow); (C) Fourth superficial tendon rupture (blue arrow), multiple rice bodied – also note the fifth finger position in extension; (d) Synovial sac is completely excised.

Histopathology examination of the resection specimens revealed in the examined fragments dense inflammatory infiltrate containing T-lymphocytes, plasma cells, macrophages, appearance of proliferative synovitis with synovial cell hyperplasia and hypertrophy, and lymphoplasmacytic infiltrate. In addition, we found blood vessel hyperplasia, epithelioid granulomas with multinucleated giant cells, some

of them Langhans cell-like, fibrin organized in the form of rice bodies with amorphous acidophilic core surrounded by a thin fibrous layer (Figure 4, A and B; Figure 5, A–D).

In all of the studied cases, microbial cultures were negative. Also, the Ziehl–Neelsen and PAS stainings did not reveal the presence of Koch bacilli or microbial or fungal colonies (Figure 6, A and B).

Postoperative course was uneventful in all cases, with complete resolution of all signs and symptoms present preoperatively at four months. In the Case No. 5 that was associated with spontaneous flexors tendons rupture, surgical reintervention three months after the first surgery was performed for tendon reconstruction. The postoperative anti-inflammatory therapy was stopped on day three and antibiotics were administrated as prophylaxis to all patients for no more than 24 hours. At one patient (Case No. 4), due to a persistent leukocytosis, the antibiotic therapy

was maintained for five days. All five patients benefited from kinesiotherapy rehabilitation. Functional reintegration of the hand was complete in all cases and patients were fully satisfied.

In all cases, three months after surgery, the laboratory tests for rheumatic and autoimmune diseases or tuberculosis infection were resumed and completed, the tests being also negative. The median follow-up was 30.4 months (range 12–56 months) and no recurrence was present.

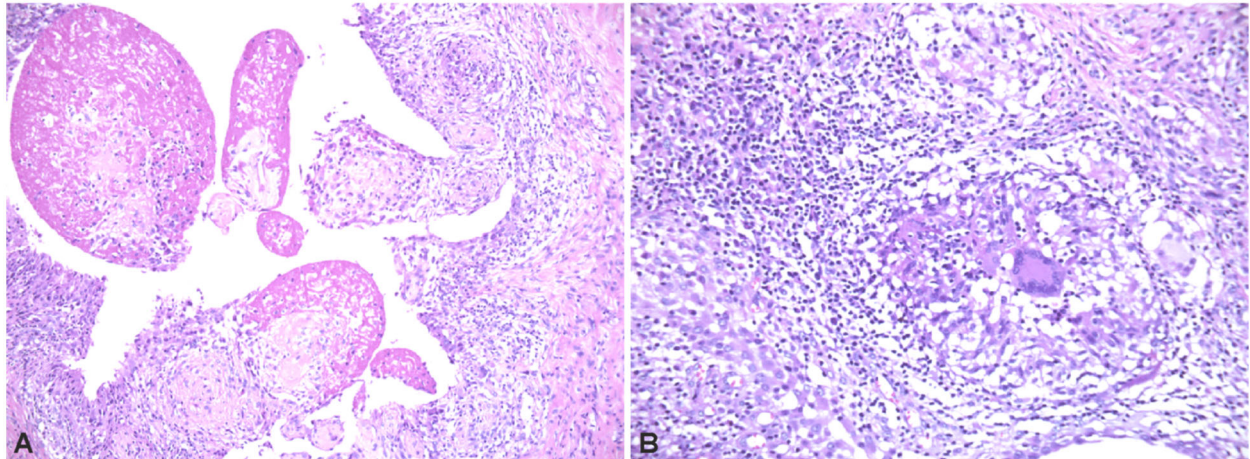


Figure 4 – (A) Body rice bodies (amorphous acidophilic core surrounded by a thin fibrous layer) with granulomatous reaction in the periphery; (B) Granulomatous reaction with Langhans cell-like in the middle associated with an abundant lymphoplasmacytic reaction in the surrounding stroma. Hematoxylin–Eosin (HE) staining: (A) $\times 100$; (B) $\times 200$.

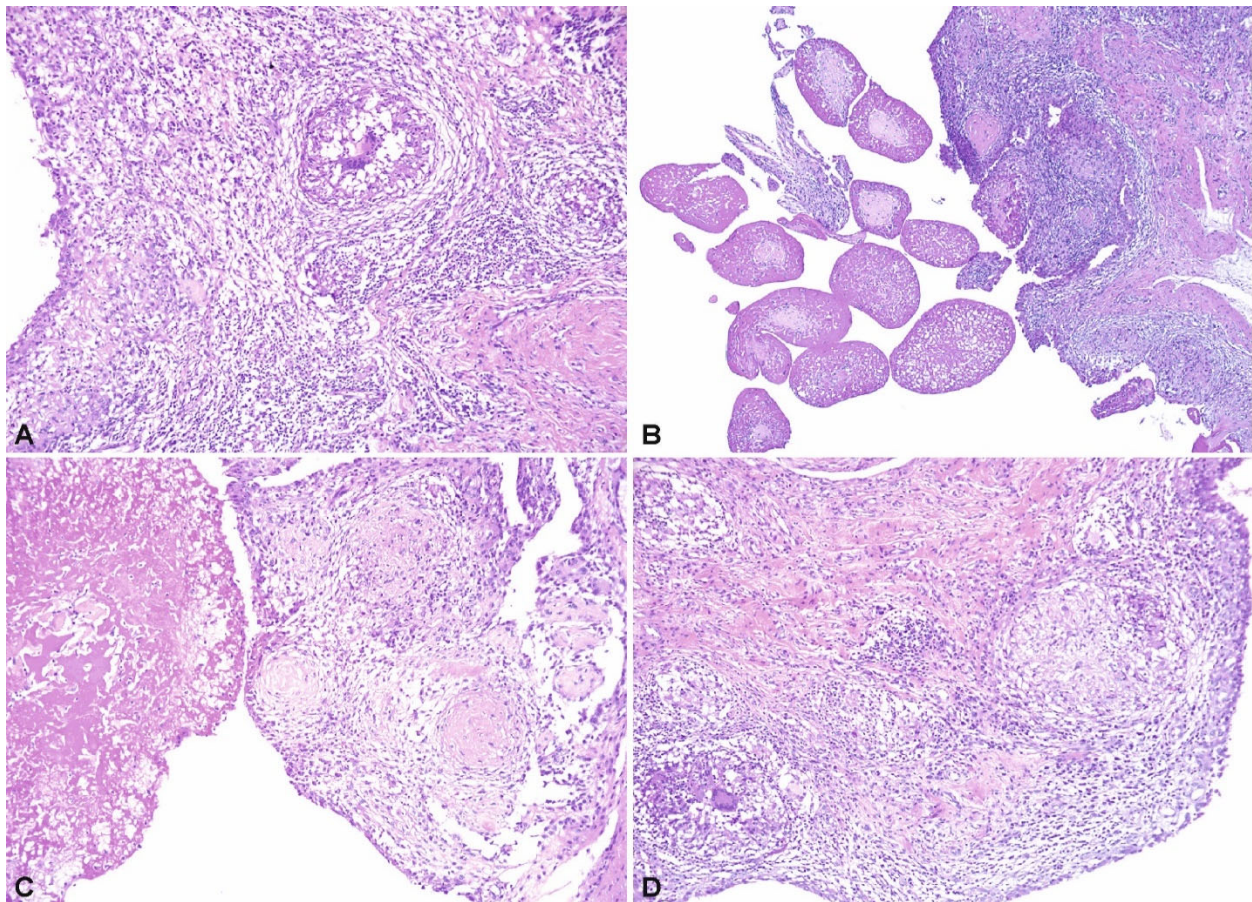


Figure 5 – (A) Proliferative synovitis with synovial cell hyperplasia and hypertrophy; (B) Fibrin organized in the form of rice bodies, some nodules with central cartilaginous transformation; (C) Fibrotic nodules surrounded by histiocytes; (D) Epithelioid granulomas with multinucleated giant cell, some of them Langhans cell-like. HE staining: (A, C and D) $\times 100$; (B) $\times 25$.

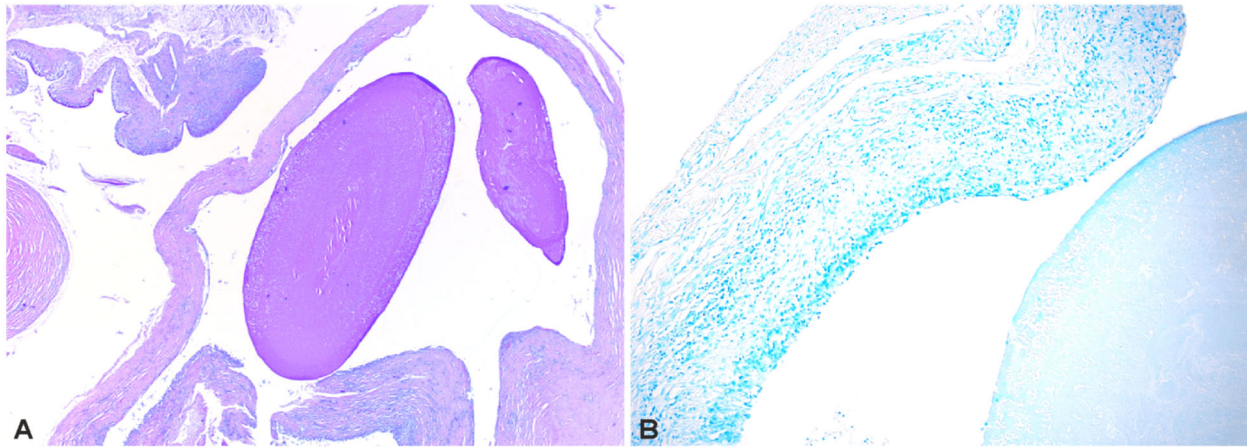


Figure 6 – (A) Crown of epithelioid cells with macrophages and lymphocytes around a rice body (Ziehl–Neelsen staining, $\times 20$); (B) Rice bodies in PAS staining ($\times 20$). PAS: Periodic Acid–Schiff.

Discussions

Tenosynovitis with abundant “rice bodies” is rarely reported in the literature, most of the cases being associated with tuberculous or non-tuberculous mycobacterial infection [2–6]. Rheumatic disease, trauma and fungal infection were also reported as causes for rice bodies’ tenosynovitis [7–10]. However, cases of rice body tenosynovitis without a known etiology were rarely reported in the literature.

Sugano *et al.* apparently reported the first case for the wrist tenosynovitis with rice body formation, at an 81-year-old man with no detected cause [11]. In 2012, Forse *et al.* collected four cases of tenosynovitis with rice bodies of unknown etiology located at the level of the tendon sheaths of hand and wrist and reported a new case [2]. Thus, of the five cases reported until 2012, four patients were male and one female. The age of these patients ranged from 32 to 81 years, and the location in three of the cases was in the left wrist. Of the clinical symptoms, pain was present in three cases represented and swelling in all five. Among nine cases of tenosynovitis with rice body in the hand, Yamamoto *et al.* reported two new cases, a 70-year-old male and 80-year-old female, in wherein a clear cause could not be established [9]. In 2018, Cegarra-Escolano *et al.* [5] and Mohammed Reda *et al.* [6] reported a case each of tenosynovitis with rice bodies. The first case was that of a 31-year-old man who presented a 15-year history of progressively growing a “sausage-like” swelling of the fourth finger and palm of his right hand. In the second case, the location was in the right hand of a 62-year-old man with a two-year disease history. In neither of these two cases, tuberculosis infection or rheumatic diseases were detected. The scarcity of case reports of tenosynovitis with rice bodies without a known cause reflects the rarity of these cases.

Pain, presence of swelling mass or neurological signs like median nerve compression are most likely symptoms and signs to be encountered with rice bodies tenosynovitis. The onset of symptoms varies from one month to 15 years, with a median patients’ age of 59.5 years (average 31–81 years). For two of our patients, those with the shortest history of the disease no swelling mass but carpal tunnel syndrome was detected, while for patients with a longer history (one to four years) a swelling mass was the determinant sign to seek medical advice.

Bacterial cultures and Ziehl–Neelsen staining, remain

the most commonly used and reliable methods in detecting mycobacterial infection. The presence of caseous necrosis in the synovial or rice bodies containing tubercular material is most helpful in diagnosing tuberculous mycobacteriosis [9, 12]. Polymerase chain reaction (PCR) may also help in establishing the infectious cause of rice body tenosynovitis [6]. However, in the study of Yamamoto *et al.*, among their nine cases with rice body tenosynovitis, PCR test was negative in all cases while microbial culture was positive in four of the cases [9]. Non-tuberculous mycobacterial infections or fungal infection must also be searched using special mycobacterial cultures or staining techniques. Despite extensive search, no clear etiology could be established for our series.

As for the pathogenesis of rice bodies, several hypotheses have been proposed, being regarded as a response to articular inflammation. First isolated in the intra-articular fluid, rice bodies have also been subsequently found in other regions: pleural fluid [13], tendon sheaths [14–16] and bursae [17], this fact hinting at the hypothesis of a non-synovial origin of rice bodies [2, 18]. Berg *et al.* suggested a *de novo* formation of rice bodies independent of the synovial elements and progressive enlargement by fibrin aggregation following an inflammatory reaction [19]. Cheung *et al.* believe that synovial microinfarctions lead to synovial shedding with subsequent encasement of fibrin derived from the synovial fluid [20]. In our study, the pathological findings in the five patients support the theory of chronic inflammation by the presence of a chronic inflammatory infiltrate containing T-lymphocytes, macrophages, and plasma cells.

Interesting in our study cases is the formation of rice bodies in amounts directly proportional to disease course, the smallest amount in symptomatic cases with short history and the highest amount in the case with a four-year history.

Preoperative diagnosis is difficult because symptoms may be absent or unspecific, with neurological symptoms similar to those in carpal tunnel syndrome [6]. Differential diagnosis includes pigmented villonodular synovitis, synovial chondromatosis, tuberculous or non-tuberculous tenosynovitis and sarcoidosis [21, 22]. MRI is the imaging technique that can guide the diagnosis. MRI describes the rice body as a homogenous nodule, iso- or hypointensive on T1-weighted sequences and minimally hyperintense on T2-weighted sequences [11, 23, 24] and differential

diagnosis includes pigmented villonodular synovitis, in which the presence of iron and hemosiderin in the synovium causes low intensity signals on T1- and T2-weighted images [21]. Nonmineralized synovial chondromatosis is also a disease that can be eliminated with the help of MRI images, the nodules being minimally hyperintense on T1-weighted sequences and not visible on T2-weighted sequences [3, 4]. In tuberculous tenosynovitis, the tumor mass around the tendons appears to be of intermediate intensity on T1-weighted sequences and hyperintense on T2-weighted sequences [25, 26]. However, few literature data provide information about images in sarcoidosis, being described as a hyperintense tumor mass on T2-weighted images [22]. In our study, in Case No. 5, we raised the suspicion of a possible rice body tenosynovitis, but in Cases No. 3 and No. 4, the preoperative diagnosis prone to villonodular synovitis.

Nagasawa *et al.* reported spontaneous flexor tendon rupture at a 68-year-old female patient diagnosed with rice body tenosynovitis of unknown etiology and rupture of right fourth and fifth flexor tendons [4]. In this case, the tendons were confirmed as intact during the first surgery, the rupture being noted one month later when a granulation tissues proliferating around the flexor tendons was observed and removed [4]. In our Case No. 5, during surgery, we found an associated spontaneous profound and superficial digit five and superficial digit four flexor tendon rupture. We believe that the mechanism by which this rupture occurs is most likely a pressure, erosion exerted by the large amount of rice bodies present under tension in the synovial sheath. Therefore, this may be the first case reported in the literature of flexor tendon rupture directly related to the presence of rice bodies in tendon synovial sheath of unknown etiology.

Both intraoperative and microscopic diagnosis are easy due to the unique features. From a microscopic point of view, “rice bodies” are made up of an amorphous, acidophilic nucleus surrounded by fibrin and collagen [27, 28]. Fibrin is the main component of the matrix, to which small amounts of collagen are associated, and the cellular components are fibroblasts, histiocytes and synovial cells. Rarely, depending on location, rice bodies may contain capillaries or cartilage [28]. A similar description of microscopic lesions was also made in the cases reported in this study. The rice bodies found in tuberculosis are supposed to be larger than those of rheumatic disease. In four of our cases, rice bodies were less than 4 mm, and in only one case, a few grains measured up to 7 mm, these findings being more consistent with a tuberculous infection. It is well known that the presence of granulomas represents a strong argument for tuberculosis or non-mycobacterial infection, but this finding is not specific to a mycobacterial infection [5, 29]. In all cases, epithelioid granulomas with multinucleated giant cell, some of them Langhans cell-like were found but extensive tests failed to demonstrate a mycobacterial infection, sarcoidosis or other disease.

Synovectomy is indicated in all cases, especially when associated with nerve compression syndromes, but also in order to avoid complications such as spontaneous tendon rupture and possible functional limitations [2, 7, 30]. Synovectomy with removal of all rice bodies was the treatment of choice in the cases reported by us, followed a three-month interval by the reconstruction of the deep flexor of the fifth finger in Case No. 5.

As some authors pointed out, the failure to prove an etiology in rice body synovitis prone the patient to recurrence [5]. In tuberculous tenosynovitis, the early recurrence rate is higher than 50% within the first year [4, 25, and 31]. Iyengar *et al.* consider that in chronic inflammatory disease early recurrence occurs if an appropriate anti-inflammatory treatment is not provided [32]. Despite negative bacterial cultures and pathological findings, Yamamoto *et al.* consider that some signs of non-specific infection, such as leukocytic infiltration, may prove an infection still is the cause of tenosynovitis, thus they propose to start antibacterial therapy in an early stage to prevent recurrence of tenosynovitis [9]. Therefore, some authors recommended that in the absence of specific etiology after further investigations, the patient should be monitored for an extended period of time [5]. In our cases, inflammatory infiltrate was present, but no postoperative long-term antibacterial or anti-inflammatory therapy was recommended. Postoperative outcomes were good, without any recurrence after 30.4-month median follow-up. Besides, no recurrences were reported in the nine cases in the literature, the median follow-up being 21.6 months [2–6, 9, 27].

☞ Conclusions

This is the largest series of patients with idiopathic rice bodies’ tenosynovitis. We report here the first case of flexor tendons rupture directly related to the presence of rice body in the tendon sheath in a patient with idiopathic tenosynovitis. In addition, one of our patients had the most extensive lesion (210 mm long) reported in literature until now with a significant amount of rice bodies. In our series, we observed that more advanced stages of disease, with longer history, are associated with the presence of a larger number of rice bodies, and involvement of a greater length of synovial sheaths. Synovectomy with removal of all rice bodies represented the optimal treatment in these patients. In these cases, not associated with any other infectious or systemic inflammatory disease, etiopathogenesis remains unclear.

Conflict of interests

The authors have no conflict of interests to declare.

References

- [1] Reise H. Die Reiskorpchen in Tuberculs erkrankten Synovial-sacken. *Dtsch Z Chir*, 1895, 42:1–99.
- [2] Forse CL, Mucha BL, Santos ML, Ongcapin EH. Rice body formation without rheumatic disease or tuberculosis infection: a case report and literature review. *Clin Rheumatol*, 2012, 31(12):1753–1756. <https://doi.org/10.1007/s10067-012-2063-8> PMID: 22941257
- [3] Ergun T, Lakadamyali H, Aydin O. Multiple rice body formation accompanying the chronic nonspecific tenosynovitis of flexor tendons of the wrist. *Radiat Med*, 2008, 26(9):545–548. <https://doi.org/10.1007/s11604-008-0270-7> PMID: 19030963
- [4] Nagasawa H, Okada K, Senma S, Chida S, Shimada Y. Tenosynovitis with rice body formation in a non-tuberculosis patient: a case report. *Ups J Med Sci*, 2009, 114(3):184–188. <https://doi.org/10.1080/03009730902931408> PMID: 19736610 PMID: PMC2852770
- [5] Cegarra-Escolano M, Jaloux C, Camuzard O. Rice-body formation without rheumatic disease or tuberculosis in a “sausage” ring finger. *Hand Surg Rehabil*, 2018, 37(4):255–258. <https://doi.org/10.1016/j.hansur.2018.03.005> PMID: 29786532
- [6] Mohammed Reda F, Talal G, Moncef B, Reda-Allah B, Moulay Omar L, Mohammed Saleh B. Mass of the thenar eminence hiding idiopathic massive rice bodies formation with a

- compression of the median nerve: case report and review of the literature. *Int J Surg Case Rep*, 2018, 50:28–31. <https://doi.org/10.1016/j.ijscr.2018.07.025> PMID: 30071378 PMCID: PMC6080574
- [7] Celikyay F, Yuksekkaya RZ, Bostan B. Flexor tenosynovitis of the wrist including rice bodies. *Joint Bone Spine*, 2018, 85(3):373. <https://doi.org/10.1016/j.jbspin.2017.07.005> PMID: 28757343
- [8] Hong SE, Pak JH, Suh HS, Kang SR, Park BY. Rice body tenosynovitis without tuberculosis infection after multiple acupuncture procedures in a hand. *Arch Plast Surg*, 2015, 42(4):502–505. <https://doi.org/10.5999/aps.2015.42.4.502> PMID: 26217578 PMCID: PMC4513066
- [9] Yamamoto D, Tada K, Suganuma S, Ikeda K, Tsuchiya H. Non-tuberculous mycobacterium or fungus induced chronic tenosynovitis with rice body of the hand. *J Hand Surg Asian Pac*, 2017, 22(3):337–342. <https://doi.org/10.1142/S0218810417500393> PMID: 28774249
- [10] Jeong YM, Cho HY, Lee SW, Hwang YM, Kim YK. *Candida* septic arthritis with rice body formation: a case report and review of literature. *Korean J Radiol*, 2013, 14(3):465–469. <https://doi.org/10.3348/kjr.2013.14.3.465> PMID: 23690715 PMCID: PMC3655302
- [11] Sugano I, Nagao T, Tajima Y, Ishida Y, Nagao K, Ohno T, Ooishi S. Variation among giant rice bodies: report of four cases and their clinicopathological features. *Skeletal Radiol*, 2000, 29(9):525–529. <https://doi.org/10.1007/s002560000258> PMID: 11000298
- [12] Balagué N, Uçkay I, Vostrel P, Hinrikson H, Van Aaken I, Beaulieu JY. Non-tuberculous mycobacterial infections of the hand. *Chir Main*, 2015, 34(1):18–23. <https://doi.org/10.1016/j.main.2014.12.004> PMID: 25579828
- [13] Kassimos D, George E, Kirwan JR. Rice bodies in the pleural aspirate of a patient with rheumatoid arthritis. *Ann Rheum Dis*, 1994, 53(6):427–428. <https://doi.org/10.1136/ard.53.6.427> PMID: 8037504 PMCID: PMC1005363
- [14] Luiz CP, Ramanathan EB, Buhl L, Muirhead D. A case of date palm thorn-induced extra articular synovitis with rice grain bodies. *Br J Rheumatol*, 1994, 33(12):1190–1191. <https://doi.org/10.1093/rheumatology/33.12.1190-a> PMID: 8000755
- [15] Suso S, Peidro L, Ramon R. Tuberculous synovitis with “rice bodies” presenting as carpal tunnel syndrome. *J Hand Surg Am*, 1988, 13(4):574–576. [https://doi.org/10.1016/s0363-5023\(88\)80099-6](https://doi.org/10.1016/s0363-5023(88)80099-6) PMID: 3418063
- [16] Cuomo A, Pirpiris M, Otsuka NY. Case report: biceps tenosynovial rice bodies. *J Pediatr Orthop B*, 2006, 15(6):423–425. <https://doi.org/10.1097/01.bpb.0000228392.62678.df> PMID: 17001249
- [17] Steinfeld R, Rock MG, Younge DA, Cofield RH. Massive subacromial bursitis with rice bodies: report of three cases, one of which was bilateral. *Clin Orthop Relat Res*, 1994, (301):185–190. <https://doi.org/10.1097/00003086-199404000-00029> PMID: 8156671
- [18] Muirhead DE, Johnson EH, Luis C. A light and ultrastructural study of rice recovered from a case of date thorn-induced extra-articular synovitis. *Ultrastruct Pathol*, 1998, 22(4):341–347. <https://doi.org/10.3109/01913129809103355> PMID: 9805359
- [19] Berg E, Wainwright R, Barton B, Puchtler H, McDonald T. On the nature of rheumatoid rice bodies: an immunological, histochemical, and electron microscope study. *Arthritis Rheum*, 1977, 20(7):1343–1349. <https://doi.org/10.1002/art.1780200707> PMID: 334184
- [20] Cheung HS, Ryan LM, Kozin F, McCarthy DJ. Synovial origins of rice bodies in joint fluid. *Arthritis Rheum*, 1980, 23(1):72–76. <https://doi.org/10.1002/art.1780230112> PMID: 7352946
- [21] Griffith JF, Peh WCG, Evans NS, Smallman LA, Wong RWS, Thomas AMC. Multiple rice body formation in chronic subacromial/subdeltoid bursitis: MR appearances. *Clin Radiol*, 1996, 51(7):511–514. [https://doi.org/10.1016/s0009-9260\(96\)80193-0](https://doi.org/10.1016/s0009-9260(96)80193-0) PMID: 8689829
- [22] Katzman BM, Caligiuri DA, Klein DM, Perrier G, Dauterman PA. Sarcoid flexor tenosynovitis of the wrist: a case report. *J Hand Surg Am*, 1997, 22(2):336–337. [https://doi.org/10.1016/S0363-5023\(97\)80173-6](https://doi.org/10.1016/S0363-5023(97)80173-6) PMID: 9195436
- [23] Chen A, Wong LY, Sheu CY, Chen BF. Distinguishing multiple rice body formation in chronic subacromial-subdeltoid bursitis from synovial chondromatosis. *Skeletal Radiol*, 2002, 31(2):119–121. <https://doi.org/10.1007/s002560100412> PMID: 11828336
- [24] Sueyoshi E, Uetani M, Hayashi K, Kohzaki S. Tuberculous tenosynovitis of the wrist: MRI findings in three patients. *Skeletal Radiol*, 1996, 25(6):569–572. <https://doi.org/10.1007/s002560050137> PMID: 8865493
- [25] Bayram S, Erşen A, Altan M, Durmaz H. Tuberculosis tenosynovitis with multiple rice bodies of the flexor tendons in the wrist: a case report. *Int J Surg Case Rep*, 2016, 27:129–132. <https://doi.org/10.1016/j.ijscr.2016.08.021> PMID: 27611797 PMCID: PMC5018083
- [26] Hsu CY, Lu HC, Shih TTF. Tuberculous infection of the wrist: MRI features. *AJR Am J Roentgenol*, 2004, 183(3):623–628. <https://doi.org/10.2214/ajr.183.3.1830623> PMID: 15333346
- [27] Tyllianakis M, Kasimatis G, Athanaselis S, Melachrinou M. Rice-body formation and tenosynovitis of the wrist: a case report. *J Orthop Surg (Hong Kong)*, 2006, 14(2):208–211. <https://doi.org/10.1177/230949900601400221> PMID: 16914791
- [28] Moreno S, Forcada P, Soria X, Altemir V, Gatus S, Gil M, Matías-Guiu X, Casanova JM, Martí RM. Tenosynovitis with rice body formation presenting as a cutaneous abscess. *J Cutan Pathol*, 2014, 41(7):602–605. <https://doi.org/10.1111/cup.12316> PMID: 24673442
- [29] Al-Qattan MM, Al-Namla A, Al-Thunayan A, Al-Omawi M. Tuberculosis of the hand. *J Hand Surg Am*, 2011, 36(8):1413–1421; quiz 1422. <https://doi.org/10.1016/j.jhsa.2011.05.036> PMID: 21764526
- [30] Reddy GP, Upadhyaya DN, Jaiswal R, Goel MM. ‘Sausage finger’ with ‘rice bodies’. *Indian J Plast Surg*, 2018, 51(1):93–97. https://doi.org/10.4103/ijps.IJPS_202_16 PMID: 29928087 PMCID: PMC5992945
- [31] Chandrasekharan J, Sambandam SN, Cheriyaakara S, Mounasamy V. Tuberculous tenosynovitis presenting as finger drop: a case report and a systematic review of the literature. *Muscles Ligaments Tendons J*, 2016, 6(2):258–263. <https://doi.org/10.11138/mltj/2016.6.2.258> PMID: 27900302 PMCID: PMC5115260
- [32] Iyengar K, Manickavasagar T, Nadkarni J, Mansour P, Loh W. Bilateral recurrent wrist flexor tenosynovitis and rice body formation in a patient with sero-negative rheumatoid arthritis: a case report and review of literature. *Int J Surg Case Rep*, 2011, 2(7):208–211. <https://doi.org/10.1016/j.ijscr.2011.07.001> PMID: 22096729 PMCID: PMC3199677

Corresponding authors

Bogdan Veliceasa, MD, PhD, Department of Orthopedics and Traumatology, Grigore T. Popa University of Medicine and Pharmacy, 16 University Street, 700115 Iași, Romania; Phone +40742–056 208, e-mail: velbogdan@yahoo.com

Mihaela Mitrea, MD, PhD, Department of Mophofunctional Sciences I, Grigore T. Popa University of Medicine and Pharmacy, 16 University Street, 700115 Iași, Romania; Phone +40744–533 723, e-mail: mihaela.mitrea77@yahoo.com