

Case Report

Air leak: An unusual manifestation of organizing pneumonia secondary to bleomycin

R Namitha, KP Nimisha, Nasser Yusuf¹, CP Rauf¹

Department of Pulmonology and ¹Department of Pulmonology and Thoracic Surgery, Chest Hospital, Kozhikode, Kerala, India

ABSTRACT

Organizing pneumonia (OP) is a less common interstitial lung disease with varying clinical picture. The development of pulmonary air leak in a case of OP is an extremely rare complication. Here, we report the case of a 46-year-old female with carcinoma ovary, postchemotherapy who developed respiratory distress with pneumomediastinum, and subcutaneous emphysema. Lung biopsy showed evidence of OP. This turned out to be a rare case of OP, secondary to bleomycin chemotherapy, presenting with pulmonary air leak.

KEY WORDS: Air leak, bleomycin chemotherapy, lung biopsy, organizing pneumonia, subcutaneous emphysema

Address for correspondence: Dr. R Namitha, Department of Pulmonology, Chest Hospital, Kozhikode, Kerala, India. E-mail: namitha46@gmail.com

INTRODUCTION

Organizing pneumonia (OP) is characterized by an indolent clinical course and a favorable prognosis although a fulminant variant has been documented. The patient typically presents with fever, cough, dyspnea, and weight loss. Imaging studies would show bilateral patchy consolidations and ground-glass appearance. Pulmonary air leak comprising pneumothorax, pneumomediastinum, and subcutaneous emphysema is rarely a presenting feature of an OP. The exact pathogenesis and an appropriate management guideline have not yet been established for this dreaded complication. Review of medical literature reveals only a few case reports of air leak in OP. Here, we report a case of OP secondary to bleomycin chemotherapy, where pulmonary air leak was the major presenting symptom, which has never been reported previously.

CASE REPORT

A 43-year-old female presented to our emergency department with severe shortness of breath, diffuse neck

swelling, and neck pain, of 1 day duration. She had a Stage III ovarian immature teratoma diagnosed 6 months back and was treated with bilateral salpingo oophorectomy followed by 6 cycles of chemotherapy with bleomycin, etoposide, and cisplatin. She had shortness of breath for the last 4 months. One week prior to the admission, she had fever and severe cough which was treated from a local hospital.

On examination, she had respiratory distress with a respiratory rate of 32/min. Her SpO₂ was 82% in room air, blood pressure 110/70 mmHg, and heart rate 110/min. Further examination revealed subcutaneous emphysema in the neck and chest wall. Examination of the respiratory system showed equal breath sounds on both sides with bilateral fine basal crepitations and muffled heart sounds. She had leukocytosis with predominant neutrophils and a normal metabolic panel. The values for the blood gas analysis were a pH of 7.42, PCO₂ of 34 mmHg, and PO₂ of 65 mmHg.

This is an open access article distributed under the terms of the Creative Commons Attribution-NonCommercial-ShareAlike 3.0 License, which allows others to remix, tweak, and build upon the work non-commercially, as long as the author is credited and the new creations are licensed under the identical terms.

For reprints contact: reprints@medknow.com

How to cite this article: Namitha R, Nimisha KP, Yusuf N, Rauf CP. Air leak: An unusual manifestation of organizing pneumonia secondary to bleomycin. Lung India 2017;34:173-5.

Access this article online	
Quick Response Code: 	Website: www.lungindia.com
	DOI: 10.4103/0970-2113.201306

Chest X-ray showed [Figure 1] features suggestive of subcutaneous emphysema and mediastinal emphysema with bilateral haziness and alveolar opacities in lower zones. A computed tomography (CT) thorax [Figure 2] with findings of ground-glass opacities and peripheral consolidation, confirmed the diagnosis of pneumonia and mediastinal emphysema.

With this clinical presentation of a pulmonary air leak syndrome and radiologic picture of bilateral predominant ground glass opacities with patchy consolidations, we considered the possibility of pneumocystis jiroveci pneumonia or a drug-induced lung disease like diffuse alveolar damage/OP.

Since the patient had severe respiratory distress and hypoxemia, she was immediately taken up for surgical management. A video-assisted thoracoscopy was done [Figure 3], and the mediastinum dissected revealing multiple paracardiac blebs. These blebs were ablated; the pneumomediastinum drained into left hemithorax, and an intercostal drainage tube was inserted in left hemithorax. A lung biopsy was taken.

Patient's condition improved dramatically with rising oxygen saturation. She was shifted to the Intensive Care Unit and was treated with antibiotics, steroids, and supportive treatment. Biopsy of the lung specimen [Figure 4] revealed bronchiolitis obliterans organizing pneumonia (BOOP). None of the serologic parameters or tissue cultures was positive for any infectious cause. Soon the air-leak disappeared, and she was discharged from the hospital with a long-term course of steroids and macrolide. She is now kept on regular follow-up.

DISCUSSION

OP is a clinicopathologic syndrome first described by Davison and Epler *et al.* in the 1980s.^[1] OP is classified into idiopathic (also called cryptogenic OP) and secondary OP. Causes of secondary OP include infections, drugs, connective tissue diseases, organ transplantation, and inflammatory bowel diseases.^[2]

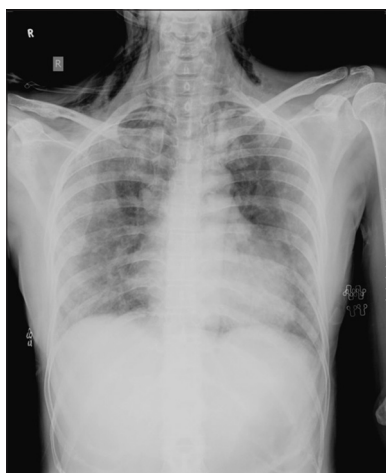

Figure 1: Mediastinal emphysema and diffuse haziness in chest X-ray

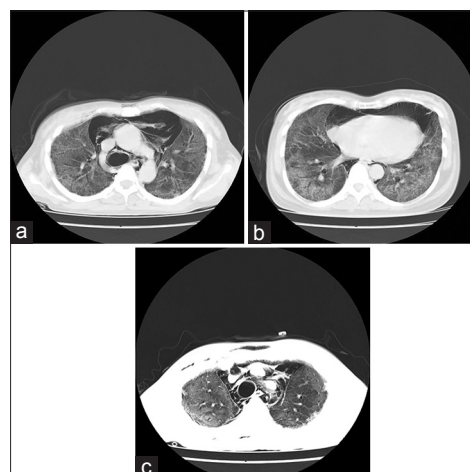


Figure 2: (a-c) Serial computed tomography images showing bilateral diffuse ground-glass opacities, mediastinal emphysema, and peripheral consolidation

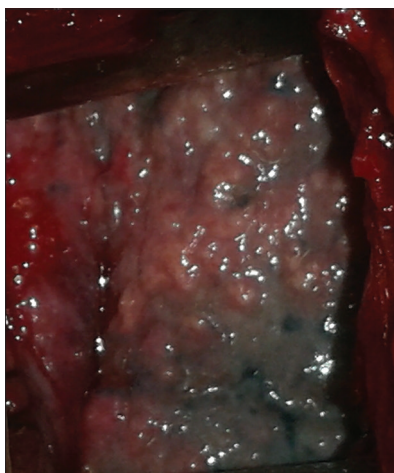


Figure 3: Video-assisted thoracoscopy showing paracardiac blebs

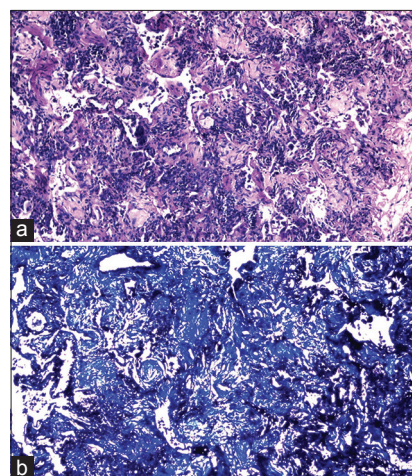


Figure 4: (a) Histology showed plugs of fibrous tissue in terminal bronchioles, (b) trichrome stain showing fibrous proliferation

The manifestations of OP are nonspecific; hence, the diagnosis is delayed in many. High index of suspicion should be kept to diagnose secondary OP, especially in patients with chemotherapy, organ transplantation, etc. A unique manifestation of bleomycin toxicity is multiple pulmonary nodules in CT mimicking metastasis and having histologic characteristic of OP/BOOP. Other manifestations include diffuse alveolar damage and chronic pneumonitis with fibrosis. Bleomycin pulmonary toxicity has an incidence of 0.4%.^[3] Lung biopsy is the gold standard diagnostic procedure.

A study conducted by Mokhtari *et al.* found that of the 43 patients with isolated BOOP in cancer patients, 3 were found to be due to bleomycin.^[4] Kofteridis *et al.*,^[5] Iwanaga *et al.*,^[6] and Yang *et al.*^[7] have published case reports of air leak syndrome in BOOP. None of case reports showed OP secondary to bleomycin presenting as air leak.

The hallmark of OP is the presence of intraalveolar buds of granulation tissue consisting of fibroblasts-myofibroblasts embedded in connective tissue. These buds may extend from one alveolus to the next through the interalveolar pores and into the bronchioles obstructing the lumen (bronchiolitis obliterans).^[2] The pathogenesis proposed for air leak is that, localized plugs of fibrous tissue in the bronchiole lumen in OP, produce a ball valve mechanism and alveolar over-distension, eventually leading to rupture. The air dissects through the bronchovascular sheath and ascends toward the hilum to produce a pneumomediastinum and also along the subcutaneous connective tissue to cause subcutaneous emphysema. Air leakage in the mediastinum may also occur due to the rupture of paracardiac bleb. In severe interstitial lung disease (ILD), subpleural or paracardiac blebs are formed due to the distortion of lung architecture.^[8]

We also considered the possibility of pneumocystis jiroveci pneumonia and metastasis as a differential in this immunocompromised patient with fever, cough, radiologically bilateral ground glassing, and air leak, but investigation profile proved against this. In our patient, OP was secondary to bleomycin.

The treatment of OP is long-term steroid, and the treatment for massive pneumomediastinum is limited mediastinotomy and drainage.^[9]

CONCLUSION

OP should be included in our differential diagnosis list, whenever a patient presents with air leak. Lung biopsy should be done to confirm the diagnosis and would prove to be lifesaving as this disease responds well to steroids. Paracardiac and subpleural blebs in severe ILD causing pneumomediastinum are usually under-reported. Limited mediastinotomy and drainage of pneumomediastinum in massive air leak is lifesaving and gives rapid improvement.

Acknowledgment

Department of pulmonology, Chest Hospital Calicut for general support. Department of Pathology:MIMS HOSPITAL ,Calicut.

Financial support and sponsorship

Nil.

Conflicts of interest

There are no conflicts of interest.

REFERENCES

1. Epler GR, Colby TV, McLoud TC, Carrington CB, Gaensler EA. Bronchiolitis obliterans organizing pneumonia. *N Engl J Med* 1985;312:152-8.
2. Herzog EL, Rubinstein AN, Gulati M. Idiopathic interstitial pneumonias other than idiopathic pulmonary fibrosis. In: Grippi MA, editor. *Fishman's Pulmonary Diseases and Disorders*. 5th ed. United States of America: McGraw Hill Education; 2015.
3. Webb WR. Iatrogenic lung diseases: Drug induced lung diseases and radiation pneumonitis. In: Webb WR, Higgins CB, editors. *Thoracic Imaging Pulmonary and Cardiovascular Radiology*. 2nd ed. Philadelphia, USA: Lippincott Williams and Wilkins; 2011.
4. Mokhtari M, Bach PB, Tietjen PA, Stover DE. Bronchiolitis obliterans organizing pneumonia in cancer: A case series. *Respir Med* 2002;96:280-6.
5. Kofteridis DP, Bouros DE, Vamvakas LN, Stefanaki KS, Voludaki AE, Barbounakis EM, *et al.* Pneumothorax complicating fatal bronchiolitis obliterans organizing pneumonia. *Respiration* 1999;66:266-8.
6. Iwanaga T, Hirota T, Ikeda T. Air leak syndrome as one of the manifestations of bronchiolitis obliterans organizing pneumonia. *Intern Med* 2000;39:163-5.
7. Yang DG, Kim KD, Shin DH, Choe KO, Kim SK, Lee WY. Idiopathic bronchiolitis obliterans with organizing pneumonia presenting with spontaneous hydropneumothorax and solitary pulmonary nodule. *Respirology* 1999;4:267-70.
8. Powell C, Kendall B, Wernick R, Hefner JE. A 34-year-old man with amyopathic dermatomyositis and rapidly progressive dyspnea with facial swelling. Diagnosis: Pneumomediastinum and subcutaneous emphysema secondary to amyopathic dermatomyositis-associated interstitial lung disease. *Chest* 2007;132:1710-3.
9. Herlan DB, Landreneau RJ, Ferson PF. Massive spontaneous subcutaneous emphysema. Acute management with infraclavicular "blow holes". *Chest* 1992;102:503-5.