

His bundle capture proximal to the site of bundle branch block: A novel pitfall of the para-Hisian pacing maneuver



Marek Jastrzebski, MD, PhD,* Piotr Kukla, MD, PhD,[†] Danuta Czarnecka, MD, PhD*

From the *First Department of Cardiology, Interventional Electrophysiology and Hypertension, Jagiellonian University, College of Medicine, Cracow, Poland, and [†]Department of Cardiology, H. Klimontowicz Specialistic Hospital, Gorlice, Poland.

Introduction

The para-Hisian pacing maneuver is useful in determining whether retrograde conduction is dependent on atrioventricular (AV) nodal conduction. Loss of direct His bundle capture results in a longer route for the depolarization wave to reach the AV node and the atrium, as it has to travel through the working myocardium to engage the distal Purkinje fibers. Thus, loss of direct His bundle capture results in obligatory ventriculoatrial (VA) interval prolongation unless a nonphysiological retrograde conduction route (an accessory pathway [AP]) is present. Consequently, a stable VA interval with loss of His bundle capture is considered diagnostic of the presence of an AP. This concept has been regarded as useful, especially when concentric retrograde atrial activation is present.¹ Subsequently, however, potential important pitfalls in the interpretation of this differentiating maneuver were described. These include the recognition of inadvertent atrial capture, pure His bundle capture, the presence of fasciculoventricular pathways, and the impact of retrograde dual AV nodal physiology.^{2–5}

Case report

A 14-year-old boy presented with recurrent syncope and preexcitation on the surface electrocardiogram. An electrophysiology study was performed under general anesthesia. The AP conducted intermittently in the basal state, unmasking incomplete right bundle branch. After administration of isoprenaline, however, the AP was capable of 1:1 conduction at a cycle length of 240 ms. The fully preexcited QRS morphology observed indicated localization in the left posterior region. The anterograde Wenckebach point was reached at 230 ms, with conduction only via His-Purkinje system at this rate, along with normal atrium-His and His-ventricle intervals and

KEY TEACHING POINTS

- Care should be taken in interpreting the results of para-Hisian pacing maneuvers in patients with preexisting, functional or even transient, mechanically induced bundle branch block. In such cases, proximal His bundle capture with sudden QRS prolongation mimics complete loss of His bundle capture and might lead to misinterpretation of the response as extranodal.
- Paced QRS morphology should be assessed to differentiate between complete loss of His bundle capture and loss of distal His bundle capture alone. This might be enough in patients with proximal right bundle branch block; however, in patients with proximal left bundle branch block, QRS morphology might be similar with loss of His bundle capture and with proximal His bundle capture.
- A further reduction in pacing output or pushing the pacing catheter slightly deeper into the right ventricle to ensure pure right ventricular myocardial capture may be useful to avoid misinterpretation of proximal His bundle capture as pure right ventricular myocardial capture.
- This pitfall may be avoided by recording retrograde His potential with a second catheter to confirm the loss of direct His bundle capture rather than relying on the usual observation of sudden QRS prolongation with the decrease in pacing output.

KEYWORDS Accessory pathway; Bundle branch block; His bundle; Para-Hisian pacing
(Heart Rhythm Case Reports 2018;4:22–25)

This work was supported by the Jagiellonian University (grant no. K/ZDS/006433). **Address reprint requests and correspondence:** Dr Marek Jastrzebski, First Department of Cardiology, Interventional Electrophysiology and Hypertension, University Hospital, ul. Kopernika 17, 31-501 Cracow, Poland. E-mail address: mcjastrz@cyf-kr.edu.pl.

right bundle branch block. Retrograde conduction was decremental with 1:1 conduction up to a cycle length of 240 ms and was mildly eccentric, with earliest atrial activation just after coronary sinus ostium, corresponding to the presumed AP localization. Despite isoprenaline infusion, no arrhythmia was induced. Para-Hisian pacing was performed to determine whether the AP conducted in a retrograde manner. The decrease

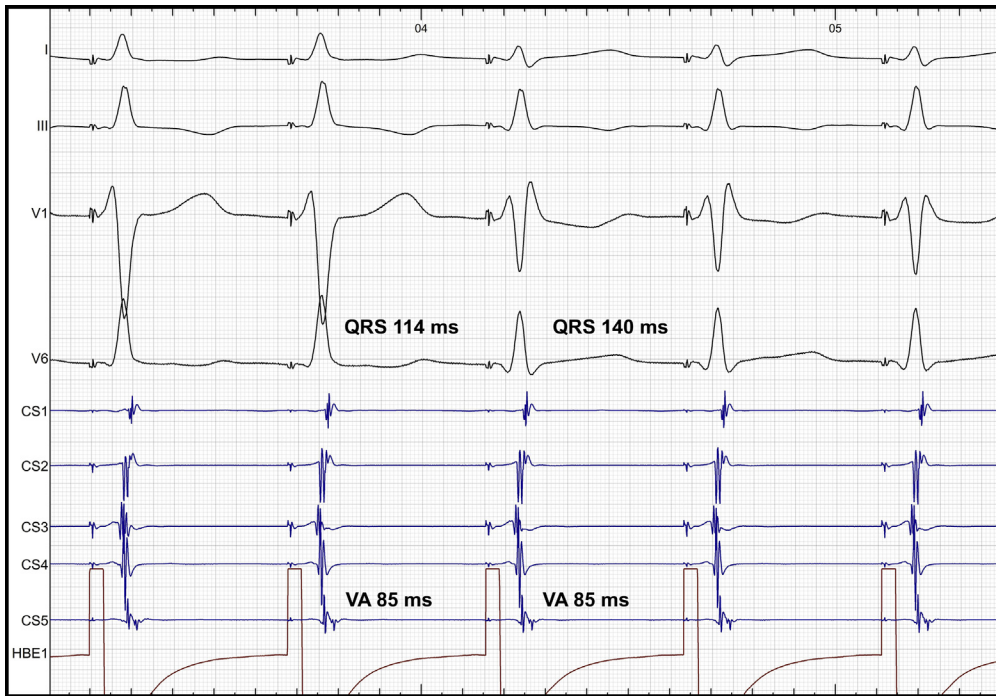


Figure 1 The decrease in pacing output was accompanied by QRS complex prolongation, suggestive of loss of His bundle capture. However, there was no corresponding prolongation of the ventriculoatrial (VA) interval, indicating an extranodal response. CS1 to CS5 represent proximal to distal coronary sinus electrodes.

in pacing output resulted in a sudden QRS complex prolongation, but there was no corresponding change in the retrograde atrial activation sequence or in the VA interval of 85 ms

(Figure 1). Such a response to para-Hisian pacing is considered indicative of retrograde conduction via an AP. However, in the present case this was a variant of the nodal response.

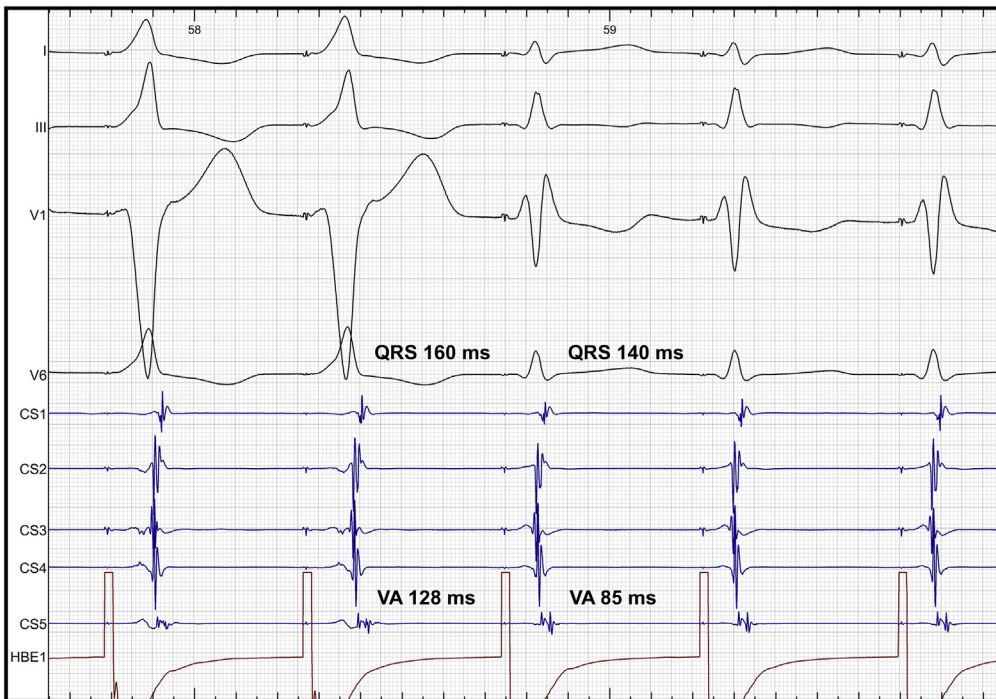

Figure 2 Para-Hisian pacing with increase in pacing output. The first 2 QRS complexes of left bundle branch block morphology result from pure right ventricular myocardial capture. Subsequent narrower QRS complexes of right bundle branch block morphology represent His bundle capture proximal to the site of block in the right bundle. Narrowing of the QRS complex with His bundle capture corresponds to shortening of the ventriculoatrial (VA) interval from 128 to 85 ms. CS1 to CS5 represent proximal to distal coronary sinus electrodes.

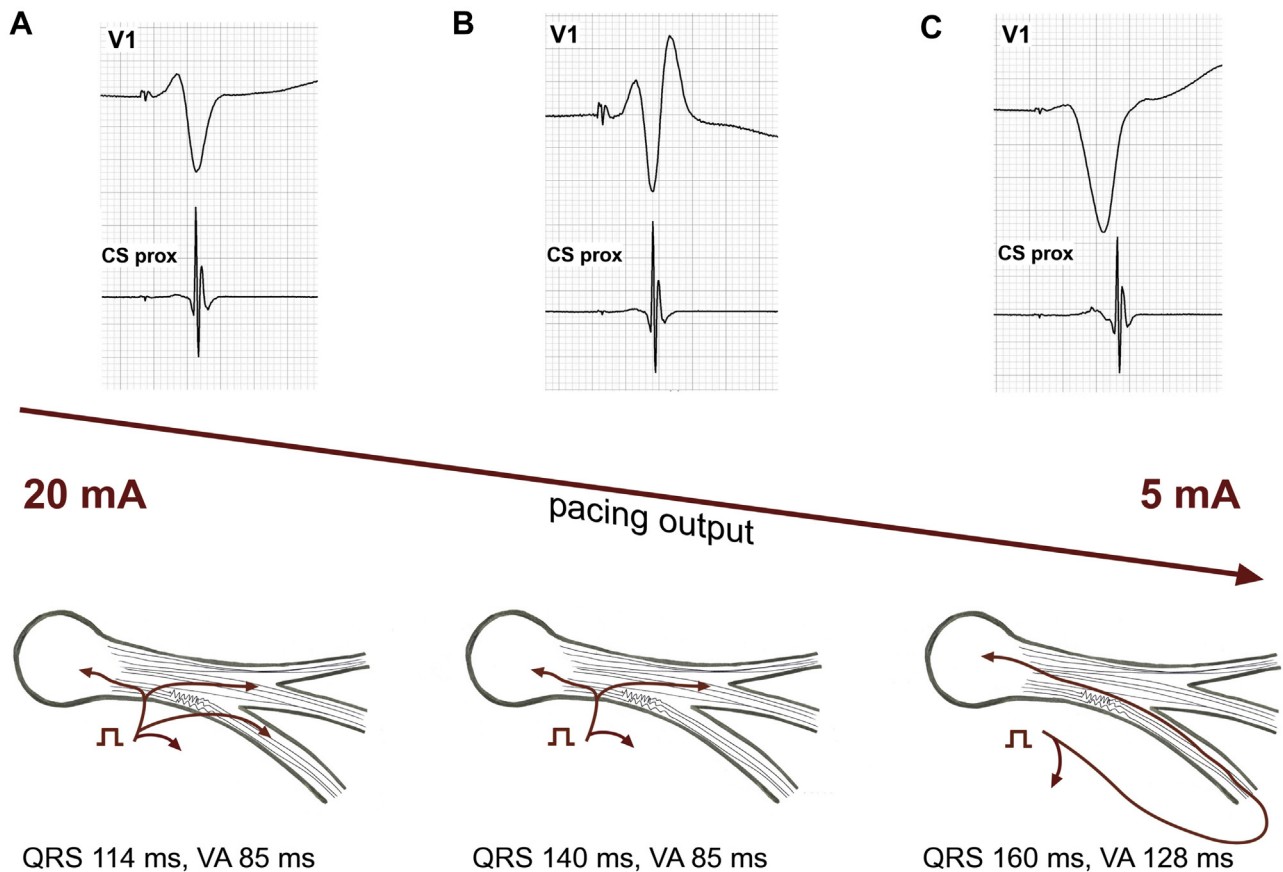


Figure 3 Schematic explanation of the 3 observed responses to para-Hisian pacing. **A:** High-output pacing with capture of the RV myocardium and distal His bundle capture (beyond the area of blockage in the right bundle fibers), resulting in a narrow QRS duration of 114 ms and a short VA interval of 85 ms. **B:** Intermediate-output pacing with capture of the RV myocardium and proximal His bundle capture (proximal to the area of blockage in the right bundle fibers), resulting in an intermediate QRS duration (140 ms) of right bundle branch block morphology and a short VA interval of 85 ms. **C:** Low-output pacing with capture of the RV myocardium only, resulting in a still longer QRS duration (160 ms) of left bundle branch block morphology and a longer VA interval of 128 ms. Retrograde conduction most likely occurred via right bundle (unidirectional block) since conduction via left bundle would result in much larger prolongation of VA conduction (by additional 50 ms). CS prox = proximal coronary sinus; RV = right ventricular; VA = ventriculoatrial.

Discussion

This patient showed no evidence of VA interval prolongation despite a sudden change in QRS morphology and an increase in QRS duration from 114 to 140 ms. However, several basic questions must be asked when interpreting the results of a para-Hisian pacing maneuver, including: (1) Was the His bundle truly directly captured? (2) Was there loss of His bundle capture with only pure right ventricular (RV) capture achieved? and (3) Was direct capture of the atrium avoided? The first 2 questions are usually addressed by the observation of a narrow QRS complex during high-output pacing and a sudden QRS complex broadening with a reduction of the pacing output. Observation of changes in the timing of a retrograde His potential is a more certain and elegant method, although using a single catheter for pacing and recording often results in a suboptimal position for recording His bundle potential. Moreover, saturation of the channel by the pacing stimulus often obscures a small His bundle potential. Direct capture of the atrium is unlikely with coronary sinus ostium VA interval >85 ms and can be excluded by shortening of the VA by >20 ms with deliberate capture of the right atrium.² All these “prerequisites” were present in

the present case, but the findings in [Figure 1](#) were misleadingly indicative of retrograde AP conduction.

The key observation in this patient was that the broad QRS complexes, initially regarded as resulting from pure RV myocardial capture, did not have a morphology compatible with pacing of the high interventricular septum. After loss of His bundle capture, the QRS complexes are always of left, not right, bundle branch morphology. The lead V₁ QRS complex should be uniformly negative, and lead I QRS complex should be a monophasic R wave, which is often slurred or notched. The phenomenon observed in [Figure 1](#) can be explained as resulting from loss of distal His bundle capture with unmasking of the underlying right bundle branch block, not as loss of direct His bundle capture. Direct His bundle pacing in the presence of bundle branch block can result in the normalization of QRS duration and morphology, especially with higher pacing output. This phenomenon, initially described by Narula in 1977, is currently observed more frequently, as the QRS complex normalizes with pacing in $\sim 70\%$ of patients with bundle branch block and permanent direct His bundle pacing.^{6,7} The classic explanation of this phenomenon involves the longitudinal

dissociation of the His bundle, in that this bundle consists of fibers that are isolated and “predestined” to form the right or left bundle fascicles, as well as His bundle capture beyond the area of the block. Because the pacing site did not change in this patient, the higher pacing amplitude likely resulted in extension of the area of direct capture beyond the level of the block in the right bundle fibers of the His bundle. Alternative explanations involving hyperpolarization and mobilization of the diseased/dysfunctional tissue with higher output have been proposed.⁸

This explanation was supported by the subsequent findings. A further reduction in pacing stimulus energy resulted in bona fide pure RV capture, characterized by further QRS prolongation to 160 ms and typical QRS morphology. This corresponded to a VA interval prolongation from 85 to 128 ms, indicating an AV nodal response (Figure 2). The patient underwent AP ablation because of the high AP catecholamine sensitivity and history of syncope, after which the para-Hisian pacing maneuver was repeated. The para-Hisian pacing results obtained after ablation were identical to those obtained before ablation. Moreover, adenosine administration during ventricular pacing confirmed lack of retrograde AP conduction. Figure 3 illustrates the proposed mechanism underlying the para-Hisian pacing results, unifying the observed VA intervals and QRS morphologies with changes in pacing output and capture of different heart structures.

Conclusion

This report describes a novel pitfall of the para-Hisian pacing maneuver: proximal His bundle capture in a patient with intra-Hisian bundle branch block mimics complete loss of His bundle capture and extranodal response.

References

1. Hirao K, Otomo K, Wang X, Beckman KJ, McClelland JH, Widman L, Gonzalez MD, Arruda M, Nakagawa H, Lazzara R, Jackman WM. Para-Hisian pacing: a new method for differentiating retrograde conduction over an accessory AV pathway from conduction over the AV node. *Circulation* 1996;94:1027–1035.
2. Obeyesekere M, Leong-Sit P, Skanes A, Krahn A, Yee R, Gula LJ, Bennett M, Klein GJ. Determination of inadvertent atrial capture during para-Hisian pacing. *Circ Arrhythm Electrophysiol* 2011;4:510–514.
3. Heidbuechel H, Ector H, Adams J, Van de Werf F. Use of only a regular diagnostic His-bundle catheter for both fast and reproducible “para-Hisian pacing” and stable right ventricular pacing. *J Cardiovasc Electrophysiol* 1997;8:1121–1132.
4. Hojo R, Fukamizu S, Sakurada H. Accurate evaluation of para-Hisian pacing in a patient with fasciculoventricular bypass. *Europace* 2014;16:1475.
5. van Opstal JM, Crijns HJ. Paradoxical increase of stimulus to atrium interval despite His-bundle capture during para-Hisian pacing. *Europace* 2009;11:1702–1704.
6. Lustgarten DL, Calame S, Crespo EM, Calame J, Lobel R, Spector PS. Electrical resynchronization induced by direct His-bundle pacing. *Heart Rhythm* 2010;7:15–21.
7. Sharma PS, Huizar J, Ellenbogen KA, Tan AY. Recruitment of bundle branches with permanent His bundle pacing in a patient with advanced conduction system disease: what is the mechanism? *Heart Rhythm* 2016;13:623–625.
8. Teng AE, Massoud L, Ajjajola OA. Physiological mechanisms of QRS narrowing in bundle branch block patients undergoing permanent His bundle pacing. *J Electrocardiol* 2016;49:644–648.