

## Long-Term Follow-Up of the Half-Turned Truncal Switch Operation for Transposition of the Great Arteries with Ventricular Septal Defect and Pulmonary Stenosis

Jong Uk Lee, M.D., Woo Sung Jang, M.D., Ph.D., Young Ok Lee, M.D., Ph.D., Joon Yong Cho, M.D.

The half-turned truncal switch (HTTS) operation has been reported as an alternative to the Rastelli or *réparation à l'étage ventriculaire* procedures. HTTS prevents left ventricular outflow tract (LVOT) obstruction in patients with complete transposition of the great arteries (TGA) with a ventricular septal defect (VSD) and pulmonary stenosis (PS), or in those with a Taussig-Bing anomaly with PS. The advantages of the HTTS procedure are avoidance of late LVOT or right ventricular outflow tract (RVOT) obstruction, and of overstretching of the pulmonary artery. We report the case of a patient who underwent HTTS for TGA with VSD and PS, in whom there was no LVOT obstruction and only mild aortic regurgitation and mild RVOT obstruction, including observations at 12-year follow-up. Our experience with long-term follow-up of HTTS supports a solution for late complications after the Rastelli procedure.

Key words: 1. Congenital heart disease, arterial switch  
2. Transposition of great vessels  
3. Heart septal defects, ventricular  
4. Pulmonary valve stenosis  
5. Half-turned truncal switch operation

### CASE REPORT

A 34-day-old male infant with cyanosis and weighing 3,900 g was referred to Kyungpook National University Hospital for surgery. Oxygen saturation was below 80% and gradually decreased to 70% at the time of operation. Echocardiography indicated a complete transposition of the great arteries (TGA) with a ventricular septal defect (VSD) and mild pulmonary stenosis (PS), with a systolic pressure gradient of 36 mmHg. The pulmonary valve was tricuspid and hypoplastic, and the pulmonary annulus measured 6.6 mm (Z-value = -1.8). The segmental anatomy by the Van Praagh classi-

fication was (S, D, D) with an anterior-posterior great artery relationship. The coronary arterial pattern was 1LCx-2R.

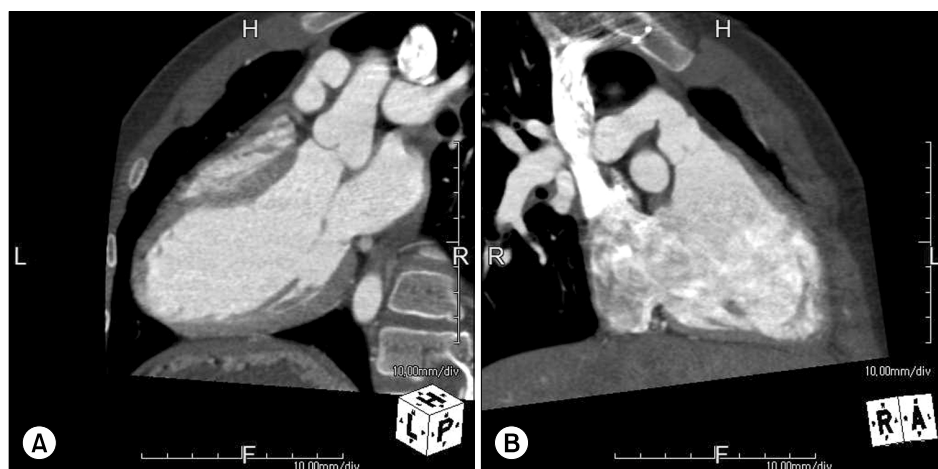
The half-turned truncal switch (HTTS) operation was performed 45 days after birth when the patient weighed 4,400 g. The small size of the conduit for the Rastelli procedure and the potential risk of left ventricular outflow tract (LVOT) obstruction were the reasons for deciding to perform the HTTS. The details of the surgical procedure for the HTTS have been reported previously [1]. In brief, the aorta was transected above the coronary orifices, and the main pulmonary artery (MPA) was incised obliquely. The anterior wall of the right ventricle was then incised along the aortic annulus following

Department of Thoracic and Cardiovascular Surgery, Kyungpook National University Hospital, Kyungpook National University School of Medicine  
Received: June 3, 2015, Revised: September 28, 2015, Accepted: September 30, 2015, Published online: April 5, 2016

Corresponding author: Woo Sung Jang, Department of Thoracic and Cardiovascular Surgery, Kyungpook National University Hospital, Kyungpook National University School of Medicine, 130 Dongdeok-ro, Jung-gu, Daegu 41944, Korea  
(Tel) 82-53-200-5832 (Fax) 82-53-426-4765 (E-mail) whiteuri@hanmail.net

© The Korean Society for Thoracic and Cardiovascular Surgery. 2016. All right reserved.

© This is an open access article distributed under the terms of the Creative Commons Attribution Non-Commercial License (<http://creativecommons.org/licenses/by-nc/4.0>) which permits unrestricted non-commercial use, distribution, and reproduction in any medium, provided the original work is properly cited.



**Fig. 1.** On a computed tomography angiogram at the 12-year follow-up. (A) Straight flow of left ventricular outflow tract and (B) straight flow of right ventricular outflow tract and stenosis of main pulmonary artery are observed.

resection of both coronary arterial buttons. The midline of the fibrous continuity between the pulmonary and mitral valves was incised after care was taken to avoid mitral valve injury. The resected truncal block was then half turned and was anastomosed to the ventricular outflow tract. After anastomosis of the aortic annulus, both coronary arteries were anastomosed. The VSD closure was performed with autologous pericardium. Angioplasty of the MPA was performed with a polytetrafluoroethylene vascular graft patch (Gore-Tex; WL Gore & Associates Inc., Flagstaff, AZ, USA). Right ventricular outflow tract (RVOT) reconstruction was not performed.

The cardiopulmonary bypass and cardiac arrest times were 207 and 134 minutes, respectively. The postoperative course was uneventful, and there was no conduction disturbance. Postoperative echocardiography at two weeks showed that the LVOT was wide without turbulence; mild aortic regurgitation (AR) and a mild systolic gradient of the pulmonary valve (PV) were seen.

Echocardiography at the two-year follow-up was without LVOT flow disturbance, and there was only trivial AR. The RVOT was widely patent, although a mild systolic gradient at the PV was detected. The flow velocities at the RVOT and MPA were 0.8 m/sec and 2.5 m/sec, respectively.

At the 12-year postoperative follow-up, the patient was free of symptoms. Echocardiography showed normal left ventricular systolic function and a widely patent LVOT without turbulence. Computed tomographic angiography showed a straightforward LVOT and RVOT (Fig. 1). Mild AR was observed as before; the annulus of the ascending aorta measured

17 mm (Z-value=0.19) and the mean flow velocity of the ascending aorta was 1.2 m/sec. The annulus of the pulmonary artery measured 16 mm (Z-value=-2.0). However, the peak velocities of the MPA and PA branches remained low (2.6 m/sec and 2.6-3.5 m/sec, respectively) due to the stenosis of the MPA (9 mm, Z-value=-5.36) and PA branches (right, 9.4 mm; Z-value=-2.09; left, 11 mm; Z-value=-0.24). Pulmonary regurgitation (PR) was not observed.

## DISCUSSION

The optimal approach to anatomic surgical repair in patients with TGA, VSD, and PS or with a Taussig-Bing anomaly with PS is controversial. The Rastelli or *réparation à l'étage ventriculaire* procedures have become standard methods in the surgical management of patients with this pathology. However, the late complication of outflow obstruction in both ventricles is a common problem associated with the Rastelli and Lecompte procedures and has prompted the consideration of other procedures [2,3]. As an alternative, the Nikaidoh procedure solves the problems of the Rastelli or *réparation à l'étage ventriculaire* procedures, but can result in serious complications, such as coronary insufficiency and subsequent myocardial damage [4]. The HTTS has been reported as an alternative to the Rastelli procedure or one of its variants [1]. However, it is very complicated and requires dedicated skills and a relatively long cardiac arrest time. Moreover, HTTS is contraindicated in patients with complex coronary patterns, such as a right coronary artery crossing the RVOT. A nor-

mal-sized pulmonary annulus is also considered a relative contraindication because of the possibility of coronary insufficiency due to stretching of arteries [3]. However, HTTS also has many advantages. Late LVOT obstruction can be avoided because of the posterior translocation of the ascending aorta and straight flow of the LVOT, unimpeded by the VSD or the intraventricular tunnel. Moreover, the HTTS procedure, by using the native aortic root, can prevent complications at the neoaorta such as dilatation, stenosis, and valve regurgitation following the TGA procedure. In addition, the risk of PR is significantly reduced by using a preserved autologous PV in conjunction with the unstretched MPA. Late RVOT obstruction can also be avoided because of elimination of the extracardiac conduit. In addition, the preserved MPA has the capability of growth throughout life.

In our patient, LVOT obstruction and significant AR were not observed, and normal LV systolic function was maintained during follow-up. Moreover, significant RVOT obstruction or regurgitation was not seen, although mild PA stenosis was observed at the final follow-up. There are few studies on the long-term follow-up results for patients undergoing the HTTS procedure. Our experience provides evidence of a solution for late complications associated with the Rastelli procedure. However, additional long-term follow-up

studies of the HTTS procedure are necessary to verify its utility and safety.

## CONFLICT OF INTEREST

No potential conflict of interest relevant to this article was reported.

## REFERENCES

1. Yamagishi M, Shuntoh K, Matsushita T, et al. *Half-turned truncal switch operation for complete transposition of the great arteries with ventricular septal defect and pulmonary stenosis.* J Thorac Cardiovasc Surg 2003;125:966-8.
2. Vouhe PR, Tamisier D, Leca F, Ouaknine R, Vernant F, Neveux JY. *Transposition of the great arteries, ventricular septal defect, and pulmonary outflow tract obstruction: Rastelli or Lecompte procedure?* J Thorac Cardiovasc Surg 1992; 103:428-36.
3. Kreutzer C, De Vive J, Oppido G, et al. *Twenty-five-year experience with rastelli repair for transposition of the great arteries.* J Thorac Cardiovasc Surg 2000;120:211-23.
4. Nikaidoh H. *Aortic translocation and biventricular outflow tract reconstruction: a new surgical repair for transposition of the great arteries associated with ventricular septal defect and pulmonary stenosis.* J Thorac Cardiovasc Surg 1984;88: 365-72.