

Antihyperlipidemic, anti-inflammatory, analgesic, and antipyretic activities of “dimethyl dimethoxy biphenyl dicarboxylate” in male Wistar rats

Heba M. I. Abdallah,
Gihan F. Asaad,
Mahmoud S. Arbid,
Yousra A. Nomier¹

Department of Pharmacology,
Division of Medical Sciences, National
Research Centre, Dokki, Giza, Egypt,
¹Department of Pharmacology and
Toxicology, Pharmacy College, Jazan
University, Jazan, Saudi Arabia

J. Adv. Pharm. Technol. Res.

ABSTRACT

Dimethyl dimethoxy biphenyl (DDB) dicarboxylate has been applied as a therapeutic modality for curing liver diseases, particularly hepatitis virus. The objective of this study was to assess the protective potential against Triton X-100 induced abnormal fat metabolism in addition to anti-inflammatory, analgesic, and antipyretic effects of DDB. The anti-inflammatory, antinociceptive, and antipyretic of DDB were investigated through induction of paw edema, pain, and fever in experimental rats. DDB decreased cholesterol and triglyceride contents. DDB resulted in inhibition of inflammation, nociception, and fever in the experimental models. DDB improved lipid profile, as evidence of hypolipidemic potential. It also showed anti-inflammatory, analgesic, and antipyretic properties.

Key words: Analgesic, antipyretic, antihyperlipidemic, anti-inflammatory, dimethyl dimethoxy biphenyl dicarboxylate, Triton X-100

INTRODUCTION

Lipid disorders associated with hyperlipidemia increase exposure to atherosclerosis, subsequent vascular disease, and cardiovascular diseases,^[1] as well as increasing the probability of hepatic steatosis and malignant melanoma.^[2] Hyperlipidemia is manifested by the increase in serum total cholesterol (TC), low-density lipoprotein (LDL), and very-LDL, and a decrease in high-density lipoprotein levels, which are the main causes of cardiovascular events for cardiovascular.^[3] Triton X-100 is used to induce

hyperlipidemia and is a well-known animal model for screening of the antihyperlipidemic effect of both natural and synthetic agents.^[4] Unfortunately, most of the hypolipidemic drugs in markets have been implicated in deleterious side effects.^[5] The “lipid” and “inflammation” hypotheses are closely interconnected as their recorded data that support inflammation was parallel to those supporting LDL cholesterol. Moreover, statins efficacy was determined by significant amelioration of LDL cholesterol and C-reactive protein.^[6] Although statins may lead to detrimental effects, such as severe muscle pain, hepatic, and renal failure.^[5] Therefore, it is essential to find new sources of determined hypolipidemic agents and lacking possible therapeutic complications. In our research, we are going to explain the ameliorative effect of dimethyl dimethoxy biphenyl (DDB) against triton-induced hyperlipidemia, carrageenan-induced inflammatory, hot plate-induced

Address for correspondence:

Dr. Yousra A. Nomier,
Department of Pharmacology and Toxicology, Pharmacy
College, Jazan University, P O Box 114, Jizan 45142,
Saudi Arabia.
E-mail: yousra.nomier@yahoo.com

Submitted: 02-Oct-2021

Revised: 18-Dec-2021

Accepted: 11-Jan-2022

Published: 07-Apr-2022

Access this article online

Quick Response Code:



Website:

www.japtr.org

DOI:

10.4103/japtr.japtr_292_21

This is an open access journal, and articles are distributed under the terms of the Creative Commons Attribution-NonCommercial-ShareAlike 4.0 License, which allows others to remix, tweak, and build upon the work non-commercially, as long as appropriate credit is given and the new creations are licensed under the identical terms.

For reprints contact: WKHLRPMedknow_reprints@wolterskluwer.com

How to cite this article: Abdallah HM, Asaad GF, Arbid MS, Nomier YA. Antihyperlipidemic, anti-inflammatory, analgesic, and antipyretic activities of “dimethyl dimethoxy biphenyl dicarboxylate” in male Wistar rats. *J Adv Pharm Technol Res* 2022;13:83-8.

nociception as well as brewer's yeast-induced fever. DDB is an analog of Schizandrin C, available as a Chinese remedy extracted from *Fructus Schizandrae*.^[7] DDB was recorded previously to exert a hepatoprotective as well as antioxidant efficacy along with anti-inflammatory properties.^[8,9]

MATERIALS AND METHODS

Drugs and chemicals

1) Pure DDB powder was purchased from Arabic company of Pharmaceutical and Medicinal Plants (Egypt). 2) Triton™ X-100, Paracetamol (purity 99.9%) and carrageenan were purchased from Sigma-Aldrich (St. Louis, MO, USA). 3) Indomethacin capsules were purchased from Kahira Pharm and Chem IND. CO. (Cairo, Egypt). 4) Tramadol hydrochloride (purity \geq 99.3%) was purchased from Grünenthal Ltd. (Aachen, Germany). 5) Diagnostic kits (TC, triglycerides (TG), aspartate transaminase (AST), and alanine transaminase (ALT) enzymes were purchased from Bio diagnostic Company (Giza, Egypt).

Animals and care

Male Wistar rats weighing (150–170 g) were provided by the animal breeding unit at the National Research Centre (NRC). All instructions of the ethical committee of NRC were followed accurately during animal handling following "National Institutes of Health (NIH) Guide and Use of Laboratory Animals" (NIH Publications No. 8023, revised 1978). All the experiments have been approved by the ethics committee of the NRC ensuing the European Economic Area agreement applying the EU directive 2010/63/EU for laboratory animal shielding.

Experimental design

Triton X-100-induced hyperlipidemia

Hyperlipidemia was induced using Triton X-100 according to Kim *et al.*^[7] Forty-eight hours after Triton X-100 injection, from the retro-orbital venous plexus of rats blood, was collected under anesthesia (ketamine 40 mg/kg),^[10] and serum was separated in Eppendorf Tubes and kept for determination of (TC, TG, AST, and ALT) using commercially available kits.

Histopathological studies

Under anesthesia, scarification was applied by cervical dislocation; liver tissue was removed and kept in formalin. For the histopathological aim section, thickness of 5 μ m was stained with hematoxylin and eosin.

Anti-inflammatory, central analgesic, and antipyretic effects of dimethyl dimethoxy biphenyl

Carrageenan-induced paw edema was performed as follows:^[11,12] antinociceptive efficacy of DDB was performed following the method of Turner (1965).^[13] Antipyretic efficacy of DDB was performed following the protocol of Roszkowski *et al.*^[14]

Data analysis

All results (mean \pm SE) were analyzed using one-way analysis of variance and then by the Tukey-Kramer test for confirmation.

RESULTS

Effect of dimethyl dimethoxy biphenyl on serum lipid profile (total cholesterol and triglycerides)

Rats injected with Triton X-100 significantly ($P < 0.05$) increased TC and TG level (175.6 ± 7.22 and 138.9 ± 9.88 mg/dl), respectively, in correlative to the control group (69.64 ± 1.03 and 62.39 ± 1.37 mg/dl), respectively. On the other hand, group-administered DDB + Triton X-100 significantly decreased TC and TG (91.16 ± 4.39 and 78.98 ± 1.00 mg/dl), respectively, showing (1.92- and 1.75-fold decrease), respectively, in comparison to the Triton X-100 group. Hyperlipidemia was a result of the reduction of TC and TG evidenced a potent hypolipidemic of DDB against Triton X-100 as dissipated in Figure 1.

Effect of dimethyl dimethoxy biphenyl on serum liver enzymes (alanine transaminase and aspartate transaminase)

The group injected with Triton X-100 significantly ($P < 0.05$) increased ALT and AST levels (89.18 ± 1.19 and 237.18 ± 3.74 U/L) sequentially correlate to the control group (40.03 ± 1.58 and 95.65 ± 1.85 U/L). On the other hand, group-administered DDB + Triton X-100 significantly ($P < 0.05$) decreased ALT and AST levels (54.67 ± 1.71 and 198.2 ± 1.96 U/L), respectively, showing (1.79 and 1.2-fold decrease) in comparison to the control positive group (Triton-x-100) [Figure 2].

Histopathological studies

The normal control group showed normal-sized noncongested central vein with preserved hepatic architecture with one and two hepatocytes thickness [Figure 3a]. The Triton X-100 group showed massive lipid infiltrations of hepatocytes in the three hepatic zones but minimal at zone three. Areas of necrosis and lymphocytic infiltrate were also detected. Engorged and dilated central veins were observed with sinusoidal congestion [Figure 3b]. DDB + Triton X-100 section examination revealed normally looking at hepatocytes in zones two and three. Limited lipid infiltrated hepatocytes were seen in zone one. Sinusoidal congestion was diminished. The central veins were congested but not dilated [Figure 3c].

The normal control group showed normal-sized noncongested central veins with preserved hepatic architecture with one and two hepatocytes thickness-A1 (100 \times) and A2 (400 \times). Triton X-100-treated rats showed massive lipid infiltrations of hepatocytes in the three hepatic zones but minimal in the zone there. Areas of necrosis and lymphocytic infiltration were also detected. Engorged and dilated central veins were observed with sinusoidal congestion B1 (\times 40) and B2 (\times 400).

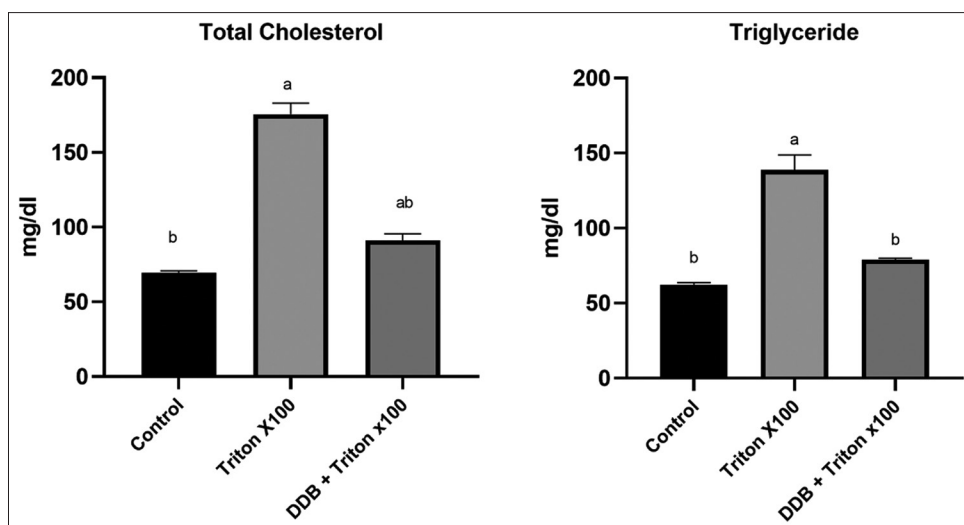


Figure 1: Results (mean \pm SE) ($n = 6$), ^a $P < 0.05$ was representing significance. ^a $P < 0.05$ versus control group, ^b $P < 0.05$ versus Triton X-100

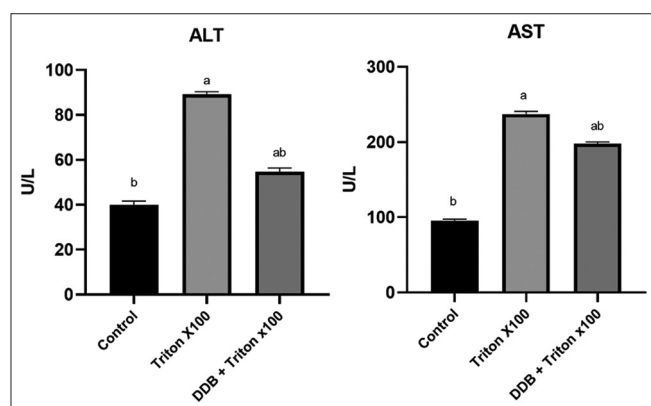


Figure 2: Results are mean \pm SE. ($n = 6$), ^a P value of < 0.05 was representing significance. ^a $P < 0.05$ versus control group, ^b $P < 0.05$ versus Triton X-100

DDB + Triton X-100 section examination revealed normally looking hepatocytes at zones two and three. Limited lipid infiltrated hepatocytes were seen in zone one. Sinusoidal congestion was diminished. Central veins were congested but not dilated C1 ($\times 100$) and C2 ($\times 400$).

Anti-inflammatory effect of dimethyl dimethoxy biphenyl

200 mg/kg DDB showed a % of inhibition (23.34%, 27.79%, 35.16%, and 28.86%) as compared to control group and exerting potency % (458.54%, 90.81%, 88.21%, and 78.74%) as correlated to standard group (indomethacin 10 mg/kg). It was obvious that the highest anti-inflammatory potency for DDB was reported after the 1st h following carrageenan injection as the edema rate was significantly ($P < 0.05$) inhibited as correlated to the standard drug (indomethacin). It was worthy to note that the anti-inflammatory potency and inhibition rate of DDB remain significant as correlated to the control group showing a substantial % inhibition (28.86%) and potency (78.74%). The data are dissipated in Table 1.

Antinociception effect of dimethyl dimethoxy biphenyl

After 30 minutes, group treated with DDB showed a significant increase in latency period (30.62 ± 1.74 s) (208%) as compared to control group and showing 1.28-fold increase than standard group treated with tramadol (23.9 ± 0.75 s) (163%) compared to control group. Similarly, after 60 min, the latency response of the group given DDB (33.12 ± 2.66 s) (216%) increased significantly as compared to the control group showing a 1.4-fold increase in latency period as compared to the tramadol group (22.64 ± 0.66 s) (148%) compared to the control. Data are illustrated in Figure 4.

Antipyretic effects of dimethyl dimethoxy biphenyl

Animals administered DDB and paracetamol experienced a slight decrease in rectal temperature beginning from 60 min following injection with the drugs; however, these reductions were not significant ($P < 0.05$) in correlation to the control group. After 90 min of drug injections, only DDB showed a remarkable ($P < 0.05$) reduction in temperature ($37.06 \pm 0.35^\circ\text{C}$) in comparison to the control group, and after 120 min, both DDB and paracetamol groups showed significant ($P < 0.05$) reduction in temperature (36.78 ± 0.19 and $36.72 \pm 0.22^\circ\text{C}$ sequentially) as correlated to control ($38.52 \pm 0.2^\circ\text{C}$), but no significant difference between DDB and paracetamol effects was recorded. Data are illustrated in Figure 5.

DISCUSSION

Hypolipidemic drugs such as statins had achieved success in managing hyperlipidemia; however, some detrimental side effects acquired detailed monitoring such as myopathy, sleep disturbance, headache, impairment of liver function tests, and creatinine phosphokinases.^[15] In addition, the major alternative modalities for statins such as fibrates, nicotinic acid, and bile acid sequestrants also showed many adverse effects.^[16] Available data supporting the role of

Table 1: Anti-inflammatory effect of dimethyl dimethoxy biphenyl dicarboxylate against carrageenan-induced inflammation

Group	1 h		2 h		3 h		4 h	
	Edema rate (%)	Potency (%)	Edema rate (%)	Potency (%)	Edema rate (%)	Potency (%)	Edema rate (%)	Potency (%)
Control (carrageenan)	43.96±1.43	-	57.31±2.08 ^b	-	96.49±3.73 ^b	-	98.79±3.7 ^b	-
DDB (200 mg/kg) + Carrageenan	33.7±2.93 ^{a,b} (23.34)	458.54	41.39±4.01 ^a (27.79)	90.81	62.57±6.13 ^a (35.16)	88.21	70.27±3.45 ^a (28.86)	78.74
Indomethacin (10 mg/kg)	41.72±0.64 (5.09)	100	39.78±0.28 ^a (30.6)	100	58.03±0.95 ^a (39.86)	100	62.58±3.73 ^a (36.65)	100

Data are presented as mean±SE (n=6). $P < 0.05$ was representing significance, ^a $P < 0.05$ versus control group, ^b $P < 0.05$ versus indomethacin. Values in brackets indicate the percentage inhibition rate. Calculations of potency were in comparison to indomethacin as a reference drug. DDB: Dimethyl dimethoxy biphenyl dicarboxylate, SE: Standard error

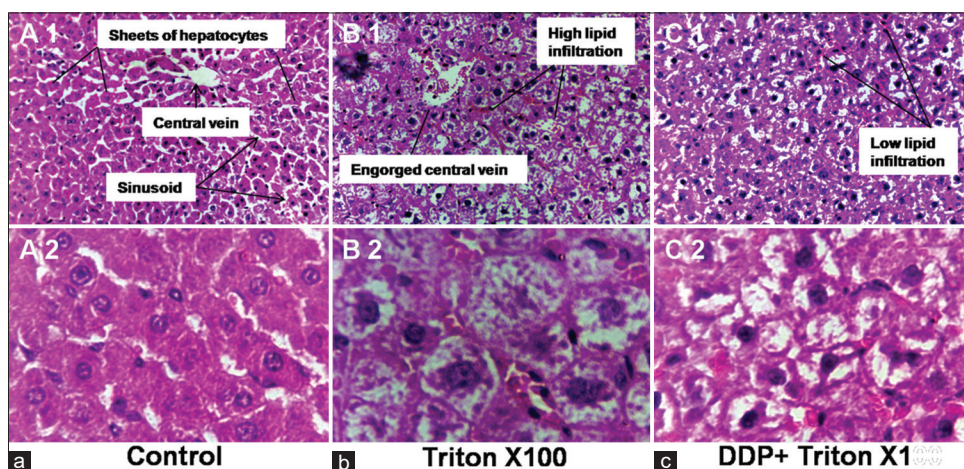


Figure 3: Effect of dimethyl dimethoxy biphenyl on liver histopathology. Normal control group (3a), Triton X-100 group (3b) and DDB+ Triton X-100 group (3c)

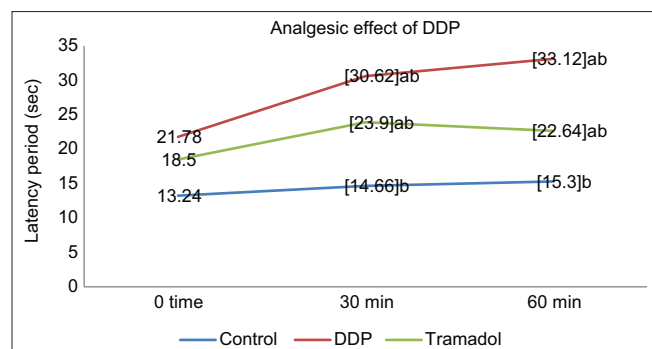


Figure 4: Results are mean ± SE. (n = 6), ^a $P < 0.05$ was representing significance. ^a $P < 0.05$ versus control group, ^b $P < 0.05$ versus tramadol

DDB as an effective hepatoprotective drug is plentiful, but so far, its effect in modulation of hyperlipidemia, edema, pain, and pyrexia was still unknown. Hence, our current study aimed to address the potential hypolipidemic DDB against Triton×-100 causing hyperlipidemia, paw edema caused by carrageenan, thermal-induced nociception, and brewer's yeast-induced pyrexia.

The hyperlipidemic effect of triton had been attributed to its ability to inhibit the destructive metabolism of triacylglycerol-rich lipoproteins through lipoprotein

lipase, so, it blocks the elimination of triacylglycerol from the plasma.^[17] It was also reported in previous studies that in addition to the hyperlipidemic effect of Triton X-100, it could exert oxidative metabolic activity leading to prominent oxidative damage in liver and brain tissues. Al-Awadi *et al.*,^[18] reported that Triton X-100 caused a liver injury which was evidenced by remarkable increase in lipid peroxidation in liver tissues and remarkably reduced glutathione which is mainline of defense against the oxidative injury induced by Triton X-100. The reduction of glutathione was also implicated in the inactivation of enzymes due to the protein damage caused by lipid peroxidation.^[19] Thus, the hypolipidemic potency might be attributed to the antioxidative effect which was evidenced by significant amelioration of the impaired lipid profile in hyperlipidemic rats.^[20] In the current study, the liver injury was evidenced by the significant elevation of liver transaminases (ALT and AST) and histopathological changes as a result of intraperitoneal injection of Triton X-100. Osman *et al.*^[21] who attributed these impairments to the extent of tissue injury triggered by hypercholesterolemia were concerned about these results. DDB reveals a remarkable reduction in serum ALT and AST that refers to the ability of DDB to shield liver cells against tissue injury reported as a consequence of Triton X-100 injection.

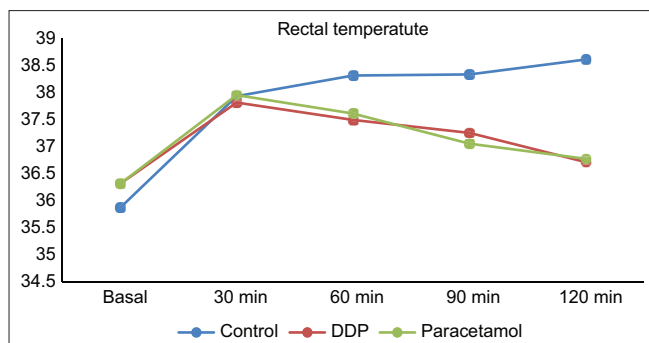


Figure 5: Results are mean \pm SE. ($n = 6$), $^aP < 0.05$ was representing significance. $^aP < 0.05$ versus control group, $^bP < 0.05$ versus paracetamol

The histopathological changes observed in our study were corroborated with those of Gundamaraju *et al.*,^[4] and Hashem *et al.*^[22]

Previous studies have verified that the anti-inflammatory effect of DDB was attributed to the capability to reduce NF- κ B activation and tumor necrosis factor- α exhibition.^[9,23] In running an investigation, we also examined the possible central analgesic effect^[24] as compared to the opioid analgesic tramadol using the hot plate method.^[25] The potent and prolonged duration of analgesic activity of DDB as compared to tramadol was attributed to its high protein binding affinity. The central analgesic effect of opioid analgesics is mediated by their effect on opioid receptors.^[26,27] The antipyretic action of DDB could be due to a reduction in prostaglandin levels and pro-inflammatory mediators.^[25]

CONCLUSIONS

As per our findings, we recommend the use of DDB as a potent hypolipidemic, anti-inflammatory, analgesic, and antipyretic agent.

Financial support and sponsorship

Nil.

Conflicts of interest

There are no conflicts of interest.

REFERENCES

- Sudha SS, Karthi R, Rengaramanujam J. Anti hyperlipidemic activity of *Spirulina platensis* in Triton x-100 induced hyperlipidemic rats. *Hygeia J Drugs Med* 2011;3:32-7.
- Woo MN, Bok SH, Choi MS. Hypolipidemic and body fat-lowering effects of Fatclean in rats fed a high-fat diet. *Food Chem Toxicol* 2009;47:2076-82.
- Cox RA, Garcia-Palmieri MR. Cholesterol, Triglycerides, and Associated Lipoproteins In: Walker, HK; Hall, WD; Hurst, JW (ed) *Clinical Methods: The History, Physical, and Laboratory Examinations* 1990.
- Gundamaraju R, Hwi KK, Singla RK, Vemuri RC, Mulapalli SB.

Antihyperlipidemic potential of *Albizia amara* (Roxb) Boiv. bark against Triton X-100 induced hyperlipidemic condition in rats. *Pharmacognosy Res* 2014;6:267-73.

- Golomb BA, Evans MA. Statin adverse effects: A review of the literature and evidence for a mitochondrial mechanism. *Am J Cardiovasc Drugs* 2008;8:373-418.
- Braunwald E. Creating controversy where none exists: The important role of C-reactive protein in the CARE, AFCAPS/TexCAPS, PROVE IT, REVERSAL, A to Z, JUPITER, HEART PROTECTION, and ASCOT trials. *Eur Heart J* 2012;33:430-2.
- Kim SN, Kim SY, Yim HK, Lee WY, Ham KS, Kim SK, *et al.* Effect of dimethyl-4,4'-dimethoxy-5,6,5',6'-dimethylenedioxybiphenyl-2,2'-dicarboxylate (DDB) on chemical-induced liver injury. *Biol Pharm Bull* 1999;22:93-5.
- el-Sawy SA, el-Shafey AM, el-Bahrawy HA. Effect of dimethyl diphenyl bicarboxylate on normal and chemically-injured liver. *East Mediterr Health J* 2002;8:95-104.
- Morsy MA, Ibrahim MA, Abd-Elghany MI. Dimethyl dimethoxy biphenyl dicarboxylate attenuates hepatic and metabolic alterations in high fructose-fed rats. *Toxicol Ind Health* 2016;32:59-67.
- Grimm KA, Lamont LA, Tranquilli WJ, Greene SA, Robertson SA. *Veterinary Anesthesia and Analgesia: The Fifth Edition of Lumb and Jones*. Wiley-Blackwell (Hoboken, New Jersey, USA); 2017.
- Winter CA, Risley EA, Nuss GW. Carrageenin-induced edema in hind paw of the rat as an assay for anti-inflammatory drugs. *Proc Soc Exp Biol Med* 1962;111:544-7.
- Abdelhameed MF, Asaad GF, Ragab TI, Ahmed RF, El Gendy AE, Abd El-Rahman SS, *et al.* Oral and topical anti-inflammatory and antipyretic potentialities of *Araucaria bidiwillii* shoot essential oil and its nanoemulsion in relation to chemical composition. *Molecules* 2021;26:5833.
- Grimm H, Turner, Robert A.: *Screening methods in pharmacology*. Academic Press, New York, London 1965. XV+332 S., 51 Tab. Preis \$ 12,-. *Biometrical J* 1968;10:93-4.
- Roszkowski AP, Rooks WH 2nd, Tomolonis AJ, Miller LM. Anti-inflammatory and analgetic properties of d-2-(6'-methoxy-2'-naphthyl)-propionic acid (naproxen). *J Pharmacol Exp Ther* 1971;179:114-23.
- Al Mamun A, Hashimoto M, Katakura M, Tanabe Y, Tsuchikura S, Hossain S, *et al.* Effect of dietary n-3 fatty acids supplementation on fatty acid metabolism in atorvastatin-administered SHR.Cg-Lepr^{cp}/NDmcr rats, a metabolic syndrome model. *Biomed Pharmacother* 2017;85:372-9.
- Rang HP, Ritter JM, Flower RJ, Henderson G. Rang & Dale's *Pharmacology: With Student Consult Online Access*. Elsevier health sciences (churchill livingstone); 2014. p. 776.
- Shrivastava A, Chaturvedi U, Singh SV, Saxena JK, Bhatia G. Lipid lowering and antioxidant effect of miglitol in triton treated hyperlipidemic and high fat diet induced obese rats. *Lipids* 2013;48:597-607.
- Al-Awadi J, Rashid K, Hassen A. High fat diet induces hyperlipidemia incidences with sever changes in liver tissue of male albino rats: A histological and biochemical study. *Karbala J Pharm Sci* 2013;6:21-32.
- Saxena R, Garg P, Jain DK. *In vitro* anti-oxidant effect of vitamin E on oxidative stress induced due to pesticides in rat erythrocytes. *Toxicol Int* 2011;18:73-6.
- Parwin A, Najmi AK, Ismail MV, Kaundal M, Akhtar M. Protective effects of alendronate in Triton X-100-induced hyperlipidemia in rats. *Turk J Gastroenterol* 2019;30:557-64.
- Osman M, Fayed SA, Mahmoud GI, Romeilah RM. Protective effects of chitosan, ascorbic acid and gymnema sylvestre against hypercholesterolemia in male rats. *Aust J Basic Appl Sci* 2010;4:89-98.



22. Hashem MA, Abd-Allah NA, Mahmoud EA, Amer SA, Alkafafy M. A preliminary study on the effect of psyllium husk ethanolic extract on hyperlipidemia, hyperglycemia, and oxidative stress induced by Triton X-100 injection in rats. *Biology (Basel)* 2021;10:335.
23. El-Bahy AA, Kassem LA, Heikal OA, Mahran LG. Antiapoptotic effect of DDB against hepatic ischemia-reperfusion injury. *J Toxicol Sci* 2011;36:145-54.
24. Jokinen V, Lilius T, Laitila J, Niemi M, Kambur O, Kalso E, *et al.* Do diuretics have antinociceptive actions: Studies of spironolactone, eplerenone, furosemide and chlorothiazide, individually and with oxycodone and morphine. *Basic Clin Pharmacol Toxicol* 2017;120:38-45.
25. Shah M, Parveen Z, Khan MR. Evaluation of antioxidant, anti-inflammatory, analgesic and antipyretic activities of the stem bark of *Sapindus mukorossi*. *BMC Complement Altern Med* 2017;17:526.
26. Spahn V, Del Vecchio G, Rodriguez-Gaztelumendi A, Temp J, Labuz D, Klöner M, *et al.* Opioid receptor signaling, analgesic and side effects induced by a computationally designed pH-dependent agonist. *Sci Rep* 2018;8:8965.
27. Kumatia EK, Appiah-Opong R. The hydroethanolic stem bark extract of *Tieghemella heckelii* (A.Chev.) pierre ex dubard (Sapotaceae) produced N-Methyl-D-aspartate (NMDA) receptor-dependent analgesia and attenuates acute inflammatory pain via disruption of oxidative stress. *Evid Based Complement Alternat Med* 2021;2021:3466757.