

Available online at www.sciencedirect.com

ScienceDirect

journal homepage: www.elsevier.com/locate/radcr

Case report

CT features of Wolman disease (lysosomal acid lipase enzyme deficiency) – A case report ☆☆☆★★

Naqibullah Foladi, MD^{a,1,*}, Mohammad Tahir Aien, MD^b^a Department of Radiology, French Medical Institute for Mothers and Children (FMIC), 3rd district, Kabul, Afghanistan^b Department of Radiology, Kabul University of Medical Sciences (KUMS), Kabul, Afghanistan

ARTICLE INFO

Article history:

Received 14 May 2021

Revised 24 June 2021

Accepted 26 June 2021

Keywords:

Wolman disease

Acid lipase enzyme

Lysosomal storage disease

Case report

ABSTRACT

Wolman disease is a lethal rare autosomal recessive disorder defined by the deficiency of acid lipase enzyme. The disease is a lysosomal storage disease. Multiple organs such as adrenal glands, liver, spleen, bone marrow, small bowel loops, and abdominal lymph nodes are infiltrated by the deposition of lipids. Infants generally present with failure to thrive, abdominal distention, vomiting, steatorrhea, and hepatosplenomegaly. Authors' present a 1 month-old male infant with abdominal distention and failure to thrive who was referred for abdomen CT scan. The CT scan revealed stippled calcifications of both enlarged adrenal glands, without the distortion of the adreniform shape, fatty liver, splenomegaly and thickened small bowel loops; characteristic imaging findings of Wolman disease. CT scan is the imaging modality of choice for the recognition of the disease. There is no definite cure explained yet. Further studies are required to find the definite treatment of the disease.

© 2021 The Authors. Published by Elsevier Inc. on behalf of University of Washington.

This is an open access article under the CC BY-NC-ND license

(<http://creativecommons.org/licenses/by-nc-nd/4.0/>)

Background

Wolman disease, a lysosomal storage disease, is a rare autosomal recessive disorder characterized by the deficiency of acid lipase enzyme activity [1–4] secondary to a mutation in LIPA gene [3]. Infants present with abdominal distension, vomit-

ing, failure to thrive, steatorrhea [3], and hepatosplenomegaly [1]. Due to the absence of acid lipase enzyme activity, lipids accumulate in adrenal glands, liver, spleen, bone marrow, small bowel [1,2,4], and even vascular endothelium, causing atherosclerosis [3]. The pathognomonic appearance of the disease is enlarged bilateral adrenal calcifications with preserved shape [3]. CT scan is the imaging modality of choice for the

Abbreviations: CT, Computed Tomography; MRI, Magnetic Resonance Imaging.

☆ Acknowledgments: Not applicable

☆☆ Competing interests: The authors declare that they have no competing interests.

* Availability of data and materials: Data sharing is not applicable to this article as no datasets were generated or analyzed during the current study (as this is a case report).

** Funding: Not applicable

* Corresponding author.

E-mail address: Naqibfoladi@gmail.com (N. Foladi).¹ Twitter: @naqibfoladi<https://doi.org/10.1016/j.radcr.2021.06.084>1930-0433/© 2021 The Authors. Published by Elsevier Inc. on behalf of University of Washington. This is an open access article under the CC BY-NC-ND license (<http://creativecommons.org/licenses/by-nc-nd/4.0/>)

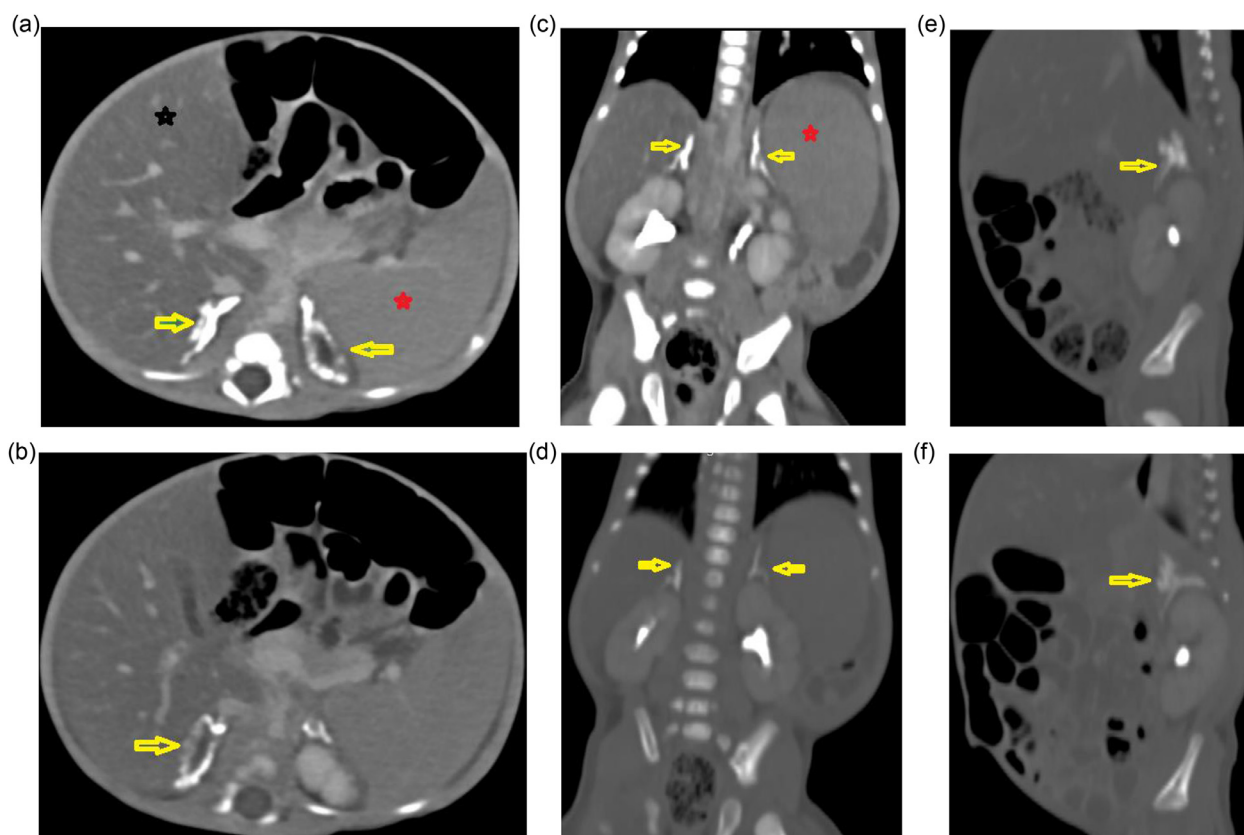


Fig. 1 – (A-F): Selected axial, coronal and sagittal contrast-enhanced abdomen CT scan soft tissue and bone window images demonstrating demonstrating enlarged adrenal glands with stippled cortical calcifications preserving their adreniform shape (yellow arrows), fatty liver (black asterisk), and enlarged spleen (red asterisk). (Color version of figure is available online.)

evaluation of Wolman disease [4]. The typical CT features are enlargement and adreniform calcification of both adrenal glands. The morphology of adrenal glands is preserved in the disease [2,4,5]. Additional CT findings are hepatomegaly with fat infiltration, splenomegaly [2], and hypoattenuating enlarged mesenteric lymph nodes [4,5]. The prognosis of Wolman disease is severely poor, and patient demise occurs in the first year of life [1–4]. The imaging features are important for the recognition of the disease. No evidence was found in English literature regarding the calcification and enlargement of bilateral adrenal glands retaining their adreniform shape, apart from the Wolman disease. No definite treatment is explained yet. Further studies are needed to explore the treatment of the disease.

Case presentation

A 1-month-old male child was brought to the radiology department for an abdomen CT scan. The patient had a history of abdominal distension and malabsorption. Physical examination revealed hepatosplenomegaly. There was no pertinent prior medical, family, and psycho-social history including any genetic predisposition. No pertinent prior interventions were

noted. Limited available lab values were present showing anemia (8mg/dl) and leukopenia (4000/mm³). The platelet count was in normal range (200,000/mcl). The patient was coming from a poor socioeconomic status, lacking all the necessary lab examinations. No histopathologic or detailed hematologic workup was performed until the imaging diagnosis of the disease. Abdomen CT scan revealed diffuse calcifications and enlargement of both adrenal glands but retaining normal morphology. (Fig. 1A - F) The liver was enlarged in size showing diffuse hypoattenuation, representing fat infiltration. Enlargement of the spleen was also visualized. The small bowel loops were demonstrating mural thickening and hyperenhancement. (Fig. 2A-D). Additionally, small ascites was present. The patient was lost to follow up after imaging diagnosis.

Discussion

Wolman disease is a rare autosomal recessive disorder first described by Moshe Wolman in 1956. The disease is characterized by a deficiency of acid lipase enzyme in lysosomes [1–3,6] presenting in infancy [4].

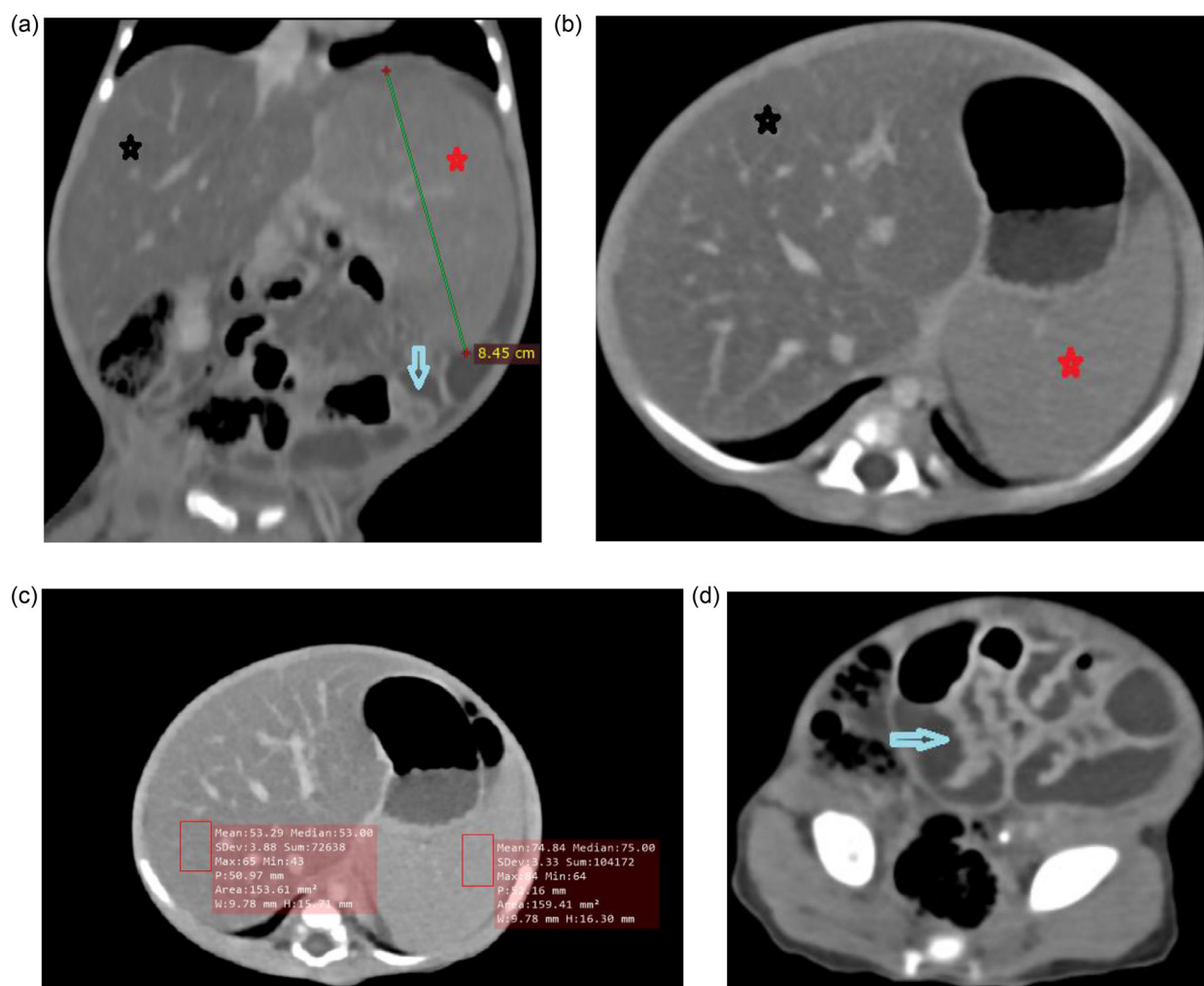


Fig. 2 – Selected axial and coronal contrast-enhanced abdomen CT scan images demonstrating fatty liver (black asterisk), splenomegaly (red asterisk), hyperenhancing thickened small bowel loops (blue arrows), and perisplenic ascites. Selected axial contrast-enhanced abdomen CT scan demonstrating the Hounsfield units of liver and spleen. (Color version of figure is available online.)

The incidence of Wolman disease is 1 in 500,000 live births [3]. Iranian, Ashkenazi Jewish, and German are commonly affected by the disease [3].

The mutation occurs on a gene present on chromosome 10q23.2-q23.2 [1,6]. There are variable degrees of mutations of the gene, but a mutation with complete functional loss of the acid lipase enzyme results in Wolman disease. In cholesterol ester storage disease, partial mutation of the involved gene is seen, which is not as severe as the Wolman disease [1,3].

In elderly patients, the disorder is known as cholesteryl ester storage disease [2]. The activity of acid lipase enzyme is less than 1% in Wolman disease, but there is a partial activity in cholesterol ester storage disorder, about 1%–12%. These findings are corresponding to variable degrees of clinical presentations [3]. The function of lysosomal acid lipase is the hydrolysis of triglycerides and cholesterol esters before entering cells [1]. Due to error in the acid lipase activity in the lipid metabolism, the cholesteryl esters and triglycerides

deposit within the liver, spleen, mucosa and external layers of the small bowel, and the cortex of adrenal glands [1,2,4]. These patients may also develop atherosclerosis because of the deposition of lipids in the vessels [3].

Stippled calcification of the adrenal cortex is a typical pattern of Wolman disease [1,6].

The adrenal glands enlarge and calcify with a characteristic pattern of calcification involving zona reticularis and inner fasciculata but sparing zona glomerulosa, and outer fasciculata, and medulla. The cells in the adrenal cortex are synthesizing steroids and receive high amounts of LDL (Low density lipoproteins) eventually resulting in cellular death with subsequent calcification. The necrosis and calcification of the cells in the adrenal cortex may cause insufficiency in the production of essential hormones responsible for blood pressure, metabolism, and immunity [2]. The process of saponification and excessive fat deposition in the adrenal cortex is responsible for the enlargement and extensive calcification of adrenal glands [4–6].

The affected children are born on term, usually to consanguineous parents [1]. Children present in the early months of life with hepatosplenomegaly and enlarged abdominal lymph nodes, because of the aggregation of lipids within the cells of mentioned organs [2,5].

Foam cells are the macrophages that have engulfed the lipids and can be found within the liver, spleen, lymph nodes [6], and bone marrow of the affected patients [2]. Swollen Kupfer cells are responsible for the hepatomegaly [1]. Not only the reticuloendothelial system is affected, but anywhere histiocytes are present such as the cardiovascular system, and brain. The villi of the small intestine are severely infiltrated by foam cells [1,6]. The dilatation and thickening of the small bowel loops are because of the accumulation of foam cells in the lamina propria [2,6].

Early clinical features in Wolman disease include failure to thrive, vomiting, abdominal distension, steatorrhea [3], and hepatosplenomegaly [1]. Late complications are hepatic cirrhosis and respiratory failure [1]. Amongst the patients with Wolman disease, 9 of them had liver biopsies demonstrating liver fibrosis [3].

The diagnosis of Wolman disease is based on both lab and radiologic examinations [4]. The hallmark of Wolman disease is the calcification of enlarged both adrenal glands outlining the glands and is pathognomonic for the disease [3,6]. Calcification of adrenal glands is seen in about half of cases [3]. Blood tests can give a wide range of abnormalities including elevated levels of triglycerides and cholesterol [3,4] as well as anemia, low platelets, low albumin, deranged clotting, elevated bilirubin, and deranged liver function tests [1]. Increased lymphocytes in peripheral blood smear and vacuolated macrophages in bone marrow aspirates are expected [1,4,6]. Elliptical cholesterol clefts are visualized on liver biopsies [1] only to be noted in Wolman disease [6]. Wolman disease can be confirmed by culturing skin fibroblasts and the assay of acid lipase enzyme in white blood cells [6]. Different imaging modalities are used to diagnose the disease, such as ultrasound, abdomen radiograph, contrast-enhanced abdomen CT scan [4] and MRI [6]. Abdomen x-ray may show calcification of adrenal glands, and enlarged hepatic shadow. In abdomen ultrasound both adrenal glands are enlarged with calcifications [2]. The contrast-enhanced abdomen CT scan is the imaging modality of choice for the diagnosis of the disease [4]. The typical CT features are symmetric enlargement of both adrenal glands with extensive calcification but preserved adrenal morphology [2,4,5]. Additional features include enlarged fatty liver, and splenomegaly without any mass effects [2], low attenuating abdominal enlarged lymph nodes [4,5] as well as thickening of small bowel loops [6]. CT scan also can reveal late-stage complications of Wolman disease such as liver cirrhosis and portal hypertension [1]. Low T1 and T2 signal intensities of adrenal glands are seen on abdomen MRI representing calcifications [2,5,6]. Moreover, the fatty portion of enlarged adrenal glands would return T1WI and T2WI signal intensities similar to abdominal fat [6].

There is a broad differential in adrenal calcification, but in Wolman disease, adrenal glands are uniformly enlarged with calcifications within the adrenal cortex on both sides, with preserved adreniform shape. The other etiologies resulting in the bilateral adrenal calcifications are adrenal hemor-

rhages, tumors and infections [6]. The calcifications of adrenal glands other than Wolman disease can cause either smaller or normal-sized glands such as in adrenal hemorrhage and granulomatous disease [2]. In neuroblastoma, neoplastic growth of the adrenal gland is seen, with internal specks of calcification. In adrenal hemorrhage, the adrenal gland is shrunken with nonuniform globular calcification [1,6].

Wolman disease is almost always lethal in the first year of life [1–4]. The main cause of death is malabsorption and diarrhea [1,2]. Generalized lipid deposition may result in multiple organ failure [2].

There is no cure for the disease available yet. The therapeutic approach is to reduce the complications and conducting parenteral nutrition, steroids, and dietary supplements [4–6]. Diets free of fatty-esters can prevent steatorrhea [2,6]. Bone marrow transplantations are inconclusive [2,4].

Our patient was a 1 month old infant with characteristic CT features of Wolman disease, such as the enlargement and stipple calcification of both adrenal glands, accompanied by enlarged fatty liver, splenomegaly, enlarged abdominal lymph nodes and thickening of the small bowel loops. Imaging findings are characteristic for the recognition of the disease. No other lysosomal storage diseases, infection, or neoplasms can express the constellation of the above findings. The adrenal glands that are calcified in other diseases either shrinks or preserves normal size, but in Wolman disease, the adrenal glands enlarge bilaterally. In Wolman disease, the pattern of calcification is stippled and cortical, outlining the boundaries of the adrenal glands, but in opposite, the type of calcification is non uniform in other diseases. The typical findings of the disease, were in concordance with literature, and are enlargement and calcification of both adrenal glands, hepatosplenomegaly, fatty liver, small bowel wall thickening and enlarged mesenteric lymph nodes. The radiologic choice of the examination is CT scan. Although trials and different approaches have been carried out, no effective treatment is explained yet. Further trials and studies are needed, hopefully, to find a treatment.

Patient consent

The manuscript has got ethical review exemption from Ethical Review Committee (ERC) of the authors' institution (French medical institute for Mothers and Children- {FMIC}) as case reports are exempted from review according to the institutional ethical review committee's policy. Written consent is obtained from the participants for publishing the case.

Written informed consent was obtained from the patient for publication of this case report and any accompanying images. A copy of the written consent is available for review by the Editor of this journal.

Authors' contributions

All of the authors have participated sufficiently in the submission and take public responsibility for its content. NF: writ-

ing and editing the manuscript, selecting the case and images, and corresponding with the journal. MTA: Revising the manuscript. All of the authors have read and approved the final manuscript.

REFERENCES

-
- [1] Low G, Irwin GJ, MacPhee GB, Robinson PH. Characteristic imaging findings in Wolman's disease. *Clinical Radiology Extra*. 2004 Oct 1;59(10):106–8.
 - [2] Dao T V, Mandell GA, Jorgensen SA, Patel M, Southard R, Taylor S, et al. Wolman disease 2017.
 - [3] Menon Jagadeesh, Shanmugam Naresh, Srinivas Sripriya, Vij Mukul, Jalan Anil, Reddy. Wolman's Disease: A Rare Cause of Infantile Cholestasis and Cirrhosis. *Journal of Pediatric Genetics* 2020. doi:[10.1055/s-0040-1715119](https://doi.org/10.1055/s-0040-1715119).
 - [4] Shenoy P, Karegowda L, Sripathi S, Mohammed N. Wolman disease in an infant 2014. doi:[10.1136/bcr-2014-203656](https://doi.org/10.1136/bcr-2014-203656).
 - [5] Alshahrani MA, Bin Saeedan M, Alkhunaizan T, Aljohani IM, Azzumee FM. Bilateral adrenal abnormalities : imaging review of different entities. *Abdominal Radiology* 2019;44(1):79–154 [Internet]Available at. doi:[10.1007/s00261-018-1670-5](https://doi.org/10.1007/s00261-018-1670-5).
 - [6] Col L, Sen D, Lovleen B, Sudhir C. ScienceDirect Case Report a rare constellation of imaging findings in wolman disease. 2014;1(0):10–3.