

## Clinical Report

# Episodic electrolyte disorders and renal failure due to a rare disease: the McKittrick–Wheelock syndrome

Sadie van Esch<sup>1</sup>, Marc van Milligen de Wit<sup>1</sup>, Kees van Laarhoven<sup>2</sup> and Pieter L. Rensma<sup>1</sup>

<sup>1</sup>Department of Internal Medicine, St Elisabeth Hospital Tilburg, Tilburg, The Netherlands and <sup>2</sup>Department of Surgery, St Elisabeth Hospital Tilburg, Tilburg, The Netherlands

Correspondence and offprint requests to: Sadie van Esch; E-mail: sadievanesch@gmail.com

### Abstract

We describe a patient with intermittent bouts of malaise and muscle weakness due to profound electrolyte disturbances. Colonoscopy showed a giant villous adenoma of the sigmoid. The patient was diagnosed with a McKittrick–Wheelock syndrome with pre-renal disease and electrolyte disorders due to periodic rectal fluid loss. The diagnosis was delayed by the patient's misinterpretation of the doctor's questions. In cases where the patient's history is contrary to what the data reveal, the expected culprit organ should be investigated early in the course of the disease. Extracting relevant and guiding information out of the patient's history remains an important skill.

**Keywords:** electrolyte disturbances; McKittrick–Wheelock syndrome

### Background

The patient's history is thought to point to the correct diagnosis in some 75% of cases, but the reliability can be questionable at times [1]. Reasons may be misunderstanding of the doctor's questions or deliberately giving wrong information to attract attention or to experience personal benefit of being ill. If the patient's answers are contrary to what might be expected, e.g. denial of vomiting or diarrhoea in the case of unexplained electrolyte losses, objective information should be sought for early in the course of the disease.

### Case report

A 52-year-old woman presented to the emergency department because she nearly collapsed on standing up. She complained of malaise and muscle weakness. A flu-like feeling had been present for some days, with nausea, but no vomiting, diarrhoea or fever. Because the weather had been unusually hot, she had sweated profusely and had drunk mainly ice water. She had rheumatoid arthritis for which she used hydroxychloroquine. Pulse rate was 84/min and blood pressure was 120/80 mmHg when supine. Skin turgor was normal, but the mucous membranes were dry. The remainder of the physical examination was normal. Blood investigations showed the following: erythrocyte sedimentation rate 45 mm/h, haematocrit 49%, white-cell count  $15.4 \times 10^3/\mu\text{L}$ , sodium 122 mmol/L, potassium 2.9 mmol/L, chloride 71 mmol/L, creatinine 437  $\mu\text{mol/L}$  (4.9 mg/dL) and urea 46.5 mmol/L (130 mg/dL). An arterial blood gas analysis: pH 7.51, bicarbonate 28.6 mmol/L, base excess 6.0 mmol/L. Plasma magnesium, creatinine kinase and cortisol levels

were normal. Urinalysis showed no protein, cells or casts. Fractional sodium excretion index was <1%. The potassium level in urine was 6 mmol/L and chloride 27 mmol/L. The electrocardiogram showed a prolonged QT time. On ultrasound, the kidneys appeared normal.

The data indicated a pre-renal origin of kidney failure, with marked electrolyte losses, without an evident cause. She did not suffer from vomiting or diarrhoea, nor did she use diuretics. The test results exclude inappropriate renal salt and water loss. Metabolic alkalosis associated with hypokalaemia can be caused by vomiting, diuretic use or volume contraction. Since she did not have a low urinary chloride level, the former two are unlikely [2]. Also, there was adequate renal potassium retention, arguing against recent diuretic abuse.

The patient was submitted for potassium and fluid replacement. After 3 days, renal function and electrolyte levels had become normal. It was hypothesized that intense perspiration in combination with a superfluous intake of water was the explanation for this clinical problem, analogous to runners' hyponatraemia [3]. She left the hospital in a good condition. At check-ups, creatinine and electrolyte levels were normal. However, the next year, she presented twice with the same symptoms and findings. Again, she responded quickly to fluid and electrolyte administration.

There had to be extrarenal fluid losses to explain these acute drops in plasma sodium and potassium concentrations and pre-renal failure. She did not have signs of self-induced vomiting, like parotid gland enlargement or front teeth erosions [4, 5]. Urine analysis was negative for laxatives and diuretics. A stool assay was also negative for laxatives.

She was admitted for measurement of 24-h stool volume and colonoscopy. The 24-h faeces showed a volume of 1.2 L of a clear fluid with a sodium level of 99 mmol/L and a

Good history taking is crucial in solving a case

potassium level of 56 mmol/L. Colonoscopy showed a giant, 8 × 15 cm, soft and flat tumour, located at the rectosigmoid level (Figure 1). Histopathological examination showed a villous adenoma with mild dysplasia.

When asked directly, she confirmed rectal loss of a clear fluid other than normal stools, but did not envisage it as diarrhoea. The final diagnosis was McKittrick-Wheelock syndrome. The surgeon performed a rectum extirpation. During follow-up of 3 years, no further episodes of dehydration and electrolyte disturbances occurred.

## Discussion

This case illustrates the importance of collecting relevant information from the patient's medical history. Failure to do so can lead to misdiagnosis and unnecessary hospital admissions and investigations. Furthermore, when test results are contradictory to the patient's accounts, objective information of the expected culprit organ should be sought for. Measurement of faecal volume and colonoscopy finally revealed the diagnosis in this case.

In the McKittrick-Wheelock syndrome, a large rectal or sigmoid villous adenoma causes secretory diarrhoea with marked electrolyte and acid-base disturbances and dehydration as a consequence [6]. Several mechanisms can explain the electrolyte disturbances and dehydration in this syndrome. The tumours have a large surface area where fluid is secreted and because of the distal localization, this fluid cannot be reabsorbed by the colon. Furthermore, the tumour may secrete prostaglandins, adenylate cyclase and cyclic adenosine monophosphate. These substances lead to increased chloride secretion and decreased sodium absorption, producing the massive fluid and electrolyte loss characteristic of the disease; the same mechanism is responsible for diarrhoea caused by cholera infection [7, 8]. Surgical resection is always needed to stop the electrolyte and fluid loss completely and because of the risk of cancer formation. Untreated secretory adenoma has a mortality of 100% [9].

The intermittent and protracted course of the disease in this patient is remarkable. The first two episodes occurred in summertime and it may be that a delicate balance was disturbed by increased levels of perspiration. After further growth, fluid and electrolyte losses by the tumour could no longer be compensated for. William Osler's remark that careful listening to a patient will reveal the diagnosis is not always evident. Asking the right questions greatly contributes to the applicability of this aphorism.

**Acknowledgements.** Prof R. Zietse and Prof R.T. Krediet are acknowledged for critically reviewing the manuscript.

**Conflict of interest statement.** None declared.

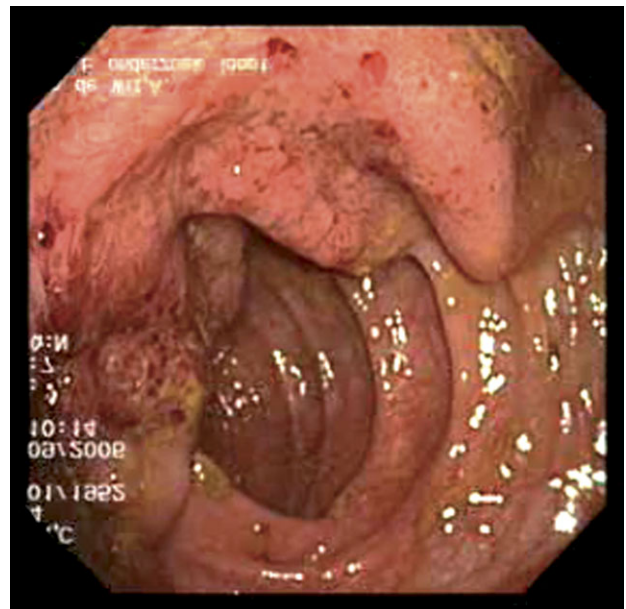


Fig. 1. Endoscopy of the colon showed a giant, 8 × 15 cm, soft and flat tumour, located at the rectosigmoid level.

## References

1. Paley L, Zornitzki T, Cohen J et al. Utility of clinical examination in the diagnosis of emergency department patients admitted to the department of medicine of an academic hospital. *Arch Intern Med* 2011; 171: 1394–1396
2. Kamel KS, Ethier JH, Richardson RM et al. Urine electrolytes and osmolality: when and how to use them. *Am J Nephrol* 1990; 10: 89–102. Review
3. Rosner MH, Kirven J. Exercise-associated hyponatremia. *Clin J Am Soc Nephrol* 2007; 2: 151–161
4. Mehler PS. Bulimia nervosa. *N Engl J Med* 2003; 349: 875–881
5. Mehler PS. Diagnosis and care of patients with anorexia nervosa in primary care settings. *Ann Intern Med* 2001; 134: 1048–1059
6. Winstanley V, Little MA, Wadsworth C et al. The McKittrick-Wheelock syndrome: a case of acute renal failure due to neoplastic cholera. *Ren Fail* 2008; 30: 469–473
7. Jacob H, Schlondorff D, St Onge G et al. Villous adenoma depletion syndrome: evidence for a cyclic nucleotide-mediated diarrhea. *Dig Dis Sci* 1985; 7: 637–641
8. Pugh S, Thomas GA. Patients with adenomatous polyps and carcinomas have increased colonic mucosal prostaglandin E2. *Gut* 1994; 35: 675–678
9. Emrich J, Niemeyer C. The secreting villous adenoma as a rare cause of acute renal failure. *Med Klin (Munich)* 2002; 97: 619–623

Received for publication: 27.5.11; Accepted in revised form: 19.12.11