

Received: 2012.11.18
Accepted: 2013.04.17
Published: 2013.12.02

Achalasia – balloon dilation or surgery?

Authors' Contribution:
Study Design A
Data Collection B
Statistical Analysis C
Data Interpretation D
Manuscript Preparation E
Literature Search F
Funds Collection G

ABCDEF **Renata Tabola**
AG **Krzysztof Grabowski**
BG **Andrzej Lewandowski**
C **Katarzyna Augoff**
F **Krystyna Markocka-Maczka**

Department and Clinic of Gastrointestinal and General Surgery, Medical University
in Wrocław, Wrocław, Poland

Corresponding Author: Renata Tabola, e-mail: tabrena@op.pl
Source of support: Departmental sources

Background: The optimal therapeutic schedule in patients with achalasia is still under discussion. The aim of this study was to review our institution's experience with myotomy and dilation in patients with achalasia.





Material/Methods: Clinical data were available for 59 patients who had ever had myotomy (n=38), dilation (n=21), or both procedures (n=8) between 2000 and 2007. Patients were followed prospectively with objective (a barium esophagogram) and subjective (a simple survey that scored dysphagia and overall patient satisfaction with the procedure) diagnostic tools. In the group of patients after pneumatic dilatations, frequency of interventions was higher (1, 2) than in the myotomy group (0, 2) at 2-year follow-up. Patients after myotomy with recurrence of dysphagia were treated with dilations.

Results: Mean time of dysphagia occurrence was similar in both groups (10 months). The statistically significant differences in treatment outcomes in both groups were in favor of myotomy during 2-year follow-up.

Conclusions: The data indicates that both methods of treatment might be useful in dysphagia control, but better results are obtained after myotomy. Repeat interventions are more frequent after endoscopic dilation. One method of treatment does not exclude the other. A short period of symptom relief after myotomy may suggest the myotomy was incomplete.

Key words: **achalasia • balloon dilations • myotomy**

Full-text PDF: <http://www.medscimonit.com/download/index/idArt/884028>

 2997  2  2  25

Background

The most common clinical symptom for achalasia is dysphagia. Patients typically present with solid food dysphagia and varied degrees of liquid dysphagia, in particular cold liquids, occasional regurgitations of undigested food, and heartburn. Clinical symptoms may also suggest respiratory complications (nocturnal cough and aspirations) [1–3]. Symptoms worsen gradually with disease duration. The esophagus slowly dilates and loses its function in food transport. The single objective measure in assessing esophageal dysfunction is barium esophagogram. Ninety percent of patients with achalasia have typical radiographic finding (the so-called “bird beak”) created by failure of the lower esophageal sphincter to relax [4,5]. In the early phase of the disease, endoscopic and radiologic findings can be completely normal. Finally, the diagnosis is confirmed or ruled out by manometry of the upper digestive tract. Absence of effective peristalsis of the esophageal body and failure of the lower esophageal sphincter (LES) to completely relax upon swallowing are the most characteristic. The cause of the disease remains far from clear, but it is assumed to arise from a relative absence of inhibitory ganglion cells in Auerbach’s plexuses of the esophageal wall. Treatment is aimed at reducing LES pressure and is still limited to mechanical or pharmacological disruption of its fibers. At present, the most popular options are surgery and pneumatic dilation [3,6–8]. Both procedures have similar hazard of esophageal perforation, but multiple dilations may increase perforation ratio [9].

Both methods require subjective as well as objective tools for evaluation of their outcomes. Several authors reported divergence between patients’ subjective symptomatic improvement and objective result of the treatment [5,10]. The most sensitive objective examination for LES disruption is esophageal manometry; however, the examination is not sufficient in long-term follow-up (evaluation of esophageal mucosa). Barium esophagogram – apart from revealing an enlarging esophageal diameter indirectly suggesting difficulty in its clearance, abnormalities of its wall, and a deteriorated antireflux barrier of LES – may also suggest coexisting upper digestive tract disorders such as impaired gastric emptying.

Material and Methods

The study cohort comprised of 71 patients who were treated for achalasia in the Clinic of Gastrointestinal and General Surgery of the University of Medicine in Wroclaw between 2000 and 2007. Achalasia was diagnosed by barium swallow study and upper digestive tract endoscopy in all the patients; most patients (85%) included in the study had esophageal manometry. Manometry was neglected only in patients older than 70 years, and/or with clinical record of the disease

Table 1. Demographics.

Baseline demographics	Myotomy group	Dilation group
Men/women n (%)	18/20 (47.4)	9/12 (42.9)
Age: years (mean, SD)	49.7 (12.9)	55.6 (16.6)
Symptom duration: months (mean, SD)	39.9 (15.0)	32.9 (24.9)
Severe dysphagia n (%)	17 (44.7))	8 (38.1)

duration longer than 36 months, who presented typical bird beak on barium study, and who did not agree to the procedure, but presented no findings on endoscopy. Patients with megaesophagus in the course of achalasia were excluded. We diagnosed megaesophagus in patients whose widest thoracic esophageal diameter was ≥ 7 cm.

Baseline characteristic of the patients are presented in Table 1. Clinical evaluation of the patients was adapted from the subjective dysphagia score developed by Eckardt et al. [11]. Severe dysphagia was diagnosed if the patient experienced difficulty in swallowing during every meal and reported weight loss greater than 20% body weight. None of the patients included in the study had received previous treatment for achalasia. Five patients out of endoscopic group were classified as worse candidates for myotomy, mainly due to their age and co-morbidity. Patients with the widest esophageal diameter greater than 5 cm were offered myotomy. We accepted other patients’ preferences: they could choose between myotomy and dilation after discussion with an experienced surgeon.

Session of balloon dilation begun from size 30 or 35mm, and duration of the dilatation was 2.5–3 minutes. If the dilatation was unsuccessful (radiogram a day after dilatation with soluble contrast after patient’s subjective complaints), the second session was attempted on the 3rd or 4th day with use of higher or the same diameter balloon and the same duration of the session. Patients who were treated endoscopically had to use PPI for 2 weeks after the procedure because we believe that a potential mucosal tear after mechanical disruption of the LES heals quicker in a non-acidic environment. Surgery was considered after 3 trials of balloon dilatation within a period shorter than 12 months and the narrowest esophageal diameter on esophagogram smaller than 0.4 cm.

Surgery was performed through transabdominal approach. The anterior part of the distal esophagus and esophago-gastric junction were exposed. Myotomy was performed 6–7 cm along the esophagus and 2–3 cm on to the gastric wall. Vagal nerves were spared. After myotomy, anterior fundoplication was constructed. The anterior wall of the fundus was fixed to

the diaphragmatic hiatus and the left and right walls of the esophagus. The procedure aimed to reconstruct the abdominal portion of the esophagus and its antireflux barrier. If a perforation occurred, it was sutured in 2 layers with 5.0 absorbable sutures, and myotomy was continued and completed with anterior fundoplication. The perforation after endoscopic dilation occurred on the anterior wall of the esophagus. It was double-layer sutured, myotomy was performed laterally to the perforation, and the operation was finished with anterior fundoplication and drainage of the hiatal area. Patients remained on intravenous nutrition for 7 days. Patients in whom perforation appeared during myotomy remained on intravenous crystalloids for 3–4 days. All patients, regardless of the type of procedure, underwent a postoperative barium swallow study 6 to 8 days postsurgery or within 6 weeks after balloon dilation. Patients were also questioned, using the same Eckardt's 4-grade scale, after they resumed oral feeding, to evaluate degree of dysphagia: "very good" result of the operation if a patient experienced no difficulty in swallowing of both solid and liquid food or experienced the sensation rarely in a month, "good" result when patient had minor difficulty with solid food or problems appeared sporadically (no more than twice a week), and "poor" result if the problems with solid food occurred at least once a day. All patients were also asked if they would choose to undergo the procedure again under similar postoperative outcomes. Patients were questioned 8 days after surgery or 1 day after balloon dilation, and between 6 months and 2 years after the procedure. The most important parameters evaluated in control barium swallow were esophageal emptying and the narrowest dimension along the lower esophageal sphincter. If the narrowest dimension of the esophagus after myotomy or balloon dilation was not smaller than 0.4 cm and the esophagus cleared within 5 min, the procedure was considered successful. Barium study was performed in all the patients shortly after the procedure and in 83.1% of them in long-term follow-up (between 1 and 2 years after the operation). Patients who had balloon dilation had a barium study a day after or within 6 weeks since the procedure. The control study was repeated between 6 and 18 months after the dilation. Statistical evaluation was performed using Statistica.pl package version 10.0. We use the chi-square and Fisher tests to show whether sex, age, disease duration, procedure type, or their combination influenced outcomes. P-value <0.05 was considered significant.

Results

Out of 71 patients included in the mid-term follow-up cohort, 12 patients were excluded: 1 patient (89 years old) dilation was unable to complete the interview after balloon due to dementia. One patient who underwent balloon dilation and 10 patients who underwent surgery did not appear for the control examination. The study cohort consisted of 2 groups: the

dilation group (21 patients ages 23–82 years, mean age 55.6 years) and the myotomy group (38 patients aged 21–74 years, mean age 49.7). Nine (15.3%) patients required both procedures, in 2 (9.5%) patients unsuccessful dilatation was followed by the operation, and in 6 (15.8%) patients poor result of surgical intervention resulted in endoscopy with balloon dilation within 2 years after the surgery. One (4.8%) patient had esophageal perforation on the first trial of balloon dilation and underwent urgent surgical repair consisting of suturing the perforation and lateral myotomy completed with fundoplication. He crossed over to the myotomy group.

Most patients were satisfied with the results of their surgery. All 6 (15.8%) patients who had endoscopic dilation after surgery indicated they if they could have chosen again, they would have preferred endoscopy and balloon dilation instead of surgery. The vast majority of patients treated with endoscopic dilations did not change their opinion and did not want to have surgery at 2-year follow-up. Although 8 (38.1%) patients treated with balloon dilation 2 years after the first dilation scored the result as poor, only 2 of them agreed to surgical myotomy. One patient, who had perforation after endoscopic intervention, decided he would not have chosen the dilation again and scored the outcome of surgery as good. Eleven (52.4%) patients were satisfied with the dilation result and evaluated it as very good (9.5%) or good (42.9%). Surgical complications consisted of 2 (5.2%) perforations that did not interfere with the result of the surgery. The tear was located in the anterior wall of the esophagus in both cases and was double-layer sutured; myotomy was performed laterally to the perforation and was completed with anterior fundoplication. Patients who had perforation reported good and very good surgical outcome and the result of their esophageal radiogram showed good esophageal passage, with lower esophageal sphincter diameter between 0.6 and 0.8 cm 2 years after the surgery. At 2-year follow-up, 19 (50.0%) patients in the surgical group scored the result of their surgery as very good, 4 (10.5%) patients scored the result as poor, and their scoring of dysphagia corresponded well with the narrowest esophageal diameter (0.2–0.4 cm). Figure 1 presents mean values of Eckardt's score at baseline and after 24-month follow-up for both groups. In both groups mean time of dysphagia recurrence was similar, but frequency of reintervention was higher in the dilation group (Table 2). Outcomes in the patients treated with myotomy were statistically significantly better than in the patients treated with dilation shortly after the procedure and during the 2-year follow-up (Figure 2). There were not statistically significant differences in sex, age, or disease duration between the groups.

Discussion

Achalasia is a relatively rare disease. Few studies have compared short- or long-term results of treatment between balloon

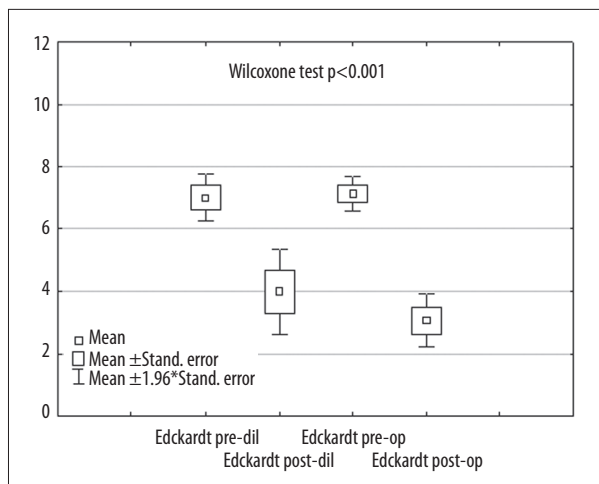


Figure 1. Mean values of Eckardt's score pre-and post procedure.

Table 2. Treatment modalities for patient groups. Mean time of dysphagia symptom since the first procedure and percentage of patients who developed dysphagia after balloon dilation and surgical myotomy.

Treatment	Dilatation group	Myotomy group
Total postmyotomy dilations	0	9
Mean number of dilatations	1.0	0.2
Total postdilatation myotomies	3	0
Mean number of interventions	1.2	0.2
Mean time of dysphagia recurrence (months)	10	10
Number and percentage of patients	10 (47.6%)	6 (15.6%)

dilations and surgical myotomy supported by partial fundoplication in an adequate number of patients. Overall outcomes are expected to differ in long-term follow-up. Results of the first procedure are thought to last for a shorter period of time, but both procedures achieve similar control of dysphagia in short-term follow-up [6–8,10–15]. According to the literature, both procedures are also associated with equivalent perforation rate [12,15]. In our study, perforation rate was 4.76% after dilation and 5.26% during myotomy. Perforation after dilation is a devastating complication; usually it requires an urgent operation to save the patient's life, but perforation during surgery does not affect postoperative outcome. The perforation rate after dilation increases with balloon diameter and patient age. We start dilation with a 30-mm balloon and prefer myotomy after the perforation instead of conservative treatment. According to the literature and our own experience, myotomy decreases the risk of further interventions. As shown in Figure 2, dilation improved symptoms in 61.9% of patients evaluated

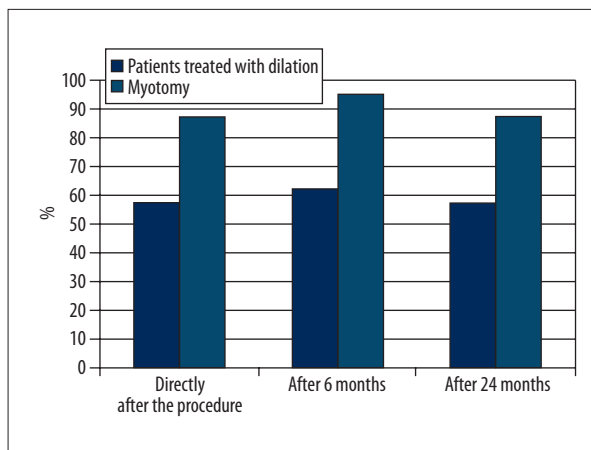


Figure 2. Symptom improvement rates between patients treated with dilation (1st column) and myotomy (2nd column) directly after the procedure, 6 and 24 months since the treatment ($p < 0.05$, $p < 0.01$ and $p < 0.05$ respectively).

6 month after the procedure. The success rate was highest at 12 months and declined after 24 months (81.0% and 52.4%, respectively). Myotomy had a greater percentage of patients with clinical improvement (94.7%, 92.1%, and 89.5%, $p < 0.05$). At 24-month follow-up, similarly to meta-analysis data, there were more treatment failures in the dilation group than in the myotomy group: 15.6% vs. 47.6%, respectively. Overall results did not differ from the results presented in a meta-analysis [14].

There are 2 types of failure after surgical myotomy for achalasia: early and late. Early failure is a consequence of incomplete myotomy, especially along the stomach wall or scarred myotomy, and is easily verified by difficulty in food intake and on esophagograms (length and minimal width of the stenosis, time of esophageal emptying). Reflux esophagitis, with all its consequences, as a result of deteriorating fundoplication occurs as a long-term failure. Similar times of dysphagia recurrence after myotomy and balloon dilation in our data support the thesis. The observation time in our study might not have been sufficient to judge the outcome of balloon dilation. Successful single dilation may overcome the effect of incomplete or scarred myotomy but still end in treatment failure in long-term follow-up [16–19]. Dilated patients are theoretically at higher risk of reflux consequences. Long-term follow-up is required to evaluate the influence of reflux on dysphagia control and overall success rate in patients treated by balloon dilations.

Our experience and data from the literature show that significant proportion of patients do not consent to follow-up with use of invasive methods such as manometry, especially if the result of the procedure is satisfactory in their opinion [4,5]. For this reason, we prefer less invasive techniques such as barium

study and use of the same survey, which patients have to complete before and after the procedure. During the study, barium examination was evaluated or supervised by experienced radiologists who looked for simple criteria: the minimal and maximal esophageal width and length, and minimal width of the stenosis (area of LES) during the first 1–4 minutes after the patient swallowed 150–200 ml of low-density barium suspension. According to the survey, patients were questioned about details concerning difficulty with food intake and frequency of their occurrence. Exactly the same survey was completed by the patient pre- and post-operatively as an objective way to categorize symptom severity [1,4]. We also asked all patients if they would repeat the treatment considering all the post-operative circumstances. The success or failure of the procedure from the patient's perspective is strongly determined by symptom relief; however, attention should also be paid to mean esophageal diameter [17]. In our opinion, barium study verifies the narrowest dimension and mean diameter of the esophagus, and is useful in early detection of treatment failures and in prognosing the risk of treatment failure in long-term follow-up. Increasing mean diameter of the esophageal body is an indicator of further deterioration of esophageal function that may lead to megaesophagus. Data from the literature suggests that some patients with subjective improvement after dilation may not present objective evidence of esophageal emptying [4,5,9]. In this regard, a barium esophagogram is a very useful and quite comfortable examination that may help identify patients with subjective improvement and with no or little difference in esophageal emptying [11,16,18].

Our study evaluated only clinical outcomes during a 2-year follow-up. Limitations of this study are its lack of manometry after the procedure, small sample size, and only short-term follow-up. According to some authors, the percentage of satisfied patients who underwent myotomy with successful dysphagia score after the first 24 months remains on a similar level in long-term follow-up in the majority of patients [12,16]. The attitude towards incomplete or scarred myotomy has evolved: both might be treated with dilation, but re-myotomy should be reserved for non-responders [2,12].

An important question is what kind of the procedure is the most appropriate for a particular individual. The surgeon should consider the patient's general condition, age, personal expectations, attitude towards surgery, and the desire to avoid subsequent interventions. Subsequent interventions are common in patients treated for achalasia, although the risk of further intervention is relatively higher for patients treated with pneumatic dilations [6,20–22]. The observation is also in agreement with our data (Table 2). An algorithm updated from the American College of Gastroenterology Practice Guidelines 1999 for the treatment of achalasia indicates that the therapeutic schedule depends on age and sex, but our results do

not support this. Treatment results did not differ statistically by sex or age in both groups during 2-year follow-up. Stronger LES muscle characteristic for male sex and younger age may need more than 1 session with wider balloon dimension in 1 treatment trial. We think that application of 1 procedure does not exclude the second option. Pastor et al. found increased tension in some cases of previously dilated cardia, but it did not increase perforation rate or influence results of the surgery [2]. The perforations in our material occurred in primarily operated patients and did not affect the outcomes (“good” and “very good” result of the surgery). The study has confirmed that in certain circumstances both procedures are of similar effectiveness and the decision of which option to use must be carefully discussed with the patient. The average time for presentation of recurrent dysphagia was 10 months for both groups, although percentage of patients who developed dysphagia was higher in the dilation group (Figure 2, Table 2). Our observation, similar to data from the literature, confirms the thesis that incomplete myotomy leads to dysphagia within 2 years after the surgery [19,20,23–25]. Endoscopic dilation may achieve long dysphagia control, even in patients who did not benefit after the first session and who had to undergo a second session. Patients who do not respond to dilation therapy and present with rapid dysphagia recurrences should be offered surgery. Deteriorating esophageal function, subjectively and on esophagograms, is indicative of myotomy. The observation was also made by Snyder et al, who found worse outcomes of myotomy in patients who had undergone multiple endoscopic dilations pretreatment [8]. In this context, barium esophagogram is a good diagnostic tool and might be used in follow-up, especially when there is no consistency in the predictive value of manometry in that aspect. Bravi et al. suggested that high LES pressure after first dilation does not discriminate the patient from patients with low LES pressure, although the group of patients with high LES pressure shows the tendency towards the need for more than 1 dilation session to achieve clinical remission [16].

Conclusions

Ever myotomy or balloon dilation might be useful in dysphagia control, but better results are obtained after myotomy. Re-interventions are more frequent after endoscopic dilation. One method of treatment does not exclude the other. A short period of symptom relief after myotomy may suggest incomplete myotomy.

Statement

Authors: Renata Tabola, Krzysztof Grabowski, Andrzej Lewandowski, Katarzyna Augoff and Krystyna Markocka-Maczka declare no conflict of interest.

References:

- Zaninotto G, Rizzetto C, Zambon P et al: Long-term outcome and risk of oesophageal cancer after surgery for achalasia. *Br J Surg*, 2008; 95(12): 1488–94
- Pastor AC, Mills J, Marcon MA et al: A single center 26-year experience with treatment of esophageal achalasia: is there an optimal method? *J Pediatr Surg*, 2009; 44(7): 1349–54
- Boeckxstaens GE: Achalasia. *Best Pract Res Clin Gastroenterol*, 2007; 21(4): 595–608
- Chuah SK, Hu TH, Wu KL et al: The role of barium esophagogram measurements in assessing achalasia patients after endoscope-guided pneumatic dilation. *Dis Esophagus*, 2009; 22(2): 163–68
- Andersson M, Lundell L, Kostic S et al: Evaluation of the response to treatment in patients with idiopathic achalasia by timed barium esophagogram: results from a randomized clinical trial. *Dis Esophagus*, 2009; 22: 264–73
- Lopushinsky SR, Urbach RD: Pneumatic dilatation and surgical myotomy for achalasia. *JAMA*, 2006; 296(18): 2227–33
- Yu L, Li J, Wang T et al: Functional analysis of long-term outcome after Heller's myotomy for achalasia. *Dis Esophagus*, 2010; 23(4): 277–83
- Snyder CW, Burton RC, Brown LE et al: Multiple preoperative endoscopic interventions are associated with worse outcomes after laparoscopic Heller myotomy for achalasia. *J Gastrointest Surg*, 2009; 13(12): 2095–103
- Katzka DA: Castell Review article: an analysis of the efficacy, perforation rates and methods used in pneumatic dilation for achalasia. *Aliment Pharmacol Ther*, 2011; 34(8): 832–39
- Kala Z, Weber P, Marek F et al: Achalasia – Which method of treatment to choose for senior patients? *Z Gerontol Geriat*, 2009; 42: 408–11
- Eckardt VF, Aignherr C, Bernhard G: Predictors of outcome in patients with achalasia treated by pneumatic dilation. *Gastroenterology*, 1992; 103: 1732–38
- Chen Z, Bessell JR, Chew A, Watson DI: Laparoscopic cardiomyotomy for achalasia: clinical outcomes beyond 5 years. *J Gastrointest Surg*, 2010; 14(4): 594–600
- Eldaif SM, Mutrie CJ, Rutledge WC et al: The risk of esophageal resection after esophagomyotomy for achalasia. *Ann Thorac Surg*, 2009; 87(5): 1558–63
- Campos GM, Vittinghoff E, Rabl C et al: Endoscopic and surgical treatments for achalasia: a systematic review and meta-analysis. *Ann Surg*, 2009; 249(1): 45–57
- Boeckxstaens GE, Anness V, des Varannes SB et al: Pneumatic dilation versus laparoscopic Heller's myotomy for idiopathic achalasia. *European Achalasia Trial Investigators. N Engl J Med*, 2011; 364(19): 1807–16
- Ferguson MK, Reeder LB, Olak J: Results of myotomy and partial fundoplication after pneumatic dilatation for achalasia. *Ann Thorac Surg*, 1996; 62: 327–30
- Omura N, Kashiwagi H, Yano F et al: Reoperation for esophageal achalasia. *Surg Today*, 2012 Jul 13
- Rosemurgy AS, Morton CA, Rosas M et al: A single institution's experience with more than 500 laparoscopic Heller myotomies for achalasia. *J Am Coll Surg*, 2010; 210(5): 637–47
- Lee CW, Kays DW, Chen MK, Islam S: Outcomes of treatment of childhood achalasia. *J Pediatr Surg*, 2010; 45(6): 1173–77
- Bravi I, Nicita MT, Duca P et al: A pneumatic dilation strategy in achalasia: prospective outcome and effects on oesophageal motor function in the long term. *Aliment Pharmacol Ther*, 2010; 31(6): 658–65
- Hulselmans M, Vanuytsel T, Degreef T et al: Long-term outcome of pneumatic dilation in the treatment of achalasia. *Clin Gastroenterol Hepatol*, 2010; 8(1): 30–35
- Streitz JM Jr, Ellis FH Jr, Gibb SP, Heatley GM: Achalasia and squamous cell carcinoma of the esophagus: analysis of 241 patients. *Ann Thorac Surg*, 1995; 59(6): 1604–9
- Reynoso JF, Tiwari MM, Tsang AW, Oleynikov D: Does illness severity matter? A comparison of laparoscopic esophagomyotomy with fundoplication and esophageal dilation for achalasia. *Surg Endosc*, 2011; 25(5): 1466–71
- Devaney EJ, Lannettoni MD, Orringer MB, Marshall B: Esophagectomy for achalasia: patient selection and clinical experience. *Ann Thorac Surg*, 2001; 72(3): 854–58
- Zaninotto G, Costantini M, Portale G et al: Etiology, diagnosis, and treatment of failures after laparoscopic Heller myotomy for achalasia. *Ann Surg*, 2002; 235(2): 186–92