



## Original Article

### Corresponding Author

Tuna Pehlivanoglu

<https://orcid.org/0000-0001-8886-7538>

Emsey Hospital/Yeni Yuzyil University,  
Faculty of Health Sciences, Camlik  
Mahallesi, Selcuklu Caddesi, No:22,  
Kurtköy, Istanbul, Turkey  
Email: dr.tuna@hotmail.com

Received: December 16, 2020

Revised: January 12, 2021

Accepted: January 25, 2021

# Unilateral Posterior Surgery for Severe Osteoporotic Vertebrae Fractures' Sequelae in Geriatric Population: Minimum 5-Year Results of 109 Patients

Tuna Pehlivanoglu<sup>1,2</sup>, Yigit Erdag<sup>2</sup>, Ismail Oltulu<sup>2</sup>, Umut Dogu Akturk<sup>2</sup>, Emre Korkmaz<sup>2</sup>, Kerem Yildirim<sup>2</sup>, Ender Sarioglu<sup>2</sup>, Kerem Gun<sup>2</sup>, Ender Ofluoglu<sup>2</sup>, Mehmet Aydogan<sup>2</sup>

<sup>1</sup>Yeni Yuzyil University, Faculty of Health Sciences, Istanbul, Turkey

<sup>2</sup>Emsey Hospital, Advanced Spine Surgery Center, Istanbul, Turkey

**Objective:** This study aimed to evaluate the efficacy and safety of modified posterior vertebral column resection (PVCR) combined with anterior column restoration in elderly patients presenting with thoracic or thoracolumbar osteoporotic fractures with spinal cord compression and severe pain.

**Methods:** One hundred nine patients with one level thoracolumbar osteoporotic fracture and at least 5 years of follow-up were included. They underwent posterior instrumentation performed with polymethylmethacrylate augmented pedicle screws. A modified PVCR (unilateral costotransversectomy+hemilaminectomy) combined with the insertion of an expandable titanium cage for anterior column restoration was undertaken. Patients were evaluated clinically and radiographically.

**Results:** Patients had a mean age of 74.1 and a follow-up duration of 92.3 months. Mean duration of operations, hospital stays, and mean loss of blood were 172.3 minutes, 4.3 days, and 205.4 mL. All of the patients were mobilized immediately after surgery. The mean preoperative local kyphosis angle improved from 39.3° to 4.7° at the last follow-up ( $p = 0.003$ ). Patients preoperative mean visual analogue score, Japanese Orthopaedic Association, and Oswestry Disability Index scores improved from 7.7/8.6/76.3 to 1.6/26.1/17.4 ( $p < 0.001$  for all), respectively. The average 36-item Short-Form survey physical component summary/mental component summary scores at the last follow-up were 55.1/56.8. A dural tear was detected intraoperatively in 1 patient and repaired immediately.

**Conclusion:** Subtotal PVCR combined with the insertion of an expandable titanium cage was detected as a safe and effective method for osteoporotic vertebrae fractures' sequelae in the older population involving spinal cord compression by enabling the decompression of the spinal canal and reconstruction of the resected segment, resulting in significant improvement in clinical and radiographic outcomes.

**Keywords:** Osteoporotic thoracolumbar vertebrae fractures, Geriatric population, Modified posterior vertebral column resection, Anterior column restoration, Local kyphosis angle, Quality of life



This is an Open Access article distributed under the terms of the Creative Commons Attribution Non-Commercial License (<https://creativecommons.org/licenses/by-nc/4.0/>) which permits unrestricted non-commercial use, distribution, and reproduction in any medium, provided the original work is properly cited.

Copyright © 2021 by the Korean Spinal Neurosurgery Society

## INTRODUCTION

Osteoporotic vertebrae fractures (OVF) were commonly associated with refractory low back pain and kyphotic deformity. At the same time, all of these clinical features could be complicated with the development of a sagittal imbalance due to progressive kyphosis and with any neurological deterioration as a result of spinal canal compromise.<sup>1-3</sup>

AO (Arbeitsgemeinschaft für Osteosynthesefragen) type A1 and A3<sup>4</sup> simple compression fractures without any neurological involvement can be managed with conservative treatment including pain-medications, brace and bed rest, or with minimal invasive surgery including percutaneous vertebroplasty (PVP) or balloon kyphoplasty.<sup>5,6</sup> However, for severe fractures associated with progressive kyphosis and neurological symptoms, these conservative or minimally invasive methods could neither yield a sufficient spinal cord decompression and clinical amelioration nor could they correct kyphotic deformity together with restoration of sagittal balance and reconstruction of spinal stability.<sup>7-9</sup>

For patients with OVF sequelae, besides the treatment of the underlying cause, open surgery is indicated in the presence of progressive kyphosis ( $> 35^\circ$ ), neurological deficit, and intractable pain, with the aims to eliminate the pain, reconstruct the sagittal balance and mobilize the patients as soon as possible to prevent any immobilization related complication and to provide sufficient quality of life.<sup>9-11</sup>

Dealing with the osteoporotic spine was frequently reported to be extremely challenging because of the poor bone quality, which could jeopardize the pedicle screw holding force leading to increased rates of loosening and pull-out of the screws.<sup>2,3,12</sup> Therefore the ideal treatment of severe OVF requiring open surgery is still under debate. We hypothesized if the modified

PVCR was an acceptable treatment alternative for OVF sequela with hyperkyphosis and severe pain requiring open surgery, while presenting the long-term results, our modified posterior vertebral column resection (PVCR) method combined with restoration of anterior column applied that group of patients. We questioned whether this method in the geriatric population was able to provide adequate spinal decompression and successful restoration of the sagittal balance, which could be sustained in the long term.

## MATERIALS AND METHODS

Following the approval of the Institutional Review Board of EMSEY Hospital (Nr:1121052), within the framework of a retrospective study, analysis of patients with osteoporotic (T-score  $< -2.5$  standard deviation [SD] measured with dual-energy x-ray absorptiometry performed in the same institution) thoracolumbar vertebral fractures between 2011–2014 was conducted. Four hundred twenty-eight consecutive patients were detected. Among them, 266 patients were noted to have AO type A1 and A3 simple compression fractures, that conservative treatment including brace-pain medication-bed rest (167 patients), PVP (85 patients), and percutaneous balloon kyphoplasty (14 patients) were applied.

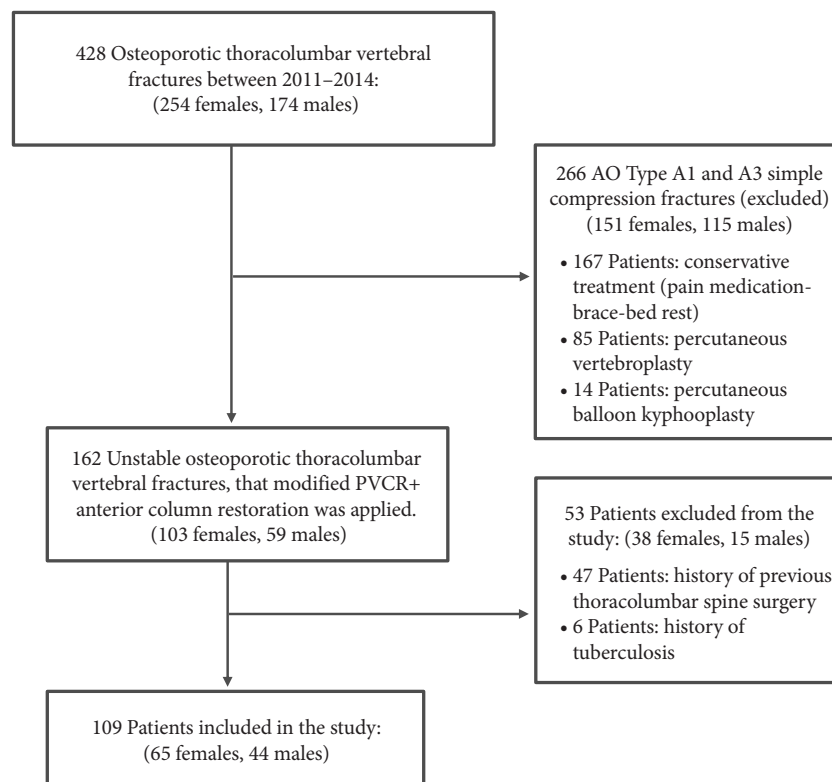
The remaining 162 patients with severe OVF have been assessed according to the strict inclusion and exclusion criteria. Table 1.

As a result of the inclusion and exclusion criteria, 53 patients (47 patients had a history of previous thoracolumbar spine surgery; 6 patients had a history of vertebral tuberculosis) were excluded from the study. The remaining 109 patients were enrolled in the study (Fig. 1).

All patients provided informed consent so that their opera-

**Table 1.** Inclusion and exclusion criteria

Inclusion criteria	Exclusion criteria
Diagnosis of osteoporosis (T-score $< -2.5$ SD)	No documented diagnosis of osteoporosis
Age $> 65$ years	Age $< 65$ years
Thoracolumbar vertebral fracture requiring open surgery (local kyphosis angle $> 35^\circ$ , presenting-deteriorating neurological deficit (any Frankel grade except E and/or nerve compression symptoms), unstable fracture, spinal canal compromise $> 30\%$ , anterior vertebral body height $< 30\%$ of the adjacent vertebra)	A thoracolumbar vertebral fracture, that did not require open surgery/ managed conservatively or with percutaneous vertebroplasty or percutaneous balloon kyphoplasty
Modified PVCR (as we described) combined with anterior column restoration using a titanium mesh/expandable cage	A history of previous spinal surgery, tumor, infection (including tuberculosis)
A minimum follow-up duration of 60 months (5 years)	A minimum follow-up duration of less than 60 months (5 years)



**Fig. 1.** Flowchart of the study population.

tive, intraoperative, and postoperative data, including the x-rays, computed tomography (CT), and MRI images, could be used for publication by hiding their identity.

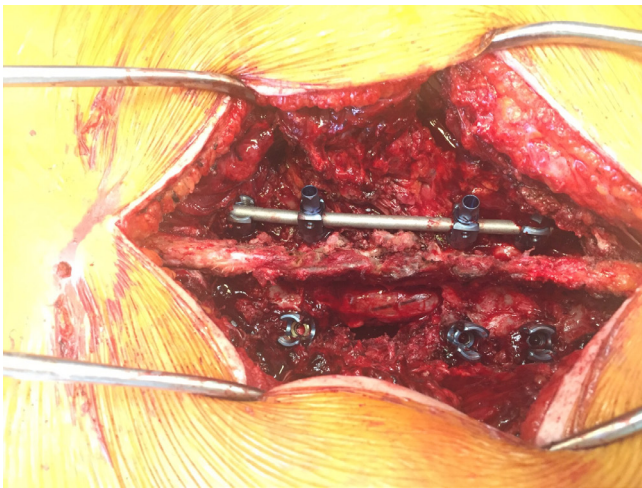
### 1. Surgical Technique

Before the planning of surgeries, patients with poor bone density were placed on bone replacement medication by the endocrinology specialist. However, considering that most of these patients who were needed open surgery were referred to our clinic as a result of failed conservative treatment and worsening of clinical course regarding their neurological status and pain intensity, to prevent any further clinical-neurological deterioration, they were operated on right away after the admission with no additional loss of time. As a result of the consultation with an endocrinology specialist, patients were either started on bisphosphonates before the surgery and continued on that medication postoperatively, or they were started with teriparatide postoperatively.

All surgeries were performed with the same technical guidelines under intraoperative neuromonitoring, while the preoperative preparation and postoperative treatment and rehabilitation protocol were also identical in all patients.

Under general anesthesia, patients were placed in a prone position on an operating table. After the confirming the fractured level with the C-arm, a posterior midline skin incision in the length of 2 vertebral levels above and 2 levels below was undertaken. After meticulous soft tissue dissection, pedicle screw entry points were marked. Fenestrated and cannulated pedicle screws were inserted 2/3 levels above and 2/3 levels below the fractured segment under fluoroscopic guidance with the free-hand technique bicortically. Polymethylmethacrylate (PMMA) bone cement was prepared and injected into the pedicle screw channels using PVP catheters with 2 mL/screw in all patients.

After that, modified PVCR was undertaken to the fractured level. A modified PVCR was defined as: (1) unilateral hemilaminectomy combined with costotransversectomy; (2) discectomy of the upper and lower spinal level, together with curettage of the endplates; (3) adequate decompression from one side: At spinal levels above L1 the nerve root was ligated. But at levels below L1, not to cause any neurologic deficit regarding the lower extremity, the posterior ramus of the associated nerve root was ligated, leading to the mobilization of the nerve root. By protecting the nerve root with a root retractor, enough space was freed for the advancement of the expandable cage from



**Fig. 2.** An intraoperative photo indicating the posterior approach of modified posterior vertebral column resection technique.

posterior; (4) unilateral corpectomy and decancellation of the vertebral body while leaving the anterior cortex and the lateral cortex on the contralateral side intact; (5) insertion of the expandable titanium cage into the vertebral body. During modified PVCR and cage insertion, the posterior construct was secured with one temporary rod placed on the contralateral side. Fig. 2.

After the placement of permanent rods and securing of the entire posterior construct, one-two adjacent uninstrumented level(s) above and below prophylactic vertebroplasty was undertaken in all patients as described formerly.<sup>13</sup>

## 2. Evaluation of Clinical Outcomes

Clinical outcome parameters were determined using self-assessment questionnaires, including visual analogue score<sup>14</sup> to evaluate the pain level, and Oswestry Disability Index (ODI)<sup>15</sup> completed individually by all patients. Japanese Orthopaedic Association (JOA) scoring system as a validated and reliable method<sup>16</sup> was utilized to evaluate the neurological status and Frankel score.<sup>17</sup> The quality of life of the study population was evaluated by using 36-item Short-Form survey (SF-36) scores.

## 3. Evaluation of Radiographic Outcomes

Radiographic evaluation was undertaken by 1 senior spine surgeon (TP) pre-, postoperatively and at the follow-up, comprised local kyphosis angle and sagittal vertical axis (SVA).

## 4. Statistical Analysis

For the statistical analysis IBM SPSS Statistics ver. 22.0 (IBM

**Table 2.** Demographic data (n = 109)

Variable	Value
Sex, male:femal	44:65
Age (yr)	74.1 (67–84)
Body mass index (kg/m <sup>2</sup> )	23.4 (21.7–28.2)
Duration of follow-up (mo)	92.3 months (60–106)
Preoperative T-score measured with dual energy x-ray absorptiometry	-3.4 (-2.7 to -4.2)
No. of fractured levels	
T8	2
T9	5
T11	11
T12	47
L1	41
L2	3
Duration from the onset of symptoms to surgery (mo)	4.6 (3–9)
Duration of operation (min)	172.3 (161.4–221.9)
Loss of blood (mL)	205.4 (129.1–467.2)
Duration of hospital stay (day)	4.3 (3–9)

Values are presented as number or mean (range).

Co., Armonk, NY, USA) was used. A Wilcoxon signed-rank test was used to evaluate preoperative to postoperative deformity correction. Data were expressed as mean  $\pm$  SD. Chi-square test and Fisher exact test were used for the analysis of categorical variables where appropriate. One-way analysis of variance was used to determine a significant difference at various time points. A p-value less than 0.05 was considered statistically significant.

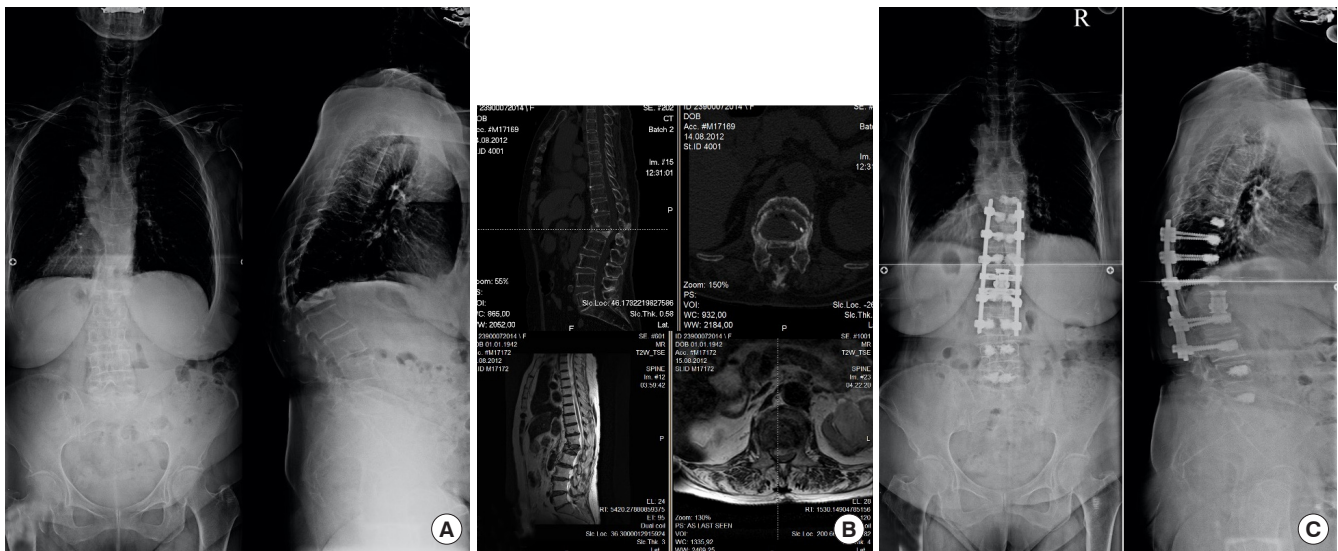
## RESULTS

### 1. Demographic Data

A total number of 109 patients (65 females, 44 males) were included. Their demographic data were summarized in Table 2. The average duration of operations was detected as 172.3 minutes (range, 161.4–221.9 minutes), while patients were detected to have an average loss of blood of 205.4 mL (range, 129.1–467.2 mL). The average duration of hospital stay was 4.3 days (range, 3–9 days). All patients were mobilized immediately after surgery.

### 2. Clinical Outcome Scores

All of the clinical outcome scores, including SF-36 scores in-



**Fig. 3.** A 71-year-old female patient with an osteoporotic fracture (A) and canal compromise (B) at the level of L1. Postoperative 6th year (C). The local kyphosis angle of 51.2° improved to 4.1°, sagittal vertical axis improved from 63.4 mm to 9.2 mm.

**Table 3.** Clinical outcome scores

Variable	Preoperative	Last follow-up	p-value
JOA score	8.6 (8–12)	26.1 (24–27)	<0.001
ODI score	76.3 (73–86)	17.4 (15–21)	<0.001
VAS score	7.7 (5–9)	1.6 (0–3)	<0.001
SF-36 MCS	47.1 (46.4–49.4)	55.1 (53.3–57.6)	<0.001
SF-36 PCS	44.3 (44.2–46.8)	56.8 (54.6–57.7)	<0.001

Values are presented as mean (range).

JOA, Japanese Orthopaedic Association; ODI, Oswestry Disability Index; VAS, visual analogue score; SF-36, 36-item Short-Form survey; MCS, mental component summary; PCS, physical component summary.

dicating quality of life, were detected to be improved with high statistical significance. Patients were Frankel D at the initial presentation, except 3 patients who were Frankel C. All patients were Frankel E postoperatively while those 3 patients improved to Frankel D immediate-postoperatively and were detected to improve to E at the last follow-up appointment. All patients with neurologic symptoms were detected to have complete relief of their nerve compression symptoms at the final follow-up. Table 3.

### 3. Radiographic Outcome Measurements

The average preoperative local segmental kyphosis angle improved from 39.3° (range, 31.7°–47.4°) to 4.9° (range, 3.9°–10.1°) at the last follow-up ( $p < 0.001$ ). The average preoperative SVA improved from 61.2 mm (range, 43.1–82.4 mm) to 10.2 mm

**Table 4.** Radiographic outcome measurements

Variable	Preoperative	At the last follow-up	p-value
Preoperative local segmental kyphosis (°)	39.3 (31.7–47.4)	4.7 (3.9–10.1)	<0.001
SVA (mm)	61.2 (43.1–82.4)	10.2 (8.7–12.9)	<0.001

Values are presented as mean (range).  
SVA, sagittal vertical axis.

(range 8.7–12.9 mm) at the last follow-up ( $p < 0.001$ ) (Table 4, Fig. 3).

### 4. Complications

Dural tear (1.8%) was detected intraoperatively in 2 patients and repaired immediately. Five patients (4.6%) developed distal junctional level fracture and underwent early vertebroplasty (postoperation 6th–8th month, 1st year). Two patients (1.8%) underwent revision due to cage subsidence (both: postoperation 1st year). Fusion was confirmed on the last follow-up visit using CT, while no pseudoarthrosis or implant failure was evident.

## DISCUSSION

Severe OVF in geriatric population accompanied with kyphosis and neurologic deficit are difficult to treat besides causing high-intensity pain, diminished mobility, decreased quality of life, depression, worsening of daily activities of living and

progressive problems regarding pulmonary and gastrointestinal system.<sup>18-21</sup>

As a result of percutaneous kyphoplasty (PKP), a high incidence of recollapse of the treated vertebra in the long-term follow-up was reported,<sup>22,23</sup> while balloon inflation was associated with bone rupture.<sup>24</sup> PMMA augmentation, which was provided as the main goal during PVP and PKP, was reported to be associated with intervertebral cement leakage leading to the collapse of adjacent endplates and intervertebral discs, resulting in intervertebral instability and eventually new compression fractures.<sup>25,26</sup>

In severe, unstable OVFs, which comprise a progressive kyphosis, severe-intractable back pain, and associated neurologic deficits, PVP or PKP can neither provide adequate spinal decompression nor successful fracture reduction, together with anterior column restoration and sagittal balance correction.<sup>2,9,27</sup> Therefore, open surgery is indicated for that particular group of geriatric patients. Meanwhile, open surgery was indicated for patients in the present study, while PVP and PKP were not suited to be applied as standalone treatment options.

Options regarding open surgery comprise anterior, posterior, or combined approaches, while the ideal approach for geriatric patients with severe OVFs' sequela is controversial.<sup>1,28</sup> Geriatric patients with severe OVFs were frequently reported to have an advanced age with a wide spectrum of comorbidities so that they might be unable to tolerate multiple surgical approaches, while a surgery performed in a single seating might be the best option.<sup>2,9</sup> Beside this fact, the anterior or anterior-posterior combined approaches were carried out by opening the thoracic cavity in addition to retroperitoneal space, and was, therefore, associated with higher risks and complications as compared to posterior only approach.<sup>12,29</sup> In the present study, posterior only approaches were applied to geriatric osteoporotic patients to prevent the risks associated with the combined anterior approach, which was in conjunction with the current literature stating that posterior approach could provide shortening of the operative time, reduction of the blood loss and accomplish adequate decompression and anterior column restoration.<sup>30,31</sup>

In terms of posterior approaches, pedicle subtraction osteotomy (PSO) was considered the widely accepted treatment option for vertebral compression pressures with progressive kyphosis and sagittal imbalance.<sup>1,32</sup> However, to perform PSO, the anterior vertebral body was utilized as a hinge, but in OVFs, the anterior portion of the osteoporotic vertebral body might be devoid of adequate bone mass and cannot be used as a hinge, making PSO technically impossible.<sup>1,32</sup> As a result of the afore-

mentioned problems, PSO was preferred not to be applied to osteoporotic patients with severe OVFs.

PVCR was defined as a procedure, which successfully provided adequate spinal cord decompression through the bilateral osteotomy approaches that were capable to completely remove the vertebral body of the fractured segment together with the adjacent cranial and caudal intervertebral discs.<sup>2,9</sup> As combined with the anterior placement of a cage, this procedure was noted to be capable of successfully restoring the anterior column without changing the spinal length and causing any neural damage due to spinal wrinkling.<sup>1,9,12</sup>

There is very limited information regarding the application of PVCRC combined with anterior column restoration to patients with OVFs' sequela. The existing literature is mainly based on a small number of patients with relatively short term follow-up (Dreimann et al.<sup>2</sup>: 10 patients, 18.4 ± 8 months, Sehmisch et al.<sup>9</sup>: 10 patients, 14 months, Wei et al.<sup>27</sup>: 24 patients, 32.68 ± 8.72 months, Ma et al.<sup>1</sup>: 26 patients, 28.7 ± 3.2 months). Regarding the application of PVCRC in geriatric patients with OVFs, this study has the largest patient number (109) and longest average follow-up duration (92.3 months).

Despite all of the advantages mentioned above, PVCRC was considered to be associated with intraoperative risks, including bleeding and long duration of operations as applied to geriatric patients with severe OVFs.<sup>2,9,27</sup> This is why we modified this procedure and reduced it to a unilaterally applicable type of osteotomy, which was shown to shorten the average duration of surgery together with average bleeding. Dreimann et al.<sup>2</sup> applied PVCRC with 2 small titanium mesh cages to 10 patients and reported mean surgical time of 318 ± 62 minutes and an average blood loss of 1,540 ± 745 mL. Wei et al.<sup>27</sup> used a single titanium mesh cage and reported an average surgical duration of 223.08 ± 28.78 minutes and 413.25 ± 84.50 mL of average bleeding. Ma et al.<sup>1</sup> also used a single titanium mesh cage and reported an average surgical duration of 208 ± 49 minutes and an average of 756 ± 244 mL of blood loss. Sehmisch et al.<sup>9</sup> used 2 small titanium mesh cages and reported an average surgical duration of 318 ± 62 minutes and an average blood loss of 1,540 ± 745 mL. The present study reported an average surgical time of 172.3 minutes and an average blood loss of 205.4 mL, which are lower than the reported data in the literature, indicating the less invasiveness of this modification. The limited amount of bleeding might be attributed to the less-invasive nature of the unilateral posterior surgery together with meticulous attempts to coagulate any intraoperative bleeding together with the usage of tranexamic acid.

While performing the PVCR procedure, correction of the kyphotic deformity and restoration of the anterior column was reported to be of high importance because the correct sagittal balance leading to improvements of the volumes of thoracic and abdominal cavities were highly correlated with patients' quality of life.<sup>33,34</sup> Ma et al.<sup>1</sup> reported an average follow-up SVA of  $18.3 \pm 3.5$  mm, while the other studies did not analyze regarding the SVA and sagittal balance. This study reported an average SVA of 10.2 mm at the latest follow-up showing the efficacy of the modified PVCR procedure in terms of the realignment and correction of sagittal balance.

Correction of kyphosis is considered one of the main goals of surgical treatment in geriatric patients with OVFs. It was reported that the magnitude of kyphosis—sagittal imbalance—was positively correlated with the worsening of quality of life.<sup>33</sup> The average degree of local segmental kyphosis at the last follow-up was  $8^\circ \pm 7^\circ$  in the study of Sehmisch et al.,<sup>9</sup>  $9.5^\circ \pm 3.8^\circ$  in the study of Ma et al.,<sup>1</sup>  $11.65^\circ \pm 7.51^\circ$  in the study of Wei et al.<sup>27</sup> The present study reported an average degree of local segmental kyphosis of  $4.7^\circ$ , underlining the correctional efficacy of this procedure, which would also explain the high scores regarding the quality of life.

Instrumentation of the osteoporotic spine frequently constituted a challenge because patients with low bone mineral density (as the ones in the present study) were noted to be associated with postoperative implant-related complications, including pedicle screw loosening as a result of the fact that screws were subjected to a high force during the correction phase of the PVCR.<sup>2,3</sup> To overcome these problems, larger diameter and longer screws were recommended to increase the surface area and minimize screw toggle within the pedicle.<sup>35</sup> Cement augmented pedicle screw technique was also highly advised in the osteoporotic spine because of enhancing the pull-out strength of the screws, providing a stable screw-bone cement-bone interface to distribute the stresses and assuring a strong fixation resulting in the reduction of the postoperative incidence of screw failure and loosening.<sup>1,36,37</sup> We placed fenestrated pedicle screws 2 levels cranial and caudal of the OVF combined with application of 2-mL PMMA bone cement inside every screw, combined with prophylactic vertebroplasty at the adjacent cranial and caudal levels.

The present study reported excellent clinical results yielded by modified PVCR combined with anterior column restoration. Our results were in conjunction with the previous studies that also reported significant improvements in clinical scores, including VAS, JOA, and ODI.<sup>1,2,9,27</sup> However, this study, for the

first time in the literature, by reporting about SF-36 scores, also showed that as a result of modified PVCR combined with anterior column restoration, significant improvements regarding the quality of life could also be achieved.

Application of PVCR to the osteoporotic spine was associated with a wide spectrum of complications. Wei et al.<sup>27</sup> reported 3 of 24 patients with intraoperative dural injury with cerebrospinal fluid leakage, Dreimann et al.<sup>2</sup> reported 3 of 10 rates of complications (1 posterior ligamentous dislocation requiring revision, 1 wound infection requiring debridement, 1 serious clinical deterioration); Ma et al.<sup>1</sup> reported 2 of 26 patients with dural injury and venous thrombosis, 2 of 26 recurrent lumbar back-pain. Regarding the relatively short average follow-up duration of the studies mentioned above (18 to 32 months), it is expected that no implant-related complication was reported so far. In contrast, the present study reported 2 cases of cage subsidence resulting in revision and underlining that this system might also fail and should further be optimized. The present study with 5 years of minimal follow-up duration reported that distal junctional level fracture and cage subsidence could be encountered, and surgeons performing PVCR to the osteoporotic spine should be aware of that in the long term.

One of the limitations of the present study is its retrospective nature. Another limitation is the relatively limited number of patients, which is owed to the strict inclusion criteria defined to obtain a homogenous group of patients.

## CONCLUSION

Application of modified PVCR together with anterior column restoration by using an expandable titanium cage to geriatric patients with severe OVFs' sequela was detected to yield excellent clinical and functional outcomes, in addition to adequate correction of kyphosis together with successful sagittal balance. This approach was shown to provide significant improvement regarding the quality of life in geriatric patients.

## CONFLICT OF INTEREST

The authors have nothing to disclose.

## REFERENCES

1. Ma Z, Jiao J, Yang D, et al. Posterior vertebral column resection combined with bone cement augmentation of pedicle screw fixation for treatment of severe vertebral compression

- fractures with kyphotic deformity: a retrospective case series. *Clin Spine Surg* 2020;33:E269-75.
2. Dreimann M, Hempfing A, Stangenberg M, et al. Posterior vertebral column resection with 360-degree osteosynthesis in osteoporotic kyphotic deformity and spinal cord compression. *Neurosurg Rev* 2018;41:221-8.
  3. Nakajima H, Uchida K, Honjoh K, et al. Surgical treatment of low lumbar osteoporotic vertebral collapse: a single-institution experience. *J Neurosurg Spine* 2016;24:39-47.
  4. Vaccaro AR, Oner C, Kepler CK, et al. AOSpine thoracolumbar spine injury classification system: fracture description, neurological status, and key modifiers. *Spine (Phila Pa 1976)* 2013;38:2028-37.
  5. Neviaser A, Toro-Arbelaez JB, Lane JM. Is kyphoplasty the standard of care for compression fractures in the spine, especially in the elderly? *Am J Orthop (Belle Mead NJ)* 2005;34:425-9.
  6. Garfin SR, Yuan HA, Reiley MA. New technologies in spine: kyphoplasty and vertebroplasty for the treatment of painful osteoporotic compression fractures. *Spine (Phila Pa 1976)* 2001;26:1511-5.
  7. Ensrud KE, Schousboe JT. Clinical practice. Vertebral fractures. *N Engl J Med* 2011;364:1634-42.
  8. Schroeder GD, Kepler CK, Kurd MF, et al. Is it necessary to extend a multilevel posterior cervical decompression and fusion to the upper thoracic spine? *Spine (Phila Pa 1976)* 2016;41:1845-9.
  9. Sehmisch S, Lehmann W, Dreimann M, et al. Posterior vertebral column resection for correction of kyphotic deformity due to osteoporotic fractures of the thoracic spine. *Oper Orthop Traumatol* 2019;31:311-20.
  10. Bouza C, Lopez-Cuadrado T, Almendro N, et al. Safety of balloon kyphoplasty in the treatment of osteoporotic vertebral compression fractures in Europe: a meta-analysis of randomized controlled trials. *Eur Spine J* 2015;24:715-23.
  11. Rzewuska M, Ferreira M, McLachlan AJ, et al. The efficacy of conservative treatment of osteoporotic compression fractures on acute pain relief: a systematic review with meta-analysis. *Eur Spine J* 2015;24:702-14.
  12. Uchida K, Kobayashi S, Nakajima H, et al. Anterior expandable strut cage replacement for osteoporotic thoracolumbar vertebral collapse. *J Neurosurg Spine* 2006;4:454-62.
  13. Aydogan M, Ozturk C, Karatoprak O, et al. The pedicle screw fixation with vertebroplasty augmentation in the surgical treatment of the severe osteoporotic spines. *J Spinal Disord Tech* 2009;22:444-7.
  14. Serlin RC, Mendoza TR, Nakamura Y, et al. When is cancer pain mild, moderate or severe? Grading pain severity by its interference with function. *Pain* 1995;61:277-84.
  15. Fairbank J. Use of Oswestry Disability Index (ODI). *Spine (Phila Pa 1976)* 1995;20:1535-7.
  16. Kuribayashi M, Takahashi KA, Fujioka M, et al. Reliability and validity of the Japanese Orthopaedic Association hip score. *J Orthop Sci* 2010;15:452-8.
  17. Frankel HL, Hancock DO, Hyslop G, et al. The value of postural reduction in the initial management of closed injuries of the spine with paraplegia and tetraplegia. I. Paraplegia 1969;7:179-92.
  18. Silverman SL. The clinical consequences of vertebral compression fracture. *Bone* 1992;13 Suppl 2:S27-31.
  19. Gold DT. The clinical impact of vertebral fractures: quality of life in women with osteoporosis. *Bone* 1996;18(3 Suppl): 185S-189S.
  20. Lombardi IJ, Oliveira LM, Mayer AF, et al. Evaluation of pulmonary function and quality of life in women with osteoporosis. *Osteoporos Int* 2005;16:1247-53.
  21. Kado DM, Browner WS, Palermo L, et al. Vertebral fractures and mortality in older women: a prospective study. Study of Osteoporotic Fractures Research Group. *Arch Intern Med* 1999;159:1215-20.
  22. Fang X, Yu F, Fu S, Song H. Intravertebral clefts in osteoporotic compression fractures of the spine: incidence, characteristics, and therapeutic efficacy. *Int J Clin Exp Med* 2015;8:16960-8.
  23. Li Z, Liu T, Yin P, et al. The therapeutic effects of percutaneous kyphoplasty on osteoporotic vertebral compression fractures with or without intravertebral cleft. *Int Orthop* 2019;43:359-65.
  24. Jarvik JG, Kallmes DE, Mirza SK. Vertebroplasty: learning more, but not enough. *Spine (Phila Pa 1976)* 2003;28:1487-9.
  25. Rho YJ, Choe WJ, Chun YI. Risk factors predicting the new symptomatic vertebral compression fractures after percutaneous vertebroplasty or kyphoplasty. *Eur Spine J* 2012;21:905-11.
  26. Nagad P, Rawall S, Kundnani V, et al. Postvertebroplasty instability. *J Neurosurg Spine* 2012;16:387-93.
  27. Wei H, Dong C, Zhu Y. Posterior fixation combined with vertebroplasty or vertebral column resection for the treatment of osteoporotic vertebral compression fractures with intravertebral cleft complicated by neurological deficits. *Biomed Res Int* 2019;2019:4126818.
  28. Liu F, Chen Z, Lou C, et al. Anterior reconstruction versus



- posterior osteotomy in treating Kummell's disease with neurological deficits: a systematic review. *Acta Orthop Traumatol Turc* 2018;52:283-8.
29. Suk SI, Kim JH, Lee SM, et al. Anterior-posterior surgery versus posterior closing wedge osteotomy in posttraumatic kyphosis with neurologic compromised osteoporotic fracture. *Spine (Phila Pa 1976)* 2003;28:2170-5.
30. Cho Y. Corpectomy and circumferential fusion for advanced thoracolumbar Kummell's disease. *Musculoskelet Surg* 2017; 101:269-74.
31. Lenke LG, Newton PO, Sucato DJ, et al. Complications after 147 consecutive vertebral column resections for severe pediatric spinal deformity: a multicenter analysis. *Spine (Phila Pa 1976)* 2013;38:119-32.
32. Zhu Z, Wang X, Qian B, et al. Loss of correction in the treatment of thoracolumbar kyphosis secondary to ankylosing spondylitis: a comparison between Smith-Petersen osteotomies and pedicle subtraction osteotomy. *J Spinal Disord Tech* 2012;25:383-90.
33. Glassman SD, Bridwell K, Dimar JR, et al. The impact of positive sagittal balance in adult spinal deformity. *Spine (Phila Pa 1976)* 2005;30:2024-9.
34. Krishnakumar R, Lenke LG. "Sternum-into-abdomen" deformity with abdominal compression following osteoporotic vertebral compression fractures managed by 2-level vertebral column resection and reconstruction. *Spine (Phila Pa 1976)* 2015;40:E1035-9.
35. Bianco RJ, Arnoux PJ, Wagnac E, et al. Minimizing pedicle screw pullout risks: a detailed biomechanical analysis of screw design and placement. *Clin spine Surg* 2017;30:E226-32.
36. Chandra VVR, Prasad BCM, Jagadeesh MA, et al. Segmental polymethylmethacrylate-augmented fenestrated pedicle screw fixation for lumbar spondylolisthesis in patients with osteoporosis - A case series and review of literature. *Neurol India* 2017;65:89-95.
37. Choma TJ, Pfeiffer FM, Swope RW, et al. Pedicle screw design and cement augmentation in osteoporotic vertebrae: effects of fenestrations and cement viscosity on fixation and extraction. *Spine (Phila Pa 1976)* 2012;37:E1628-32.