

Superior segmental optic nerve hypoplasia accompanied by progressive normal-tension glaucoma

Yoshio Yamazaki
Fukuko Hayamizu

Department of Ophthalmology,
Division of Visual Science, Nihon
University School of Medicine,
Tokyo, Japan

Abstract: This is the first case report of a superior segmental optic hypoplasia (SSOH) combined with normal-tension glaucoma accompanied by a progressive glaucomatous visual field defect. A 40-year-old man, incidentally diagnosed as having bilateral SSOH, had disc hemorrhage associated with expansion of the width of a retinal nerve fiber layer defect and deterioration of a visual field defect in the right eye during the follow-up period. His left eye showed a stable visual field. The diurnal variation in intraocular pressure (IOP) showed a higher mean IOP in his right eye compared with his left eye, although both IOPs remained under 21 mmHg.

Keywords: visual field defects, disc hemorrhage, retinal nerve fiber layer defect, intraocular pressure

Introduction

Superior segmental optic nerve hypoplasia (SSOH) is defined as a nonprogressive congenital anomaly affecting the optic nerve head and is characterized by a localized inferior visual field defect, superior retinal nerve fiber layer (RNFL) defect, and good visual acuity.¹ Because SSOH has often been misdiagnosed as glaucomatous optic neuropathy (GON) when the disc is cupped, differentiation of this condition is of clinical importance. In particular, normal-tension glaucoma (NTG) resembles SSOH in its localized rim thinning and lack of increased intraocular pressure (IOP). The best method to differentiate the two conditions is to confirm the stability of the optic disc appearance and visual field sensitivity over time. Ohguro and Ohguro² documented a case of bilateral SSOH accompanied with GON in an initial clinical report, but did not report observation of the progression of GON.

To the best of our knowledge, no clinical case showing that eyes with SSOH had progressive glaucomatous visual field changes over time has ever been reported prior to this interesting case that presented SSOH in conjunction with NTG.

Case report

A 40-year-old man with no systemic disease and no family history of glaucoma or maternal diabetes mellitus visited a private clinic for a fundus examination in September 2002. His best corrected visual acuity was 1.2×-8.0 D OD and 0.6×-8.0 D OS. No abnormalities were detected in pupil reaction, color vision, eye position, ocular movement, the anterior segment of the eye, or ocular media. His IOP was 12 mmHg in both eyes. The gonioscopic examination revealed a normal wide-open angle with deep pigmentation in both eyes. The fundus examination revealed a relatively superior entrance to the central retinal artery, thinning of the superior peripapillary RNFL,

Correspondence: Yoshio Yamazaki
Department of Ophthalmology, Division
of Visual Science, Nihon University
School of Medicine,
30-1 Oyaguchikami-machi, Itabashi-ku,
Tokyo 173-8610, Japan
Tel +81 3 3972 8111
Fax +81 3 5995 3495
Email yamazaki.yoshio@nihon-u.ac.jp

a superior peripapillary scleral halo, and superior optic disc pallor in both eyes. In addition, a temporal papilla-macular RNFL defect and thinning of the RNFL in the inferotemporal region appeared in the right eye. Thinning of the RNFL in the superotemporal region and a neuroretinal rim defect associated with inferior peripapillary atrophy were found in the left eye. As shown in Figure 1, a visual field examination with the Humphrey field analyzer program 30-2 (Carl Zeiss Meditec, Dublin, CA) showed a paracentral scotoma and a dense sectorial defect connecting to the blind spot in the inferotemporal field in the right eye. An irregular arcuate scotoma and an inferior nasal step connecting to the inferior region were found in the left eye. Based on these findings, the patient was diagnosed as having bilateral SSOH with suspected glaucoma, and began receiving annual ophthalmic examinations.

He complained of a right visual disturbance and was referred to our clinic in April 2007. In comparison with the previous reference fundus photograph from 2002 (Figure 2), in the right eye, it appeared that disc cupping was increased, that a new disc hemorrhage was associated with the RNFL defect in the superotemporal region, and that there was expansion of the width of the RNFL defect in the temporal papilla-macular bundle. Figure 3 shows the time-course change of the visual field defect in both eyes from 2003 to 2007. A visual field examination showed that a paracentral deep scotoma had developed in the right eye, but that an irregular arcuate scotoma was stable in the left eye.

After a visit to our hospital, the patient was admitted for examination of the diurnal variation in IOP. As shown in Figure 4, the diurnal variation in IOP was a double-variation type³ in that IOPs were at a low phase at 6 am and rose to a maximum IOP from 8 am to 10 am, after which there was a fall to a low level in the afternoon, followed by a second

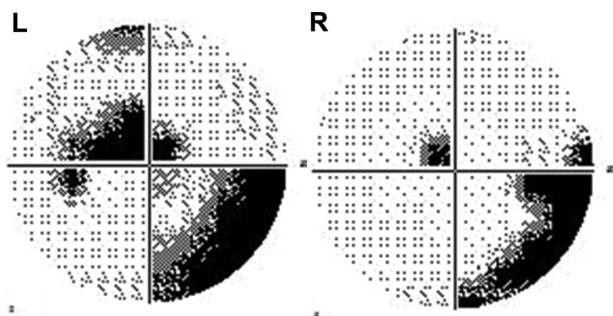


Figure 1 Visual fields at the initial visit.

Notes: A relative sensitivity loss in the papilla-macular region and a dense sectorial defect connecting to the blind spot were found in the right eye, and an irregular arcuate scotoma and an inferior nasal step connecting to the inferior region were found in the left eye.

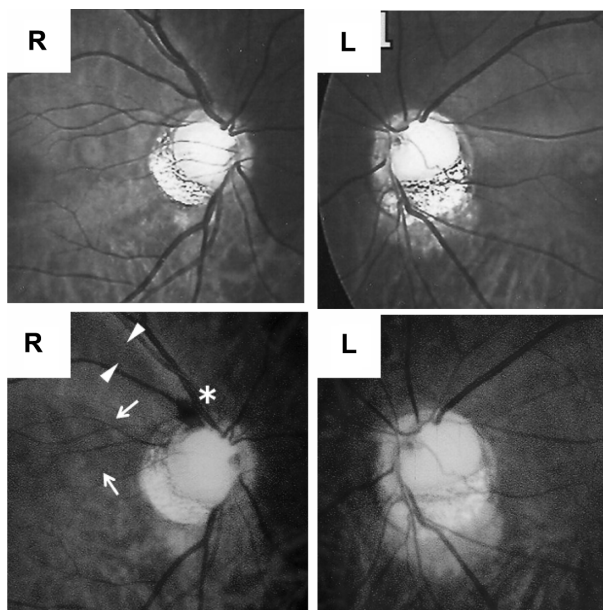


Figure 2 Red-free fundus photographs of the patient taken in 2002 (top) and 2007 (bottom).

Notes: The right eye showed a newly developed disc hemorrhage (asterisk) associated with the RNFL defect in the superior-temporal region (triangles), and expansion of the width of the RNFL defect in the temporal papillo-macular region (arrows).

Abbreviation: RNFL, retinal nerve fiber layer.

rise between 4 pm and 6 pm. His highest IOP did not exceed 21 mmHg, and the mean IOP was 17.1 mmHg in the right eye and 15.7 mmHg in the left eye. He had no other apparent ocular, cardiovascular, neurosurgical, or rhinological abnormalities that would account for the visual field progression or the optic disc change.

According to these clinical symptoms, the patient's right eye was diagnosed as SSOH combined with NTG, accompanied by progressive glaucomatous visual field defects. Beta-blocker solution was started as topical medication and the IOPs in his right eye were controlled at approximately 12 mmHg. No progression of the visual field defect was found.

Discussion

SSOH resembles GON in that localized rim thinning is seen when the optic disc shows cupping. NTG is common in Japan and its prevalence increases with age.⁴ The similarity of these two conditions should be taken into consideration because both conditions lack elevated IOP. Yamamoto et al⁵ reported that the prevalence of SSOH is 0.3% in the Japanese population, based on data from large-scale screening for eye disease. Awareness of SSOH should increase in clinical practice.

In the present case, IOPs did not exceed 21 mmHg and there were no alternative causes of glaucoma-like visual field defects. We found that the asymmetry of the progressive

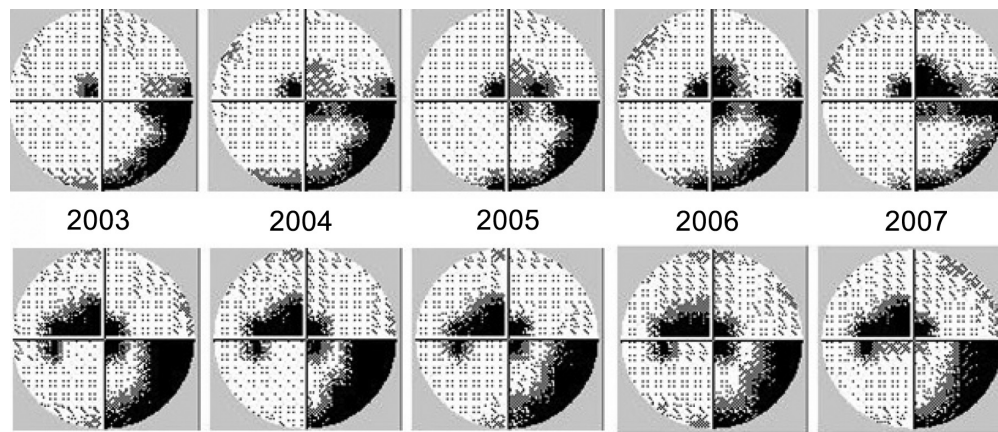


Figure 3 Time-course change of the visual field defects in the right eye (top) and the left eye (bottom).
Note: The right eye showed the development of a paracentral deep scotoma.

change in the visual field damage corresponded to the asymmetry of the mean value in the diurnal variation of IOP. The association between elevated IOP has been unquestionably demonstrated to be a risk factor for development and progression of GON.⁶⁻⁹ It was established that, even if IOPs remained less than 21 mmHg, lowering of the IOP by at least 30% delayed the progression of visual field defects in patients that were found to have GON.¹⁰ In patients with NTG whose mean IOP was asymmetric, the visual field defects appeared to be greater on the side with a higher mean IOP compared with those with a lower mean IOP.^{11,12} These findings suggest that the progression of the visual field defect in the right eye might have been affected by IOP.

The present case showed a disc hemorrhage associated with expansion of the width of the RNFL defect and deterioration of visual field defects in the right eye. Optic disc

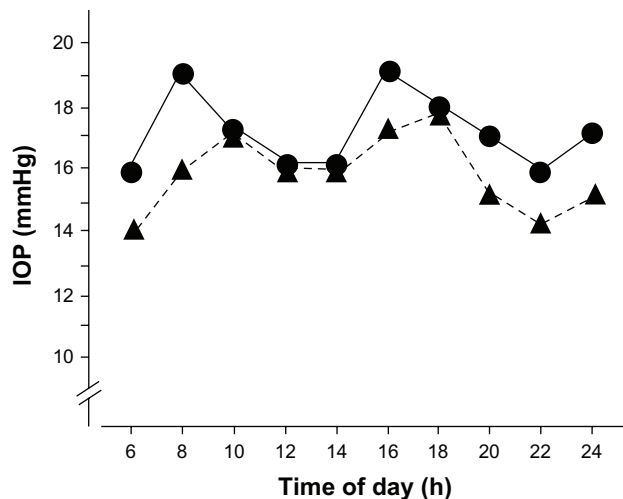


Figure 4 Diurnal variation of intraocular pressure (IOP) in the right eye (●) and the left eye (▲).

hemorrhage has previously been reported to have a predictive value in patients with glaucoma; in these studies, development and progression of visual field defects were seen more often in patients with hemorrhage than in patients with equal levels of IOP but without hemorrhage.¹³⁻¹⁶ Optic disc hemorrhage was described as present on the border or adjacent to the border between the RNFL defect and the apparently healthy-looking RNFL.^{17,18} The presence of disc hemorrhage associated with a RNFL defect and expansion of the width of the RNFL defect in the right eye suggested that the pathologic process of glaucoma might have occurred in this case during the follow-up period. Therefore, taken together, these findings suggest a diagnosis of NTG in addition to SSOH.

As this patient had high myopia, it is important to differentiate between glaucomatous changes and myopic changes in the development of a paracentral scotoma. It is well known that in high myopia, visual field defects parallel those seen with chorioretinal degeneration.¹⁹ In this case, because there was absence of abnormality in the macular region, the development of visual field defects was considered for the progression of GON. Myopic glaucoma has previously been defined as a subclass of primary open-angle glaucoma, including NTG, according to classification of the optic disc appearance.²⁰ The characteristics of myopic glaucoma were described as a tilted disc with a myopic temporal crescent, and a thinning of the superior rim, inferior rim, or both. The optic disc of this case showed similarities with myopic glaucoma, and it might be diagnosed as SSOH accompanied by myopic NTG.

This is the first clinical report of an observation of SSOH merging with NTG. It is important that SSOH is defined as a specific form of congenital optic disc or optic nerve anomaly characterized by relative hypoplasia of the superior portion

of the optic nerve head. To date, several investigators have noted that visual field defects and optic disc appearance have remained unchanged in eyes with SSOH, and they have mentioned that patients diagnosed with SSOH do not need follow-up examination.^{2,21,22} In the present case, characteristic disc findings were observed and, in addition, progressive glaucomatous visual field changes were disclosed. However, the best way to identify the type of SSOH that would merge with GON is still unclear. Long-term follow-up involving fundus examination and visual field examination is needed. At this point, the adequate interval of long-term follow up involving fundus examination and visual field examination is controversial, because there has been a lack of evidence-based guidance on the frequency of visual field examination that is required to identify a clinically meaningful rate of change in glaucoma.²³ Further research is needed to clarify the association between SSOH and NTG.

Disclosure

The authors report no conflicts of interest in this work.

References

- Kim RY, Hoyt WF, Lessell S, Narahara MH. Superior segmental optic hypoplasia. A sign of maternal diabetes. *Arch Ophthalmol*. 1989;107(9):1312–1315.
- Ohguro I, Ohguro H. A case of superior segmental optic hypoplasia accompanied by a glaucomatous optic neuropathy. *Clin Ophthalmol*. 2008;2(2):475–478.
- Langley D, Swanljung H. Ocular tension in glaucoma simplex. *Br J Ophthalmol*. 1951;35(8):445–458.
- Iwase A, Suzuki Y, Araie M, et al; the Tajimi Study Group, Japan Glaucoma Society. The prevalence of primary open-angle glaucoma in Japanese. The Tajimi Study. *Ophthalmology*. 2004;111(9):1641–1648.
- Yamamoto T, Sato M, Iwase K. Superior segmental optic hypoplasia found in Tajimi Eye Health Care Project participants. *Jpn J Ophthalmol*. 2004;48(6):578–583.
- Leske MC, Heijl A, Hussein M, et al; the Early Manifest Glaucoma Trial Group. Factors for glaucoma progression and the effect of treatment: the Early Manifest Glaucoma Trial. *Arch Ophthalmol*. 2003;121(1):48–56.
- Kass MA, Heuer DK, Higginbotham EJ, et al. Ocular Hypertension Treatment Study: a randomized trial determines that topical ocular hypertensive medication delays or prevent the onset of primary-open angle glaucoma. *Arch Ophthalmol*. 2002;120(6):701–713.
- Lichter PR, Musch DC, Gillespie BW, et al; the CIGTS Study Group. Interim clinical outcomes in the Collaborative Initial Glaucoma Treatment Study comparing initial treatment randomized to medications or surgery. *Ophthalmology*. 2001;108(11):1943–1953.
- The AGIS Investigators. The Advanced Glaucoma Intervention Study (AGIS): 7. The relationship between control of intraocular pressure and visual field deterioration. The AGIS Investigators. *Am J Ophthalmol*. 2000;130(4):429–440.
- Collaborative Normal-Tension Glaucoma Study Group. The effectiveness of intraocular pressure reduction in the treatment of normal-tension glaucoma. *Am J Ophthalmol*. 1998;126(4):498–505.
- Cartwright MJ, Anderson DR. Correlation of asymmetric damage with asymmetric intraocular pressure in normal-tension glaucoma (low-tension glaucoma). *Arch Ophthalmol*. 1988;106(7):898–900.
- Crichton A, Drance SM, Douglas GR, Schulzer M. Unequal intraocular pressure and its relation to asymmetric visual field defects in low-tension glaucoma. *Ophthalmology*. 1989;96(9):1312–1314.
- Drance SM, Fairclough M, Butler DM, Kottler MS. The importance of disc hemorrhage in the prognosis of chronic open angle glaucoma. *Arch Ophthalmol*. 1977;95(2):226–228.
- Ishida K, Yamamoto T, Sugiyama K, Kitazawa Y. Disc hemorrhage is a significantly negative prognostic factor in normal-tension glaucoma. *Am J Ophthalmol*. 2000;129(6):707–714.
- Drance S, Anderson DR, Schulzer M; the Collaborative Normal-Tension Glaucoma Study Group. Risk factors for progression of visual field abnormalities in normal-tension glaucoma. *Am J Ophthalmol*. 2001;131(6):699–708.
- Nakagami T, Yamazaki Y, Hayamizu F. Prognostic factors for progression of visual field damage in patients with normal-tension glaucoma. *Jpn J Ophthalmol*. 2006;50(1):38–43.
- Sugiyama K, Uchida H, Tomita G, Sato Y, Iwase A, Kitazawa Y. Localized wedge-shaped defects of retinal nerve fiber layer and disc hemorrhage in glaucoma. *Ophthalmology*. 1999;106(9):1762–1767.
- Nitta K, Sugiyama K, Higashide T, Ohkubo S, Tanahashi T, Kitazawa Y. Does the enlargement of retinal nerve fiber layer defects relate to disc hemorrhage or progressive visual field loss in normal-tension glaucoma? *J Glaucoma*. 2011;20(3):189–195.
- Harrington DO. Myopia. In: Harrington DO, editor. *The Visual Fields: A Textbook and Atlas of Clinical Perimetry*. St Louis: Mosby; 1956:152.
- Nicolela MT, Drance SM. Various glaucomatous optic nerve appearances. clinical correlations. *Ophthalmology*. 1996;103(4):640–649.
- Hayashi K, Tomidokoro A, Aihara M, Tsuji H, Shirato S, Araie M. Long-term follow-up of superior segmental optic hypoplasia. *Jpn J Ophthalmol*. 2008;52(5):412–414.
- Hashimoto M, Ohtsuka K, Nakagawa T, Hoyt WF. Topless optic disc syndrome without maternal diabetes mellitus. *Am J Ophthalmol*. 1999;128(1):111–112.
- Chauhan BC, Garway-Heath DF, Goñi FJ, et al. Practical recommendations for measuring rates of visual field change in glaucoma. *Br J Ophthalmol*. 2008;92(4):569–573.

Clinical Ophthalmology

Publish your work in this journal

Clinical Ophthalmology is an international, peer-reviewed journal covering all subspecialties within ophthalmology. Key topics include: Optometry; Visual science; Pharmacology and drug therapy in eye diseases; Basic Sciences; Primary and Secondary eye care; Patient Safety and Quality of Care Improvements. This journal is indexed on

Submit your manuscript here: <http://www.dovepress.com/clinical-ophthalmology-journal>

Dovepress

PubMed Central and CAS, and is the official journal of The Society of Clinical Ophthalmology (SCO). The manuscript management system is completely online and includes a very quick and fair peer-review system, which is all easy to use. Visit <http://www.dovepress.com/testimonials.php> to read real quotes from published authors.