Journal of Advanced Research (2017) 8, 89–97

Cairo University

Journal of Advanced Research

REVIEW

New insights into HCV-related rheumatologic disorders: A review

Patrice Cacoub [a,b,c,d,*], **Cloé Comarmond** [a,b,c,d]

[a] *Sorbonne Universités, UPMC Univ Paris 06, UMR 7211, and Inflammation-Immunopathology-Biotherapy Department (DHU i2B), F-75005 Paris, France*
[b] *INSERM, UMR_S 959, F-75013 Paris, France*
[c] *CNRS, FRE3632, F-75005 Paris, France*
[d] *AP-HP, Groupe Hospitalier Pitié-Salpêtrière, Department of Internal Medicine and Clinical Immunology, F-75013 Paris, France*

GRAPHICAL ABSTRACT

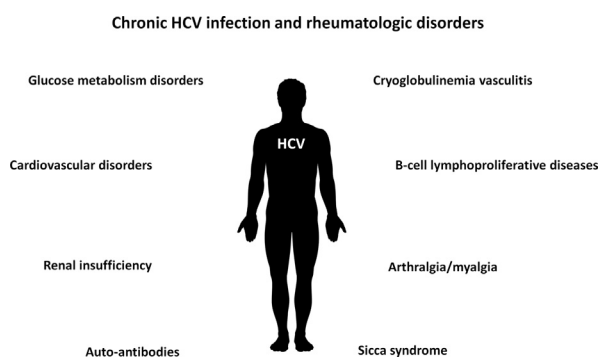

ARTICLE INFO

Article history:
Received 15 April 2016
Received in revised form 17 July 2016
Accepted 18 July 2016
Available online 25 July 2016

ABSTRACT

Hepatitis C virus (HCV) infected patients are known to be exposed to major liver complications i.e. cirrhosis and hepatocellular carcinoma. In addition, many extrahepatic manifestations including rheumatologic disorders have been reported in up to two-third of HCV infected patients. These manifestations include frank auto-immune and rheumatic diseases (such as arthralgia, myalgia, arthritis, sicca syndrome and vasculitis) which may dominate the course

* Corresponding author. Fax: +33 1 42 17 80 33.
E-mail address: patrice.cacoub@aphp.fr (P. Cacoub).

Peer review under responsibility of Cairo University.

Production and hosting by Elsevier

http://dx.doi.org/10.1016/j.jare.2016.07.005

Keywords:
HCV
Cryoglobulinemia
Vasculitis
Lymphoma
Arthritis
Treatment

of infection. Until recently, the standard of care of HCV has been the use of interferon-alpha based regimens, which not only had limited effectiveness in HCV cure but were poorly tolerated. In patients with rheumatic diseases interferon-based regimens may be problematic given their association with a wide variety of autoimmune toxicities. Recent therapeutic advances with new direct anti-HCV therapies (interferon-free) which are more effective and better tolerated, make screening for this comorbidity in patients with rheumatic disorders more important than ever. This review aimed to outline main HCV extrahepatic with a special focus on rheumatologic manifestations.



Professor Patrice Cacoub is currently a Professor of Internal Medicine at the Pierre and Marie Curie University and Head of the Vasculitis Unit in the Department of Internal Medicine and Clinical Immunology, La Pitié-Salpêtrière Hospital, Paris, FRANCE. During his career, Professor Cacoub has conducted research on auto-immune diseases, hepatitis C and B virus, HIV, peripheral neuropathies, anemia, and vascular medicine. He has been involved in the development of a number of national and international guidelines, clinical trials and initiatives to improve clinical care, particularly in hepatitis C treatment, extrahepatic manifestations associated to HCV, co-infection with HCV and HIV and in peripheral arterial disease.

Cloé Comarmond, M.D., M.Sc., is a resident in Internal Medicine at the Pierre and Marie Curie University, Paris, France. She is specialized in immunology, with special interest in autoimmune diseases and vasculitis.

Introduction

Hepatitis C Virus (HCV) infection, a major global health problem leading to heavy costs, is present in 150–170 million people, including 19 million people in Europe [1]. Liver complications, including cirrhosis and liver cancer, are currently reported during chronic HCV infection, with an estimated liver-related mortality of 350,000 people/year. Additionally, extrahepatic manifestations are presented in up to two-third of patients [2]. Several of these manifestations are common and well-described while others are infrequent [3–5]. In the literature, autoimmune and lymphoproliferative diseases are well-known HCV-related disorders [6]. Other more recently reported HCV-associated disorders include cardiometabolic, renal, and neurocognitive disorders. With the arrival of direct acting antivirals (DAAs), the perspective of HCV eradication is important in a therapeutic and preventive aspect, for liver and non-liver consequences of the disease. This review aimed to outline most of rheumatologic HCV extrahepatic manifestations that are currently deeper investigated.

Cryoglobulinemia vasculitis

Mixed cryoglobulinemia vasculitis (CryoVas) is a systemic vasculitis which leads to clinical manifestations ranging from purpura, arthralgia and fatigue to more serious lesions with neurologic and renal involvement [7]. Circulating mixed cryoglobulins are detected in 40–60% of patients chronically infected with HCV whereas overt CryoVas is observed in only 5–10% of cases. HCV infection represents the cause of CryoVas in 70–80% of cases [7–9]. The disease expression may range from mild symptoms to fulminant life-threatening complications. The main skin symptom is a palpable purpura; chronic cutaneous ulcers, Raynaud's phenomenon, acrocyanosis, and digital ulcerations can also occur [7]. Patients present with arthralgia of large peripheral joints in 70% of cases, rarely with arthritis. The most frequently described neurologic manifestation is a distal sensory or sensory-motor polyneuropathy, with painful, asymmetric paresthesia. Multiple mononeuropathy may occur less frequently. An acute or chronic membranoproliferative glomerulonephritis with subendothelial deposits represents the large majority of cryoglobulinemia-renal diseases, strongly linked with the type II IgM kappa mixed cryoglobulinemia (MC). It presents usually with proteinuria, hematuria and a variable intensity of renal insufficiency.

Cryoglobulinemia is defined as the presence protein which precipitates in the serum at 4 °C during 7 days and which dissolved at 37 °C. During chronic HCV infection, mixed cryoglobulinemia are characterized as type II or type III cryoglobulins which consist of polyclonal IgG with monoclonal or polyclonal IgM with rheumatoid factor (RF) activity, respectively [10]. During follow-up, improvement is assessed by the serum level of cryoglobulinemia and surrogate markers (C4, CH50, RF).

Main predictive factors of CryoVas in HCV-infected patients are advanced age, longer duration of infection, type II mixed cryoglobulin, and clonal B-cell expansions in both the blood and liver. The worse pronostic factors are an age older than 60 years and renal manifestations, with a 5 year survival ranging from 90% to 50% in case of kidney involvement. Other causes of mortality include liver disease, cardiovascular disease, infectious disease and lymphoma [11]. Among 231 patients, 79 of 97 deaths were linked to vasculitis (46%), cancer/hemopathy (23%), or liver disease (13%) [12]. HCV-CryoVas may result in progressive (renal involvement) or acute (gut, cardiac, CNS, pulmonary hemorrhage) life-threatening

organ damage, with mortality rate ranging from 20% to 80% [13,14].

Multiple factors predispose patients to develop a CryoVas. HCV-lymphocytes interaction directly modulates B- and T-cell function and results in polyclonal activation and expansion of B-cell producing IgM with RF activity [15]. Regulatory T cell, known to control self-tolerance, is reduced in HCV-CryoVas patients. Regulatory T cell deficiency may contribute to autoreactive B-cell expansion driving autoimmune manifestations in HCV-CryoVas patients [16,17]. HLA-DR11 increases the risk of CryoVas whereas HLA-DR7 decreases the risk of type II mixed cryoglobulin production [18]. A SNP within an intronic region of NOTCH4 ($p = 6.2 * 10^{-9}$) and another between HLA-DRB1 and HLA–DQA1 ($p = 1.2 * 10^{-7}$) on chromosome 6 were associated with HCV-CryoVas [19]. A high prevalence of homozygosity and a great frequency of a particular allele of the BAFF promoter were found in HCV-CryoVas patients compared to HCV patients [20]. Different expression profiles of microRNAs in peripheral blood mononuclear cell associated with lymphoproliferative and autoimmune disorders have been reported [21]. Today, no specific virologic factors have been found.

Most HCV-CryoVas manifestations have been shown to disappear after HCV clearance post antiviral therapy with pegylated interferon (IFN) plus ribavirin [22,23] whereas virological relapsers usually relapse for the CryoVas [24]. Current treatment of HCV-CryoVas is guided by organ involvement and the severity of the disease (Fig. 1). In case of persistent CryoVas manifestations in patients with a sustained virologic response (SVR), another underlying condition should be considered, especially B-cell lymphoma [25]. Combination therapy with pegylated-IFN/ribavirin plus a NS3/4A protease inhibitor (boceprevir or telaprevir) showed at week 24 post-treatment that 20/30 (67%) patients were complete clinical and SVRs [26], with serious adverse events almost fifty percent. Use of Peg-IFN/ribavirin in combination with boceprevir for 48 weeks in 35 HCV GT1 patients showed a drastic reduction of the cryocrit values, and an improvement of CryoVas symptoms [27]. New interferon-free DAAs are now available which facilitate shortened courses of IFN-free antivirals associated with SVR rates >95% and few side effects. International guidelines (i.e., EASL 2015) [28] state that treatment should be scheduled, not deferred, for patients with clinically significant extra-hepatic manifestations, like CryoVas. In a recent French study, sofosbuvir (400 mg/day) plus ribavirin (200–1400 mg/day) combination for 24 weeks was associated with a high rate of complete clinical response of CryoVas (87.5%) and a low rate of serious adverse events (8.3%) [29]. Other recent studies report both safety and efficacy of IFN-free DAA antivirals including non SOF-based regimens, in difficult-to-treat patients [30,31]. Sise et al. [32] have reported a retrospective case series of twelve HCV-CryoVas patients treated with SOF-based regimens [median age 61 years, 58% male, 50% cirrhotic]. All patients had undetectable HCV RNA by week 4. A SVR12 was achieved in 10/12 (83%) patients. Individual eGFR changes showed a positive impact in two out of seven patients with active glomerulonephritis; there was a reduction in proteinuria in 3/3 cases. Only two (17%) patients experienced serious adverse events.

Rituximab has proved a clear benefit in CryoVas as it targets B-cells which are responsible for cryoglobulin production [33–37]. In a randomized trial rituximab showed a better efficacy than conventional immunosuppressants [38]. Similar results have been reported in a placebo controlled trial [39]. There was no risk of viral reactivation in HCV patients, contrary to HBV infection [40]. Rituximab plus pegylated-IFN/ribavirin compared to pegylated-IFN/ribavirin led to a shorter time to clinical remission, better renal response rate, and higher rates of cryoglobulin clearance [41,42].

To summarize, in HCV-CryoVas with mild to moderate disease, an optimal antiviral IFN-free treatment should be given alone. For patients with severe vasculitis (i.e. worsening of renal function, mononeuritis multiplex, extensive skin disease, and intestinal ischemia) control of disease with rituximab, with or without plasmapheresis, is usually required and antiviral IFN-free therapy should be started at the same time [43]. Low-dose corticosteroids may help to control inflammatory signs such arthralgia but do not succeed in case of major organ involvement. Other immunosuppressants should be given only in case of refractory forms of CryoVas, frequently associated with underlying B-cell lymphoma [44].

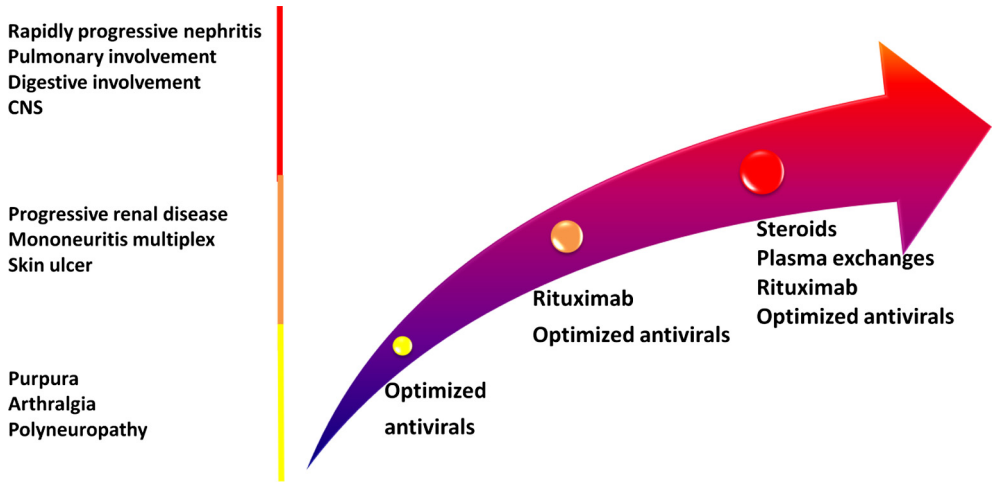

Fig. 1 Therapeutic strategies in HCV-CryoVasc.

B-cell lymphoproliferative diseases

Initially, few cohorts reported a high prevalence of HCV infection in patients with B-cell non-Hodgkin's lymphoma (B-NHL) [45,46], then this observation was confirmed in meta-analyses [47–51]. HCV chronic infection was associated with marginal zone B-NHL (OR 2.47) and diffuse large B-NHL (OR 2.24). A serum IgMk gammopathy has been frequently noted in HCV patients [52].

In addition, incidence of B-NHL was lower in patients with SVR [53]. A SVR was associated with NHL regression while a viral relapse was followed by the lymphoma relapse [54,55]. HCV-positive splenic lymphoma with villous lymphocytes (SLVL) regressed after antiviral therapy [56]. Regression of clonal B-cell expansion following successful antiviral therapy has been described with novel expansion of the same clones in patients who relapsed [57,58]. This suggests no-return points in the HCV-driven lymphomagenesis, making the pathogenic mechanism progressively less dependent on the viral antigen [59].

HCV-related lymphoproliferative diseases appear to be the result of multiple events such as a sustained B-cells activation, an aberrant B-cell survival, genetic/epigenetic and environmental factors [59,60]. The role of a prolonged antigenic stimulation has been demonstrated by the lymphotropism of HCV and the presence of HCV antigens in peripheral blood or liver infiltrating lymphocytes and lymph-nodes [61–63]. The linking of HCV surface E2 protein with the tetraspanin CD81 diminished B-cell activation threshold [64]. BCR sequence analyses and affinity in HCV-related NHL showed conflicting results [65,66]. Higher prevalence of HCV infection in PBMCs and bone marrow [67,68] and *in vitro* studies support the lymphotropism of the virus [69,70]. The rate of mutations in oncogenes and immunoglobulin genes is increased in HCV-infected cells [71]. The expression of HCV core and lymphoma was correlated in transgenic models [72,73]. The (14;18) translocation increased Bcl-2 levels and B-cell survival [58,74,75] that disappeared after antivirals [57,76,77]. The role of cytokines and chemokines [15,78–81], including BAFF [20,60,82–84], and the role of microRNAs [21,85] have been studied extensively in HCV-related lymphoproliferative diseases.

Several studies showed a clinical remission following antivirals in low-grade B-cell NHL, mainly in marginal zone lymphoma [55,56,86–89]. The use of IFN-based therapy in patients with indolent HCV-NHL has been associated with an improved overall survival [89]. IFN-based treatment is difficult because of IFN hematological toxicity. However, antivirals after lymphoma remission showed prolonged disease-free survival [90,91]. Rituximab alone or with antivirals and/or chemotherapy showed good results in low-grade B-NHL [42,92]. The recent availability of IFN-free DAAs with a high virological efficacy and no hematological toxicity should easily permit their association with chemotherapy, taking into account possible pharmacological interference.

Arthralgia/myalgia

Arthralgia are found in 30–70% of HCV-infected patients with mixed cryoglobulin [3,93]. Patients present with bilateral, symmetric, non-deforming joint pains involving mainly knees and hands, more rarely elbows and ankles. HCV arthritis, unlinked to mixed cryoglobulin, is uncommon (< 10%). A RF activity is found in 70–80% of CryoVas patients due to the presence of a mixed cryoglobulin; it is not associated with the presence or the activity of joint manifestations. Radiographic joint destruction is not found. Search for antibodies to cyclic citrullinated peptide is negative. IFN-based combinations for HCV may exacerbate arthralgia and myalgia, thus confounding clinical presentation. Clinicians should use main characteristics to differentiate rheumatologic manifestations such as arthralgia, myalgia, and arthritis that may occur in HCV infected patients due to HCV infection itself or to a newly developed rheumatologic disease.

Sicca syndrome

An ocular and/or buccal sicca syndrome is described in 20–30% of HCV infected patients, whereas a definite Sjögren's syndrome (xerostomia, xerophthalmia, anti-SSA/anti-SSB antibodies and typical salivary gland histology) is reported in less than 5% of HCV-positive patients [3]. The presentation may be confusing between HCV-related sicca syndrome and "true" Sjögren's syndrome [94]. HCV-positive patients with a Sjögren's syndrome are older and more likely to have a photosensitivity and a mixed cryoglobulinemia compared to those with a primary Sjögren's syndrome. Presence of low titers of antinuclear antibodies and a RF are common in HCV patients with sicca syndrome, and the presence of Sjögren's syndrome autoantibodies (i.e. anti-SSA/SSB antibody) is rare. The sialadenitis found in HCV infected patients may be related to the allotropism of the virus [95]. In transgenic mice, the development of sialadenitis has been associated with the expression of E1- and E2-HCV glycoproteins [96].

Auto-antibodies

HCV infected patients are frequently positive for autoantibodies (up to 53%), i.e. mixed cryoglobulins (60–80%), RF activity (70%), and antinuclear (20–40%), anticardiolipin (aCL) (20–15%), anti-thyroid (12%) and anti-smooth muscle antibodies (7%) [2,3]. Such autoantibodies have not been associated with connective tissue disease manifestations, except for mixed cryoglobulins and CryoVas. For example, while aCL occurs frequently in viral infections, particularly in HIV (49.75%), HBV (24%) and HCV (20–15%), they are very rarely associated with anti-beta2 glycoprotein I antibodies and are not correlated with a thrombotic risk [97]. In patients with non-autoimmune liver diseases, the production of aCL is a non-specific phenomenon of the liver damage, and it is not associated with thrombotic complications [98]. The HCV-induced activation and proliferation of B cells is the most reported reason for such auto-antibody production, although many other auto-antibodies are not found in HCV infected patients.

Renal insufficiency

The more frequent and severe renal manifestations in HCV infected patients are related to CryoVas (see above). However other mechanisms may be involved leading to renal involvement in such patients. A higher rate of MPGN was found in HCV-positive compared to HCV-negative U.S. hospitalized

male veterans (0.36% *vs.* 0.05%, $P < 0.0001$), but not membranous glomerulopathy (0.33% *vs.* 0.19%, $P = 0.86$) [99]. A higher rate of renal insufficiency has been reported in HCV infected patients compared with subjects without HCV infection, after adjusting for age, gender, race, diabetes, and hypertension [100]. HCV infection may affect renal function in the general population as it has been associated with low GFR, with odds ratio up to 2.80 [101]. In addition, HCV infection appears to increase the risk of proteinuria in healthy individuals, with odds ratio of 1.14–1.99, independently of diabetes mellitus, arterial hypertension, obesity, and dyslipidemia [102–106].

Increased non liver-related mortality/morbidity, i.e. cardiovascular and glucose metabolism disorders

The main cause of mortality in HCV infected patients is the liver disease [107–113]. However, HCV infected patients showed increased mortality rates due to extra-hepatic complications (i.e., cardiovascular, renal, tumoral) [111,112,114–116]. Some chronic infections have been suggested as triggers for cardiovascular diseases [117–119]. Their identification as cardiovascular risk factors may offer new perspectives in cardiovascular disease prevention [120]. HCV seropositivity is associated with high rates of carotid-artery plaques, carotid intima-media thickening, and the risk of stroke independently of other well known atherosclerosis risk factors [117]. The HCV is able to induce the production of pro-atherogenic cytokines [121] that may promote the atherosclerotic plaque instability, supporting a role of the virus in the cerebrovascular diseases risk [122]. In addition, cohort studies suggested a positive impact of antivirals on the incidence of stroke [123].

HCV infection has been shown to increase the risk of coronary artery disease, after adjustment for cardiovascular risk factors [124]. Patients with SVR after antivirals showed an improvement in their myocardial perfusion defect whereas relapsers showed a worsening after a transient improvement [125]. The risk of major cardiovascular events (i.e. cerebrovascular accident and ischemic heart disease) is higher in patients with HCV infection compared to controls, independent of the severity of the liver disease or the common cardiovascular risk factors [126]. The beneficial impact of IFN-based therapy needs to be confirmed with new IFN-free DAAs in prospective studies with extended follow-up.

Insulin-resistance, commonly associated with obesity and metabolic syndrome, can evolve to diabetes mellitus [127]. The presence of insulin-resistance has been analyzed in SVRs after pegylated IFN plus ribavirin. On one hand, the therapeutic response was not altered by insulin-resistance. On the other hand, therapeutic failure and elevated body mass index were independent risk factors for *de novo* appearance of insulin-resistance after treatment. No new case of insulin-resistance was registered in SVR patients, suggesting a possible prevention of insulin-resistance onset and its evolution to diabetes [128]. Insulin resistance has been found to alter SVR rate to pegIFN plus ribavirin in HIV-HCV coinfected patients [129]. Increased risk of type 2 diabetes in HCV infected patients may arise from interactions between insulin resistance, steatosis and inflammatory mechanisms [130]. Many epidemiologic studies support the link between type 2 diabetes and HCV infection [131,132,133]. Type 2 diabetes was more frequent in HCV- than HBV-related cirrhosis (23.6% vs. 9.4%; OR 2.78; 95%CI, 1.6–4.79; $P = 0.0002$) [134,135]. In HCV infected patients type 2 diabetes was more frequent in male cirrhotics.

The prevalence and spectrum of rheumatic disorders and autoimmune phenomena in HCV-infected patients have been reported [8,136]. Many of these extrahepatic manifestations are autoimmune disorders, with added mortality and morbidity due to involvement of multiple organ systems [137]. Until recently, the standard of care of HCV has been the use of interferon-based regimens, which not only have limited effectiveness in curing the underlying viral illness but are poorly tolerated and in patients with rheumatic diseases especially problematic given their association with a wide variety of autoimmune toxicities [138]. CryoVasc can be treated at different levels by means of etiological treatment with antivirals aimed at HCV eradication and/or pathogenetic/symptomatic treatments directed to both immune-system alterations and the vasculitic process (rituximab, cyclophosphamide, steroids, plasmapheresis) [133]. In clinical practice, the therapeutic strategy should be modulated according to severity/activity of the CryoVasc and possibly tailored to each individual patient's conditions. In our review, we investigated clinical and therapeutic facets of HCV-related extrahepatic manifestations.

Conclusions

In summary, beyond the liver manifestations, HCV chronic infection frequently leads to a true systemic disease where many manifestations appear to be in the field of rheumatology. Therefore, rheumatologists should be aware of these numerous manifestations and they should increase the screening of HCV infection in their patients.

Conflict of interest

The authors have declared no conflict of interest.

Compliance with Ethics Requirements

This article does not contain any studies with human or animal subjects.

References

[1] Negro F. Epidemiology of hepatitis C in Europe. Dig Liver Dis Off J Ital Soc Gastroenterol Ital Assoc Study Liver 2014;46 (suppl 5):S158–64.
[2] Cacoub P, Poynard T, Ghillani P, Charlotte F, Olivi M, Piette JC, et al. Extrahepatic manifestations of chronic hepatitis C. MULTIVIRC Group. Multidepartment Virus C. Arthritis Rheum 1999;42(10):2204–12.
[3] Cacoub P, Renou C, Rosenthal E, Cohen P, Loury I, Loustaud-Ratti V, et al. Extrahepatic manifestations associated with hepatitis C virus infection. A prospective multicenter study of 321 patients. The GERMIVIC. Groupe d'Etude et de Recherche en Medecine Interne et Maladies Infectieuses sur le Virus de l'Hepatite C. Medicine (Baltimore) 2000;79(1):47–56.
[4] Zignego AL, Bréchot C. Extrahepatic manifestations of HCV infection: facts and controversies. J Hepatol 1999;31(2):369–76.

[5] Zignego AL, Ferri C, Pileri SA, Caini P, Bianchi FB. Italian association of the study of liver commission on extrahepatic manifestations of HCV infection. Extrahepatic manifestations of Hepatitis C Virus infection: a general overview and guidelines for a clinical approach. Dig Liver Dis Off J Ital Soc Gastroenterol Ital Assoc Study Liver 2007;39 (1):2–17.
[6] Zignego AL, Giannini C, Monti M, Gragnani L. Hepatitis C virus lymphotropism: lessons from a decade of studies. Dig Liver Dis Off J Ital Soc Gastroenterol Ital Assoc Study Liver 2007;39(suppl 1):S38–45.
[7] Cacoub P, Comarmond C, Domont F, Savey L, Saadoun D. Cryoglobulinemia vasculitis. Am J Med 2015;128(9):950–5.
[8] Cacoub P, Gragnani L, Comarmond C, Zignego AL. Extrahepatic manifestations of chronic hepatitis C virus infection. Dig Liver Dis Off J Ital Soc Gastroenterol Ital Assoc Study Liver 2014;46(suppl 5):S165–73, 15 déc.
[9] Cacoub P, Comarmond C, Domont F, Savey L, Desbois AC, Saadoun D. Extrahepatic manifestations of chronic hepatitis C virus infection. Ther Adv Infect Dis 2016;3(1):3–14.
[10] Sene D, Ghillani-Dalbin P, Thibault V, Guis L, Musset L, Duhaut P, et al. Longterm course of mixed cryoglobulinemia in patients infected with hepatitis C virus. J Rheumatol 2004;31 (11):2199–206.
[11] Terrier B, Semoun O, Saadoun D, Sène D, Resche-Rigon M, Cacoub P. Prognostic factors in patients with hepatitis C virus infection and systemic vasculitis. Arthritis Rheum 2011;63 (6):1748–57.
[12] Ferri C, Sebastiani M, Giuggioli D, Cazzato M, Longombardo G, Antonelli A, et al. Mixed cryoglobulinemia: demographic, clinical, and serologic features and survival in 231 patients. Semin Arthritis Rheum 2004;33(6):355–74.
[13] Retamozo S, Díaz-Lagares C, Bosch X, Bové A, Brito-Zerón P, Gómez M-E, et al. Life-threatening cryoglobulinemic patients with hepatitis C: clinical description and outcome of 279 patients. Medicine (Baltimore) 2013;92(5):273–84.
[14] Terrier B, Karras A, Cluzel P, Collet J-P, Sène D, Saadoun D, et al. Presentation and prognosis of cardiac involvement in hepatitis C virus-related vasculitis. Am J Cardiol 2013;111 (2):265–72.
[15] Saadoun D, Bieche I, Maisonobe T, Asselah T, Laurendeau I, Piette JC, et al. Involvement of chemokines and type 1 cytokines in the pathogenesis of hepatitis C virus-associated mixed cryoglobulinemia vasculitis neuropathy. Arthritis Rheum 2005;52(9):2917–25.
[16] Boyer O, Saadoun D, Abriol J, Dodille M, Piette J-C, Cacoub P, et al. CD4 + CD25 + regulatory T-cell deficiency in patients with hepatitis C-mixed cryoglobulinemia vasculitis. Blood 2004;103(9):3428–30.
[17] Saadoun D, Rosenzwajg M, Joly F, Six A, Carrat F, Thibault V, et al. Regulatory T-cell responses to low-dose interleukin-2 in HCV-induced vasculitis. New Engl J Med 2011;365 (22):2067–77.
[18] Cacoub P, Renou C, Kerr G, Hüe S, Rosenthal E, Cohen P, et al. Influence of HLA-DR phenotype on the risk of hepatitis C virus-associated mixed cryoglobulinemia. Arthritis Rheum 2001;44(9):2118–24.
[19] Zignego AL, Wojcik GL, Cacoub P, Visentini M, Casato M, Mangia A, et al. Genome-wide association study of hepatitis C virus- and cryoglobulin-related vasculitis. Genes Immun 2014;15(7):500–5.
[20] Gragnani L, Piluso A, Giannini C, Caini P, Fognani E, Monti M, et al. Genetic determinants in hepatitis C virus-associated mixed cryoglobulinemia: role of polymorphic variants of BAFF promoter and Fcγ receptors. Arthritis Rheum 2011;63 (5):1446–51.
[21] Fognani E, Giannini C, Piluso A, Gragnani L, Monti M, Caini P, et al. Role of microRNA profile modifications in hepatitis C virus-related mixed cryoglobulinemia. PLoS ONE 2013;8(5): e62965.
[22] Ferri C, Marzo E, Longombardo G, Lombardini F, La Civita L, Vanacore R, et al. Interferon-alpha in mixed cryoglobulinemia patients: a randomized, crossover-controlled trial. Blood 1993;81(5):1132–6.
[23] Misiani R, Bellavita P, Fenili D, Vicari O, Marchesi D, Sironi PL, et al. Interferon alfa-2a therapy in cryoglobulinemia associated with hepatitis C virus. New Engl J Med 1994;330 (11):751–6.
[24] Saadoun D, Resche-Rigon M, Thibault V, Piette J-C, Cacoub P. Antiviral therapy for hepatitis C virus–associated mixed cryoglobulinemia vasculitis: a long-term followup study. Arthritis Rheum 2006;54(11):3696–706.
[25] Landau D-A, Saadoun D, Halfon P, Martinot-Peignoux M, Marcellin P, Fois E, et al. Relapse of hepatitis C virus-associated mixed cryoglobulinemia vasculitis in patients with sustained viral response. Arthritis Rheum 2008;58(2): 604–11.
[26] Saadoun D, Resche Rigon M, Pol S, Thibault V, Blanc F, Pialoux G, et al. Peg-IFNαRibavirin/Protease inhibitor combination in severe hepatitis C virus associated mixed cryoglobulinemia vasculitis. J Hepatol 2015;62(1):24–30.
[27] Gragnani L, Fabbrizzi A, Triboli E, Urraro T, Boldrini B, Fognani E, et al. Triple antiviral therapy in hepatitis C virus infection with or without mixed cryoglobulinaemia: a prospective, controlled pilot study. Dig Liver Dis Off J Ital Soc Gastroenterol Ital Assoc Study Liver 2014;46(9):833–7.
[28] European Association for Study of Liver. EASL recommendations on treatment of hepatitis C 2015. J Hepatol 2015;63(1):199–236.
[29] Saadoun D, Thibault V, Si Ahmed SN, Alric L, Mallet M, Guillaud C, et al. Sofosbuvir plus ribavirin for hepatitis C virus-associated cryoglobulinaemia vasculitis: VASCUVALDIC study. Ann Rheum Dis 2016;75(10):1777–82.
[30] Flemming JA, Lowe CE. Successful treatment of hepatitis C, genotype 3, with sofosbuvir/ledipasvir in decompensated cirrhosis complicated by mixed cryoglobulinaemia. BMJ Case Rep 2016. http://dx.doi.org/10.1136/bcr-2016-215293, pii: bcr2016215293.
[31] Gragnani L, Piluso A, Urraro T, Fabbrizzi A, Fognani E, Petraccia L, et al. Virological and clinical response to interferon-free regimens in patients with HCV-related mixed cryoglobulinemia: preliminary results of a prospective pilot study. Curr Drug Targets 2016;17. http://dx.doi.org/10.2174/1389450117666160208145432.
[32] Sise ME, Bloom AK, Wisocky J, Lin MV, Gustafson JL, Lundquist AL, et al. Treatment of hepatitis C virus-associated mixed cryoglobulinemia with direct-acting antiviral agents. Hepatol Baltim Md 2016;63(2):408–17.
[33] Roccatello D, Baldovino S, Rossi D, Mansouri M, Naretto C, Gennaro M, et al. Long-term effects of anti-CD20 monoclonal antibody treatment of cryoglobulinaemic glomerulonephritis. Nephrol Dial Transplant Off Publ Eur Dial Transpl Assoc - Eur Ren Assoc 2004;19(12):3054–61.
[34] Saadoun D, Resche-Rigon M, Sene D, Perard L, Karras A, Cacoub P. Rituximab combined with Peg-interferon-ribavirin in refractory hepatitis C virus-associated cryoglobulinaemia vasculitis. Ann Rheum Dis 2008;67(10):1431–6.
[35] Sansonno D, De Re V, Lauletta G, Tucci FA, Boiocchi M, Dammacco F. Monoclonal antibody treatment of mixed cryoglobulinemia resistant to interferon alpha with an anti-CD20. Blood 2003;101(10):3818–26.
[36] Zaja F, De Vita S, Mazzaro C, Sacco S, Damiani D, De Marchi G, et al. Efficacy and safety of rituximab in type II mixed cryoglobulinemia. Blood 2003;101(10):3827–34.
[37] Cacoub P, Delluc A, Saadoun D, Landau DA, Sene D. Anti-CD20 monoclonal antibody (rituximab) treatment for

cryoglobulinemic vasculitis: where do we stand? Ann Rheum Dis 2008;67(3):283–7.
[38] De Vita S, Quartuccio L, Isola M, Mazzaro C, Scaini P, Lenzi M, et al. A randomized controlled trial of rituximab for the treatment of severe cryoglobulinemic vasculitis. Arthritis Rheum 2012;64(3):843–53.
[39] Sneller MC, Hu Z, Langford CA. A randomized controlled trial of rituximab following failure of antiviral therapy for hepatitis C virus-associated cryoglobulinemic vasculitis. Arthritis Rheum 2012;64(3):835–42.
[40] Droz N, Gilardin L, Cacoub P, Berenbaum F, Wendling D, Godeau B, et al. Kinetic profiles and management of hepatitis B virus reactivation in patients with immune-mediated inflammatory diseases. Arthritis Care Res 2013;65(9):1504–14.
[41] Dammacco F, Tucci FA, Lauletta G, Gatti P, De Re V, Conteduca V, et al. Pegylated interferon-alpha, ribavirin, and rituximab combined therapy of hepatitis C virus-related mixed cryoglobulinemia: a long-term study. Blood 2010;116 (3):343–53.
[42] Saadoun D, Resche Rigon M, Sene D, Terrier B, Karras A, Perard L, et al. Rituximab plus Peg-interferon-alpha/ribavirin compared with Peg-interferon-alpha/ribavirin in hepatitis C-related mixed cryoglobulinemia. Blood 2010;116(3), 326-334-505.
[43] Saadoun D, Delluc A, Piette JC, Cacoub P. Treatment of hepatitis C-associated mixed cryoglobulinemia vasculitis. Curr Opin Rheumatol 2008;20(1):23–8.
[44] Saadoun D, Pineton de Chambrun M, Hermine O, Karras A, Choquet S, Jego P, et al. Using rituximab plus fludarabine and cyclophosphamide as a treatment for refractory mixed cryoglobulinemia associated with lymphoma. Arthritis Care Res 2013;65(4):643–7.
[45] Ferri C, La Civita L, Caracciolo F, Zignego AL. Non-Hodgkin's lymphoma: possible role of hepatitis C virus. JAMA J Am Med Assoc 1994;272(5):355–6.
[46] Ferri C, Caracciolo F, La Civita L, Monti M, Longombardo G, Greco F, et al. Hepatitis C virus infection and B-cell lymphomas. Eur J Cancer Oxf Engl 1990 1994;30A(10):1591–2.
[47] Gisbert JP, García-Buey L, Pajares JM, Moreno-Otero R. Prevalence of hepatitis C virus infection in B-cell non-Hodgkin's lymphoma: systematic review and meta-analysis. Gastroenterology 2003;125(6):1723–32.
[48] Dal Maso L, Franceschi S. Hepatitis C virus and risk of lymphoma and other lymphoid neoplasms: a meta-analysis of epidemiologic studies. Cancer Epidemiol Biomark Prev Publ Am Assoc Cancer Res Cosponsored Am Soc Prev Oncol 2006;15(11):2078–85.
[49] Matsuo K, Kusano A, Sugumar A, Nakamura S, Tajima K, Mueller NE. Effect of hepatitis C virus infection on the risk of non-Hodgkin's lymphoma: a meta-analysis of epidemiological studies. Cancer Sci 2004;95(9):745–52.
[50] Negri E, Little D, Boiocchi M, La Vecchia C, Franceschi S. B-cell non-Hodgkin's lymphoma and hepatitis C virus infection: a systematic review. Int J Cancer J Int Cancer 2004;111(1):1–8.
[51] de Sanjose S, Benavente Y, Vajdic CM, Engels EA, Morton LM, Bracci PM, et al. Hepatitis C and non-Hodgkin lymphoma among 4784 cases and 6269 controls from the International Lymphoma Epidemiology Consortium. Clin Gastroenterol Hepatol Off Clin Pract J Am Gastroenterol Assoc 2008;6(4):451–8.
[52] Andreone P, Zignego AL, Cursaro C, Gramenzi A, Gherlinzoni F, Fiorino S, et al. Prevalence of monoclonal gammopathies in patients with hepatitis C virus infection. Ann Intern Med 1998;129(4):294–8.
[53] Kawamura Y, Ikeda K, Arase Y, Yatsuji H, Sezaki H, Hosaka T, et al. Viral elimination reduces incidence of malignant lymphoma in patients with hepatitis C. Am J Med 2007;120 (12):1034–41.
[54] Casato M, Mecucci C, Agnello V, Fiorilli M, Knight GB, Matteucci C, et al. Regression of lymphoproliferative disorder after treatment for hepatitis C virus infection in a patient with partial trisomy 3, Bcl-2 overexpression, and type II cryoglobulinemia. Blood 2002;99(6):2259–61.
[55] Saadoun D, Suarez F, Lefrere F, Valensi F, Mariette X, Aouba A, et al. Splenic lymphoma with villous lymphocytes, associated with type II cryoglobulinemia and HCV infection: a new entity? Blood 2005;105(1):74–6.
[56] Hermine O, Lefrère F, Bronowicki J-P, Mariette X, Jondeau K, Eclache-Saudreau V, et al. Regression of splenic lymphoma with villous lymphocytes after treatment of hepatitis C virus infection. New Engl J Med 2002;347(2):89–94.
[57] Giannelli F, Moscarella S, Giannini C, Caini P, Monti M, Gragnani L, et al. Effect of antiviral treatment in patients with chronic HCV infection and t(14;18) translocation. Blood 2003;102(4):1196–201.
[58] Zignego AL, Ferri C, Giannelli F, Giannini C, Caini P, Monti M, et al. Prevalence of bcl-2 rearrangement in patients with hepatitis C virus-related mixed cryoglobulinemia with or without B-cell lymphomas. Ann Intern Med 2002;137 (7):571–80.
[59] Zignego AL, Giannini C, Gragnani L. HCV and lymphoproliferation. Clin Dev Immunol 2012;2012:980942.
[60] Landau D-A, Rosenzwajg M, Saadoun D, Klatzmann D, Cacoub P. The B lymphocyte stimulator receptor-ligand system in hepatitis C virus-induced B cell clonal disorders. Ann Rheum Dis 2009;68(3):337–44.
[61] Lai R, Weiss LM. Hepatitis C virus and non-Hodgkin's lymphoma. Am J Clin Pathol 1998;109(5):508–10.
[62] Sansonno D, De Vita S, Iacobelli AR, Cornacchiulo V, Boiocchi M, Dammacco F. Clonal analysis of intrahepatic B cells from HCV-infected patients with and without mixed cryoglobulinemia. J Immunol Baltim Md 1950 1998;160 (7):3594–601.
[63] Vallat L, Benhamou Y, Gutierrez M, Ghillani P, Hercher C, Thibault V, et al. Clonal B cell populations in the blood and liver of patients with chronic hepatitis C virus infection. Arthritis Rheum 2004;50(11):3668–78.
[64] Pileri P, Uematsu Y, Campagnoli S, Galli G, Falugi F, Petracca R, et al. Binding of hepatitis C virus to CD81. Science 1998;282(5390):938–41.
[65] Ng PP, Kuo C-C, Wang S, Einav S, Arcaini L, Paulli M, et al. B-cell receptors expressed by lymphomas of hepatitis C virus (HCV)-infected patients rarely react with the viral proteins. Blood 2014;123(10):1512–5.
[66] De Re V, De Vita S, Marzotto A, Rupolo M, Gloghini A, Pivetta B, et al. Sequence analysis of the immunoglobulin antigen receptor of hepatitis C virus-associated non-Hodgkin lymphomas suggests that the malignant cells are derived from the rheumatoid factor-producing cells that occur mainly in type II cryoglobulinemia. Blood 2000;96 (10):3578–84.
[67] Galli M, Zehender G, Monti G, Ballaré M, Saccardo F, Piconi S, et al. Hepatitis C virus RNA in the bone marrow of patients with mixed cryoglobulinemia and in subjects with noncryoglobulinemic chronic hepatitis type C. J Infect Dis 1995;171(3):672–5.
[68] Zignego AL, Macchia D, Monti M, Thiers V, Mazzetti M, Foschi M, et al. Infection of peripheral mononuclear blood cells by hepatitis C virus. J Hepatol 1992;15(3):382–6.
[69] Bronowicki JP, Loriot MA, Thiers V, Grignon Y, Zignego AL, Bréchot C. Hepatitis C virus persistence in human hematopoietic cells injected into SCID mice. Hepatol Baltim Md 1998;28(1):211–8.
[70] Sung VM-H, Shimodaira S, Doughty AL, Picchio GR, Can H, Yen TSB, et al. Establishment of B-cell lymphoma cell lines persistently infected with hepatitis C virus in vivo and in vitro:

the apoptotic effects of virus infection. J Virol 2003;77 (3):2134–46.
[71] Machida K, Cheng KT-N, Sung VM-H, Shimodaira S, Lindsay KL, Levine AM, et al. Hepatitis C virus induces a mutator phenotype: enhanced mutations of immunoglobulin and protooncogenes. Proc Natl Acad Sci USA 2004;101 (12):4262–7.
[72] Kasama Y, Sekiguchi S, Saito M, Tanaka K, Satoh M, Kuwahara K, et al. Persistent expression of the full genome of hepatitis C virus in B cells induces spontaneous development of B-cell lymphomas in vivo. Blood 2010;116(23):4926–33.
[73] Tsukiyama-Kohara K, Sekiguchi S, Kasama Y, Salem NE, Machida K, Kohara M. Hepatitis C virus-related lymphomagenesis in a mouse model. ISRN Hematol 2011:167501.
[74] Zignego AL, Giannelli F, Marrocchi ME, Giannini C, Gentilini P, Innocenti F, et al. Frequency of bcl-2 rearrangement in patients with mixed cryoglobulinemia and HCV-positive liver diseases. Clin Exp Rheumatol 1997;15 (6):711–2.
[75] Zignego AL, Giannelli F, Marrocchi ME, Mazzocca A, Ferri C, Giannini C, et al. T(14;18) translocation in chronic hepatitis C virus infection. Hepatol Baltim Md 2000;31(2):474–9.
[76] Giannini C, Giannelli F, Zignego AL. Association between mixed cryoglobulinemia, translocation (14;18), and persistence of occult HCV lymphoid infection after treatment. Hepatol Baltim Md 2006;43(5), 1166-1167-1168.
[77] Giannini C, Petrarca A, Monti M, Arena U, Caini P, Solazzo V, et al. Association between persistent lymphatic infection by hepatitis C virus after antiviral treatment and mixed cryoglobulinemia. Blood 2008;111(5):2943–5.
[78] Libra M, Indelicato M, De Re V, Zignego AL, Chiocchetti A, Malaponte G, et al. Elevated serum levels of osteopontin in HCV-associated lymphoproliferative disorders. Cancer Biol Ther 2005;4(11):1192–4.
[79] Libra M, Mangano K, Anzaldi M, Quattrocchi C, Donia M, di Marco R, et al. Analysis of interleukin (IL)-1beta IL-1 receptor antagonist, soluble IL-1 receptor type II and IL-1 accessory protein in HCV-associated lymphoproliferative disorders. Oncol Rep 2006;15(5):1305–8.
[80] Saadoun D, Bieche I, Authier F-J, Laurendeau I, Jambou F, Piette JC, et al. Role of matrix metalloproteinases, proinflammatory cytokines, and oxidative stress-derived molecules in hepatitis C virus-associated mixed cryoglobulinemia vasculitis neuropathy. Arthritis Rheum 2007;56(4):1315–24.
[81] Sansonno D, Tucci FA, Ghebrehiwet B, Lauletta G, Peerschke EIB, Conteduca V, et al. Role of the receptor for the globular domain of C1q protein in the pathogenesis of hepatitis C virus-related cryoglobulin vascular damage. J Immunol Baltim Md 1950 2009;183(9):6013–20.
[82] Sène D, Limal N, Ghillani-Dalbin P, Saadoun D, Piette J-C, Cacoub P. Hepatitis C virus-associated B-cell proliferation–the role of serum B lymphocyte stimulator (BLyS/BAFF). Rheumatol Oxf Engl 2007;46(1):65–9.
[83] De Vita S, Quartuccio L, Fabris M. Hepatitis C virus infection, mixed cryoglobulinemia and BLyS upregulation: targeting the infectious trigger, the autoimmune response, or both? Autoimmun Rev 2008;8(2):95–9.
[84] Giannini C, Gragnani L, Piluso A, Caini P, Petrarca A, Monti M, et al. Can BAFF promoter polymorphism be a predisposing condition for HCV-related mixed cryoglobulinemia? Blood 2008;112(10):4353–4.
[85] Peveling-Oberhag J, Crisman G, Schmidt A, Döring C, Lucioni M, Arcaini L, et al. Dysregulation of global microRNA expression in splenic marginal zone lymphoma and influence of chronic hepatitis C virus infection. Leukemia 2012;26 (7):1654–62.
[86] Kelaidi C, Rollot F, Park S, Tulliez M, Christoforov B, Calmus Y, et al. Response to antiviral treatment in hepatitis C virus-associated marginal zone lymphomas. Leukemia 2004;18 (10):1711–6.
[87] Vallisa D, Bernuzzi P, Arcaini L, Sacchi S, Callea V, Marasca R, et al. Role of anti-hepatitis C virus (HCV) treatment in HCV-related, low-grade, B-cell, non-Hodgkin's lymphoma: a multicenter Italian experience. J Clin Oncol Off J Am Soc Clin Oncol 2005;23(3):468–73.
[88] Mazzaro C, De Re V, Spina M, Dal Maso L, Festini G, Comar C, et al. Pegylated-interferon plus ribavirin for HCV-positive indolent non-Hodgkin lymphomas. Br J Haematol 2009;145 (2):255–7.
[89] Arcaini L, Vallisa D, Rattotti S, Ferretti VV, Ferreri AJM, Bernuzzi P, et al. Antiviral treatment in patients with indolent B-cell lymphomas associated with HCV infection: a study of the Fondazione Italiana Linfomi. Ann Oncol Off J Eur Soc Med Oncol ESMO 2014;25(7):1404–10.
[90] Musto P, Dell'Olio M, Carotenuto M, Mangia A, Andriulli A. Hepatitis C virus infection: a new bridge between hematologists and gastroenterologists? Blood 1996;88(2):752–4.
[91] La Mura V, De Renzo A, Perna F, D'Agostino D, Masarone M, Romano M, et al. Antiviral therapy after complete response to chemotherapy could be efficacious in HCV-positive non-Hodgkin's lymphoma. J Hepatol 2008;49 (4):557–63.
[92] Hainsworth JD, Litchy S, Burris HA, Scullin DC, Corso SW, Yardley DA, et al. Rituximab as first-line and maintenance therapy for patients with indolent non-hodgkin's lymphoma. J Clin Oncol Off J Am Soc Clin Oncol 2002;20(20):4261–7.
[93] Lee YH, Ji JD, Yeon JE, Byun KS, Lee CH, Song GG. Cryoglobulinaemia and rheumatic manifestations in patients with hepatitis C virus infection. Ann Rheum Dis 1998;57 (12):728–31.
[94] Ramos-Casals M, García-Carrasco M, Cervera R, Rosas J, Trejo O, de la Red G, et al. Hepatitis C virus infection mimicking primary Sjögren syndrome. A clinical and immunologic description of 35 cases. Medicine (Baltimore) 2001;80(1):1–8.
[95] Verbaan H, Carlson J, Eriksson S, Larsson A, Liedholm R, Manthorpe R, et al. Extrahepatic manifestations of chronic hepatitis C infection and the interrelationship between primary Sjögren's syndrome and hepatitis C in Swedish patients. J Intern Med 1999;245(2):127–32.
[96] Koike K, Moriya K, Ishibashi K, Yotsuyanagi H, Shintani Y, Fujie H, et al. Sialadenitis histologically resembling Sjogren syndrome in mice transgenic for hepatitis C virus envelope genes. Proc Natl Acad Sci USA 1997;94(1):233–6.
[97] Sène D, Piette J-C, Cacoub P. Antiphospholipid antibodies, antiphospholipid syndrome and infections. Autoimmun Rev 2008;7(4):272–7.
[98] Mangia A, Margaglione M, Cascavilla I, Gentile R, Cappucci G, Facciorusso D, et al. Anticardiolipin antibodies in patients with liver disease. Am J Gastroenterol 1999;94(10):2983–7.
[99] El-Serag HB, Hampel H, Yeh C, Rabeneck L. Extrahepatic manifestations of hepatitis C among United States male veterans. Hepatol Baltim Md 2002;36(6):1439–45.
[100] Dalrymple LS, Koepsell T, Sampson J, Louie T, Dominitz JA, Young B, et al. Hepatitis C virus infection and the prevalence of renal insufficiency. Clin J Am Soc Nephrol CJASN 2007;2 (4):715–21.
[101] Fabrizi F, Plaisier E, Saadoun D, Martin P, Messa P, Cacoub P. Hepatitis C virus infection, mixed cryoglobulinemia, and kidney disease. Am J Kidney Dis Off J Natl Kidney Found 2013;61(4):623–37.
[102] Butt AA, Wang X, Fried LF. HCV infection and the incidence of CKD. Am J Kidney Dis Off J Natl Kidney Found 2011;57 (3):396–402.

[103] Huang J-F, Chuang W-L, Dai C-Y, Ho C-K, Hwang S-J, Chen S-C, et al. Viral hepatitis and proteinuria in an area endemic for hepatitis B and C infections: another chain of link? J Intern Med 2006;260(3):255–62.
[104] Lee J-J, Lin M-Y, Yang Y-H, Lu S-N, Chen H-C, Hwang S-J. Association of hepatitis C and B virus infection with CKD in an endemic area in Taiwan: a cross-sectional study. Am J Kidney Dis Off J Natl Kidney Found 2010;56(1):23–31.
[105] Liangpunsakul S, Chalasani N. Relationship between hepatitis C and microalbuminuria: results from the NHANES III. Kidney Int 2005;67(1):285–90.
[106] Wyatt CM, Malvestutto C, Coca SG, Klotman PE, Parikh CR. The impact of hepatitis C virus coinfection on HIV-related kidney disease: a systematic review and meta-analysis. AIDS Lond Engl 2008;22(14):1799–807.
[107] Backus LI, Boothroyd DB, Phillips BR, Belperio P, Halloran J, Mole LA. A sustained virologic response reduces risk of all-cause mortality in patients with hepatitis C. Clin Gastroenterol Hepatol Off Clin Pract J Am Gastroenterol Assoc 2011;9(6):509–16.
[108] El-Kamary SS, Jhaveri R, Shardell MD. All-cause, liver-related, and non-liver-related mortality among HCV-infected individuals in the general US population. Clin Infect Dis Off Publ Infect Dis Soc Am 2011;53(2):150–7.
[109] Harris HE, Ramsay ME, Andrews NJ, HCV National Register Steering Group. Survival of a national cohort of hepatitis C virus infected patients, 16 years after exposure. Epidemiol Infect 2006;134(3):472–7.
[110] Hsu Y-C, Lin J-T, Ho HJ, Kao Y-H, Huang Y-T, Hsiao N-W, et al. Antiviral treatment for hepatitis C virus infection is associated with improved renal and cardiovascular outcomes in diabetic patients. Hepatol Baltim Md 2014;59(4):1293–302.
[111] Lee M-H, Yang H-I, Lu S-N, Jen C-L, You S-L, Wang L-Y, et al. Chronic hepatitis C virus infection increases mortality from hepatic and extrahepatic diseases: a community-based long-term prospective study. J Infect Dis 2012;206(4):469–77.
[112] Uto H, Stuver SO, Hayashi K, Kumagai K, Sasaki F, Kanmura S, et al. Increased rate of death related to presence of viremia among hepatitis C virus antibody-positive subjects in a community-based cohort study. Hepatol Baltim Md 2009;50(2):393–9.
[113] Younossi ZM, Stepanova M, Mishra A, Venkatesan C, Henry L, Hunt S. The impact of chronic hepatitis C on resource utilisation and in-patient mortality for Medicare beneficiaries between 2005 and 2010. Aliment Pharmacol Ther 2013;38(9):1065–75.
[114] Maasoumy B, Wedemeyer H. Natural history of acute and chronic hepatitis C. Best Pract Res Clin Gastroenterol. 2012;26(4):401–12.
[115] Omland LH, Jepsen P, Krarup H, Schønning K, Lind B, Kromann-Andersen H, et al. Increased mortality among persons infected with hepatitis C virus. Clin Gastroenterol Hepatol Off Clin Pract J Am Gastroenterol Assoc 2011;9(1):71–8.
[116] Negro F, Forton D, Craxì A, Sulkowski MS, Feld JJ, Manns MP. Extrahepatic morbidity and mortality of chronic hepatitis C. Gastroenterology 2015;149(6):1345–60.
[117] Ishizaka N, Ishizaka Y, Takahashi E, Toda Ei E, Hashimoto H, Ohno M, et al. Increased prevalence of carotid atherosclerosis in hepatitis B virus carriers. Circulation 2002;105(9):1028–30.
[118] Lindsberg PJ, Grau AJ. Inflammation and infections as risk factors for ischemic stroke. Stroke J Cereb Circ 2003;34(10):2518–32.
[119] Palm F, Urbanek C, Grau A. Infection, its treatment and the risk for stroke. Curr Vasc Pharmacol 2009;7(2):146–52.
[120] Negro F. Facts and fictions of HCV and comorbidities: steatosis, diabetes mellitus, and cardiovascular diseases. J Hepatol 2014;61(1 Suppl):S69–78.
[121] Adinolfi LE, Zampino R, Restivo L, Lonardo A, Guerrera B, Marrone A, et al. Chronic hepatitis C virus infection and atherosclerosis: clinical impact and mechanisms. World J Gastroenterol WJG 2014;20(13):3410–7.
[122] He Huang null, Kang R, Zhao Z. Hepatitis C virus infection and risk of stroke: a systematic review and meta-analysis. PLoS ONE 2013;8(11):e81305.
[123] Hsu C-S, Kao J-H, Chao Y-C, Lin HH, Fan Y-C, Huang C-J, et al. Interferon-based therapy reduces risk of stroke in chronic hepatitis C patients: a population-based cohort study in Taiwan. Aliment Pharmacol Ther 2013;38(4):415–23.
[124] Butt AA, Xiaoqiang W, Budoff M, Leaf D, Kuller LH, Justice AC. Hepatitis C virus infection and the risk of coronary disease. Clin Infect Dis Off Publ Infect Dis Soc Am 2009;49(2):225–32.
[125] Maruyama S, Koda M, Oyake N, Sato H, Fujii Y, Horie Y, et al. Myocardial injury in patients with chronic hepatitis C infection. J Hepatol 2013;58(1):11–5.
[126] Domont F, Cacoub P. Chronic hepatitis C virus infection, a new cardiovascular risk factor? Liver Int Off J Int Assoc Study Liver 2016;36(5):621–7.
[127] Taskoparan M, Serin E, Gokturk HS, Icer MO, Abaci K, Ozer B, et al. Early effect of peginterferon alpha-2b plus ribavirin treatment on blood pressure and insulin resistance in patients with chronic hepatitis C. Hepatogastroenterology 2011;58(107–108):875–9.
[128] Aghemo A, Prati GM, Rumi MG, Soffredini R, D'Ambrosio R, Orsi E, et al. Sustained virological response prevents the development of insulin resistance in patients with chronic hepatitis C. Hepatol Baltim Md 2012;56(5):1681–7.
[129] Cacoub P, Carrat F, Bédossa P, Lambert J, Pénaranda G, Pol S, et al. Insulin resistance impairs sustained virological response rate to pegylated interferon plus ribavirin in HIV-hepatitis C virus-coinfected patients: HOMAVIC-ANRS HC02 Study. Antivir Ther 2009;14(6):839–45.
[130] Serfaty L, Capeau J. Hepatitis C, insulin resistance and diabetes: clinical and pathogenic data. Liver Int Off J Int Assoc Study Liver 2009;29(Suppl 2):13–25.
[131] Ozyilkan E, Arslan M. Increased prevalence of diabetes mellitus in patients with chronic hepatitis C virus infection. Am J Gastroenterol 1996;91(7):1480–1.
[132] Ozyilkan E, Erbaş T, Simşek H, Telatar F, Kayhan B, Telatar H. Increased prevalence of hepatitis C virus antibodies in patients with diabetes mellitus. J Intern Med 1994;235(3):283–4.
[133] Ferri C, Sebastiani M, Antonelli A, Colaci M, Manfredi A, Giuggioli D. Current treatment of hepatitis C-associated rheumatic diseases. Arthritis Res Ther 2012;14(3):215.
[134] Caronia S, Taylor K, Pagliaro L, Carr C, Palazzo U, Petrik J, et al. Further evidence for an association between non-insulin-dependent diabetes mellitus and chronic hepatitis C virus infection. Hepatol Baltim Md 1999;30(4):1059–63.
[135] Mason AL, Lau JY, Hoang N, Qian K, Alexander GJ, Xu L, et al. Association of diabetes mellitus and chronic hepatitis C virus infection. Hepatol Baltim Md 1999;29(2):328–33.
[136] Buskila D. Hepatitis C-associated rheumatic disorders. Rheum Dis Clin North Am 2009;35(1):111–23.
[137] Sayiner ZA, Haque U, Malik MU, Gurakar A. Hepatitis C virus infection and its rheumatologic implications. Gastroenterol Hepatol 2014;10(5):287–93.
[138] Calabrese LH, Cacoub PP. For patients with rheumatic disease and hepatitis C infection: the end of interferon. RMD Open 2015;1(1):e000008.