



Benefits of Combined MRI Sequences in Meningioma Consistency Prediction: A Prospective Study of 287 Consecutive Patients

Kriengsak Limpastan¹ Kittisak Unsrison² Tanat Vaniyapong¹ Thunya Norasetthada¹
Wanarak Watcharasakul¹ Chumpon Jetjumong¹

¹Neurosurgery Unit, Clinical Surgical Research Center, Faculty of Medicine, Chiang Mai University, Chiang Mai, Thailand

²Department of Radiology, Faculty of Medicine, Chiang Mai University, Chiang Mai, Thailand

Address for correspondence Kriengsak Limpastan, MD, Neurosurgery Unit, Faculty of Medicine, Chiang Mai University, Chiang Mai 50200, Thailand (e-mail: limpastan@gmail.com).

AJNS 2022;17:614–620.

Abstract

Objective Consistency of meningiomas is one of the most important factors affecting the completeness of removal and major risks of meningioma surgery. This study used preoperative magnetic resonance imaging (MRI) sequences in single and in combination to predict meningioma consistency.

Methods The prospective study included 287 intracranial meningiomas operated on by five attending neurosurgeons at Chiang Mai University Hospital from July 2012 through June 2020. The intraoperative consistency was categorized in four grades according to the method of surgical removal and intensity of ultrasonic aspirator, then correlated with preoperative tumor signal intensity pattern on MRI including T1-weighted image, T2-weighted image (T2WI), fluid-attenuated inversion recovery (FLAIR), and diffusion-weighted image (DWI), which were described as hypointensity, isointensity, and hyperintensity signals which were blindly interpreted by one neuroradiologist.

Results Among 287 patients, 29 were male and 258 female. The ages ranged from 22 to 83 years. A total of 189 tumors were situated in the supratentorial space and 98 were in the middle fossa and infratentorial locations. Note that 125 tumors were found to be of soft consistency (grades 1, 2) and 162 tumors of hard consistency (grades 3, 4). Hyperintensity signals on T2WI, FLAIR, and DWI were significantly associated with soft consistency of meningiomas (relative risk [RR] 2.02, 95% confidence interval [CI] 1.35–3.03, $p = 0.001$, RR 2.19, 95% CI 1.43–3.35, $p < 0.001$, and RR 1.47, 95% CI 1.02–2.11, $p = 0.037$, respectively). Further, chance to be soft consistency significantly increased when two and three hyperintensity signals were combined (RR 2.75, 95% CI 1.62–4.65, $p \leq 0.001$, RR 2.79, 95% CI 1.58–4.93, $p < 0.001$, respectively). Hypointensity signals on T2WI, FLAIR, and DWI were significantly associated with hard consistency of meningiomas (RR 1.82, 95% CI 1.18–2.81, $p = 0.007$, RR 1.80, 95% CI 1.15–2.83,

Keywords

- ▶ combined MRI
- ▶ consistency
- ▶ meningioma consistency
- ▶ preoperative MRI
- ▶ prediction
- ▶ sequences

article published online
December 10, 2022

DOI <https://doi.org/10.1055/s-0042-1758849>.
ISSN 2248-9614.

© 2022. Asian Congress of Neurological Surgeons. All rights reserved.

This is an open access article published by Thieme under the terms of the Creative Commons Attribution-NonDerivative-NonCommercial-License, permitting copying and reproduction so long as the original work is given appropriate credit. Contents may not be used for commercial purposes, or adapted, remixed, transformed or built upon. (<https://creativecommons.org/licenses/by-nc-nd/4.0/>)

Thieme Medical and Scientific Publishers Pvt. Ltd., A-12, 2nd Floor, Sector 2, Noida-201301 UP, India

$p = 0.010$, RR 1.67, 95% CI 1.07–2.59, $p = 0.023$, respectively) and chance to be hard consistency significantly increased when three hypointensity signals were combined (RR 1.82, 95% CI 1.11–2.97, $p = 0.017$).

Conclusion T2WI, FLAIR, and DWI hyperintensity signals of the meningiomas was solely significantly associated with soft consistency and predictive value significantly increased when two and three hyperintensity signals were combined. Each of hypointensity signals on T2WI, FLAIR, and DWI was significantly associated with hard consistency of tumors and tendency to be hard consistency significantly increased when hypointensity was found in all three sequences.

Introduction

Meningiomas are one of the most common intracranial extra-axial tumors found in clinical practice in most neurosurgical departments. Meningiomas vary in many aspects including pathologic, imaging appearance, neurovascular involvements, tumor consistency, and treatment outcome. Many factors including peritumoral arachnoid plane and brain invasion,¹ major neurovascular involvement,² and tumor consistency may affect the completeness of tumor removal and surgical outcome. Tumor consistency is one of the critical factors affecting the completeness of surgical removal and treatment outcome^{2–11} especially in the case of neurovascular involvement. Recognition of tumor consistency constitutes valuable data to preoperative planning for safe surgical approaches and improved outcomes.⁵

Water and collagen content of the tumor are important determinants of meningioma consistency.⁷ Soft consistency tumors harbor more water and less collagen content for which T2-weighted image (T2WI) on magnetic resonance imaging (MRI) sequences could be detected as hyperintensity. High signal intensity on T2WI and fluid-attenuated inversion recovery (FLAIR) image is due to long T2WI relaxation time of the material which is related to the amount of water content and impurity of the water within the material. For tumor signal intensity on the T2WI and FLAIR, the higher signal intensity correlates with greater amount of tumor water content and vascularity which prior studies have shown to correlate with the angioblastic, meningothelial, or syncytial histopathologic subtype and tended to be softer tumors. Meningioma with high collagen content (fibroblastic subtype), has less amount of water molecule within the tumor, is shown by lower T2WI signal, and the tumor consistency tended to be firmer.^{12–14} Diffusion-weighted imaging (DWI) represent the random Brownian movement of water molecule within the object in which tumor with high cellularity or dense collagen matrix (fibroblastic subtype) will restrict the movement of water molecule within the tumor, causing high signal intensity on the DWI.

Many studies reported the benefits of preoperative MRI using different techniques to establish the consistency of the tumor including both qualitative and quantitative methods. Related studies have investigated the routine sequences of MRI intensity including T1-weighted image (T1WI), T2WI,

and FLAIR to predict meningioma consistency.⁸ Among the quantification methods, many techniques were reported including using magnetic resonance fingerprinting quantification of T1 and T2 relaxometry³ and fractional anisotropy (FA) value calculated from preoperative magnetic resonance diffusion tensor imaging to predict meningioma consistency.^{2,5} Currently, the absence remains of a definite method in meningioma consistency prediction. Many studies reported hyperintensity of meningioma on T2WI was associated with soft consistency of meningioma.^{7,8,15,16} However, using the combination of MRI sequences which may add additional predictive value has not yet been studied well. This study used T1WI, T2WI, FLAIR, and DWI sequences of a preoperative MRI to predict the consistency of the tumor and study the combination of these MRI sequences to evaluate the value in meningioma consistency prediction.

Methods

The prospective study included all the patients with a diagnosis of an intracranial meningioma undergoing tumor evaluation on two 1.5T MRI systems (Signa Excite HD Software, Versions 14 and 16; GE Medical Systems) using an 8-channel head coil. Preoperative MRI pulse sequence protocol was the standard used to evaluate intracranial tumor (T1WI, T2WI, FLAIR, DWI, gradient recalled echo T2*, and post-gadolinium T1W with fat suppression). The signal intensity of the tumor was evaluated blindly by an experienced neuroradiologist, comparing the tumor signal with the signal intensity of cerebral cortical grey matter in vicinity to the tumor. The tumor signal intensity pattern was described as hypointensity, isointensity, and hyperintensity (► **Fig. 1**). The patients were operated on by one of the five attending neurosurgeons at the Faculty of Medicine, Chiang Mai University Hospital from July 1, 2012 to June 8, 2020. All 287 patients included were pathologically confirmed as meningiomas. The data collected included sex, age, tumor location, intraoperative consistency, and reported pathology. Intraoperative consistency was categorized in four grades according to the method of surgical removal. The grades were identified as the methods of the major part of the tumor (> 75%) removed including suction, the intensity of the ultrasonic aspirator (Söring: SONOCA 300), sharp cut, and cautery loop. Grade 1 was defined as soft tumor, which was

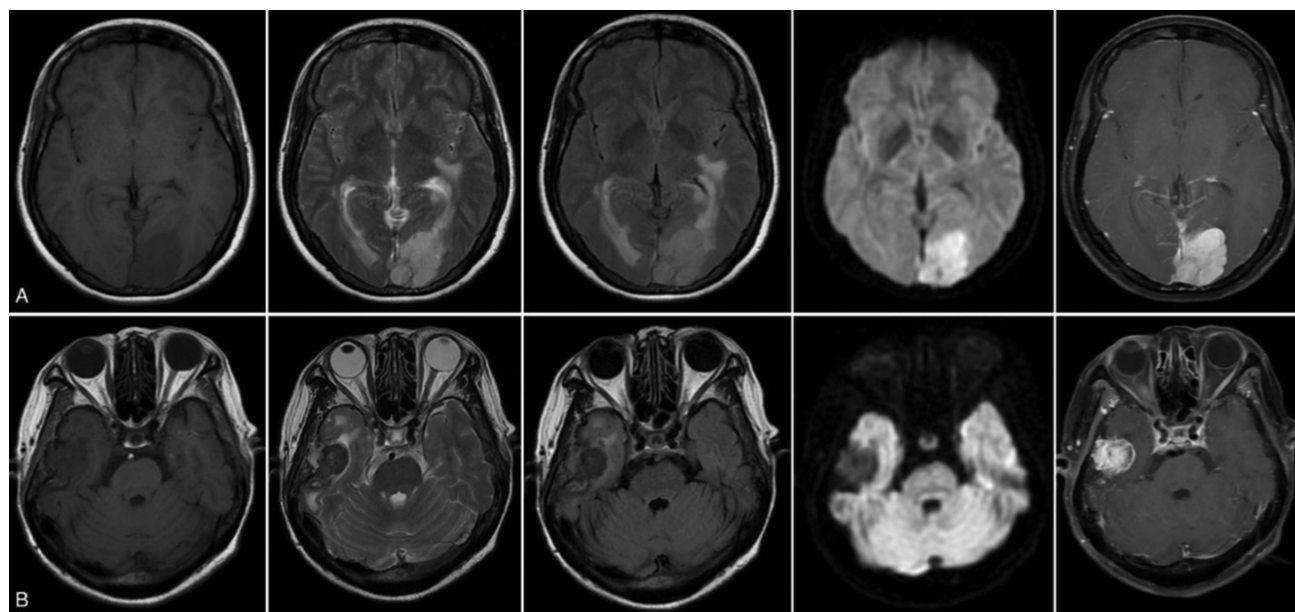


Fig. 1 (A) T1-weighted image (T1WI) = 0, T2-weighted image (T2WI) = 2, fluid-attenuated inversion recovery (FLAIR) = 2, diffusion-weighted image (DWI) = 2, T1WI with gadolinium. (B) T1WI = 0, T2WI = 0, FLAIR = 0, DWI = 0, T1WI with gadolinium. Magnetic resonance imaging (MRI). T1WI, T2WI, FLAIR, DWI, and T1WI with gadolinium sequences in orders. While 0 = hypointensity, 1 = isointensity, 2 = hyperintensity.

easily removed by suction. Grade 2 was defined as quite soft tumor, some fibrous stroma with capsule which could be removed by ultrasonic aspirator with power intensity less than 50%. Grade 3 was defined as average consistency tumor, denser stroma with capsule whose removal required more than 50% of ultrasonic aspirator power intensity. Grade 4 was defined as hard or calcified tumor requiring sharp cut or cutting cautery loop for removal. Grades 1 and 2 consistencies were considered to be soft, while grades 3 and 4 were considered to be hard. The intraoperative findings regarding consistency correlated with preoperative MRI sequences which were interpreted blindly by an experienced neuro-radiologist. Statistical analysis was performed using STATA Program, Version 11 (serial number 40110561832). For statistical analysis, we collected the data and analyzed using percent and mean (standard deviation). Univariable risk regression was used to identify the risk for soft and hard consistency. A *p*-value of 0.05 or less was considered statistically significant. The study was reviewed and approved by the Research Ethics Committee, Faculty of Medicine, Chiang Mai University, Chiang Mai, Thailand (ID266/2557).

Result

Of 287 patients enrolled in the study, 29 (10.10%) were male and 258 (89.90%) female. Their ages ranged from 22 to 83 years. In total, 189 tumors were situated in the supratentorial space including 26 convexity meningiomas, 25 parasagittal, and 138 anterior cranial fossa and sphenoid wing meningiomas. In all, 98 were in the middle fossa including cavernous sinus meningiomas and those in the infratentorial location. Details of tumor location are shown in ►Table 1. In total, 187 were World Health Organization (WHO) grade I, 95 were WHO grade II, and 5 were

WHO grade III in which WHO grades were not significantly associated with meningioma consistency as shown in ►Table 2. Altogether, 125 tumors were found to be of soft consistency (grades 1, 2) and 162 tumors of hard

Table 1 Characteristic of patients

Parameters	N (%) (n = 287)
Sex, n (%)	
• Female	258 (89.90)
• Male	29 (10.10)
Age (y)	
Mean (SD)	51.72 (9.87)
Min-max	22–83
≤ 60 y	235 (81.88)
> 60 y	52 (18.12)
Location, n (%)	
• Anterior cranial fossa	138 (48.08)
• Middle cranial fossa	37 (12.89)
• Posterior cranial fossa	61 (21.25)
• Convexity	26 (9.06)
• Parasagittal	25 (8.71)
Consistency grading, n (%)	
• Suction	105 (36.59)
• < 50% power	20 (6.97)
• > 50% power	82 (28.57)
• Scissors	80 (27.87)

Abbreviation: SD, standard deviation.

consistency (grades 3, 4). The consistency was not significantly associated with tumor location ($p=0.151$) as shown in **Table 2**. T1WI signal intensity was not significantly associated with meningioma's consistency. Hyperintensity signals on T2WI, FLAIR, and DWI were significantly associated with soft consistency of meningiomas (relative risk [RR] 2.02, 95% confidence interval [CI] 1.35–3.03, $p=0.001$, RR 2.19, 95% CI 1.43–3.35, $p<0.001$, and RR 1.47, 95% CI 1.02–2.11, $p=0.037$, respectively). Chance to be soft consistency significantly increased when two and three hyperintensity signals

Table 2 Demographic data and patients' parameter (MRI findings, location, pathology) and tumor consistency

Parameters	Soft	Hard	p-Value
	N = 125	N = 162	
Age, year, n (%)			0.443
• ≤ 60	105 (84)	130 (80.25)	
• > 60	20 (16)	32 (19.75)	
Gender, n (%)			0.559
• Male	11 (8.80)	18 (11.11)	
• Female	114 (91.20)	144 (88.89)	
Location, n (%)			0.151
• Anterior cranial fossa	56 (44.80)	82 (50.62)	
• Middle cranial fossa	23 (18.40)	14 (8.64)	
• Posterior cranial fossa	23 (18.40)	38 (23.46)	
• Convexity	11 (8.80)	15 (9.26)	
• Parasagittal	12 (9.60)	13 (8.02)	
T1WI signal, n (%)			0.347
• Hypointensity	22 (17.60)	22 (13.58)	
• Isointensity	88 (70.40)	126 (77.78)	
• Hyperintensity	15 (12)	14 (8.64)	
T2WI signal, n (%)			< 0.001
• Hypointensity	1 (0.80)	24 (14.81)	
• Isointensity	31 (24.80)	62 (38.27)	
• Hyperintensity	93 (74.40)	76 (46.91)	
FLAIR, n (%)			< 0.001
• Hypointensity	1 (0.80)	22 (13.58)	
• Isointensity	26 (20.80)	59 (36.42)	
• Hyperintensity	98 (78.40)	81 (50)	
DWI, n (%)			< 0.001
• Hypointensity	3 (2.40)	23 (14.29)	
• Isointensity	76 (60.80)	103 (63.98)	
• Hyperintensity	46 (36.80)	35 (21.74)	
Consistency grading, n (%)			< 0.001
• Suction	105 (84)	0	
• $< 50\%$ ultrasonic aspirator power	20 (16)	0	
• $> 50\%$ ultrasonic aspirator power	0	82 (50.62)	
• Sharp cut and cautery loop	0	80 (49.38)	
WHO			0.422
• Grade I	79 (63.20)	108 (66.67)	
• Grade II	45 (36.0)	50 (30.86)	
• Grade III	1 (0.8)	4 (2.47)	

Abbreviations: DWI, diffusion-weighted image; FLAIR, fluid-attenuated inversion recovery; MRI, magnetic resonance imaging; T1WI, T1-weighted image; T2WI, T2-weighted image; WHO, World Health Organization.

Table 3 Chance for soft consistency (univariable analysis)

Signal	RR	95% CI	p-Value
T1WI hyperintensity	1.21	0.71–2.08	0.483
T2WI hyperintensity	2.02	1.35–3.03	0.001
FLAIR hyperintensity	2.19	1.43–3.35	< 0.001
DWI hyperintensity	1.47	1.02–2.11	0.037
Combination of either hyperintensity T2WI, FLAIR, DWI			
- Hyperintensity in 1 phase	2.19	1.05–4.56	0.035
- Hyperintensity in 2 phase	2.75	1.62–4.65	< 0.001
- Hyperintensity in 3 phase	2.79	1.58–4.93	< 0.001

Abbreviations: CI, confidence interval; DWI, diffusion-weighted image; FLAIR, fluid-attenuated inversion recovery; RR, relative risk; T1WI, T1-weighted image; T2WI, T2-weighted image.

were combined (RR 2.75, 95% CI 1.62–4.65, $p \leq 0.001$ and RR 2.79, 95% CI 1.58–4.93, $p < 0.001$, respectively), as shown in **Table 3**. Hypointensity signals on T2WI, FLAIR, and DWI were significantly associated with hard consistency of meningiomas (RR 1.82, 95% CI 1.18–2.81, $p = 0.007$, RR 1.80, 95% CI 1.15–2.83, $p = 0.010$, and RR 1.67, 95% CI 1.07–2.59, $p = 0.023$, respectively) and chance to be hard consistency significantly increased when three hypointensity signals were combined (RR 1.82, 95% CI 1.11–2.97, $p = 0.017$) as shown in **Table 4**.

Discussion

Meningiomas are globally one of the most common intracranial tumors, more than 90% being pathologically benign¹⁷. The management strategy goal is to keep the patient fully functional and provide long-term relief or prevent intracranial tumor growth-associated problems.¹⁸ Extent and completeness of surgical resection are clearly related to recurrence rate.¹⁸ Many factors including deep-seated location of the tumors, adjacent structure involvement, and major neurovascular encasement are all influential and can preclude safe total surgical removal of the meningioma.

Consistency of the meningioma is one of the most important factors influencing the completeness of surgical excision and surgical risks especially in situations with neurovascular involvement. Meningiomas with soft consistency are simply

removable by suction and are quite safe to achieve total removal even in situations of major neurovascular encasement.¹⁹ However, hard consistency tumors, where tumor removal requires a sharp cut or cutting cautery loop, may harbor much higher risks of neurovascular injury while attempting total surgical removal. In this situation maximum safe resection should be considered to avoid devastating complications from iatrogenic neurovascular injury. Hence, preoperative recognition of tumor consistency represents valuable information to optimize surgical approach selection and good surgical planning to enable achieving the optimal goal for the individual patient.

Tumor consistency grading systems were proposed by some studies. Zada et al¹¹ reported five consistency score grades according to the method used in the tumor debulking process including suction, ultrasonic aspirator, sharp dissection, and loop cautery. Smith et al⁹ reported three tumor consistency grading scales based on Cavitron ultrasonic surgical aspirator intensity used in tumor removal. Currently, tumor consistency grading systems remain inconclusive. Tumor consistency may differ in parts of the tumor. In this study, we graded tumor consistency by methods used to remove the major part of tumor (> 75%) including suction, ultrasonic aspirator power less than 50%, ultrasonic aspirator power greater than 50%, and sharp cut or cautery loop which is more clearly defined and less subjective as shown in **Table 5**.

Table 4 Chance for hard consistency (univariable analysis)

Signal	RR	95% CI	p-Value
T1WI hypointensity	0.87	0.55–1.36	0.537
T2WI hypointensity	1.82	1.18–2.81	0.007
FLAIR hypointensity	1.80	1.15–2.83	0.010
DWI hypointensity	1.67	1.07–2.59	0.023
Combination of either hypointensity T2WI, FLAIR, DWI			
- Hypointensity in 1 phase	1.37	0.56–3.34	0.490
- Hypointensity in 2 phase	1.92	0.79–4.68	0.153
- Hypointensity in 3 phase	1.82	1.11–2.97	0.017

Abbreviations: CI, confidence interval; DWI, diffusion-weighted image; FLAIR, fluid-attenuated inversion recovery; RR, relative risk; T1WI, T1-weighted image; T2WI, T2-weighted image.

Table 5 Meningioma consistency grading system

Consistency grade	General description	Instrument(s) used for internal debulking for more than 75% of tumor volume
1	Soft	Suction
2	Quite soft, some fibrous stroma with capsule	Ultrasonic aspirator power < 50%
3	Average consistency, denser stroma with capsule	Ultrasonic aspirator power > 50%
4	Hard or calcified tumor	Sharp cut with scissor or cautery loop

MRI is an important imaging tool for preoperative evaluation in most intracranial brain tumors, providing essential details of soft tissue components and related adjacent structure. The hyperintensity of soft meningiomas on T2WI are thought to be related to higher water content of the tumor, while hypointensity on T2WI of hard tumors might be due to less water, more collagen and calcium content, and hypercellularity of the tumors.⁷ Benign meningiomas typically showed isointensity to slightly hypointensity to the gray matter on T1WI and iso- to slightly hyperintensity on T2WI.²⁰ Meningiomas have a wide spectrum of histologic appearances in which some features cause distinct MRI signal patterns. Microcystic variant shows predominant uniform hypointensity on T1WI and hyperintensity on T2WI²¹; lipoblastic meningioma shows hyperintensity of intratumoral fat on T1WI,²² and sclerotic meningioma (densely packed hyalinized collagen bundles and abundant tumor calcification) shows hypointensity on T1WI and marked hypointensity on T2WI.²³

Many earlier published studies endeavored to predict meningioma consistency using several methods including quantitative measurement and conventional MRI sequence qualitative methods, but a definite conclusion remains unavailable.^{2,5,7-10,16,24,25}

Regarding quantitative studies, MRI calculation of FA values of hard fibroblastic meningiomas were reported significantly higher than those of soft meningothelial meningiomas ($p = 0.002$).⁵ FA value of more than 0.3 reported a significant predictive value of hard consistency of meningiomas.² Ortega-Porcayo et al²⁴ reported FA values for hard tumors were not significantly higher than those for soft tumors ($p = 0.115$) and concluded FA value was not an independent predictor for tumor consistency.

Among conventional MRI sequence qualitative studies, mainly based on detecting free water content of the tumor,² hyperintensity on protein density and that T2WI reported signs of a soft tumor.¹⁶ Signal intensity of T2WI and FLAIR significantly correlated with the tumor consistency; hypointense tumors on T2WI and FLAIR sequences tended to be hard, whereas tumors showing hyperintensity of T2WI and FLAIR were associated with soft consistency.⁸ These findings were also reported in related studies.^{7,8,16}

In the present study, we found hyperintensity solely on T2WI, FLAIR, and DWI was significantly associated with meningiomas of soft consistency and when two and three hyperintensity of T2WI, FLAIR, and DWI were combined the predictive value of soft consistency significantly increased as

shown in ►Table 3. Also, hypointensity solely on T2WI, FLAIR, and DWI was significantly associated with hard consistency and chance to be hard consistency significantly increased when hypointensity was revealed in all three sequences as shown in ►Table 4. However, while directly comparing the relative risk of each parameter with the combinations, due to limited number of sample size in each study arm, no statistical significance was observed. Further study with larger sample size needs to be carried out to better prove this finding.

Tumor size and location were also reported related to tumor consistency, meningioma size (diameter > 2 cm), and supratentorial or sphenoidal wing location and were more frequently associated with hard consistency meningiomas ($p < 0.05$).² However, in our study the location of meningiomas was not significantly associated with tumor consistency ($p = 0.151$) as shown in ►Table 2.

Conclusion

Each of T2WI, FLAIR, and DWI hyperintensity signal of the meningiomas on MRI was solely and significantly associated with soft consistency and predictive value that significantly increased when two and three hyperintensities of T2WI, FLAIR, and DWI were combined. Each hypointensity signal of the meningiomas concerning T2WI, FLAIR, and DWI on MRI was solely and significantly associated with hard consistency of tumors and chance to be hard consistency significantly increased when hypointensity was found in all three sequences. Combined intensity findings on T2WI, FLAIR, and DWI added more predictive value of meningioma consistency prediction, further study with more sample size may benefit to confirm this finding.

Conflict of Interest
None declared.

Acknowledgment

This research work was partially supported by Faculty of Medicine, Chiang Mai University, Chiang Mai, Thailand.

References

- Ong T, Bharatha A, Alsufayan R, Das S, Lin AW. MRI predictors for brain invasion in meningiomas. *Neuroradiol J* 2021;34(01):3-7
- Romani R, Tang WJ, Mao Y, et al. Diffusion tensor magnetic resonance imaging for predicting the consistency of intracranial meningiomas. *Acta Neurochir (Wien)* 2014;156(10):1837-1845

- 3 Bai Y, Zhang R, Zhang X, et al. Magnetic resonance fingerprinting for preoperative meningioma consistency prediction. *Acad Radiol* 2022;29(08):e157–e165
- 4 Cepeda S, Arrese I, García-García S, et al. Meningioma consistency can be defined by combining the radiomic features of magnetic resonance imaging and ultrasound elastography. A pilot study using machine learning classifiers. *World Neurosurg* 2021;146:e1147–e1159
- 5 Kashimura H, Inoue T, Ogasawara K, et al. Prediction of meningioma consistency using fractional anisotropy value measured by magnetic resonance imaging. *J Neurosurg* 2007;107(04):784–787
- 6 Miyoshi K, Wada T, Uwano I, et al. Predicting the consistency of intracranial meningiomas using apparent diffusion coefficient maps derived from preoperative diffusion-weighted imaging. *J Neurosurg* 2020;1–8. Doi: 10.3171/2020.6.JNS20740
- 7 Shiroishi MS, Cen SY, Tamrazi B, et al. Predicting meningioma consistency on preoperative neuroimaging studies. *Neurosurg Clin N Am* 2016;27(02):145–154
- 8 Sitthinamsuwan B, Khampalikit I, Nunta-aree S, Srirabheebhat P, Witthiwej T, Nitising A. Predictors of meningioma consistency: a study in 243 consecutive cases. *Acta Neurochir (Wien)* 2012;154(08):1383–1389
- 9 Smith KA, Leever JD, Chamoun RB. Predicting consistency of meningioma by magnetic resonance imaging. *J Neurol Surg B Skull Base* 2015;76(03):225–229
- 10 Watanabe K, Kakeda S, Yamamoto J, et al. Prediction of hard meningiomas: quantitative evaluation based on the magnetic resonance signal intensity. *Acta Radiol* 2016;57(03):333–340
- 11 Zada G, Yashar P, Robison A, et al. A proposed grading system for standardizing tumor consistency of intracranial meningiomas. *Neurosurg Focus* 2013;35(06):E1
- 12 Suzuki Y, Sugimoto T, Shibuya M, Sugita K, Patel SJ. Meningiomas: correlation between MRI characteristics and operative findings including consistency. *Acta Neurochir (Wien)* 1994;129(1-2):39–46
- 13 Chen TC, Zee CS, Miller CA, et al. Magnetic resonance imaging and pathological correlates of meningiomas. *Neurosurgery* 1992;31(06):1015–1021, discussion 1021–1022
- 14 Maiuri F, Iaconetta G, de Divitiis O, Cirillo S, Di Salle F, De Caro ML. Intracranial meningiomas: correlations between MR imaging and histology. *Eur J Radiol* 1999;31(01):69–75
- 15 Hoover JM, Morris JM, Meyer FB. Use of preoperative magnetic resonance imaging T1 and T2 sequences to determine intraoperative meningioma consistency. *Surg Neurol Int* 2011;2:142
- 16 Yamaguchi N, Kawase T, Sagoh M, Ohira T, Shiga H, Toya S. Prediction of consistency of meningiomas with preoperative magnetic resonance imaging. *Surg Neurol* 1997;48(06):579–583
- 17 Claus EB, Bondy ML, Schildkraut JM, Wiemels JL, Wrensch M, Black PM. Epidemiology of intracranial meningioma. *Neurosurgery* 2005;57(06):1088–1095, discussion 1088–1095
- 18 Pamir MNBP, Fahlbusch R. *Meningiomas: A Comprehensive Text*. Philadelphia, PA: Elsevier; 2010
- 19 Limpastan K. Planum sphenoidale meningioma with major vascular encasement: a report of 2 cases. *Bull Neurosurg Assoc Thailand* 2000;10(01):3–10
- 20 Watts J, Box G, Galvin A, Brotchie P, Trost N, Sutherland T. Magnetic resonance imaging of meningiomas: a pictorial review. *Insights Imaging* 2014;5(01):113–122
- 21 Chen CJ, Tseng YC, Hsu HL, Jung SM. Microcystic meningioma: importance of obvious hypointensity on T1-weighted magnetic resonance images. *J Comput Assist Tomogr* 2008;32(01):130–134
- 22 Radwan W, Lucke-Wold B, Cheyuo C, Ahn J, Gyure K, Bhatia S. Lipomatous meningioma: case report and review of the literature. *Case Stud Surg* 2016;2(04):58–61
- 23 Shaman MA, Zak IT, Kupsky WJ. Best cases from the AFIP: involuted sclerotic meningioma. *Radiographics* 2003;23(03):785–789
- 24 Ortega-Porcayo LA, Ballesteros-Zebadúa P, Marrufo-Meléndez OR, et al. Prediction of mechanical properties and subjective consistency of meningiomas using T1-T2 assessment versus fractional anisotropy. *World Neurosurg* 2015;84(06):1691–1698
- 25 Smith KA, Leever JD, Hylton PD, Camarata PJ, Chamoun RB. Meningioma consistency prediction utilizing tumor to cerebellar peduncle intensity on T2-weighted magnetic resonance imaging sequences: TCTI ratio. *J Neurosurg* 2017;126(01):242–248