



# Azacitidine-induced acute lung injury in a patient with therapy-related myelodysplastic syndrome

Shinichi Makita<sup>1</sup>, Wataru Munakata<sup>1</sup>,  
Daisuke Watabe<sup>2</sup>, Akiko Miyagi Maeshima<sup>3</sup>,  
Hirokazu Taniguchi<sup>3</sup>, Kosuke Toyoda<sup>1</sup>,  
Nobuhiko Yamauchi<sup>1</sup>, Suguru Fukuhara<sup>1</sup>,  
Dai Maruyama<sup>1</sup>, Yukio Kobayashi<sup>1</sup> and  
Kensei Tobinai<sup>1</sup>

## Abstract

Azacitidine is a first-in-class demethylating agent, and it is widely used globally as a first-line treatment for higher-risk myelodysplastic syndrome (MDS). Here, we report the case of a patient with MDS who suffered from a rare adverse event, an acute lung injury (ALI), which was suspected to have been caused by azacitidine and was successfully treated with corticosteroids. As it is a rare, but critical, adverse event, clinicians should consider ALI as one of the differential diagnoses in cases where 1) pneumonia and fever of unknown etiology arise in MDS patients treated with azacitidine, 2) antimicrobial agents are not effective, and 3) microbiological tests produce negative results.

## Keywords

Azacitidine, myelodysplastic syndrome, follicular lymphoma, acute lung injury

Date received: 17 January 2017; accepted: 13 February 2017

## Introduction

Myelodysplastic syndrome (MDS) is a clonal hematopoietic disease characterized by cytopenia arising from ineffective hematopoiesis and an increased risk of developing acute myeloid leukemia (AML).<sup>1</sup> The current treatment options for patients with MDS are limited, with the main treatment comprising supportive care

<sup>1</sup>Departments of Hematology, National Cancer Center Hospital, Chuo-ku, Tokyo, Japan

<sup>2</sup>Departments of Pharmacy, National Cancer Center Hospital, Chuo-ku, Tokyo, Japan

<sup>3</sup>Departments of Pathology, National Cancer Center Hospital, Chuo-ku, Tokyo, Japan

### Corresponding author:

Wataru Munakata, Department of Hematology, National Cancer Center Hospital, 5-1-1 Tsukiji, Chuo-ku, Tokyo 104-0045, Japan.

Email: wmunakat@ncc.go.jp



with blood transfusions and/or hematopoietic growth factors.

Azacitidine is a first-in-class demethylating agent which has been demonstrated to significantly prolong survival while causing mild adverse events in patients with higher-risk MDS.<sup>2,3</sup> Azacitidine was approved for use by the Japanese Ministry of Health, Labor, and Welfare in 2011 and is widely used in Japan as a first-line treatment for patients with higher-risk MDS.

Several large-scale clinical trials of azacitidine have been conducted, and the majority of severe adverse events detected in these trials were hematological.<sup>4-6</sup> However, some cases involving non-infectious pulmonary toxicities related to azacitidine treatment have been reported in Japan and in Western countries, although previous trials have not described these types of adverse events.<sup>7-14</sup> Pulmonary toxicities are rare but potentially critical adverse events, and their clinical characteristics and most appropriate management strategies remain unknown.

Here, we report the case of a patient with therapy-related MDS secondary to follicular lymphoma (FL) who suffered from a rare adverse event, an acute lung injury (ALI), which was suspected to have been caused by azacitidine treatment.

## Case report

A 77-year-old male visited our hospital to undergo follow-up examinations after treatment for FL. He had been suffering from advanced-stage FL, which was initially diagnosed 14 years previously. He had been treated with six cycles of R-CHOP (rituximab, cyclophosphamide, doxorubicin, vincristine, and prednisolone), ibritumomab tiuxetan, and two cycles of bendamustine, and achieved a durable complete remission for 4 years.

A laboratory test performed at the time of his visit showed pancytopenia. The patient's peripheral white blood cell count

was 1,200/ $\mu\text{L}$  (neutrophils, 46%; blastic cells, 2%), hemoglobin level was 7.9 g/dL, and platelet count was  $9.8 \times 10^4/\mu\text{L}$ . Bone marrow aspiration revealed a hypocellular bone marrow and dysplastic changes in three lineages. Blastic cells accounted for 8.8% of all nucleated cells. Complex karyotypic abnormalities, including del (7), were observed during G-banding. Based on these results, therapy-related MDS was diagnosed (refractory anemia with an excess of blasts type 2 (RAEB-2) with high-risk features of the International Prognostic Scoring System (IPSS)).<sup>15</sup>

The patient was treated with azacitidine (75 mg/m<sup>2</sup>/day for 5 days) via subcutaneous injection. During the first cycle, he suffered from septic arthritis of the left hip and required hospitalization, whereby intravenous piperacillin/tazobactam and vancomycin were administered for 14 days. After the patient recovered from his septic arthritis, he commenced the second cycle of azacitidine combined with oral levofloxacin as a prophylaxis against infection.

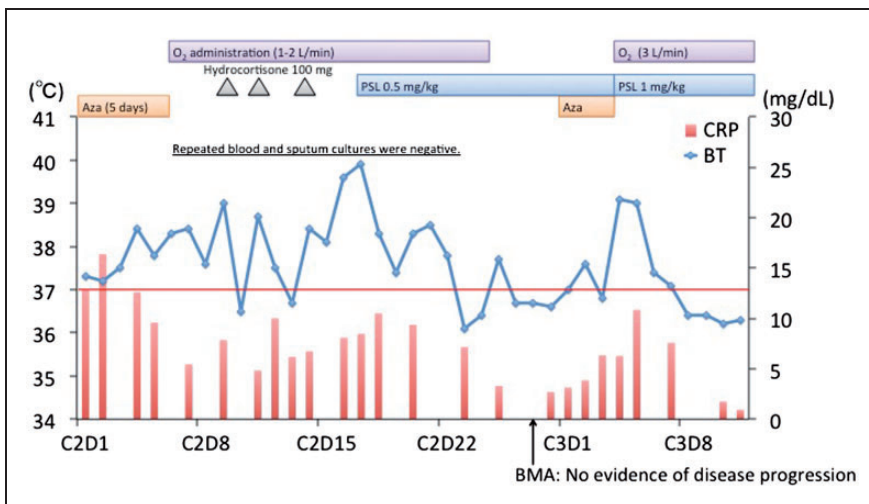
On day 4 of cycle 2, he had a fever of up to 38.4°C and exhibited oxygen desaturation. His peripheral white blood cell count was 1,300/ $\mu\text{L}$  (neutrophils, 17%; blastic cells, 13%). His CD4-positive T-cell count was low (119/ $\mu\text{L}$ ). His other laboratory findings are shown in Table 1. Treatment for febrile neutropenia (intravenous cefepime and micafungin) was initiated, but his symptoms did not improve. The patient's clinical course is summarized in Figure 1.

A whole-body computed tomography (CT) scan revealed diffuse ground-glass opacities in both lungs, which were not observed on the baseline CT scan (Figures 2(a) and 2(b)). These findings closely resembled those of *Pneumocystis jirovecii* pneumonia (PCP). However, blood and sputum cultures were negative, and the patient's serum beta-D-glucan level was not elevated. Tests for cytomegalovirus antigen and galactomannan antigen were also negative. Bronchoscopy

**Table 1.** Laboratory findings at the time of onset.

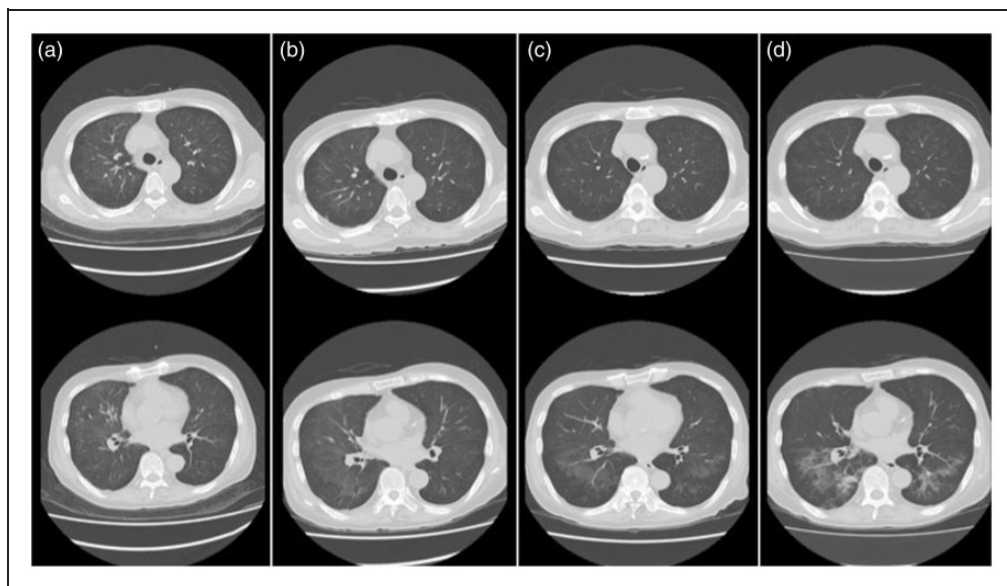
Count of blood cells			Biochemistry		
WBC	1,300	μ/L	TP	5.2	g/dL
Segmented neutrophils	10	%	Alb	2.3	g/dL
Stab neutrophils	3	%	T-Bil	0.6	mg/dL
Lymphocytes	49	%	BUN	24	mg/dL
Monocytes	20	%	Cr	0.90	mg/dL
Eosinophils	0	%	Na	133	mEq/L
Basophils	1	%	K	3.4	mEq/L
Blasts	13	%	Cl	100	mEq/L
Hemoglobin	7.3	g/dL	AST	25	U/L
Hematocrit	20.2	%	ALT	53	U/L
Platelets	2.3 × 10 <sup>4</sup>	μ/L	LDH	239	U/L
Flow cytometry			Immunology		
CD3	35.2	%	CRP	5.43	mg/dL
CD4	18.7	%	KL-6	154	U/mL
CD8	20.7	%	SP-D	68.6	ng/mL
CD20	38.6	%	Beta-D-glucan	negative	
			CMV antigenemia	negative	
			Galactomannan antigen	negative	

Abbreviations: Alb, albumin; ALT, alanine aminotransferase; AST, aspartate transaminase; BUN, blood urea nitrogen; Cl, chlorine; CMV cytomegalovirus; Cr, creatinine; CRP, C-reactive protein; K potassium; KL-6 Krebs von den Lungen-6; LDH, lactate dehydrogenase; Na, sodium; SP-D, surfactant protein-D; T-Bil, total bilirubine; TP, total protein; WBC, white blood cell count.



**Figure 1.** The patient's clinical course and changes in body temperature.

Abbreviations: Aza, azacitidine; BMA, bone marrow aspiration; BT, body temperature; CRP, C-reactive protein; PSL, prednisolone.



**Figure 2.** Chest CT scan obtained on day 4 of cycle 2 of azacitidine treatment (b) exhibited worse findings than a scan acquired at baseline (a). Prednisolone treatment improved these findings on day 25 of cycle 2 (c). However, the re-administration of azacitidine made them worse again on day 4 of cycle 3 (d).

was considered, but could not be performed because of the patient's low platelet count. Although PCP is relatively rare in patients with myeloid neoplasms, based on the patient's CT findings and low CD4-positive T cell count, atovaquone was administered as an empiric therapy for PCP.

The patient's symptoms spontaneously improved, but the intermittent elevation of his body temperature continued. To ameliorate his symptoms, 0.5 mg/kg prednisolone was initiated on day 18 of cycle 2, and the patient's fever and oxygen desaturation gradually improved within a week. His CT findings were also improved on day 25 of cycle 2 (Figure 2(c)). Based on the patient's clinical course, it was suspected that the lung injury had an immunological pathophysiology, e.g., it was tumor-related or drug-induced rather than an infectious pathophysiology.

Although azacitidine did not produce any hematological improvement, a bone marrow examination performed on day 28 of cycle 2

did not reveal any evidence of disease progression or transformation to AML. Considering these clinical benefits, a third cycle of azacitidine was started. However, the fever occurred again on day 3, and the patient's chest CT findings worsened (Figure 2(d)). The exacerbation of the lung injury followed the course of azacitidine treatment, and there was no evidence of other infectious causes, such as bacterial, fungal, or viral infections. Thus, the patient was clinically diagnosed with azacitidine-induced ALI. The azacitidine treatment was suspended, and 1 mg/kg prednisolone was administered for 2 weeks. After the initiation of prednisolone treatment, the patient's fever and oxygen desaturation improved markedly.

## Discussion

Here, we report the case of a patient with therapy-related MDS who developed an ALI following azacitidine treatment.

**Table 2.** Reports on onazacitidine-induced lung toxicities in patients with myelodysplastic syndrome.

Author	Age/Sex	Symptoms of onset	Time of onset	CT findings	Pathological findings	Treatment	Outcome
Adams, et al. <sup>7</sup>	71/M	fever	cycle 1	diffuse, bilateral, interstitial infiltrates	organizing pneumonitis	none	died
Hueser, et al. <sup>8</sup>	55/F	fever	cycle 1	bilateral interstitial opacity	no biopsy	methylprednisolone 200 mg/day	improved
Nair, et al. <sup>9</sup>	76/M	fever	cycle 2	diffuse, bilateral, patchy infiltrates	eosinophilic pneumonia	methylprednisolone 1 mg/kg, twice daily	improved
Pillai, et al. <sup>10</sup>	74/F	fever, dry cough, dyspnea	cycle 1	peribronchiolar shadowing, bilateral lower lobe	no biopsy	methylprednisolone 1.5 g/day for 3 days	improved
Sekhri, et al. <sup>11</sup>	56/M	fever, cough, dyspnea, hypoxia	cycle 1	extensive bilateral airspace disease, nodular opacities	organizing pneumonia	methylprednisolone	improved
Verriere, et al. <sup>12</sup>	86/F	fever, dry cough	cycle 3	diffuse interstitial opacities, ground-grass shadowing	no biopsy	corticosteroid 0.75 mg/kg	improved
Hayashi, et al. <sup>13</sup>	74/M	fever, dry cough, shortness of breath	cycle 1	bilateral, non-segmental consolidation with ground-glass opacities, pleural effusion	no biopsy	methylprednisolone 1 g/day for 3 days	improved
Kuroda, et al. <sup>14</sup>	72/M	fever	cycle 1	interstitial opacities and ground-glass opacities of right upper lobe	no biopsy	methylprednisolone 500 mg/day for 4 days	died
Present case	77/M	fever	cycle 2	diffuse ground-glass opacities of the bilateral lungs	no biopsy	prednisolone 1 mg/kg	improved

Abbreviations; M male; F female.

The clinical and radiological features of this case resembled those of PCP. Our group previously reported that CD4-positive T-cell lymphocyte counts of  $\leq 200/\text{mm}^3$  were associated with a higher risk of PCP in patients with B-cell non-Hodgkin lymphoma.<sup>16</sup> Therefore, we considered the possibility of PCP at presentation, although its incidence among patients with MDS/AML is relatively low. Consequently, it was determined that the patient was not suffering from PCP or any other type of infection. As no bronchoscopy or lung biopsy examination was performed in the present case, there was no definitive evidence that would allow us to rule out etiologies other than azacitidine. However, three clinical characteristics of this case support our clinical diagnosis of an azacitidine-induced ALI. First, the ALI worsened when azacitidine was re-administered. Second, no evidence of infectious disease was detected during repeated bacterial, viral, and fungal examinations. Third, corticosteroid therapy was highly effective. The Naranjo scale, which is a classical algorithm for assessing the causes of adverse drug reactions, also suggests that a correlation exists between lung injuries and the administration of azacitidine.<sup>17</sup>

To the best of our knowledge, including our case, there have only been nine reported cases of adverse pulmonary events related to azacitidine (Table 2). Among the nine reported cases, the median number of azacitidine treatment cycles administered before lung injuries developed was one cycle (range, 1–3). The initial symptoms of this type of ALI vary, but almost all patients exhibit fever at presentation. The CT findings also vary, but the associated lung lesions are generally bilateral and diffuse.

Diffuse abnormal findings in the bilateral lungs on CT scans can be caused by various etiologies in patients with MDS/AML, such as infection, leukemic cell infiltration,

extramedullary hematopoiesis, autoimmunity, and drug-induced reactions. To make a definitive diagnosis, it is necessary to perform a lung biopsy examination. However, lung biopsy examinations were not carried out in 6 out of 9 patients because of an unfavorable general condition, hypoxia, or a low platelet count. The management strategies for infectious pulmonary disease and non-infectious lung injuries are completely different; the former requires antimicrobial agents whereas the latter is most frequently treated with corticosteroids, which can worsen infectious diseases. However, physicians often must make a decision without a confirmed histological diagnosis, which requires a lung biopsy examination.

The optimal management strategy for azacitidine-induced ALI remains unknown. Our case and previous cases indicate two important facts. First, re-treatment with azacitidine should be avoided because it promotes the progression of such lung injuries. Second, corticosteroid therapy might be effective against azacitidine-induced ALI, although it increases the risk of infectious complications. Careful but prompt use of corticosteroids should be considered for managing distressing symptoms, but the further accumulation of clinical data is required to determine the optimal dose and type of corticosteroid for treating patients with azacitidine-induced ALI.

In conclusion, we report the case of a patient with MDS who experienced a rare, but critical, adverse event, an azacitidine-induced ALI, which is difficult to diagnose definitively. Azacitidine-induced ALI should be considered as one of the differential diagnoses in cases where 1) pneumonia and fever arise in MDS patients that have been treated with azacitidine, 2) antimicrobial agents are not effective, and 3) microbiological tests produce negative results.

## Declaration of conflicting interests

The author(s) declared no potential conflicts of interest with respect to the research, authorship, and/or publication of this article.

## Funding

The author(s) disclosed receipt of the following financial support for the research, authorship, and/or publication of this article: This study was supported in part by the National Cancer Center Research and Development Fund (26-A-4 and 26-A-24).

## Disclosure

Dai Maruyama has received honoraria from Takeda.

Yukio Kobayashi has received research funding from Otsuka Pharmaceutical, Boehringer Ingelheim, Ariad, Pfizer, Astellas, and Amgen Astellas Biopharma.

Kensei Tobinai has received research funding from Chugai, Kyowa Hakko Kirin, Ono Pharmaceutical, Celgene, Janssen, GlaxoSmithKline, Eisai, Mundi Pharma, Takeda, Servier, and AbbVie; and honoraria from Zenyaku Kogyo, Esai, Takeda, Mundi Pharma, Janssen, and HUYA Bioscience.

## References

1. Swerdlow SH, Campo E, Harris NL, et al. (eds.) *WHO classification of tumours of Haematopoietic and Lymphoid tissues*. 4th ed. Lyon: IARC Press, 2008, pp.88–93.
2. Oki Y and Issa JP. Treatment options in advanced myelodysplastic syndrome, with emphasis on epigenetic therapy. *Int J Hematol* 2007; 86: 306–314.
3. Gangat N, Patnaik MM and Tefferi A. Myelodysplastic syndromes: contemporary review and how we treat. *Am J Hematol* 2016; 91: 76–89.
4. Silverman LR, Demakos EP, Peterson BL, et al. Randomized controlled trial of azacitidine in patients with the myelodysplastic syndrome: a study of the cancer and leukemia group B. *J Clin Oncol* 2002; 20: 2429–2440.
5. Fenaux P, Mufti GJ, Hellstrom-Lindberg E, et al. Efficacy of azacitidine compared with that of conventional care regimens in the treatment of higher-risk myelodysplastic syndromes: a randomised, open-label, phase III study. *Lancet Oncol* 2009; 10: 223–232.
6. Uchida T, Ogawa Y, Kobayashi Y, et al. Phase I and II study of azacitidine in Japanese patients with myelodysplastic syndromes. *Cancer Sci* 2011; 102: 1680–1686.
7. Adams CD, Szumita PM, Baroletti SA, et al. Azacitidine-induced interstitial and alveolar fibrosis in a patient with myelodysplastic syndrome. *Pharmacotherapy* 2005; 25: 765–768.
8. Hueser CN and Patel AJ. Azacitidine-associated hyperthermia and interstitial pneumonitis in a patient with myelodysplastic syndrome. *Pharmacotherapy* 2007; 27: 1759–1762.
9. Nair GB, Charles M, Ogden L, et al. Eosinophilic pneumonia associated with azacitidine in a patient with myelodysplastic syndrome. *Respir Care* 2012; 57: 631–633.
10. Pillai AR, Sadik W, Jones PA, et al. Interstitial pneumonitis—An important differential diagnosis for pulmonary sepsis in haematology patients. *Leuk Res* 2012; 36: e39–e40.
11. Sekhri A, Palaniswamy C, Kurmayagari K, et al. Interstitial lung disease associated with azacitidine use: a case report. *Am J Ther* 2012; 19: e98–e100.
12. Verriere B, Ferreira V, Denis E, et al. Azacitidine-Induced Interstitial Pneumonitis. *Am J Ther* 2016; 23: e1205–e1208.
13. Hayashi M, Takayasu H, Tada M, et al. Azacitidine-induced pneumonitis in a patient with myelodysplastic syndrome: first case report in Japan. *Intern Med* 2012; 51: 2411–2415.
14. Kuroda J, Shimura Y, Mizutani S, et al. Azacitidine-associated acute interstitial pneumonitis. *Intern Med* 2014; 53: 1165–1169.

15. Greenberg P, Cox C, LeBeau MM, et al. International scoring system for evaluating prognosis in myelodysplastic syndromes. *Blood* 1997; 89: 2079–2088. Erratum in: *Blood* 1998; 91: 1100.
16. Hashimoto K, Kobayashi Y, Asakura Y, et al. Pneumocystis jiroveci pneumonia in relation to CD4+ lymphocyte count in patients with B-cell non-Hodgkin lymphoma treated with chemotherapy. *Leuk Lymphoma* 2010; 51: 1816–1821.
17. Naranjo CA, Busto U, Sellers EM, et al. A method for estimating the probability of adverse drug reactions. *Clin Pharmacol Ther* 1981; 30: 239–245.