



Venous Air Microembolism in Chest CT Angiography: Evidence of Normalization of Deviance Phenomenon

Claudio Silva¹ Ema Leal¹

¹Department of Radiology, Clinica Alemana de Santiago, School of Medicine, Clinica Alemana - Universidad del Desarrollo, Santiago, Chile

Address for correspondence Claudio Silva, MD, MSc, Department of Radiology, Clinica Alemana de Santiago, School of Medicine, Clinica Alemana - Universidad del Desarrollo, Vitacura - 5951, Santiago, Chile (e-mail: csilvafa@alemana.cl).

Indian J Radiol Imaging 2021;31:805–808.

Abstract

Purpose This article provides evidence that detection of venous air microbubbles (VAMB) in chest computed tomography angiography (CTA) can be an indicator for “normalization of deviance” phenomenon in CT.

Method and Materials Institutional review board-approved retrospective study, with waiver for informed consent. Contrast-enhanced chest CT performed during 6 months were reviewed for presence of VAMB in venous segments visible in chest CT (subclavian, brachiocephalic vein, superior vena cava) and cardiac chambers. VAMB volumes were quantified through a semiautomatic method (MIAlite plugin for OsiriX), using a region of interest (ROI) covering the bubble. With basal results, protocols for correct injection technique were reinforced, and VAMB were estimated again at 1 and 3 months. Six months later, questionnaires were sent to the CT technologists to inquire about their perception of VAMB. Descriptive measures with central distribution and dispersion were performed; statistical significance was considered at $p < 0.05$.

Results A total of 602 chest CTA were analyzed, 332 were women (55.14%), with a median age of 58 (interquartile range [IQR] 44–72) years. Among those, 16.11% (100 cases) presented VAMB. Most were emergency department patients (51.6%), male (50.3%), with a median age of 54 (IQR 26) years. There was no difference on detection of VAMB regarding sex ($p = 0.19$), age ($p = 0.46$), or referral diagnosis ($p = 0.35$). Mean air bubbles volume was 0.2 mL (range 0.01–3.4 mL). After intervention, the number of exams with VAMB dropped to 3.29% (3/91) ($p < 0.001$). On the 6-month query, 50% of the technicians still considered that VMAB is inevitable, and 60% thought that the occurrence is not associated to risk, and therefore, not actionable.

Conclusion VAMB are a frequent finding in chest CTA, and being independent from patient-related variables, it is likely due to technical issues such as intravenous access manipulation during the exam. Reduction after reinforcement of proper performance, and certification of a low concern from CT technicians for any risk associated, provides evidence that there is normalization of deviance in this everyday procedure.

Keywords

- ▶ air bubbles
- ▶ air embolism
- ▶ computed tomography angiography
- ▶ normalization of deviance

published online
January 10, 2022

DOI <https://doi.org/10.1055/s-0041-1741093>.
ISSN 0971-3026.

© 2022. Indian Radiological Association. All rights reserved.
This is an open access article published by Thieme under the terms of the Creative Commons Attribution-NonDerivative-NonCommercial-License, permitting copying and reproduction so long as the original work is given appropriate credit. Contents may not be used for commercial purposes, or adapted, remixed, transformed or built upon. (<https://creativecommons.org/licenses/by-nc-nd/4.0/>)
Thieme Medical and Scientific Publishers Pvt. Ltd., A-12, 2nd Floor, Sector 2, Noida-201301 UP, India

Introduction

“Normalization of deviation” is a concept coined in the last decade associated with quality improvement processes. It refers to the complexity of systems and the necessary close attention to interactions between all subsystems for proper functioning.¹⁻⁴

This expression was generated from the destruction of the space shuttle Challenger in 1986. During the investigation performed after this event, a series of errors in security procedures were identified related to the detection of erosion in the booster rockets' connection rings, releasing small fragments at each launch without apparent structural damage. This fact was known over many years before the accident and yet, was not considered important until the explosion. The explanation given at the time was that those small errors had been “normalized” over the years, leading to the belief that these minute failures could be expected. Therefore, they became accepted despite moving away from defined safety standards.^{2,5}

Diane Vaughan, in her exhaustive book “The Challenger Launch Decision,” coined the term “normalization of deviation.” This term refers to a gradual erosion of routine safety procedures that would not be tolerable if they occurred in a large single event.^{1-3,5} However, small deviations repeating over time could be identified and become tolerated in the absence of an adverse event and therefore become “normalized.”

This standardization of deviation is a violation of the procedures' safety and quality because it establishes a decaying process in the workflow that allows a more considerable tolerance to error. By these means, personnel involved accepted higher risks, sometimes only to comply with faster administrative processes. This line of thought is a severe threat to the safety of those involved.^{1,4,6,7}

In medicine, procedures are highly complex and require very close interactions between each subsystem for the adequate performance of the entire system. As with the National Aeronautics and Space Administration, in health procedures, there is always the temptation to do more in less time. If we consider the associated risks for space shuttle flights until 2003, with 112 missions flown and only 2 with a catastrophic failure (Challenger and Columbia), there is a failure rate of 1.7%. If one considers the enormous impact of these two failures, and we do this in parallel to the effect on our patients, the potential damage is beyond measure.²

The term “normalization of deviation” has been explored in surgical procedures and anesthesia^{6,7}; however, there has not been a similar approach in radiology, despite the presence of procedures in which failures could potentially occur in this delicate conjunction of processes.

In recent years, there have been sporadic reports of venous airborne microbubbles (VAMB) detected in computed tomography (CT) of the thorax, which had no repercussions in the patient given the filtering process performed at the pulmonary arterial circulation and lung capillaries.⁸⁻¹¹ Nevertheless, patients with right-to-left cardiac shunts or pulmonary arteriovenous malformations are at higher risk

due to exogenous air emboli.^{11,12} In anesthesia, there are some reports of cases in which at more than 50 to 70 mL of VAMB, the risk of cardiopulmonary collapse by air embolism increases considerably.^{9,11}

Our analysis is that since air bubbles are an exogenous element that has no diagnostic role in the images, they should not be present at all during the contrast media's injection procedure. In routine studies, some minuscule air bubbles may be identified in CT angiography (CTA), more apparent in vascular studies of the thorax (the product of the route of injection in the upper limbs and early phase acquisition), and these bubbles do not generate a clinically manifest event. However, it is our opinion that we are dealing with an example of the normalization of deviation in radiology, since we are accepting small flaws in the study's procedure quality due to the observation that these do not produce an evident negative effect on patients.

The objective of this study is to identify evidence of normalization of deviation in images using chest CTA (CCTA) and VAMB identification as examples.

Materials and Methods

This study was approved by the institutional ethics committee and consisted of three phases: The first was a retrospective analysis of CCTA studies conducted over 6 months, determining the prevalence of VAMB in the venous and pulmonary arterial tree. This was followed by a reinforcement of safety techniques in the injection of intravenous contrast material, concluding with a reevaluation of the images at 30 days, 1 month, and 3 months after the educational intervention.

All CCTAs from our institution performed on a Siemens Definition AS and Toshiba Aquilion One CT scanner with Medrad Stellant Dual automatic injection equipment were reviewed during the period from June 1, 2015 to November 30, 2015, by a thoracic radiologist and a second-year radiology resident. The presence of VAMB in the venous segments visible in CCTA (the subclavian veins, brachiocephalic vein, and superior vena cava [SVC]) and the right atrium, right ventricle, and pulmonary artery were identified visually with an angiographic window setting (W: 700; L: 100). In those CCTAs in which air bubbles were identified, a volumetric measurement was performed using a region of interest (ROI) on the air bubble with a range between -1,000 UH and -200 UH using a semiautomatic method with the MiaLite plugin for OsiriX. Variables of age, sex, and origin of the study were tabulated.

Three months after the preliminary results, an intervention was performed to reinforce the already established measures for contrast medium administration: (1) install proper venous access, (2) adequately prime the tubing and contrast injector, and (3) complete the contrast media's correct installation, taking special care for not allowing air to enter the system.

At 1 month (March 2016) and 3 months (May 2016) following this intervention, we reviewed the studies performed for 30 days, repeating the measurements previously described.

After 6 months, a questionnaire was sent to all of our CT technicians, with questions regarding how many CCTAs they perform per week, an estimate on how many they identify VAMB, what is their impression on the inevitability of this occurring, and if they felt that VAMB might pose a health risk to the patient.

Qualitative characteristics among groups were compared using the chi-squared test and quantitative characteristics between the groups were compared using Student's *t*-test or Wilcoxon–Mann–Whitney tests depending on whether the normality requirement was achieved (using the Shapiro–Wilk test). A statistically significant difference was considered with $p < 0.05$, and 95% confidence intervals were calculated when appropriate.

Results

Of 602 CCTA scans analyzed in the first phase, 332 were of women (55.14%) with a median age of 58 years (interquartile range [IQR] 44–72). Of these, 100 examinations (16.11%) had a VAMB. There was no significant difference in the presence of VAMB regarding gender ($p = 0.31$), age ($p = 0.14$), or patient origin (emergency department [ED], inpatient, or outpatient) ($p = 0.31$).

In the examinations with VAMB, the request was made by the ED in 52% of cases, 22% were inpatients, and 26% were outpatients. A total of 81% of the cases were requested for suspected pulmonary thromboembolism.

The most common sites of VAMB visualization were the SVC (21.8%), the pulmonary artery (18.8%), and the right subclavian vein (14.8%). The average volume of air bubbles was 0.2 mL (range 0.01–3.4 mL). The larger VAMB were visualized in the brachiocephalic vein, and the volume corresponded to 3.4 mL (►Fig. 1). The smallest VAMB were observed in the pulmonary artery with 0.01 mL. In 88 cases, the air bubbles had a single location; in 10 cases, they were observed in two areas, and only 3 cases, the air bubbles were located in three or more locations.

After a month of the intervention of reinforcement for safety procedures in contrast media administration, VAMB presence was measured again. A total of 91 examinations were conducted, of which only three examinations had air bubbles, corresponding to 3.29% ($p < 0.001$), with the largest volume of a bubble being 0.5 mL, located in the right ventricle. Mean volume for air bubbles was 0.2 mL (range 0.03–0.5 mL). All patients came from the ED with clinical concern for pulmonary embolism; all were male, with a median age of 65 (IQR 31) (►Table 1).

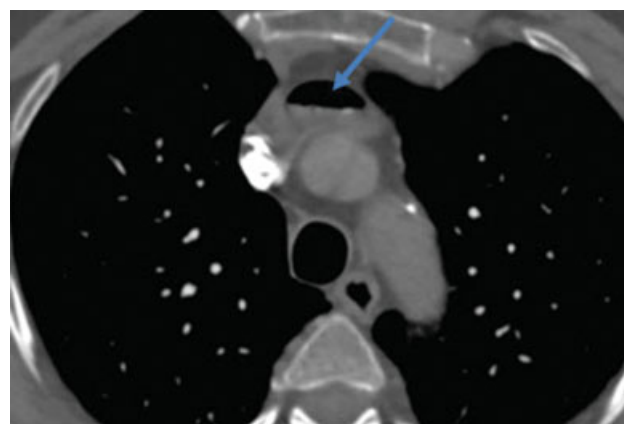


Fig. 1 Pulmonary computed tomography angiography (CTA) axial image. Presence of air bubble in the left brachiocephalic vein of 3.4 mL (yellow arrow).

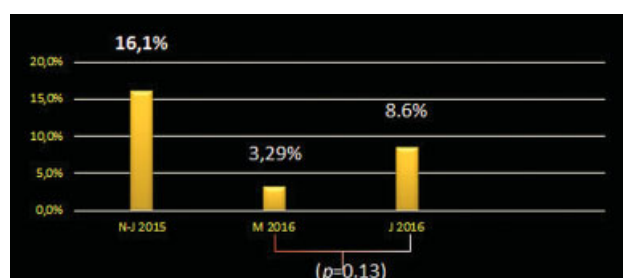


Fig. 2 Distribution of frequency of venous air microbubbles (VAMB) on basal measurement, and month 1 and 3.

At the 3-month measurement, there was a slight increase in the number of cases, and air bubbles were identified in 8 of 93 examinations (8.6%); however, this increase was not statistically significant ($p = 0.13$) (►Fig. 2).

On the 6-month questionnaire, we obtained that 66% of the CT technicians considered that VAMB are inevitable in CCTA.

Discussion

The normalization of deviation phenomenon reflects a human behavior of minimizing the importance of small protocol breaches when these violations do not significantly affect the result. Unfortunately, these marginal failures to comply lead to a relaxation of the rigorous behavior of minimizing

Table 1 Characteristics of patients with venous air microbubbles on basal, month 1 and month 3

Site of origin	Basal (100/601)	Month 1 (3/91)	Month 3 (8/93)
ED	52 (52%)	2 (67%)	4 (50%)
Inpatient	22 (22%)	1 (33%)	3 (37%)
Outpatient	26 (26%)	0	1 (13%)
Median age (IQR)	54 y (26)	65 y (31)	75 y (21)
Mean bubble volume (range)	0.2 mL (0.01–3.4)	0.2 mL (0.03–0.5)	0.1 mL (0.02–0.3)

Abbreviations: ED, emergency department; IQR, interquartile range.

and ideally suppressing the risks, and this may lead to an involuntary error of greater magnitude.

All CCTA studies at our institution require that the injection system for contrast media is primed completely to eliminate any air bubbles, thereby preventing them from entering the bloodstream. Our findings for VAMB are within the range of those previously described; in a previous study, VAMB after contrast administration were identified in 11 to 23% of patients.¹² In our first series, the number of VMBA were 16% and then after the reinforcement of measures to technologists they significantly decreased to 3%. This VMBA reduction supports that the fact that meticulous protocols and their constant supervision allows the minimization of VAMB events. There was a slight increase in the number of cases at 3 months (always with small volumes), but the increase was not statistically significant. This may reflect a developing tendency to relax; hence, it is very likely that periodic reinforcement of the strategy will be necessary.

Although the venous access in patients in the ED and general wards is installed by the respective service teams, the manipulation of the access for administration of contrast medium is the exclusive responsibility of the medical technologist performing the examination. When outpatient studies are performed, both the installation of the venous access and the administration of the contrast medium are performed in the radiology department by the technologist. Therefore, it is the responsibility of every radiology department to establish standards, monitor their compliance, measure their effects, and intervene when there is evidence of failures, even if such failures are marginal. In our processes, some procedures are required to be done at a higher speed, which can lead to a greater tolerance of minor protocol errors, thus accepting higher risks, sometimes only for complying with faster administrative processes. This line of thinking is a serious threat to the safety of those involved. Because of the demand for verification tests in which time and efficiency play fundamental roles, it is necessary to maintain the highest quality protocols to ensure the protection of patients.

Nevertheless, we must consider that the lung plays a vital filtering function for endogenous substances (such as lower extremity thrombi) and exogenous (VAMB). Therefore, the clinical repercussion is expected to be minimal or nonexistent; hence, this model is an excellent way to quantify this phenomenon and correct it before a catastrophic error occurs. In our series, we did not have immediate serious complications due to VAMB, but the anesthesia literature has reported cases where incidents with 50 to 70 mL of air in the venous territory were associated with a high risk of cardiorespiratory arrest due to air embolism.^{9,11}

This method of study is not restricted to CCTA and VAMB and may be also applicable to other CT studies.

Conclusion

VAMB are a frequent finding in CCTA, and although there are no immediate evident clinical repercussions and they do not

influence the image quality, they are susceptible to correction with an adequate manipulation of contrast media administration. Normalization of deviation is a phenomenon present in CT studies, and knowing this concept, we can intervene and optimize our procedures to make them safer for our patients.

Declaration of Patient Consent

The authors certify that they have obtained all appropriate patient consent forms. In the form the patient(s) has/have given his/her/their consent for his/her/their images and other clinical information to be reported in the journal. The patients understand that their names and initials will not be published and due efforts will be made to conceal their identity, but anonymity cannot be guaranteed.

Authors' Contributions

C.S. conceived and designed the study. C.S. and E.L. performed extensive research on the topic. C.S. and E.L. acquired the data, performed data extraction, and interpreted the data. C.S. performed the statistical analysis. C.S. and E.L. drafted, reviewed, and edited the manuscript.

Financial Support and Sponsorship

None.

Conflict of Interest

There are no conflicts of interest.

References

- Odom-Forren J. The normalization of deviance: a threat to patient safety. *J Perianesth Nurs* 2011;26(03):216–219
- Prielipp RC, Magro M, Morell RC, Brull SJ. The normalization of deviance: do we (un)knowingly accept doing the wrong thing? *Anesth Analg* 2010;110(05):1499–1502
- King CA. To err is human, to drift is normalization of deviance. *AORN J* 2010;91(02):284–286
- Banja J. The normalization of deviance in healthcare delivery. *Bus Horiz* 2010;53(02):139
- Vaughan D. *The Challenger Launch Decision: Risky Technology, Culture, and Deviance at NASA*. Chicago: University of Chicago Press; 1996:592
- McNamara SA. The normalization of deviance: what are the perioperative risks? *AORN J* 2011;93(06):796–801
- Groom R. Normalization of deviance: rocket science 101. *J Extra Corpor Technol* 2006;38(03):201–202
- Sodhi KS, Saxena AK, Chandrashekhar G, et al. Vascular air embolism after contrast administration on 64 row multiple detector computed tomography: a prospective analysis. *Lung India* 2015;32(03):216–219
- Jhamnani S, Panza JA. Power injector associated iatrogenic air embolism to the right heart. *Thorax* 2014;69(05):500
- Rubinstein D, Dangleis K, Damiano TR. Venous air emboli identified on head and neck CT scans. *J Comput Assist Tomogr* 1996;20(04):559–562
- Woodring JH, Fried AM. Nonfatal venous air embolism after contrast-enhanced CT. *Radiology* 1988;167(02):405–407
- Groell R, Schaffler GJ, Rienmueller R, Kern R. Vascular air embolism: location, frequency, and cause on electron-beam CT studies of the chest. *Radiology* 1997;202(02):459–462