



# Long term keratitis treatment with topical cyclosporin a in autoimmune polyglandular syndrome type 1

Omar AlAbbasi<sup>a,b</sup>, Moustafa S. Magliyah<sup>c,\*</sup>, Muhammad Ahad<sup>a</sup>

<sup>a</sup> Cornea and Anterior Segment Division, King Khaled Eye Specialist Hospital, Riyadh, Saudi Arabia

<sup>b</sup> Ophthalmology Department, Ohud Hospital, Madinah, Saudi Arabia

<sup>c</sup> Vitreoretinal Division, King Khaled Eye Specialist Hospital, Riyadh, Saudi Arabia

## ARTICLE INFO

### Keywords:

Cyclosporin a  
Autoimmune polyglandular syndrome  
APS1  
Autoimmune keratitis

## ABSTRACT

**Purpose:** To report long term results of two cases treated with topical cyclosporin A 1% for keratitis associated with autoimmune polyglandular syndrome (APS1).

**Observations:** A 25-year-old male and a 17-year-old female were referred from endocrinology as APS1-related autoimmune keratitis. Extended-duration treatment with topical cyclosporin A (CsA) 1% was used for 24 and 18 months, respectively. The first patient had improved best-corrected visual acuity (BCVA) from 20/200 and 20/300 in right and left eye to 20/60 in both eyes with markedly improved corneal opacification, while the second patient had improved BCVA from 20/400 and 20/300 in right and left eye to 20/160 in both eyes with persistent central stromal scarring in the right eye and discrete areas of stromal scarring in the left eye.

**Conclusions and Importance:** Long-term topical CsA 1% offers a valuable option for treatment of APS1-related autoimmune keratitis.

## 1. Introduction

Autoimmune polyglandular syndrome type 1 (APS1) is a rare autosomal recessive

Polyendocrinopathy which manifests the triad of mucocutaneous candidiasis, autoimmune destruction of endocrine glands, and ectodermal dystrophy.<sup>1</sup> It can be associated with multiple endocrine abnormalities such as hypoparathyroidism, Addison disease, hypothyroidism, and diabetes.

Ophthalmic manifestations of APS1 include keratoconjunctivitis, dry eye, iridocyclitis, cataract, retinal detachment, and optic atrophy.<sup>2</sup> Keratoconjunctivitis is the most common ophthalmic manifestation, occurring in 25%–50% of APS, and may develop prior to the onset of other systemic manifestations.<sup>2–4</sup>

Keratoconjunctivitis in APS1 is usually associated with photophobia, chronic ocular pain, blepharospasm, lacrimation, impairment of vision and can lead to stem cell deficiency.<sup>2,5</sup> It is thought that the cause of autoimmune keratoconjunctivitis in these patients is due to a defect in suppressor T-lymphocyte function.<sup>6</sup> It is reported that topical Cyclosporin A (CsA) plays its immunomodulatory role in the corneal surface by suppression of type 2 T helper lymphocytes (Th2) proliferation and activation.<sup>7,8</sup> We hypothesized that long term use of topical CsA 1% is

useful for treatment of keratitis associated with APS1.

## 2. Case report

### 2.1. Case 1

A 25-year-old male was referred by his endocrinologists to our cornea service as a case of an APS1 associated with progressively poor vision, photophobia, and burning sensation. He was using frequent lubrication. Systematic review revealed Addison disease, hypothyroidism and hypoparathyroidism for which he was taking cortisol, thyroid hormone replacement, calcium, and vitamin D. On examination, best-corrected visual acuity (BCVA) was 20/200 in the right eye and 20/300 in the left eye. Schirmer at 5 minutes without anesthetic was 6 mm in the right and 8 mm in the left. Intraocular pressure was 14 in both eyes. All 4 puncta were open. Corneal examination showed corneal limbal neovascularization, loss of palisades of Vogt, subepithelial/ anterior stromal fibrosis, diffuse epitheliopathy. Tear break up time test showed diffuse early disappearance of fluorescein from the whole corneal surface in both eyes. Dilated fundus examination showed a poor view secondary to the corneal opacity, but it was grossly normal (Fig. 1A and B).

\* Corresponding author. Vitreoretinal Division, King Khaled Eye Specialist Hospital, Al- Oruba Street, PO Box 7191 Riyadh, 11462, Saudi Arabia.

E-mail address: [mussam8@yahoo.com](mailto:mussam8@yahoo.com) (M.S. Magliyah).

<https://doi.org/10.1016/j.ajoc.2020.101009>

Received 7 July 2019; Received in revised form 4 October 2020; Accepted 30 December 2020

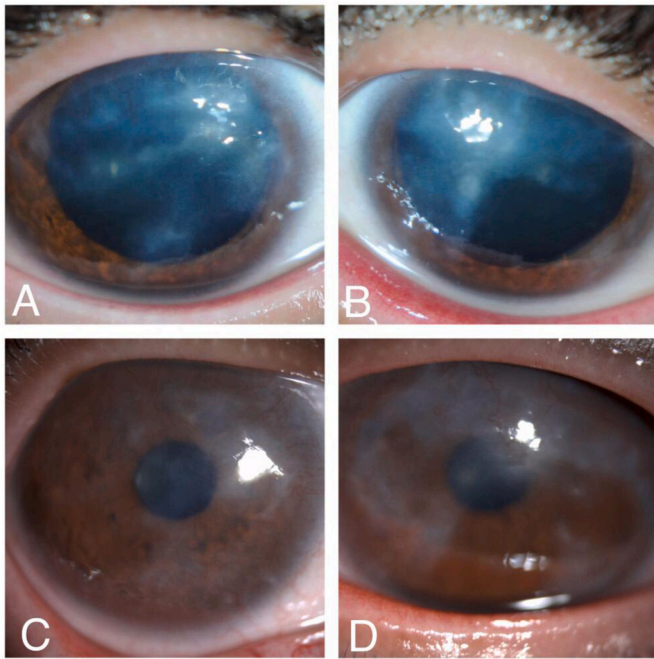
Available online 6 January 2021

2451-9936/© 2021 The Authors.

Published by Elsevier Inc.

This is an open access article under the CC BY-NC-ND license

(<http://creativecommons.org/licenses/by-nc-nd/4.0/>).



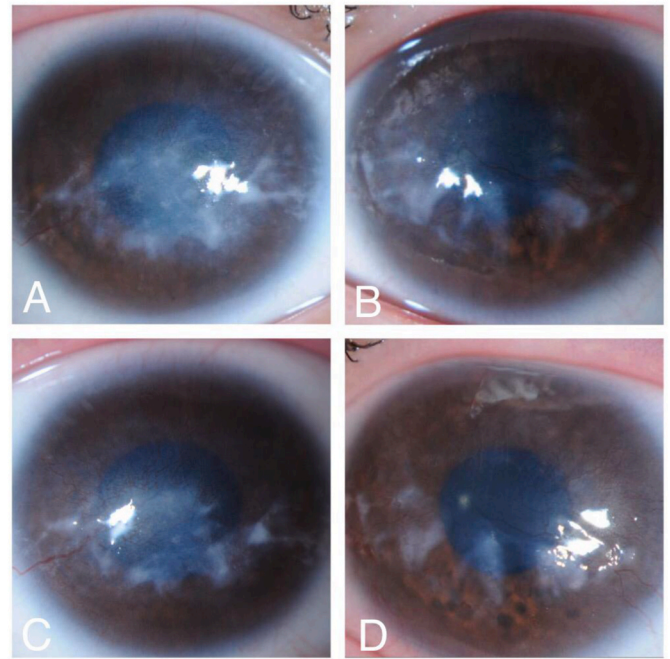
**Fig. 1.** Slit lamp anterior segment photos of a 25 years old male with Auto-immune polyglandular syndrome type 1 (APS1). A and B show extensive limbal neovascularization, subepithelial/anterior stromal fibrosis and diffuse epitheliopathy on presentation. C and D show essentially clear corneas with only mild stromal scarring and superior corneal vascularization after 24 months of topical Cyclosporin A (CsA) 1% treatment.

Punctal occlusion was done for dryness in both eyes. He was also started on CsA 1% four times a day and a 4-week course of loteprednol twice a day in both eyes. After 6 months, the patient was much more comfortable although clinical exam was largely unchanged. After 24 months, the BCVA improved to 20/60 in both eyes with significant improvement in degree of corneal stromal scarring and neovascularization (Fig. 1C and D).

## 2.2. Case2

A 17-year-old female was referred by her endocrinologists to our cornea service as a case of an APS1 associated with progressively poor vision, photophobia, and burning sensation. Systematic review revealed Addison disease, and hypoparathyroidism for which he was taking cortisol, calcium, and vitamin D. Her BCVA was 20/400 in the right eye and 20/300 in the left eye. Schirmer at 5 minutes without anesthetic was 12 mm in the right and 10 mm in the left. Intraocular pressure was 18.5 in both eyes. All 4 puncta were open. Corneal examination showed paracentral corneal opacification, extensive limbal neovascularization, loss of palisades of Vogt, subepithelial/anterior stromal fibrosis, diffuse epitheliopathy. Tear break up time test showed diffuse early disappearance of fluorescein from the center of the cornea. Dilated fundus examination showed a poor view secondary to the corneal opacity, but it was grossly normal (Fig. 2A and B).

He was also started on CsA 1% four times daily in both eyes with lubrication. After 6 months, the patient was much more comfortable although clinical exam was largely unchanged. After 18 months, the BCVA improved to 20/160 in both eyes with mild improvement in degree of corneal stromal scarring. Unfortunately there were persistent areas of central stromal scarring and temporal neovascularization OD and discrete areas of stromal scarring OS (Fig. 2C and D).



**Fig. 2.** Slit lamp anterior segment photos of a 17 years old female with APS1. A and B show paracentral corneal opacification, extensive limbal neovascularization, subepithelial/anterior stromal fibrosis and diffuse epitheliopathy on presentation. C and D show less stromal opacification in both eyes with persistent central stromal scarring and temporal corneal vascularization in the right eye and discrete areas of stromal scarring in the left eye after 18 months of topical CsA 1% treatment.

## 3. Discussion

Here we present two cases of APS1-related keratitis which were treated with topical CsA 1%. APS-1 is a condition that usually results from mutations in human autoimmune regulatory (*AIRE*) gene.<sup>9</sup> While the exact mechanism of keratitis in these patients is not well understood, it is thought that the *AIRE* gene has a role in negative selection and the deletion of autoreactive T cells during thymic maturation.<sup>10</sup> *AIRE* deficiency leads to infiltration of CD4<sup>+</sup> and CD8<sup>+</sup> T cells on the ocular surface and meibomian glands, which manifest as blepharitis and keratoconjunctivitis in patients with APS1<sup>10</sup>.

In patients with mild APS1-associated keratitis (punctate epitheliopathy and poor tear film), conservative management with over-the-counter lubricants and punctal occlusion is likely sufficient. Moderate-to-severe keratitis (diffuse epitheliopathy, sub-epithelial scarring, loss of limbal stem cells), however, requires more intensive management. Topical steroids, while effective and useful for a short-term relief at the beginning of the treatment course, can result in significant adverse events including susceptibility to infectious keratitis, elevated intraocular pressure with glaucomatous damage, and progression of cataracts when used for long durations. We believe that topical treatment with CsA 1% is a reasonable option for APS1-related autoimmune keratitis when used for 18–24 months. CsA belongs to the family of calcineurin inhibitors. CsA binds with great affinity to the cytosolic 17 kDa (kDa) cyclophilin-A, a family of cytoplasmic receptors present in most of the T-cells.<sup>11</sup> This drug-receptor complex specifically and competitively binds to calcineurin, leading to its inhibition.<sup>11,12</sup> Calcineurin inhibition suppresses dephosphorylation of the nuclear factor of activated T cells, which results in T lymphocytes inactivation.<sup>13,14</sup> Shah et al.<sup>15</sup> have also reported on use of CsA 1% in the management of APS-related keratitis. However CsA was only used for 3 months after which cadaveric limbal stem cell transplantation was performed. While this patient had significant clinical improvement, the post-operative immunosuppression

required after cadaveric limbal stem cell transplantation is significant and can interact with other systemic medications needed to manage APS-related endocrine disorders. Based on our experience, we recommend a longer trial of CsA 1% for APS1-related autoimmune keratitis. CsA1% differs from the commercially-available topical cyclosporin 0.05% (Restasis, Allergan, Dublin, Ireland) which is useful in chronic or immune-related eye dryness. CsA 1% is prepared by adding 4 ml of Carboxymethylcellulose sodium 0.5% (Refresh tears, Allergan, Dublin, Ireland) into 1 ml of CsA solution 50 mg/ml (Sandimmun, Novartis, Basel, Switzerland) to achieve the desired concentration without preservatives. The calculated cost of compounded CsA1% solution is higher than Restasis when used in the same frequency and for the same duration. In patients who show clinical improvement after 6 months of treatment, CsA1% drops are continued for 18–24 months. In cases which manifest recurrence of autoimmune keratitis within 3 months after cessation of treatment, another course of CsA 1% is recommended. In cases which show no response after the initial 6 months or develop recurrence of autoimmune keratitis more than 3 months after an 18–24 month treatment course with CsA1%, we believe topical tacrolimus is a useful second option. Long term use of topical tacrolimus was reported to be beneficial for APS1-related autoimmune keratitis.<sup>16</sup> Tacrolimus inhibits T cells by binding to FK506-binding proteins within T lymphocytes resulting in 100 times more potent calcineurin inhibition.<sup>17</sup> Topical tacrolimus is considered a useful option in keratoconjunctivitis cases not improved with topical cyclosporin with similar safety profiles.<sup>18</sup> In our patients, although symptomatic relief was achieved at short term, it was associated with progressive visual improvements in all treated eyes associated with improved corneal condition.

In conclusion, topical cyclosporin could be a good option for APS related keratitis and should be considered for long term use.

#### Patient consent

Written consents were obtained from all patients to publish their clinical details related to this study.

#### Funding

No funding or grant support

#### Authorship

All authors attest that they meet the current ICMJE criteria for Authorship.

#### Declaration of competing interest

The following authors have no financial disclosures: (insert initials of the authors who have nothing to disclose: OA, MM, MA.

#### Acknowledgements

None.

#### References

- Neufeld M, MacLaren N, Blizzard R. Autoimmune polyglandular syndromes. *Pediatr Ann*. 1980;9:154–162.
- Merenmies L, Tarkkanen A. Chronic bilateral keratitis in autoimmune polyendocrinopathy/candidiasis-ectodermal dystrophy (APECED). A long-term follow-up and visual prognosis. *Acta Ophthalmol Scand*. 2000;78:532–535.
- Gass JD. The syndrome of keratoconjunctivitis, superficial moniliasis, idiopathic hypoparathyroidism and Addison's disease. *Am J Ophthalmol*. 1962;54:660–674.
- Chang B, Brosnahan D, McCreery K, et al. Ocular complications of autoimmune polyendocrinopathy syndrome type 1. *J AAPOS*. 2006;10:515–520.
- Puangricharern V, Tseng SC. Cytologic evidence of corneal diseases with limbal stem cell deficiency. *Ophthalmology*. 1995;102:1476–1485.
- Wagman RD, Kazdan JJ, Kooh SW, et al. Keratitis associated with the multiple endocrine deficiency, autoimmune disease, and candidiasis syndrome. *Am J Ophthalmol*. 1987;103:569–575.
- Shii D, Nakagawa S, Shinomiya K, et al. Cyclosporin A eye drops inhibit fibrosis and inflammatory cell infiltration in murine type I allergic conjunctivitis without affecting the early-phase reaction. *Curr Eye Res*. 2009;34(6):426–437.
- Hingorani M, Calder VL, Buckley RJ, Lightman S. The immunomodulatory effect of topical cyclosporin A in atopic keratoconjunctivitis. *Invest Ophthalmol Vis Sci*. 1999;40(2):392–399.
- Nagamine K, Peterson P, Scott HS, et al. Positional cloning of the APECED gene. *Nat Genet*. 1997;17:393–398.
- Yeh S, de Paiva CS, Hwang CS, et al. Spontaneous T cell-mediated keratoconjunctivitis in Aire-deficient mice. *Br J Ophthalmol*. 2009;93:1260–1264.
- Matsuda S, Koyasu S. Mechanisms of action of cyclosporine. *Immunopharmacology*. 2000;47:119–125.
- Wiederrecht G, Lam E, Hung S, Martin M, Sigal N. The mechanism of action of FK-506 and cyclosporin A. *Ann N Y Acad Sci*. 2006;696:9–19.
- Sakuma S, Higashi Y, Sato N, et al. Tacrolimus suppressed the production of cytokines involved in atopic dermatitis by direct stimulation of human PBMC system. (Comparison with steroids). *Int Immunopharm*. 2001;1:1219–1226.
- Bonini S, Lambiase A, Sgrulletta R, et al. Allergic chronic inflammation of the ocular surface in vernal keratoconjunctivitis. *Curr Opin Allergy Clin Immunol*. 2003;3:381–387.
- Shah M, Holland E, Chan CC. Resolution of autoimmune polyglandular syndrome-associated keratopathy with keratolimbal stem cell transplantation: case report and historical literature review. *Cornea*. 2007;26(5):632–635.
- Shoughy SS, Tabbara KF. Topical tacrolimus solution in autoimmune polyglandular syndrome-1-associated keratitis. *Br J Ophthalmol*. 2017;101(9):1230–1233.
- Kino T, Hatanaka H, Hashimoto M, et al. FK-506, a novel immunosuppressant isolated from a Streptomyces. I. Fermentation, isolation, and physico-chemical and biological characteristics. *J Antibiot (Tokyo)*. 1987;40:1249–1255.
- Fukushima A, Ohashi Y, Ebihara N, et al. Therapeutic effects of 0.1% tacrolimus eye drops for refractory allergic ocular diseases with proliferative lesion or corneal involvement. *Br J Ophthalmol*. 2014;98(8):1023–1027.