

# Intraoperative conversion of artificial cervical disc replacement to anterior cervical discectomy and fusion for iatrogenic fracture

## A rare case report

Bei-yu Wang, MD, Ting-kui Wu, MD, Hao Liu, MD, PhD\*, Yu-xiao Deng, MD, Chen Ding, MD

### Abstract

**Rationale:** Artificial cervical disc replacement (ACDR) has been reported to be an effective and safe surgical treatment for cervical spondylosis. However, iatrogenic fracture during ACDR surgery has rarely been reported. Considering its infrequency, we report a rare clinical case, with the aim of sharing our experience and exploring when to convert ACDR to fusion intraoperatively.

**Patients concerns:** A 47-year-old woman felt neck pain with weakness and numbness in both upper limbs for 5 months.

**Diagnoses:** The patient had received discectomy and fusion procedure on C3/4 and C5/6 to relieve her radicular pain nearly 4 years prior. Neurologic examination revealed a diminished sensation at the C6–C8 skin areas and level Grade-4 power in the left wrist extensor and grip muscle strength. Magnetic resonance imaging (MRI) showed disc herniation compressing the spinal cord at C6/7. Computed tomography (CT) scans showed intervertebral fusion in both the C3/4 and C5/6 segments.

**Interventions:** Surgery was performed to remove the plate and replace C6/7 with an artificial disc, but a transverse cleavage endplate cortical fracture was detected after cutting the blades. Thus, we terminated artificial cervical disc replacement intraoperatively and changed to discectomy and fusion in C6/7.

**Outcomes:** The patient's symptoms were remarkably relieved. Postoperative CT scans showed a transverse cleavage fracture in the backside of the C6 caudal endplate. Good fusion was achieved after 6 months.

**Lessons:** Iatrogenic fracture during ACDR is rare but does occur in clinic practice. Complete examination and an alternative approach determined before surgery are important for operative safety. Anterior cervical discectomy and fusion (ACDF) is recommended as a feasible remedial surgical strategy if ACDR fails intraoperatively.

**Abbreviations:** ACDF = anterior cervical discectomy and fusion, ACDR = artificial cervical disc replacement, CT = computed tomography, MRI = magnetic resonance imaging.

**Keywords:** anterior cervical discectomy and fusion, artificial cervical disc replacement, convert, iatrogenic fracture

## 1. Introduction

As an anterior cervical nonfusion technique, artificial cervical disc replacement (ACDR) has been regarded as an effective and safe surgical alternative treatment to fusion; the protocol focuses on

stabilization, mobility, and safety during every procedural step. It also has stricter criteria and more essential in surgical technique requirements.<sup>[1]</sup> However, iatrogenic fracture during ACDR surgery has been infrequently reported. Furthermore, there have been rare studies regarding interoperative conversion of ACDR to fusion. Hererin, we report a rare clinical case, with an aim of sharing our experience and exploring when to convert ACDR to fusion intraoperatively and how to rationally revise the surgical procedure.

## 2. Case history

A 47-year-old female received anterior cervical discectomy and fusion (ACDF) in C3/4 and C5/6 for cervical spondylosis in 2011. The surgery effects were satisfactory, with postoperative symptoms relieved for nearly 4 years. Five months preceding the current surgery, the patient again began to feel neck pain again; her symptoms and signs were severe neck pain with weakness and numbness in both upper limbs.

Neurologic examination revealed a diminished sensation in the C6–C8 skin areas and level Grade-4 power in the left wrist extensor and grip muscle strength. Radiograph showed intervertebral fusion had been achieved at both C3/4 and C5/6. The long plate across 4 vertebral bodies was stable, though 1 loose screw

Editor: N/A.

This study is supported by the Application Base Research Program of the Department of Science and Technology in Sichuan Province, China (NO. 2016JY0055).

The authors have no conflicts of interest to disclose.

Department of Orthopaedic Surgery, West China Hospital, Sichuan University, Chengdu, Sichuan, China.

\* Correspondence: Hao Liu, Department of Orthopaedic Surgery, West China Hospital, Sichuan University, No. 37 Guo Xue Xiang, Chengdu, Sichuan 610041, China (e-mail: dr.liuhao6304@hotmail.com).

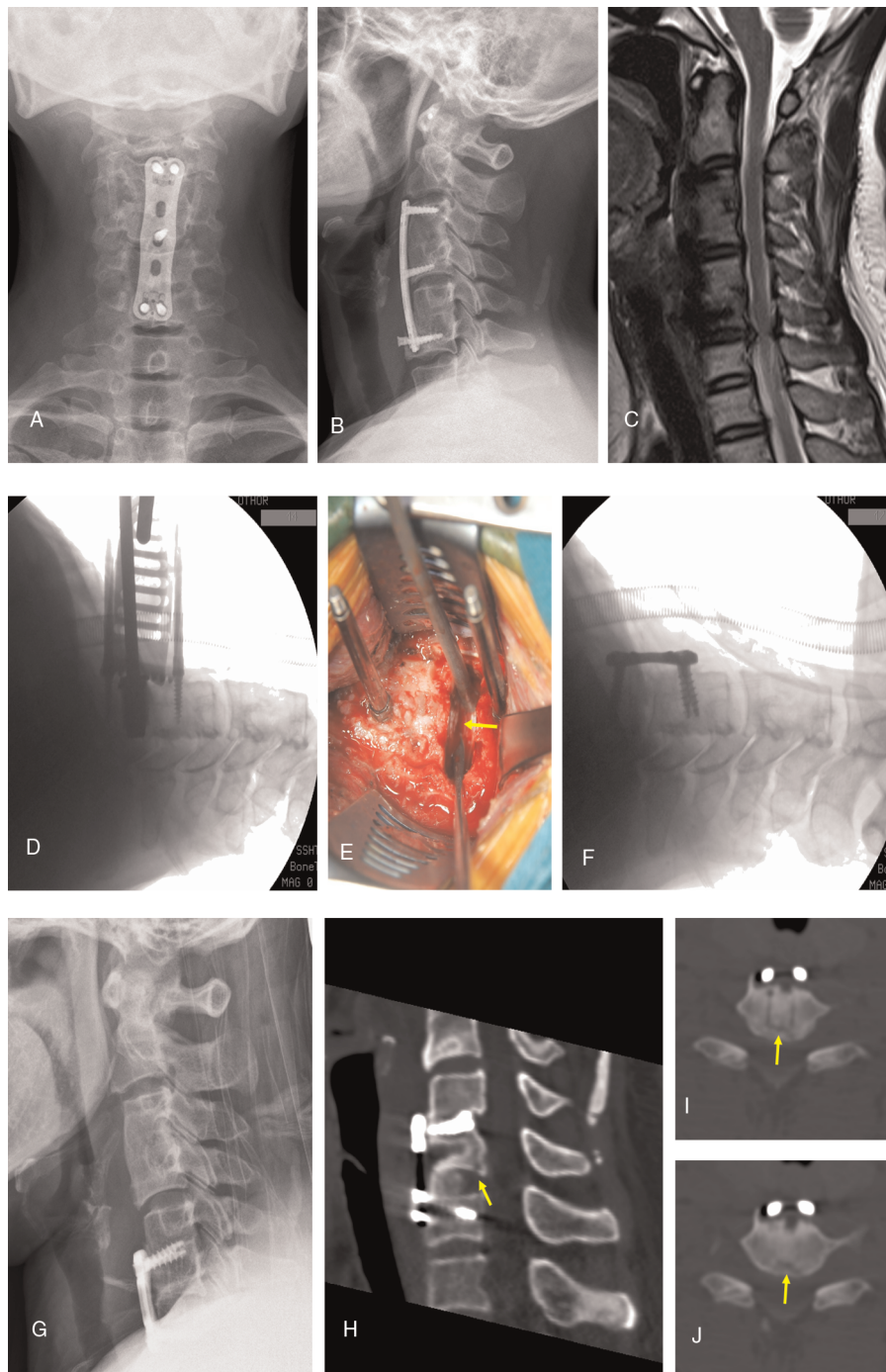
Copyright © 2017 the Author(s). Published by Wolters Kluwer Health, Inc. This is an open access article distributed under the Creative Commons Attribution-NoDerivatives License 4.0, which allows for redistribution, commercial and non-commercial, as long as it is passed along unchanged and in whole, with credit to the author.

Medicine (2017) 96:47(e8917)

Received: 24 September 2017 / Received in final form: 4 November 2017 /

Accepted: 7 November 2017

<http://dx.doi.org/10.1097/MD.0000000000008917>



**Figure 1.** A–C, Preoperative radiographs show C3/4 and C5/6 fused after the first fusion surgery 4 prior; the left caudal screw loosened, and there was a C6/7 disc herniation (D–F). Intraoperative radiographs and the picture show that the hook dissector detected a transverse cleavage cortical fracture at the back edge of the C6 caudal endplate (yellow arrow shows fracture line). F, Terminate arthroplasty was changed to a fusion intraoperatively (G–J). Postoperative radiograph and CT scans show that a transverse cleavage fracture line (yellow arrows) in the back edge of the C6 caudal endplate. CT = computed tomography.

was detected. Magnetic resonance imaging (MRI) showed disc herniation compressing the spinal cord at C6/7 (Fig. 1).

After general anesthesia was induced, the patient was placed in the neutral supine position with her shoulders and arms pulled caudally with wide tapes. A standard right-side anterior cervical approach was used. First, the long plate was removed, and then the endplates were prepared at C6/7 for artificial cervical disc prosthesis (Prestige-LP; Midtronic Sofamor Danek, Memphis, Tennessee). After the fixation channel was drilled in the

endplates, the surgeon found it different to tap the cutting blades of the rail punch to the expected depth. Therefore, the surgeon used increased force to tap the cutting blades to make channels at a sufficient depth at the posterior edge of the vertebrae. Nevertheless, after retracting the cutting blades, active bleeding was found at the backside of the C6 caudal endplate. A hooked dissector was used to detect a transverse cleavage cortical fracture in the endplate. Bone wax was used to stop the bleeding, and to insure surgical safety, the surgeon terminated

ACDR intraoperatively to perform ACDF at C6/7 (Fig. 1). Postoperatively, the patient's symptoms were remarkably relieved. Lateral radiography showed satisfactory device position. Postoperative computed tomography (CT) scans showed a transverse cleavage fracture at the backside of the C6 caudal endplate (Fig. 1).

The patient signed written informed consent, and the study protocol was approved by the Ethics Committee of West China Hospital of Sichuan University.

### 3. Discussion

Endplate integrity is essential for ACDR. Iatrogenic fracture may occur at step in the ACDR procedure. It has enormous potential risk of prosthesis migration and even spinal cord compression. This may not be easily discovered, and there is no consensus on how to handle the unpredictable occasion in which it is inappropriate to continue ACDR intraoperatively. This question still confounds many spinal surgeons. As such, we have described this case to illustrate a surgical strategy for dealing with circumstance in which we had originally planned to perform ACDR but had to revise our approach intraoperatively.

A tapping procedure leading to endplate fracture in Prestige-LP has rarely been reported. There are 2 types of artificial cervical disc prosthesis: cutting the endplate channel via tapping (e.g., Prestige-LP and ProDisc-C) and preparing the endplate without tapping (e.g., Bryan, Discover, and PCM).<sup>[2]</sup> A typical characteristic of cutting the endplate channel by tapping the prosthesis is the major crest, which is tightly embedded into bone channel of endplate to achieve immediate stability. This also helps in early functional training of the neck.

When preparing the endplate channels, surgeons usually use a small hammer with controlled, gentle tapping to protect the spinal cord. However, some patients with osteosclerosis or a nonstandard endplate structure require the surgeons to use more power for tapping. In this iatrogenic fracture case, the C6 caudal endplate had a larger arc vault than normal, which would bear more stress on the back edge of endplate. To accommodate the depth of the channels for inserting the prosthesis, reinforced tapping power facilitated the endplate fracture. However, if we had tapped the cutting blades lightly, it would have been more different to obtain adequate channel depth. In this case, the surgeon attempted to use more power to gain enough depth, contributing to the fracture. It can be difficult for, even a highly experienced surgeon to control tapping strength for different endplate types.

Hooked dissector detecting and checking repeated before prosthesis implantation was essential. Using prosthesis crests for fixation has been associated with vertebral fracture, especially when following procedures for cutting channels and inserting the prosthesis.<sup>[3]</sup> In our case, to assure adequate depth before inserting the prosthesis, we routinely used a hooked dissector to detect the depth of the back edge of the endplate. Because of this procedure, we were able to find an unexpected, active bleed and to quickly control the bleeding quickly using bone wax.

In addition, it is also sensible to prepare an alternative procedure before beginning the operation in case of unexpected intraoperative situations. In clinic practice, we routinely recommend ACDF as a standard standby surgical strategy. In this case, if ACDR had been continued, the patient might have suffered implant failure, migrations, prosthesis subsidence, or cervical spine instability; ultimately, the spinal injury may have resulted from fracture fragments.

There have been some reports of various reasons for revision surgery.<sup>[4]</sup> However, to our knowledge, no definite surgical indication for terminating ACDR intraoperatively has been reported. We propose several indications for terminating ACDR: severe disc space narrowing causing thorough decompression, anatomic deformity of the endplates that causes insufficient contact with the prosthesis, over-removal or milling of the endplates leading to unsuitable prosthesis for insertion, and fixation channels that are unsatisfied and difficult to revise.

In conclusion, our patient's symptoms were relieved, and there were no postoperative complications. Iatrogenic fracture during ACDR is rare but does occur in clinic practice. Complete examination and development of an alternative approach prior to surgery are important for operative safety. ACDF is recommended as a feasible remedial surgical strategy if ACDR fails intraoperatively.

### References

- [1] Wu T, Wang B, Ding C, et al. Artificial cervical disc replacement with the Prestige-LP prosthesis for the treatment of non-contiguous 2-level cervical degenerative disc disease: a minimum 24-month follow-up. *Clin Neurol Neurosurg* 2017;152:57–62.
- [2] Gornet MF, Burkus JK, Shaffrey ME, et al. Cervical disc arthroplasty with PRESTIGE LP disc versus anterior cervical discectomy and fusion: a prospective, multicenter investigational device exemption study. *J Neurosurg Spine* 2015;23:558–73.
- [3] Shim CS, Shin HD, Lee SH. Posterior avulsion fracture at adjacent vertebral body during cervical disc replacement with ProDisc-C: a case report. *J Spinal Disord Tech* 2007;20:468–72.
- [4] White AA 3rd, Panjabi MM. The basic kinematics of the human spine. A review of past and current knowledge. *Spine (Phila Pa 1976)* 1978;3:12–20.