

Augmentation Plate Fixation for Treating Subtrochanteric Fracture Nonunion

Abstract

Background: The treatment of subtrochanteric fracture nonunion is challenging. Although revision with either an intramedullary or extramedullary device had been advocated with acceptable results, complications that require secondary procedures still arise. The use of an intramedullary device with augmentation plate fixation is a well-known approach for femoral or tibial diaphyseal nonunion. However, this approach has not previously been reported for subtrochanteric fracture nonunion. **Materials and Methods:** A series of 21 cases of subtrochanteric fracture nonunion treated with an intramedullary device in combination with augmentation side plating were collected and retrospectively reviewed after an average of 18 months of followup. Fourteen patients with a prior well-fixed intramedullary device were treated with side plating and bone grafting. Seven patients underwent revision nailing in addition to side plating and bone grafting. **Results:** All fractures united well without major complication. The average time to union was 7.1 months. **Conclusion:** The use of an intramedullary device with augmentation plate fixation is a reliable and decisive procedure for treating subtrochanteric fracture nonunion that produces satisfactory results with a low complication rate.

Keywords: Intramedullary nail, nonunion, side plating, subtrochanteric fracture

Yu Cheng Lo,
Yu Ping Su¹,
Cheng Pu Hsieh,
Chun Hsiung Huang

Department of Orthopaedics
Surgery, Changhua Christian
Hospital, Changhua,

¹Department of Orthopaedics
and Traumatology, Veterans
General Hospital, Taipei,
Taiwan

Introduction

Subtrochanteric fractures account for 10% to 30% of all hip fractures.¹ This area of hip possesses unique mechanical and biological characteristics that render fracture union problematic. Mechanically, the proximal femur bears tremendous varus stress. Biologically, the proximal femur is largely composed of cortical bone, which achieves bony incorporation relatively slowly.^{2,3} Thus, subtrochanteric fractures are more prone to nonunion than fractures in neighboring areas, such as the intertrochanteric region. Even when contemporary methods are used, the complication of nonunion nonetheless occurs in approximately 7%–20% of cases.⁴⁻⁷ Studies have shown that intramedullary devices can achieve higher union rates and fewer complications than extramedullary devices such as a blade plate.^{8,9} This phenomenon could be attributed to the closed nailing technique, which produces less soft tissue disruption and more favorable mechanical properties, including load sharing and a shorter lever arm, than the use of extramedullary devices.

The management of subtrochanteric fracture nonunion is more challenging than the treatment of a fresh fracture because of bone loss, retained broken implants, loss of reduction, and the compromised osteogenic potential of local tissue.¹⁰⁻¹² Over the past several years, the “diamond concept,” a comprehensive strategy of evaluation and management of fracture nonunion, has been introduced. This concept emphasizes the importance of an optimized mechanical environment and enhanced biological conditions for refractory or atrophic nonunion.¹³⁻¹⁵ Accordingly, the authors believe that rigid and durable fixation is required to create a stable environment for the healing of subtrochanteric fracture nonunion. Although an intramedullary device serves as a load-sharing fixator and provides higher resistance to failure, it can only provide relative stability at the metaphyseal-diaphyseal junction area. Lateral side plating at this location acts as a tension band device that provides compressive force and adds resistance to the varus load. The use of an intramedullary device with augmentation plate fixation is a well-known method for treating nonunion for diaphysis fractures of the femur and

Address for correspondence:

Dr. Yu Cheng Lo,
Department of Orthopaedics
Surgery, Changhua Christian
Hospital, No. 135, Nanhsiao
Street, Changhua 500, Taiwan.
E-mail: 150570@cch.org.tw

Access this article online

Website: www.ijoonline.com

DOI:
10.4103/ortho.IJOrtho_476_17

Quick Response Code:



How to cite this article: Lo YC, Su YP, Hsieh CP, Huang CH. Augmentation plate fixation for treating subtrochanteric fracture nonunion. Indian J Orthop 2019;53:246-50.

This is an open access journal, and articles are distributed under the terms of the Creative Commons Attribution-NonCommercial-ShareAlike 4.0 License, which allows others to remix, tweak, and build upon the work non-commercially, as long as appropriate credit is given and the new creations are licensed under the identical terms.

For reprints contact: reprints@medknow.com

tibia.¹⁶⁻¹⁸ However, to our knowledge, this approach has not been discussed for the treatment of subtrochanteric fracture nonunion. This study presents clinical results for a series of cases of subtrochanteric fracture nonunion treated with an intramedullary device with augmentation plate fixation and autogenous bone grafting.

Materials and Methods

21 consecutive cases of subtrochanteric fracture nonunion treated with intramedullary nailing and side plating by two surgeons (YCL and YPS) at a single tertiary referral center between 2009 and 2015 were included in this retrospective study [Table 1].

This study was approved by the relevant ethical committee. Patient informed consents were obtained. Skeletally mature patients with nonunion of a surgically treated subtrochanteric fracture were enrolled and reviewed. The subtrochanteric region was defined as the area 5 cm distal to the lower border of the lesser trochanter. Initial fracture patterns were classified with the AO/OTA classification.¹⁹ In accordance with the Food and Drug Administration's definition, nonunion was defined as a fracture that had not completely healed within 9 months or showed no progression toward healing on serial radiographs over 3 consecutive months.²⁰ Implant failure or loss of reduction at any time point was also regarded as nonunion. Cases involving a pathologic fracture, an atypical fracture, and/or septic nonunion were excluded from the study. In

addition, cases of nonunion treated with an extramedullary device or solely with exchanging nailing were excluded from the study.

These cases involved 14 males and 7 females. According to AO/OTA classification, there were 16 cases of AO/OTA 32A, 2 cases of 32B, and 3 cases of 32C for the initial fracture pattern. The mechanism of the initial injury was either low energy trauma, such as a simple fall, or high energy trauma, such as a motor vehicle collision. Patients' average age at presentation was 47.9 years (range 19–79 years). Two patients are current smoker and refused to quit smoking. Three patients have type II diabetes mellitus well controlled by oral hypoglycemic agents. No patient has the evidence of metabolic bone disease. The average time that had elapsed from initial surgery to the relevant revision surgery was 13.3 months (range 9–31 months). The average followup time was 18.2 months (range 6–32 months). There were 8 cases of oligotrophic nonunion and 13 cases of atrophic nonunion according to the Weber and Cech classification.²¹ There was no evidence of infection at the time of the index operation. Initial fixators included a dynamic hip screw (Synthes, Paoli, PA, USA), a Gamma nail (Howmedica/Osteonics, Mahwah, NJ, USA), a proximal femoral nail (PFN) (Synthes), and an antegrade interlocking nail (Synthes), which were used in two, seven, four, and eight patients, respectively. Among the eight patients treated with antegrade interlocking nails with piriformis fossa starting point, all had an appropriate

Table 1: Patient demographics

Case	Age (years)/gender	Prior fixations	Nonunion type	Time elapsed (months)	Treatment	Time to union (months)	Complications
1	35/male	Gamma nail	Atrophic	12	DCP	10	Superficial infection
2	68/male	ILN	Oligotrophic	12	DCP	6	
3	70/male	Gamma nail	Oligotrophic	17	DCP, nail	4.5	
4	65/female	Gamma nail	Atrophic	9	DCP	9.5	Superficial infection
5	27/female	PFN	Atrophic	10	DCP	5	
6	54/male	PFN	Atrophic	10	DCP	17	
7	45/male	DHS	Atrophic	7	DCP, nail	8	
8	79/male	Gamma nail	Atrophic	11	DCP	18	Superficial infection
9	72/female	DHS	Atrophic	25	DCP, nail	6	Trochanteric bursitis
10	72/female	Gamma nail	Atrophic	9	DCP	7	
11	63/female	PFN	Oligotrophic	14	DCP, nail	6	
12	26/female	ILN	Atrophic	31	DCP, nail	5	
13	39/male	Gamma nail	Oligotrophic	9	DCP	6	
14	38/male	ILN	Atrophic	20	DCP, nail	5	
15	31/male	ILN	Oligotrophic	9	DCP	6	
16	19/male	PFN	Atrophic	4	DCP, nail	3	
17	43/male	ILN	Atrophic	9	DCP	4.5	
18	22/male	Gamma nail	Atrophic	9	DCP	6	
19	24/male	ILN	Oligotrophic	12	DCP	6	
20	59/male	ILN	Oligotrophic	32	DCP	6	
21	56/female	ILN	Oligotrophic	10	DCP	5	
Average	47.9			13.3		7.1	

ILN=Antegrade interlocking nail, PFN=Proximal femoral nail, DCP=Dynamic compression plate, DHS=Dynamic hip screw

starting point. The other 11 patients were treated with Gamma nails or PFNs with greater trochanter starting point. Five of them were deemed with starting point too lateral. The initial surgeries were performed by different surgeons, and some patients were referred from other hospitals. Nine patients had undergone >1 salvage treatments before the index surgery.

Implant failure was present in 7 of the 21 patients, and failed implants were removed during revision surgery and revised with an intramedullary device; in particular, a Zimmer CM nail (Zimmer, Warsaw, NJ, USA) and a PFN (Synthes) were used for two and five patients, respectively. The initial intramedullary device was maintained for the remaining 14 patients.

The revision surgery involved the following steps.

Patients were placed in the lateral decubitus position on a radiolucent table that allowed for fluoroscopic examination. An incision was made as a direct lateral approach to the proximal femur. If necessary, this incision was incorporated into a previous incision. Prior intramedullary devices that were well fixed, well positioned, and acceptably aligned were maintained. In cases involving broken or loosened implants or extramedullary devices, the original implants were completely removed. The nonunion site was debrided thoroughly and recanalized through both ends using a flexible reamer or drill. Intramedullary nailing was performed. A 4.5-mm dynamic compression plate (DCP) (Synthes) was then contoured and placed on the lateral side, and distal locking screws were inserted using a free-hand technique.

Original intramedullary devices were left *in situ* when their alignment and positioning were acceptable. Debridement and decortication were performed around the nonunion site as extensively as possible. A 4.5 mm DCP was then applied directly on the lateral side. To facilitate compression at the nonunion site, the static distal locking screw of the nail was removed before the side plate was attached. At least one distal static locking screw was then inserted.

A copious autogenous bone graft harvested from the iliac crest was applied to the nonunion site at the end of surgery. Postoperatively, patients were encouraged to ambulate with partial weight bearing on the repaired hip for the first 4 weeks. All patients were regularly followed, and union was judged based on painless ambulation and the presence of a bridging callus on both anteroposterior and lateral radiography. Each film was read by two authors.

Results

All patients achieved clinical and radiographic union. The mean union time was 7.1 months (range 4–18 months). Fifteen patients achieved union within 6 months. Four patients achieved union between 6 and 12 months. Two patients achieved union after 1 year without implant failure

[Figure 1]. Minor complications occurred in four patients; three patients experienced superficial wound infection that was managed successfully with local wound treatment alone and one patient experienced trochanteric bursitis that was managed conservatively. All patients ambulated independently at their most recent followup [Figure 2].

Discussion

The management of subtrochanteric fracture nonunion is difficult because of malalignment, bone loss, broken implants, and poor vascularity. Since Charnley and Zickel described successful management with revision nailing for subtrochanteric fracture nonunion, various methods to treat this complication have been advocated. However, there remains a lack of consensus regarding the best approach for this task.^{10,22}

Barquet *et al.* treated 26 patients with a long Gamma nail (Howmedica/Osteonics, Mahwah, NJ, USA) and the selective use of bone grafts; healing was ultimately observed for 25 of these patients, with a mean healing time of 7 months.²³ These authors claimed that a long period of protected weight bearing is necessary following fixation with an extramedullary device; this requirement would be difficult or even impossible for elderly patients. In contrast, intramedullary devices have biomechanical advantages relative to plates, including a short lever arm, a lower bending moment, and load-sharing characteristics. These advantages allow for early full weight bearing, which is beneficial for elderly patients. However, in the series examined by Barquet *et al.*, five patients received secondary interventions, including dynamization, bone grafting, and/or nail exchange, and three patients developed broken implants, which include two broken distal bolts and one broken nail. In contrast, no broken implants were observed in our study. The high durability of intramedullary devices with augmentation plate fixation is reflected by two cases in our study for which no implant breakage or loosening occurred despite the fact that >1 year was required to achieve union.

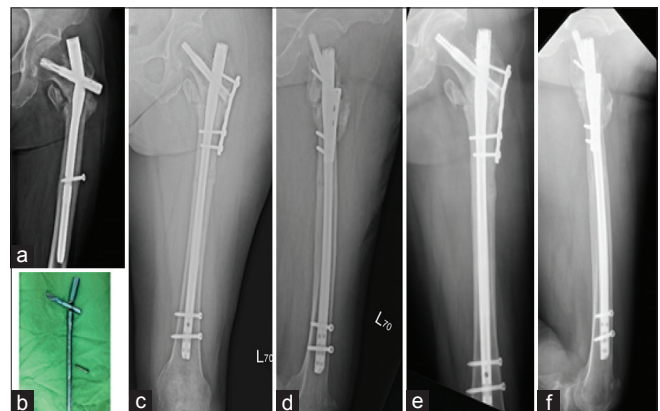


Figure 1: A 63-year-old female patient with subtrochanteric fracture nonunion and nail breakage 14 months after initial surgery (a and b). Revision with CM nail (Zimmer) and side plate, immediate postoperatively (c and d). Healed uneventfully 6 months later (e and f)

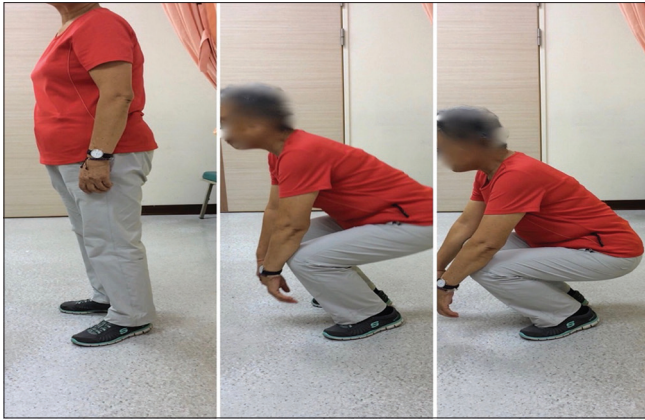

Figure 2: Patient presented in Figure 1, six months after revision surgery. She is able to stand upright with full weight bearing and to do full squat at that time

de Vries *et al.* treated 33 cases of subtrochanteric nonunion in 32 patients with blade plates and the selective use of bone grafts; eventual union was observed in 32 cases, with an average time to union of 5 months.²⁴ These researchers suggested that alignment correction and fracture site compression are more feasible with plating than nailing. Nine of the 32 patients experienced a complication after the index operation; the observed complications included blade tip protrusion and implant breakage. Due to these complications, five patients required reintervention. In contrast, in our study, no patient underwent a secondary intervention, and no major complications were observed. Haidukewych and Berry reported a similar union rate between extramedullary plating and intramedullary nailing.²⁵ In their series, 21 subtrochanteric fracture nonunions were treated with open reduction and internal fixation with a cephalomedullary nail, a standard antegrade interlocking nail, 95° blade plate, or sliding hip screws. Twenty of the 21 cases of nonunion healed and there was no difference between using intramedullary or extramedullary device. No details regarding union time or secondary interventions were discussed.

Exchanging nail alone has been shown to be a successful method for treating nonunion of the femur. However, the location of nonunion has been shown to be related to the success rate of exchanging nail. Yang *et al.* performed a retrospective review of 41 patients with aseptic femoral nonunion that was treated by exchanging nail.²⁶ Union was achieved in 87% of patients with isthmus nonunion compared with 50% only with nonisthmus nonunion.

Park *et al.* compared the augmentation plating with exchange nailing for nonisthmus femoral nonunion.²⁷ Five of the seven cases of nonunion who were treated by exchange nailing failed to achieve union. In contrast, all 11 cases of nonunions who were treated with augmentation plating achieved union. The enlargement of the medullary canal at the metaphyseal and meta-diaphyseal areas resulted in a size mismatch between the diameter of the medullary canal and the nail. A lack of a secure fit can

result in instability, particularly rotational instability, which is strongly related to failed intramedullary nailing. The authors believed that nonunion of the subtrochanteric area bears similar characteristic of the nonisthmus femoral nonunion. Isolated exchange nailing might not be sufficient enough despite better refixation.

Augmentation side plating has been reported for femoral and tibial diaphysis nonunion after nailing. Ueng *et al.* used the addition of a side plate to treat 12 cases of tibial aseptic nonunion after nailing.¹⁶ Autogenous bone grafting was only used in one patient with atrophic nonunion. All cases of nonunion healed uneventfully in 4 to 8 months and no complications were observed. Chen *et al.* reported 50 cases of femoral shaft aseptic nonunion after interlocking nailing who were treated with side plating.¹⁷ Autogenous bone grafting was performed in all cases, including 13 cases of hypertrophic nonunion. Union was achieved within 6 months for all cases of nonunion. Birjandinejad *et al.* used side plating and selected bone grafting to treat 38 cases of aseptic tibial and femoral aseptic nonunion after nailing.¹⁸ Union was achieved in all but two cases of tibial nonunion in an average of 4.7 months.

Although routine grafting is not recommended, especially when hypertrophic nonunion is impressed, we apply a low threshold for grafting. Most cases of subtrochanteric nonunion are oligotrophic or atrophic, but the discovery of an “anisotropic” condition in this area where a hypertrophic callus and sequestered cortex coexist is not uncommon. In this scenario, the use of autogenous bone grafting is a reasonable approach for securing a chance of union. Over one third of patients in our series had undergone multiple surgeries before the procedures described here; thus, a decisive operation was significant for such patients. We suggested routine bone grafting.

Intramedullary nailing with augmentation plate fixation has advantages associated with both the nail and the plate. This approach provides a rigid rotation and axial construct that can provide a stable and durable mechanical environment for nonunion to heal. Careful preoperative planning can ensure that secure lag screw purchase can still be achieved in revision surgery.

The limitations of this study include its retrospective and single-center study design; the lack of a comparison group; and the inclusion of a small number of cases due to the relative rarity of the examined surgical entity. Furthermore, our group consists of patients from broad range of age (range 19–79 years); with different comorbidities and initial injury mechanisms. All of them can possibly have influence on fracture healing. In the future, patients consist of similar age; comorbidity and injury mechanism would be desired.

Poor initial fixation can definitely lead to nonunion, and this can further bear some impact on the subsequent

management. However, the impact is beyond the scope of this study.

The virtues of side plating could not be differentiated from routine autogenous bone grafting based on this study design. However, they both delivered positive result to the successful union from the point of view of the authors.

The ideal treatment for subtrochanteric fracture nonunion has not yet been determined. Individualized treatment is advised, and various fixation methods have been proposed. Our study suggests that the use of a combination of an intramedullary device, augmentation side plating, and autogenous bone grafting is a reliable approach for treating subtrochanteric fracture nonunion without major complication

Declaration of patient consent

The authors certify that they have obtained all appropriate patient consent forms. In the form, the patients have given their consent for images and other clinical information to be reported in the journal. The patients understand that their names and initials will not be published and due efforts will be made to conceal their identity, but anonymity cannot be guaranteed.

Financial support and sponsorship

Nil.

Conflicts of interest

There are no conflicts of interest.

References

- Loizou CL, McNamara I, Ahmed K, Pryor GA, Parker MJ. Classification of subtrochanteric femoral fractures. *Injury* 2010;41:739-45.
- Melis GC, Chiarolini B, Tolu S. Surgical treatment of subtrochanteric fractures of the femur: Biomechanical aspects. *Ital J Orthop Traumatol* 1979;5:163-86.
- Maquet P, Pelzer-Bawin G. Mechanical analysis of inter- and subtrochanteric fractures of the femur. *Acta Orthop Belg* 1980;46:823-8.
- Kinast C, Bolhofner BR, Mast JW, Ganz R. Subtrochanteric fractures of the femur. Results of treatment with the 95 degrees condylar blade-plate. *Clin Orthop Relat Res* 1989;238:122-30.
- Sanders R, Regazzoni P. Treatment of subtrochanteric femur fractures using the dynamic condylar screw. *J Orthop Trauma* 1989;3:206-13.
- Sims SH. Subtrochanteric femur fractures. *Orthop Clin North Am* 2002;33:113-26, viii.
- Wiss DA, Brien WW. Subtrochanteric fractures of the femur. Results of treatment by interlocking nailing. *Clin Orthop Relat Res* 1992;283:231-6.
- Forward DP, Doro CJ, O'Toole RV, Kim H, Floyd JC, Sciadini MF, *et al.* A biomechanical comparison of a locking plate, a nail, and a 95° angled blade plate for fixation of subtrochanteric femoral fractures. *J Orthop Trauma* 2012;26:334-40.
- Kuzyk PR, Bhandari M, McKee MD, Russell TA, Schemitsch EH. Intramedullary versus extramedullary fixation for subtrochanteric femur fractures. *J Orthop Trauma* 2009;23:465-70.
- Charnley GJ, Ward AJ. Reconstruction femoral nailing for nonunion of subtrochanteric fracture: A revision technique following dynamic condylar screw failure. *IntOrthop* 1996;20:55-7.
- Marti R, Raaymakers EL, Nolte P, Besselaar PP. Pseudarthrosis of the proximal femur. *Orthopade* 1996;25:454-62.
- Rockwood CA, Green DP, Bucholz RW. *Rockwood and Green's Fractures in Adults*. 7th ed. Philadelphia (PA): Wolters Kluwer Health/Lippincott Williams & Wilkins; 2010.
- Giannoudis PV, Ahmad MA, Mineo GV, Tosounidis TI, Calori GM, Kanakaris NK, *et al.* Subtrochanteric fracture nonunions with implant failure managed with the "Diamond" concept. *Injury* 2013;44 Suppl 1:S76-81.
- Giannoudis PV, Einhorn TA, Marsh D. Fracture healing: The diamond concept. *Injury* 2007;38 Suppl 4:S3-6.
- Giannoudis PV, Einhorn TA, Schmidmaier G, Marsh D. The diamond concept – Open questions. *Injury* 2008;39 Suppl 2:S5-8.
- Ueng SW, Liu HT, Wang IC. Augmentation plate fixation for the management of tibial nonunion after intramedullary nailing. *J Trauma* 2002;53:588-92.
- Chen CM, Su YP, Hung SH, Lin CL, Chiu FY. Dynamic compression plate and cancellous bone graft for aseptic nonunion after intramedullary nailing of femoral fracture. *Orthopedics* 2010;33:393.
- Birjandinejad A, Ebrahimzadeh MH, Ahmadzadeh-Chabock H. Augmentation plate fixation for the treatment of femoral and tibial nonunion after intramedullary nailing. *Orthopedics* 2009;32:409.
- Fracture and dislocation compendium. Orthopaedic trauma association committee for coding and classification. *J Orthop Trauma* 1996;10 Suppl 1:v-ix, 1-154.
- Canale ST, Beaty JH. *Campbell's Operative Orthopaedics*. 12th ed. St. Louis (Mo): Mosby; 2012.
- Weber B, Cech O. *Pseudarthrosis: Pathology, Biomechanics, Therapy, Results*. Berne, Switzerland: Hans Huber Publishers; 1976.
- Zickel RE. Nonunions of fractures of the proximal and distal thirds of the shaft of the femur. *Instr Course Lect* 1988;37:173-9.
- Barquet A, Mayora G, Fregeiro J, López L, Rienzi D, Francescoli L, *et al.* The treatment of subtrochanteric nonunions with the long gamma nail: Twenty six patients with a minimum 2-year followup. *J Orthop Trauma* 2004;18:346-53.
- de Vries JS, Kloen P, Borens O, Marti RK, Helfet DL. Treatment of subtrochanteric nonunions. *Injury* 2006;37:203-11.
- Haidukewych GJ, Berry DJ. Nonunion of fractures of the subtrochanteric region of the femur. *Clin Orthop Relat Res* 2004;419:185-8.
- Yang KH, Kim JR, Park J. Nonisthmal femoral shaft nonunion as a risk factor for exchange nailing failure. *J Trauma Acute Care Surg* 2012;72:E60-4.
- Park J, Kim SG, Yoon HK, Yang KH. The treatment of nonisthmal femoral shaft nonunions with im nail exchange versus augmentation plating. *J Orthop Trauma* 2010;24:89-94.