

Sternal Tuberculosis

Sachdeva R, Sachdeva S¹, Arora S²

Departments of TB and Respiratory Medicine and ¹Community Medicine, Pt. B.D. Sharma, PGIMS, Rohtak, ²Department of Anesthesia, Lady Harding Medical College, New Delhi, India

Address for correspondence:

Dr. Sandeep Sachdeva,
Department of Community
Medicine, Pt. B. D. Sharma, PGIMS,
Rohtak - 124 001, India.
E-mail: drsachdeva@hotmail.com

Abstract

Extra-pulmonary tuberculosis constitutes 15-20% of total tuberculosis (TB) case load in immuno-competent patients. Affliction of the skeletal system is rare with still rarer presentation of sternal osteomyelitis even in endemic countries. A patient with primary sternal TB presenting with multiple cutaneous sinuses over the anterior chest wall is being reported. A high element of suspicion is needed more so in resource limited setting for early diagnosis and treatment.

Keywords: Asia, Tuberculosis, Skeletal, Sternum,

Introduction

Sternum is one of the least common bones of the body to get infected. Sternal osteomyelitis accounts for less than 2% of cases of osteomyelitis.^[1] The diagnosis is usually made late during presentation with limited case reported in peer-reviewed journals in the literature search.^[2,3] A high element of suspicion is needed for diagnosis and institution of anti-tubercular treatment that can prevent complications.

Case Report

A 26-year-old male presented with a primary complaint of swelling and discharge in the upper part of sternum since last 6 months [Figure 1]. There was history of development of discharging sinus and fistula following pus aspiration from swelling. He also complained of intermittent fever, anorexia and weight loss of nearly 7 kg during last 6 months. There was no past history of Koch's. On examination, there was a discharging sinus in upper part of the sternum. Rest general physical and systemic examination was within normal limits. Routine blood investigations-complete blood count, kidney function test, liver function test, random blood sugar and serum electrolytes were within normal limits; hemoglobin was 11 g/dl; erythrocyte sedimentation rate-64 mm/h; Mantoux-15 mm × 15 mm; chest radiograph was normal; patient was non-reactive to HIV test; ultrasound chest revealed

two hypoechoic linear tracts communicating with skin; pus aspirate was positive for acid fast bacilli on Ziehl-Neelsen staining; Contrast enhanced computed tomography (CECT) of the thorax [Figures 2 and 3] showed peripherally enhancing hypodense collection seen in the subcutaneous plane with underlying irregularity of body of sternum-carries of sternum with few calcified lymph node noticed in paratracheal region; underlying lung parenchyma appeared normal. Patient was counseled and started on anti-tubercular therapy under directly observed therapy short course (DOTS) of alternate day regime prescribed under Revised National Tuberculosis Control Program, i.e., isoniazid (600 mg), rifampicin (450 mg), pyrazinamide (1500 mg) and ethambutol (1200 mg). The patient is under follow up and has improved clinically with afebrile status, weight gain, resolution of pus and healing of sinuses. It is planned to administer intermittent therapy under DOTS for 9 months.

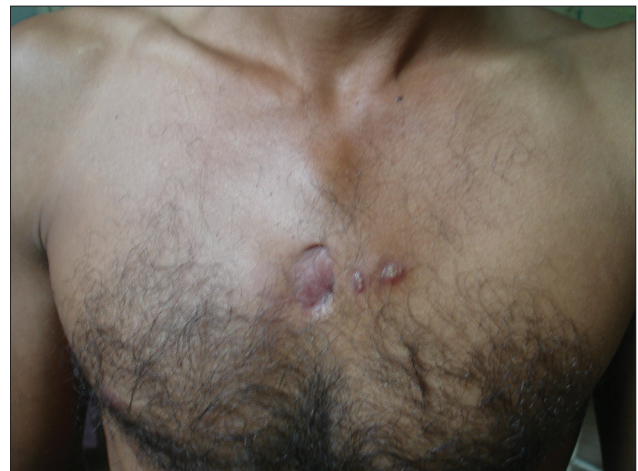

Figure 1: Young male with multiple cutaneous sinus and fistula over upper part of sternum

Access this article online

Quick Response Code:



Website: www.amhsr.org

DOI:
10.4103/2141-9248.121213

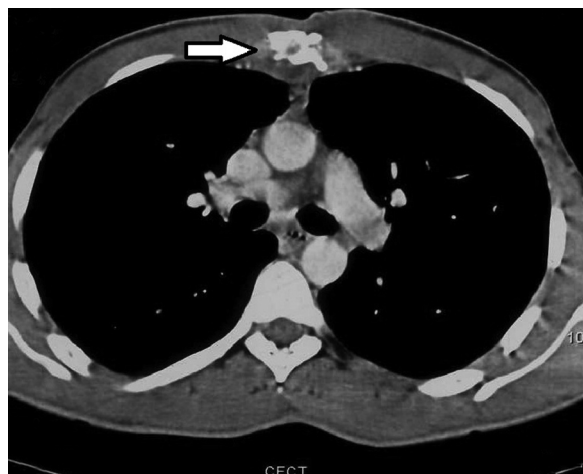

Figure 2: CECT thorax showing caries sternum (cross-sectional view)

Discussion

Tuberculosis (TB) can involve any organ system in the body. Pulmonary TB is the most common presentation while extra-pulmonary tuberculosis (EPTB) constitutes 15-20% of case load. Further, spine and hip are the most common sites affected under skeletal system.^[4] Sternum is resistant to infections and thus infrequent site of osteomyelitis. Pyogenic infections, especially due to staphylococcus are reported as the most common cause of sternal osteomyelitis. Involvement due to TB is rare even in endemic countries where the disease is extensive. India is the second-most populous country in the world with more new TB cases annually than any other country. According to most recent data of global annual incidence of 9.4 million TB cases, 2 million were estimated to have occurred in India, contributing to a fifth of the global burden of TB in the country. Notification of new EPTB under national program was 226,965 with a rate of 19/100,000 population during 2011.^[5] However due to various challenges and issues, true burden in absolute number could be still higher due to under-reporting.

Sternal TB is predominantly seen in middle aged adults although no age is immune and it has also been reported in an infant.^[6] It can arise primarily due to hematogenous route or direct extension from the hilar lymph nodes and/or could be due to lymphatic dissemination. Tubercular multiple cutaneous sinuses over the anterior chest wall may be a manifestation of TB of the internal mammary lymph nodes spreading along perforators or an extension of tubercular sternal osteomyelitis.^[7] In our patient, it seemed to be lymphatic spread as there was evidence of para-tracheal lymphadenopathy along with multiple cutaneous sinuses over the chest wall.

The computed tomography (CT) scan is more sensitive for anatomical localization and in detecting osseous destruction and soft-tissue abnormalities. Khalil *et al.* reviewed the utility of CT scan findings in the diagnosis of chest wall TB and described characteristic ring enhancing hypodense soft-tissue lesion.^[8] Atasoy *et al.* suggested the role of magnetic

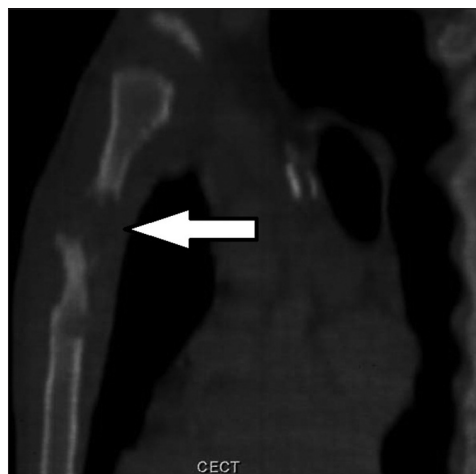


Figure 3: CECT thorax showing caries sternum (longitudinal view)

resonance imaging (MRI) for detecting early marrow and soft-tissue involvement due to high contrast resolution.^[9] TB osteomyelitis is characterized by low signal replacement of the normal marrow fat signal on T1-weighted images, with high signal intensities on T2-weighted images and enhancement on T1-weighted images.^[10]

Possible complications of sternal TB osteomyelitis include secondary infection, fistula formation, spontaneous fractures of the sternum, compression or erosion of the large blood vessels, compression of the trachea and migration of TB abscess into the mediastinum, pleural cavity or subcutaneous tissues.^[11] Diagnosis rests largely with the histological and microbiological examination of sternal tissue. Needle aspiration, as compared to surgical exploration, is less invasive and may represent the diagnostic procedure of first choice. Intermittent short course chemotherapy regimens of 6-9 months are recommended internationally for all forms of EPTB, which is usually paucibacillary in nature.^[12-14] Majority of authors are of the opinion that standard anti-tubercular chemotherapy is sufficient whereas some believe that surgical debridement with primary closure should be combined with extended chemotherapy up to 24 months to prevent recurrence.

Acknowledgments

Departments of TB and Respiratory Medicine and Radiology, Pt. B.D. Sharma, PGIMS, Rohtak.

References

1. Tuli SM. Tuberculosis of rare sites, girdle and flat bones. In: Tuli SM, editor. Tuberculosis of the Skeletal System. 2nd ed. Delhi: Jaypee Brothers Medical Publishers; 2000.
2. Vasa M, Ohikhuare C, Brickner L. Primary sternal tuberculosis osteomyelitis: A case report and discussion. Can J Infect Dis Med Microbiol 2009;20:e181-4.
3. Khaira A, Khaira DD, Gupta A, Bhowmik D, Kalra OP, Tiwari SC. Tuberculosis of sternum: Three cases with different presentations. J Assoc Physicians India 2009;57:595-6.

4. Sharma SK, Mohan A. Extrapulmonary tuberculosis. *Indian J Med Res* 2004;120:316-53.
5. TB India: Annual Status Report. Ministry of Health and Family Welfare, New Delhi: Government of India; 2012.
6. Kato Y, Horikawa Y, Nishimura Y, Shimoda H, Shigeto E, Ueda K. Sternal tuberculosis in a 9-month-old infant after BCG vaccination. *Acta Paediatr* 2000;89:1495-7.
7. Garg PK, Teckchandani N, Hadke NS. Sternal tuberculosis presenting as multiple cutaneous sinuses. *South Med J* 2008;101:303-4.
8. Khalil A, Le Breton C, Tassart M, Korzec J, Bigot J, Carette M. Utility of CT scan for the diagnosis of chest wall tuberculosis. *Eur Radiol* 1999;9:1638-42.
9. Atasoy C, Oztekin PS, Ozdemir N, Sak SD, Erden I, Akyar S. CT and MRI in tuberculous sternal osteomyelitis: A case report. *Clin Imaging* 2002;26:112-5.
10. Shah J, Patkar D, Parikh B, Parmar H, Varma R, Patankar T, *et al.* Tuberculosis of the sternum and clavicle: Imaging findings in 15 patients. *Skeletal Radiol* 2000;29:447-53.
11. Sharma S, Juneja M, Garg A. Primary tubercular osteomyelitis of the sternum. *Indian J Pediatr* 2005;72:709-10.
12. Wares F, Balasubramanian R, Mohan A, Sharma SK. Extrapulmonary tuberculosis: Management and control. In: *Tuberculosis Control in India*. New Delhi: Ministry of Health and Family Welfare; 2005. P: 95-114. Available from: <http://www.tbcindia.nic.in/. / tuberculosis%20control%20in%20india11.pdf>. [Last accessed 2012 Aug 4].
13. Bouchikh S, Stirnemann J, Prendki V, Porcher R, Kesthmand H, Morin AS, *et al.* Treatment duration of extra-pulmonary tuberculosis: 6 months or more? TB-INFO database analysis. *Rev Med Interne* 2012;33:665-71.
14. *Treatment of Tuberculosis: Guidelines*. Geneva: World Health Organization; 2010.

How to cite this article: Sachdeva R, Sachdeva S, Arora S. Sternal tuberculosis. *Ann Med Health Sci Res* 2013;3:S21-3.

Source of Support: Nil. **Conflict of Interest:** None declared.