

# Spontaneous massive hemopneumothorax: Double trouble with a twist

Milta Kuriakose, Arjun Khanna, Deepak Talwar

Metro Centre for Respiratory Diseases, Metro Multispecialty Hospital, Noida, Uttar Pradesh, India

## ABSTRACT

Spontaneous hemopneumothorax (SHP) is observed in 3%–7% cases of spontaneous pneumothorax where the tear of an adhesion can lead to bleeding with associated hemothorax. This condition has been reported in patients with hemophilia, sarcoidosis, congenital cystic adenomatoid malformation, systemic lupus erythematosus, etc., Here, we describe an unusual case of acute massive SHP in a 62-year-old male who underwent a percutaneous transluminal coronary angioplasty (PTCA) and presented with worsening dyspnea over the next 3 days. On evaluation, he had a massive hemopneumothorax which was considered to be secondary to the use of anticoagulants during the PTCA procedure. Pleural fluid analysis revealed frank blood and was consistent with the diagnosis of hemothorax. Surprisingly, the pleural fluid cytology revealed malignant cells. As the patient had a normal chest X-ray 3 days ago, thoracoscopic pleural biopsy was taken which confirmed the diagnosis of an epithelioid mesothelioma. Although post-PTCA or mesothelioma-associated hemothorax has been rarely reported, these two conditions have not been associated with SHP. Since the patient had no prior clinicoradiological features of mesothelioma, the procedure, and the anticoagulants probably contributed to the massive and rapid accumulation of blood. The presence of small amount of air added further confusion to the dual etiology and has not been described earlier.

**KEY WORDS:** Anticoagulants, hemopneumothorax, mesothelioma, percutaneous transluminal coronary angioplasty, thoracoscopy

**Address for correspondence:** Dr. Arjun Khanna, Division of Pulmonary and Critical Care Medicine, Metro Centre for Respiratory Diseases, Metro Multispecialty Hospital, Noida, Uttar Pradesh, India. E-mail: Doc.khanna@gmail.com

## INTRODUCTION

Spontaneous hemopneumothorax (SHP) has been defined as the accumulation of at least 400 mL of blood in the pleural cavity in association with spontaneous pneumothorax (SP).<sup>[1]</sup> SHP is attributed to the tearing of a vessel in an SP,<sup>[2]</sup> and pleural fluid hematocrit measurement is needed to distinguish it from blood stained effusions. It is also rarely reported in patients with SLE, sarcoidosis, cavitary lung metastasis, and bleeding diathesis.<sup>[3]</sup> Spontaneous hemothorax has been rarely reported postpercutaneous transluminal coronary

angioplasty (PTCA)<sup>[4]</sup> as well as in patients with pleural malignancy.<sup>[5]</sup> Malignant pleural mesothelioma usually presents with nonspecific chest symptoms, due to the presence of extensive intrathoracic disease for many months before diagnosis and is rarely asymptomatic<sup>[5]</sup> with occult disease diagnosed on decorticated pleural biopsies in SP.<sup>[6]</sup> Our patient presented with acute spontaneous massive hemopneumothorax, postmyocardial infarction, and PTCA considered to be related to cardiac intervention and anticoagulation. However, malignant cells in pleural fluid cytology led to thoracoscopic pleural biopsy establishing the diagnosis of epithelioid mesothelioma.

This is an open access article distributed under the terms of the Creative Commons Attribution-NonCommercial-ShareAlike 3.0 License, which allows others to remix, tweak, and build upon the work non-commercially, as long as the author is credited and the new creations are licensed under the identical terms.

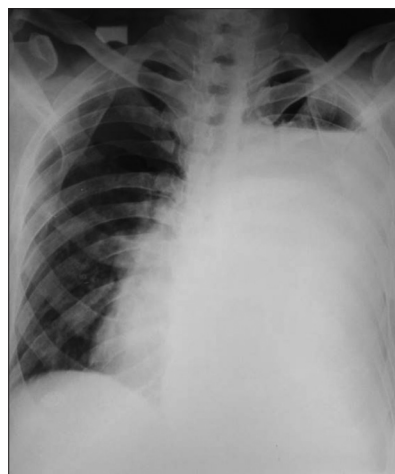
**For reprints contact:** reprints@medknow.com

**How to cite this article:** Kuriakose M, Khanna A, Talwar D. Spontaneous massive hemopneumothorax: Double trouble with a twist. Lung India 2017;34:283-6.

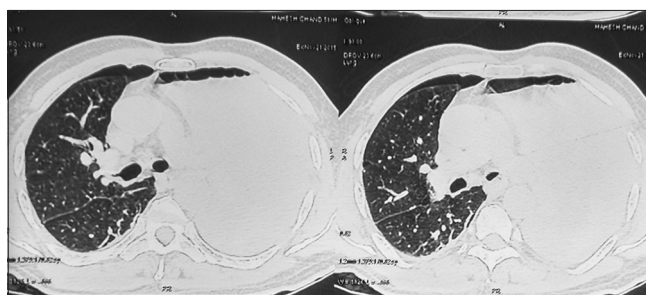
| Access this article online   |   |
|--|---|
| <b>Quick Response Code:</b><br> | <b>Website:</b><br>www.lungindia.com            |
|  | <b>DOI:</b><br>10.4103/lungindia.lungindia_6_16 |

## CASE REPORT

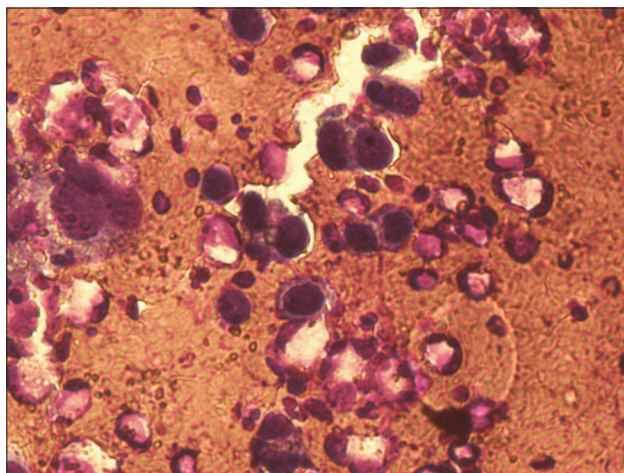
A 62-year-old male, chronic smoker, diabetic, and hypertensive had undergone PTCA for anterior wall myocardial infarction, 3 days before being referred to our center with worsening shortness of breath postprocedure. The patient presented to previous coronary care unit with acute myocardial infarction and underwent an uneventful emergency PTCA. The second day after the PTCA, the patient complained of rapidly worsening dyspnea, and the chest X-ray showed massive left-sided effusion with an air-fluid level suggestive of hydropneumothorax [Figure 1]. Pleural aspiration revealed bloody fluid, and he was shifted to our center after blood transfusion. On presentation, patient was in acute respiratory distress, with a respiratory rate of 36/min, blood pressure of 130/80 mmHg, and pulse of 130/min and oxygen saturation of 92% on 3 L/min of oxygen with nasal prongs. Routine blood tests revealed hemoglobin of 8 g/dl, total leukocyte count was 11000/mm<sup>3</sup> with polymorphonuclear leukocytosis, platelet counts were 2.2 lakhs/cumm. Blood urea was 32 mg/dl, and serum creatinine was 0.8 mg/dl. Serum bilirubin was 1.1 mg/dl, aspartate aminotransferase - 19 U/L, and alanine aminotransferase 23 U/L. Bleeding, clotting time, and prothrombin time were normal. Computed tomography (CT) chest revealed left-sided hydropneumothorax, with minimal thickening of the left-sided costal pleura and blood clots, with a very small right-sided pneumothorax, and basal pleural reaction with enlarged mediastinal lymph node in the sub carina [Figure 2]. There was no lung or pleural nodules anywhere. Semi-rigid thoracoscopic tube thoracostomy was done to drain the SHP and aspirate blood clots. Pleural fluid revealed frankly hemorrhagic exudative effusion with adenosine deaminase = 28 IU. The pleural fluid hematocrit was 27% compared to the blood hematocrit of 29.7%, establishing the diagnosis of hemothorax. Pleural fluid cytospin revealed the presence of malignant mesothelial cells [Figure 3]. Around 2 L of blood were removed from the pleural cavity, and clots were aspirated. Multiple pleural biopsies were taken from the normal appearing parietal pleura, which, on histopathological examination were suggestive of epithelioid mesothelioma [Figure 4]. The diagnosis was further confirmed by immunohistochemistry, which revealed that the tumor cells were positive for calretinin, WT1, CK5 6, and negative for TTF1, CK20, and carcinoembryonic antigen. Whole body positron emission tomography CT was done to stage the disease, which revealed mildly enhancing nodular left pleural thickening with increased fluorodeoxyglucose (FDG) uptake (SUV-4.5) involving mediastinal, costal, and diaphragmatic pleura along with FDG avid small lymph nodes in the left hilar and subcarinal (SUV-4.3) suggestive of metabolically active disease [Figure 5]. The patient underwent talc pleurodesis, after which the ICD tube was removed. We then planned for endobronchial ultrasound-guided transbronchial needle aspiration of the subcarinal node to adequately stage the disease but deferred as he developed left-sided hemiparesis as a result of an extensive acute



**Figure 1:** Chest X-ray showing massive left-sided hydropneumothorax



**Figure 2:** Computed tomography chest confirming the left-sided hydropneumothorax and confirming the right-sided pneumothorax

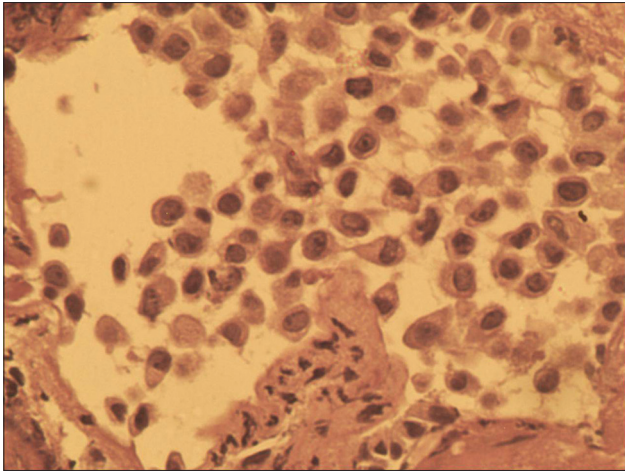


**Figure 3:** Pleural fluid cytospin demonstrating the malignant mesothelial cells

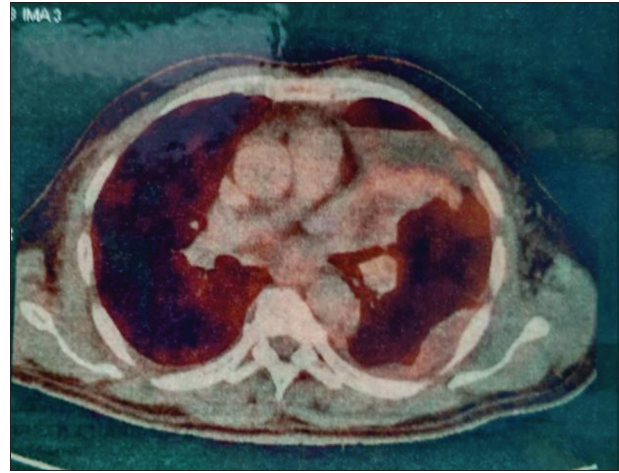infarct involving the right putamen and internal capsule. Although the mesothelioma was localized to the ipsilateral thoracic cavity, he was only offered supportive care in view of poor general condition and disabling stroke.

## DISCUSSION

Massive hemothorax and bilateral pneumothorax are mostly related to trauma and are rarely spontaneous.<sup>[7]</sup>



**Figure 4:** Histopathological examination of the pleural biopsy confirming the diagnosis of epithelioid mesothelioma



**Figure 5:** Fluorodeoxyglucose-positron emission tomography-computed tomography demonstrating fluorodeoxyglucose avid pleural disease without any lung mass, suggestive of mesothelioma

Bleeding may be massive as pleural vessels have systemic pressures and loss of tamponade effect of the collapsed lung. SHP has been reported most commonly in men of 20–60 years of age during the first episode of pneumothorax (80%–100%).<sup>[6]</sup> It presents clinically as unexplained shock or hypoxia, and chest roentgenogram remains the most useful investigation in the diagnosis of the condition. CT thorax is recommended in cases where the diagnosis of SHP is in doubt or to exclude neoplasia in hemodynamically stable patients before treatment. CT thorax done in our case showed blood clots in the pleural cavity, but no lesion in the lung parenchyma or pleura confirmed the hemopneumothorax and an occult pneumothorax on the right side.

Our patient had undergone a chest X-ray before the PTCA, which was normal and post-PTCA showed a large SHP that was considered to be secondary to postcoronary revascularization and anticoagulation. Mesothelioma presenting as SP has been reported in around 35 cases in literature, where mesothelioma was not suspected, as the pleura appeared normal on radiology. Surgical pleurectomy specimens demonstrated either mesothelioma mostly epithelioid or as mesothelial hyperplasia/nonspecific pleuritis, which were later diagnosed as mesotheliomas.<sup>[8]</sup>

However, SHP has not been reported so far with either of the two conditions as seen in our case. Since right pneumothorax was minimal, it required no treatment. Left-sided SHP required early treatment as untreated massive SHP carries high mortality. Fluid resuscitation with blood transfusions and correction of hemodynamics needs immediate attention. After stabilization either conservative management is continued or surgical intervention done, but there is no consensus regarding the optimal therapy. In general, conservative management is recommended if bleeding subsides within 24 h, and the patient remains hemodynamically stable after tube thoracostomy, which

is the initial treatment in all cases. Timing and type of surgery required are dependent on the expertise of the center. Video-assisted thoracoscopic surgery in SHP has demonstrated reduced need for delayed surgical exploration and decortication with favorable outcomes in hospital stay and morbidity.<sup>[9]</sup>

In our patient, we performed semi-rigid thoracoscopy, and chest tube insertion with pleural biopsy, triggered by malignant mesothelial cells seen in the pleural fluid. The patient had neither prior clinical, radiological, or thoracoscopic clues nor history of exposure to asbestos to raise the suspicion of mesothelioma. Our patient underwent talc pleurodesis as the drainage ceased in 24 h. Further, treatment could not be offered, due to the poor general condition of the patient.

This patient presented with two rare entities, the first being post-PTCA massive SHP and the other being incidental mesothelioma diagnosed by prudent evaluation of the pleural fluid, despite it being frank blood and appropriate use of thoracoscopy in guiding tube thoracostomy and taking multiple pleural biopsies of normal pleura as well. Although mesothelioma presenting as recurrent spontaneous hydropneumothorax with normal looking pleura has been reported;<sup>[10]</sup> however, we report SHP as the primary presentation of mesothelioma.

**Financial support and sponsorship**

Nil.

**Conflicts of interest**

There are no conflicts of interest.

**REFERENCES**

1. Ohmori K, Ohata M, Narata M. Twenty-eight cases of spontaneous hemopneumothorax. *Jpn Assoc Thorac Surg* 1988;36:1059-64.

2. Hsu NY, Shih CS, Hsu CP, Chen PR. Spontaneous hemopneumothorax revisited: Clinical approach and systemic review of the literature. *Ann Thorac Surg* 2005;80:1859-63.
3. Ng CS, Yim AP. Spontaneous hemopneumothorax. *Curr Opin Pulm Med* 2006;12:273-7.
4. Gunning MG, Williams IL, Jewitt DE, Shah AM, Wainwright RJ, Thomas MR. Coronary artery perforation during percutaneous intervention: Incidence and outcome. *Heart* 2002;88:495-8.
5. De Boer WA, Koolen MG, Roos CM, Ten Cate JW. Tranexamic acid treatment of hemothorax in two patients with malignant mesothelioma. *Chest* 1991;100:847-8.
6. Alkhuja S, Miller A, Mastellone AJ, Markowitz S. Malignant pleural mesothelioma presenting as spontaneous pneumothorax: A case series and review. *Am J Ind Med* 2000;38:219-23.
7. Ali HA, Lippmann M, Mundathaje U, Khaleeq G. Spontaneous hemothorax: A comprehensive review. *Chest* 2008;134:1056-65.
8. Yim AP, Ng CS. Thoracoscopy in the management of pneumothorax. *Curr Opin Pulm Med* 2001;7:210-4.
9. Hacıbrahimoglu G, Cansever L, Kocaturk CI, Aydogmus U, Bedirhan MA. Spontaneous hemopneumothorax: Is conservative treatment enough? *Thorac Cardiovasc Surg* 2005;53:240-2.
10. Guha K, Jones D, Hull JH, Ho TB. Recurrent hydropneumothorax as a presenting feature of malignant mesothelioma. *Eur J Intern Med* 2008;19:63-4.