

Malignant Peripheral Nerve Sheath Tumor in Neurofibromatosis Type I : Unusual Presentation of Intraabdominal or Intrathoracic Mass

Jong Gwang Kim, M.D., Woo Jin Sung, M.D., Dong Hwan Kim, M.D.,
Young Hwan Kim, M.D.², Sang Kyun Sohn, M.D. and Kyu Bo Lee, M.D.

*Departments of Oncology/Hematology and Diagnostic Radiology²,
Kyungpook National University Hospital, Daegu, Korea*

A malignant peripheral nerve sheath tumor (MPNST) is an extremely rare soft tissue tumor in the general population. On the other hand, there is a higher incidence of MPNST in patients with neurofibromatosis type I (von Recklinghausen's disease). The common sites are the extremities, trunk, head and neck. However, an intraabdominal or intrathoracic manifestation is uncommon. This paper reports two patients, a 31 year-old woman with multiple neurofibromatosis presenting as an intraabdominal malignant peripheral nerve sheath tumor, and a 33 year-old woman with an intrathoracic malignant peripheral nerve sheath tumor. The patients were treated with chemotherapy followed by radiotherapy. However, one patient died as a result of disease progression 21 months after the diagnosis and the other patient is currently being treated with radiotherapy.

Key Words : Neurofibromatosis, Sarcoma, Chemotherapy

INTRODUCTION

A malignant peripheral nerve sheath tumor (MPNST) is an extremely rare soft tissue tumor¹⁾, whereas there is a higher incidence in patients with neurofibromatosis type I (NF1, von Recklinghausen's disease)^{2,3)}. The prognosis of a MPNST associated with neurofibromatosis is generally worse than that without neurofibromatosis. The common sites of invasion are the lower and upper extremities, trunk, head and neck¹⁾. However, an intraabdominal or intrathoracic manifestation is rare. We recently encountered two cases of an intraabdominal or intrathoracic presentation of a MPNST in patients with neurofibromatosis.

CASE REPORT

Case I : A 31 year-old woman with a known neurofibromatosis

was admitted complaining of a painful abdominal mass. A physical examination revealed a large, hard soft-tissue mass bulging out from the middle abdomen, and numerous, small subcutaneous neurofibroma nodules and brownish-pigmented lesions (café au lait spots) in the trunk and extremities (Figure 1). An abdominal CT scan demonstrated a large (approximately 9×10 cm) inhomogeneous mass with an area of central necrosis (Figure 2). The histopathology of the circumscribed and encapsulated mass obtained by a wide excision indicated a MPNST from the mesentery showing frequent mitoses in more than five per one high power field (Figure 3A). In the immunohistochemical stain, the tumor cells stained positively to the S-100 protein, which is a cytoplasmic marker used for identifying Schwann cells (Figure 3B). One month after surgery, the masses of the right paracolic gutter and the left supramesic area appeared in the CT scan. The patient was then treated with 6 cycles of MAID chemotherapy (ifosfamide 2000 mg/m² for 3 days, doxorubicin 20 mg/m² for 3 days, and

• Received : January 26, 2004

• Accepted : April 16, 2004

• Correspondence to : Sang Kyun Sohn, M.D., Department of Oncology/Hematology, Kyungpook National University Hospital, 50 Samduck 2-Ga, Jung-Gu, Daegu, 700-721, Korea Tel : 82-53-420-5587, Fax : 82-53-426-2046, E-mail : sksohn@knu.ac.kr

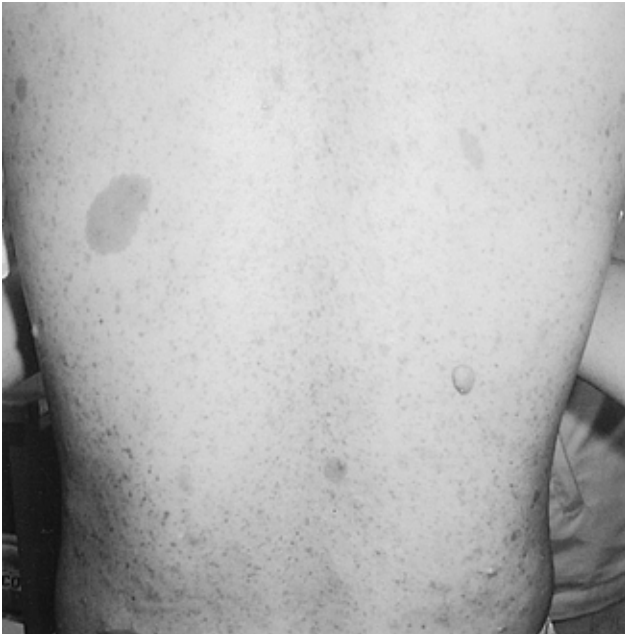

Figure 1. Skin lesions of case I. There are numerous, small subcutaneous nodules of neurofibroma and brownish-pigmented lesions (café au lait spots) in the trunk.

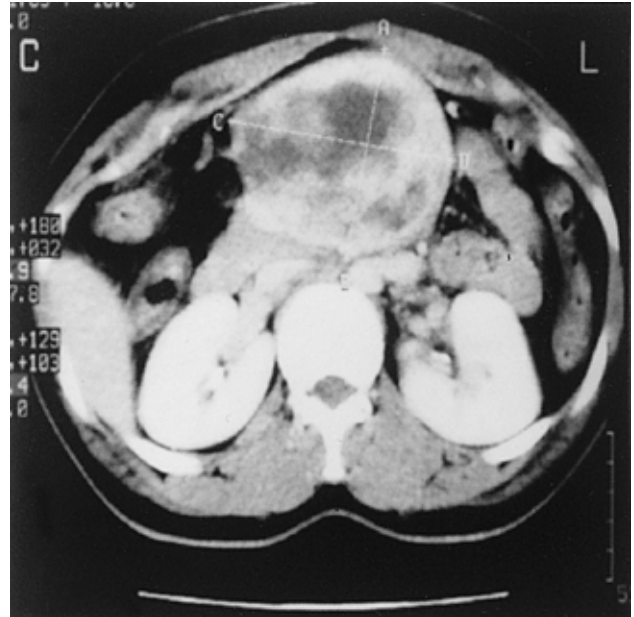


Figure 2. Abdominal CT scan of case I demonstrating a large (approximately 9×10 cm) inhomogeneous mass with an area of central necrosis.


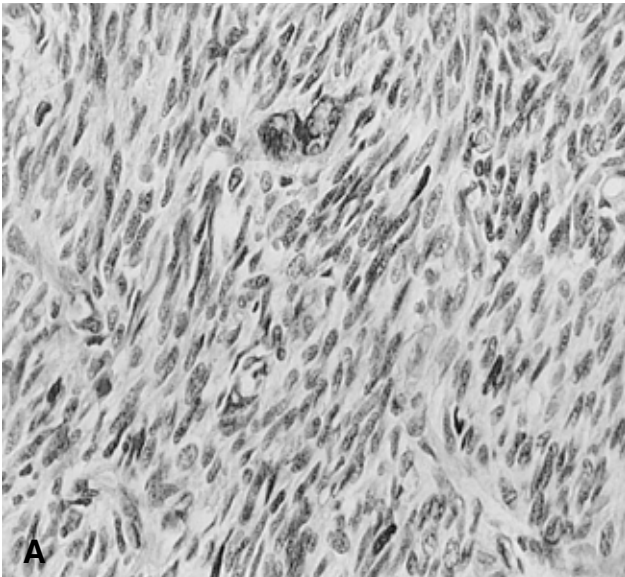


Figure 3. (A) The tumor cells show frequent mitoses of more than five per one high power field (H & E stain, ×400). (B) Immunohistochemical stain for the S-100 protein shows a positive reaction.

dacarbazine 300 mg/m² for 3 days), which was followed by radiotherapy (5400 cGY). The masses began to disappear after chemoradiotherapy but the disease progressed 2 months later. She was treated with a further 6 cycles of VIP chemotherapy (etoposide 75 mg/m² for 5 days, ifosfamide 1,000 mg/m² for 5 days, and cisplatin 20 mg/m² for 5 days), with a partial

response being observed. However, she died as a result of disease progression 21 months after the initial diagnosis.

Case II : A 33 year-old woman with a known neurofibromatosis was admitted due to left upper chest pain. A chest PA and CT scan demonstrated a homogenous mass measuring 3.5×2.5 cm at the left upper lung field with a well-demarcated

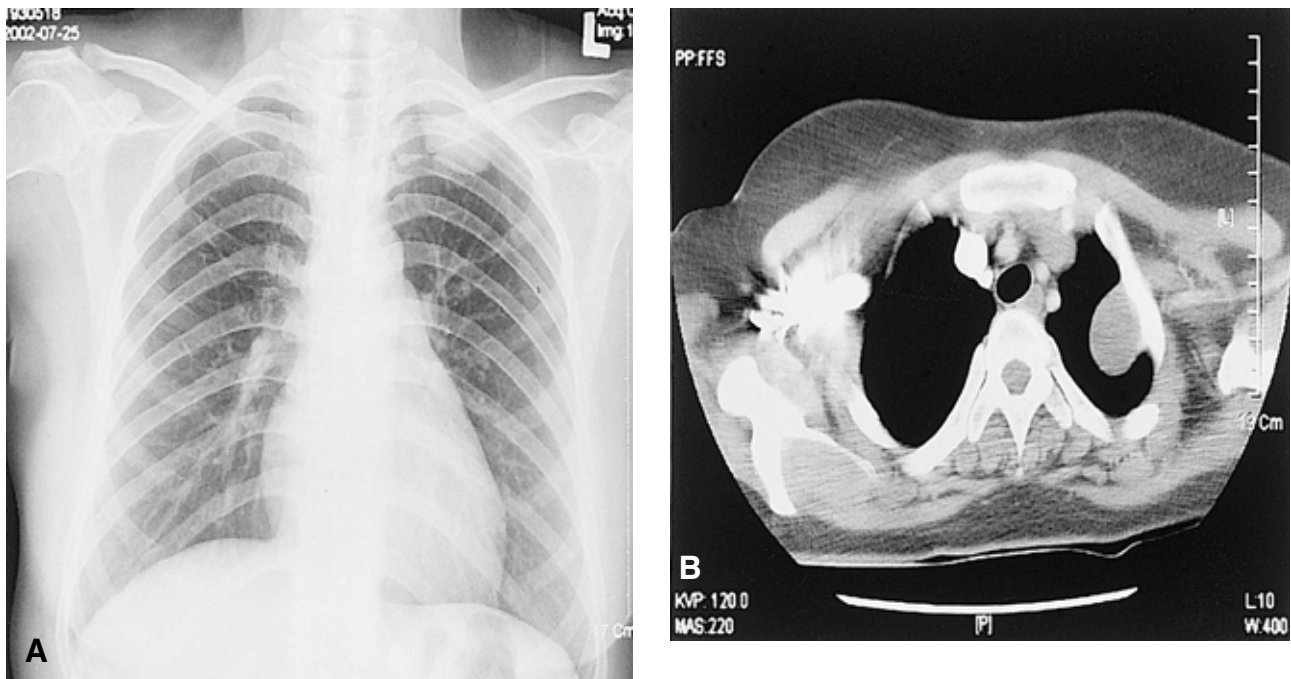


Figure 4. Chest PA (A) and CT scan (B) of case II show a homogenous mass measuring 3.5 cm×2.5 cm at the left upper lung field with a well-demarcated margin.

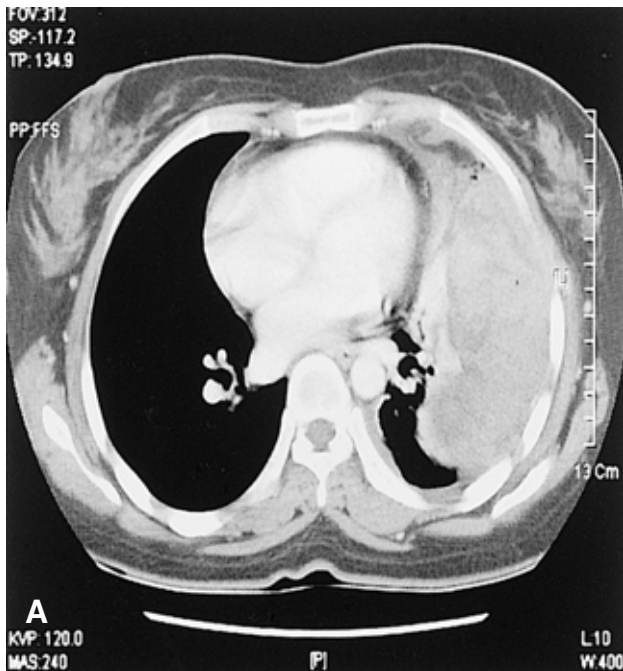


Figure 5. Chest CT scan of case II shows an inhomogeneous mass and a large amount of a left pleural effusion.

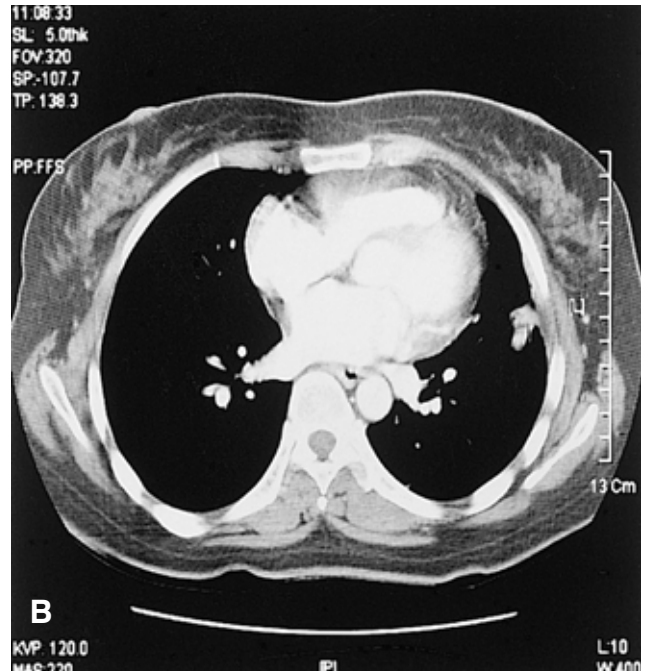


Figure 6. The chest CT scan shows that the tumor is markedly reduced after chemotherapy.

margin (Figure 4A, 4B). A wide excision was performed. The microscopic findings showed a MPNST with focal neurofibroma area and positive immunohistochemical staining for the S-100

protein on the cytoplasm of the tumor cells. She was re-hospitalized 6 months later due to persistent coughing and dyspnea. A chest CT scan demonstrated an inhomogeneous

mass and a large amount of a left pleural effusion (Figure 5). A needle biopsy of the mass showed a tumor recurrence. After 6 cycles of MAID combination chemotherapy, a CT scan showed that the mass was markedly reduced (Figure 6). She is currently being treated with radiotherapy.

DISCUSSION

A neurofibromatosis type I, which is also known as von Recklinghausen's disease, is a disease of the supporting tissues of the nervous system and is one of the most common genetic disorders, affecting approximately 1 out of 3,000 live births⁴. An autosomal dominant mutation at the 17q11.2 locus has been identified⁵. The clinical features of NF1 include café au lait spots, Lisch nodules (pigmented hamartomas) of the iris, and several types of neurofibromas. Our two patients also showed multiple café au lait spots and pigmented nodular skin lesions over the trunk and extremities.

Although higher estimates appear in the literature, approximately 5% of patients with NF1 develop MPNSTs^{2,3}, which usually arises from a plexiform neurofibroma. The common anatomic locations for MPNSTs are the lower and upper extremities, the trunk, head and neck, and miscellaneous sites in descending order⁶. Sordillo PP et al⁷ and Guccion JG et al⁸ reported that tumors associated with NF1 are located more centrally than without NF1. However, intraabdominal or intrathoracic manifestation of MPNST in patients with NF1 is quite rare⁹⁻¹¹.

It appears that the presence of NF1 has a negative impact on the clinicopathological features of MPNST. A histological examination of our cases revealed high-grade features. Ducatman et al¹ also reported that the tumors associated with NF1 were more often poorly differentiated and showed higher mitotic indices. Furthermore, MPNSTs associated with NF1 appeared to be aggressive in our cases. In case I, the metastases existed at the time of surgery and an early recurrence after excision was observed in case II. Ducatman et al¹ also reported that metastases and recurrences were more common for tumors associated with NF1. In addition, the mean interval from diagnosis to the first recurrence or metastasis was shorter. According to their report, 16% of the group with NF1 survived 5 years, which was significantly lower than the 53% in the other group.

Treatments for MPNST have principally included a surgical excision with and without adjuvant radiation or chemotherapy. Survival appears to be related to the ability of a complete tumor resection. Many authors have failed to show a survival benefit with the use of adjuvant radiation therapy¹². However, Basso-Ricci et al¹³ reported a 56% disease free survival using

combined surgical and radiation therapy for MPNST. On the other hand, there has been considerable controversy surrounding the use of adjuvant chemotherapy in adults with soft tissue sarcomas including MPNST. Because of the small sample size of the individual reports, the Sarcoma Meta-Analysis Collaboration (SMAC) performed a meta-analysis of 1568 patients that were included in 14 randomized trials of adjuvant doxorubicin-based chemotherapy versus a control¹⁴. Their study showed improvements in the local relapse free interval, the distant relapse free survival, and the overall recurrence free survival. Currently, doxorubicin-based adjuvant chemotherapy is recommended for patients who have had a sarcoma removed but with features predicting a high likelihood of a relapse (deep location, size > 5 cm, high histological grade). The role of chemotherapy in the treatment of a metastatic or recurrent MPNST is poorly understood due to its rarity. Several studies have reported that MPNST should be regarded as a drug sensitive neoplasm^{15,16}. Doxorubicin containing combination chemotherapy had moderate activity in our cases. However, there is no clear standard of care regarding the issue of palliative chemotherapy in patients with MPNST. Therefore, future multi-center clinical trials will be needed in order to determine the role of palliative chemotherapy and to define the most active chemotherapeutic regimens.

This paper reports two cases of an intraabdominal or intrathoracic presentation of a MPNST in patients with NF1. MPNST associated with NF1 showed a highly aggressive behavior and a poor prognosis. It is recommended that a MPNST associated with NF1 be treated aggressively with multi-modalities such as a radical tumor excision with a wide margin of normal tissue followed by adjuvant chemoradiotherapy. In addition, the patients should be closely monitored for the early detection of a recurrence.

REFERENCES

- 1) Ducatman BS, Scheithauer BW, Piepgras DG, Reiman HM, Ilstrup DM. *Malignant peripheral nerve sheath tumors: a clinicopathologic study. Cancer* 57:2006-2021, 1986
- 2) Sorensen SA, Mulvihill JJ, Nielsen A. *Long-term follow-up of von Recklinghausen neurofibromatosis. N Engl J Med* 314:1010-1015, 1986
- 3) Riccardi V. *Von Recklinghausen neurofibromatosis. N Engl J Med* 305:1617-1627, 1981
- 4) Riccardi V. *Neurofibromatosis: phenotype, natural history and pathogenesis. 2nd ed. Baltimore, Johns Hopkins University press, 1992*
- 5) Wallace MR, Marchuk DA, Anderson LB, Letcher R, Odeh HM, Saulino AM, Fountain JW, Breton A, Nicholson J, Mitchell AL. *Type I neurofibromatosis gene: identification of a large transcript disrupted in three NF1 patients. Science* 249:181-186, 1990

- 6) D'Agostino AM, Soule EH, Miller RM. *Sarcoma of peripheral nerves and somatic soft tissues associated with multiple neurofibromatosis (von Recklinghausen's disease)*. *Cancer* 16:1015-1027, 1963
- 7) Sordillo PP, Helson L, Hajdu SI, Magill GB, Kosloff C, Golbey RB, Beattie EJ. *Malignant schwannoma: clinical characteristics, survival, and response to therapy*. *Cancer* 47:2503-2509, 1981
- 8) Guccion JG, Enzinger FM. *Malignant schwannoma associated with von Recklinghausen's neurofibromatosis*. *Virchows Arch A Pathol Anat Histo* 383:43-57, 1979
- 9) Inoue M, Mitsudomi T, Osaki T, Oyama T, Haratake J, Yasumoto K. *Malignant transformation of an intrathoracic neurofibroma in von Recklinghausen's disease*. *Scand Cardiovasc J* 32:173-175, 1998
- 10) Suzuki H, Yamaguchi Y, Kimura H, Baba M, Hiroshima K. *Malignant mediastinal schwannoma associated with von Recklinghausen's disease: a resected case*. *Nippon Kyobu Geka Gakkai Zasshi* 44:864-868, 1996
- 11) Park JH, Choi KH, Lee HB, Rhee YK, Lee YC, Chung MJ. *Intrathoracic malignant peripheral nerve sheath tumor in von Recklinghausen's disease*. *Korean J Intern Med* 16:201-204, 2001
- 12) Storm FK, Eilber FR, Mirra J, Morton DL. *Neurofibrosarcoma*. *Cancer* 45:126-129, 1980
- 13) Basso-Ricci S. *Therapy of malignant schwannomas: usefulness of an integrated radiologic surgical therapy*. *J Neurosurg Sci* 33:253-257, 1989
- 14) Sarcoma Meta-Analysis Collaboration. *Adjuvant chemotherapy for localized respectable soft-tissue sarcoma of adults: meta-analysis of individual data*. *Lancet* 350:1647-1654, 1997
- 15) Goldman RL, Jones SE, Heusinkveld RS. *Combination chemotherapy of metastatic malignant Schwannoma with vincristine, adriamycin, cyclophosphamide, and imidazole carboxamide: a case report*. *Cancer* 39:1955-1958, 1977
- 16) Blay JY, van Glabbeke M, Verweij J, van Oosterom AT, le Cesne A, Oosterhuis JW, Judson I, Nielsen OS. *Advanced soft-tissue sarcoma: a disease that is potentially curable for a subset of patients treated with chemotherapy*. *Eur J Cancer* 39:64-69, 2003