

Learning Curve of Minimally Invasive Two-Port Laparoscopic Myomectomy

Iwaho Kikuchi, MD, Jun Kumakiri, MD, Shozo Matsuoka, MD, Satoru Takeda, MD

ABSTRACT

Background and Objects: To examine the learning curve of minimally invasive 2-port total laparoscopic myomectomy (TTLM).

Methods: TTLM was performed by using only umbilicus and left inguinal ports, for 30 patients at our university affiliated hospital between May 2009 and February 2010. The times required for each of the 5 surgical phases of the early and late cases performed by the same surgeon were compared by using a DVD time counter.

Results: The mean surgical time was 82.5 ± 5.2 minutes, blood loss was 42.1 ± 7.5 mL, and weight of specimen was 65.3 ± 13.3 g. The eighth case was the first in which the surgical time fell below the overall mean surgical time. Comparison of the mean time of each phase between the 7 early and the subsequent (late) cases revealed significant differences in the times required for suturing.

Conclusions: Although this was a feasibility study, the results suggest that this technique can be mastered after 7 cases.

Learning curve, Suturing.

Key Words: Laparoscopic myomectomy, Single port, Two-port, Flexible scope.

INTRODUCTION

Surgical techniques to further enhance the low invasiveness of laparoscopic surgery have recently been reported. Laparoscopic surgery with a single umbilical wound, so-called single-port surgery, has frequently been reported in general surgery: it is now also used in the urologic and gynecologic fields.¹⁻⁷ Single-port surgery is aesthetically beneficial for patients, but not necessarily advantageous for surgeons, because it may require special surgical equipment and complicated manipulations.

We have therefore developed and reported a surgical technique using an umbilical wound and an additional 5-mm inguinal wound.⁸ Although not a single-port technique, this approach allows full suturing manipulations due to the additional 5-mm inguinal wound. It is therefore an excellent technique with a wide range of applications based on low invasiveness and versatility. The 5-mm wound can also be used to insert a drain. This technique can be applied to total laparoscopic myomectomy (TLM), which requires difficult suturing manipulations.

We formerly used a 4-puncture method for gynecological laparoscopic surgery.⁹⁻¹² In addition to the conventional technique, we introduced the 2-port technique developed by the same surgeon (first author) for specified surgical indications in March 2009 together with the single-port technique.

The present retrospective study was designed to determine the learning curve and utility of the 2-port technique by strictly defining its indications and examining surgical results of procedures performed by the same surgeon.

MATERIALS AND METHODS

Patients diagnosed with uterine myomas and scheduled to undergo surgery at our university affiliated hospital between May 2009 and February 2010 were registered and received preoperative examinations including transvaginal ultrasonography and magnetic resonance imaging (MRI). Those who met predetermined criteria for the size and number of myomas and provided written informed consent were included. All of the subjects had received 5 or 6 courses of preoperative GnRH α therapy before hos-

Department of Obstetrics and Gynecology, Juntendo University Faculty of Medicine, Hongo, 2-1-1, Bunkyo-ku, Tokyo, Japan (all authors).

Address correspondence to: Iwaho Kikuchi, MD, Department of Obstetrics and Gynecology, Juntendo University Faculty of Medicine, Hongo, 2-1-1, Bunkyo-ku, Tokyo, 113-8421, Japan, Telephone: +81-3-5802-1100, Fax: +81-3-5689-7460, E-mail: kikuchiban@hotmail.com

DOI: 10.4293/108680812X13291597716267

© 2012 by JSLS, *Journal of the Society of Laparoendoscopic Surgeons*. Published by the Society of Laparoendoscopic Surgeons, Inc.

pitalization, which is similar to that required for our conventional method.⁹⁻¹²

Protocol

Based on preoperative MRI findings, whether or not 2-port laparoscopic myomectomy was indicated, patients were enrolled according to the following protocol.

1. Inclusion criterion: Patients with symptoms, such as hypermenorrhea, or a myoma nucleus with the longest diameter exceeding 5cm.

2. Exclusion criteria: Any submucosal myoma with a diameter ≤ 3 cm with a projection rate to the mucosal surface, as observed with a uteroscope or ultrasonography, of $\geq 50\%$ was excluded, because uteroscopic surgery was considered more appropriate. Interstitial or subserous myomas were treated with the conventional 4-puncture technique when the longest diameter was ≥ 8 cm or the number of myomas was ≥ 4 , because these exceed the limit of the 2-port technique.

3. The ninth intercostal approach was used to check for adhesions of any abdominal organ to the umbilicus in patients who had a history of open abdominal operations.¹³

4. The same surgeon (first author: has performed approximately 2000 laparoscopic surgeries) performed all surgeries using the 2-port technique. The addition of manipulation ports for conversion to the conventional 4-puncture method during surgery was allowed, at the discretion of the surgeon, when it was too difficult to achieve the operative aims using the 2-port technique.

5. Basically, only patients scheduled to receive surgery for uterine myomas were included. Patients who had a history of open abdominal surgery and postoperative adhesion or those found to require synechiotomy for adhesions due to endometriosis were surgically treated, but were excluded from evaluation as drop-outs, because such cases often require a markedly prolonged surgical time as compared to routine TLM, making it difficult to strictly examine surgical results.

Surgical Technique

An Olympus 5-mm flexible scope (LTF-VP, Olympus, Tokyo, Japan) was used, as reported earlier.⁸ This scope visualizes the surgical field, irrespective of insertion angle. The closed approach using Versa STEP (Covidien Japan, Tokyo, Japan) was used to enter the abdominal cavity

through an umbilical wound. A 12-mm trocar was placed at the umbilical wound.

However, the ninth intercostal approach was used in patients with a history of open abdominal surgery to confirm the absence of any adhesions of abdominal organs to the umbilicus.¹³ The umbilicus was examined from the inside of the abdominal cavity before a 12-mm trocar was inserted. The 5-mm flexible scope was inserted through the 12-mm trocar. A 5-mm STEP trocar was inserted from the left inguinal region under laparoscopic observation. The flexible scope was then inserted through the inguinal trocar to allow insertion of the 5-mm trocar to the caudal side of the 12-mm trocar, while the umbilicus was monitored from the inside of the abdominal cavity. The surgeon stood on the left side of the patient to manipulate the 12-mm umbilical trocar with the right hand and 5-mm inguinal trocar with the left hand. An assistant inserted the flexible scope through the 5-mm umbilical trocar and manipulated it with the left hand. The assistant adjusted the angle of the scope, as required, to visualize the surgical field during the operation. The assistant used a uterine manipulator (Ethicon Endo Surgery, Tokyo, Japan) with the right hand, as required (**Figure 1**).

The laparoscopic myomectomy was carried out similarly to the method reported above. Twenty IU/mL of vasopressin were diluted with saline to prepare a 1/100 dilution, which was locally injected at several sites on a myoma. The myometrium was then incised with a monopolar needle. A myoma screw was inserted through the incision to remove the nucleus of the myoma. The incision was then closed by suturing 2 to 3 layers of the myometrium, depending on thickness. A 0-Polysorb 37-mm 1/2 Needle (Covidien, Japan) was used for suturing. The needle was always inserted and retrieved through the 12-cm trocar. All suturing manipulations were performed in a continuous manner. Each suture was started by making an anchor using a slip knot and ligated using an Aberdeen knot,^{8,14,15} The first layer was closed with the usual continuous su-

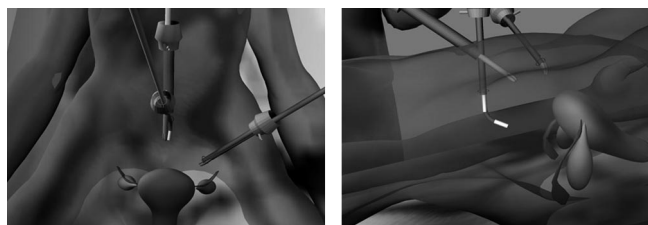


Figure 1. Trocar ports were positioned as shown in this figure. The 12-mm and 5-mm umbilical trocar ports were positioned so that they would be vertically aligned.

turing technique and the second and later layers with the interlock suturing technique to prevent loosening. Whenever oozing was observed after completion of the suturing manipulation, a Z suture was added and tightened using a slip knot.

In patients in whom the endometrium was opened during myomectomy, continuous suturing using 3-0 Polysorb (Covidien, Japan) was performed to assure closure. The removed myoma tissue was retrieved through the umbilical wound using an electric morcellator. A 12-mm electric morcellator from Karl Storz (MC Medical, Tokyo, Japan) or a disposable electric morcellator from Ethicon Endo-Surgery (Tokyo, Japan) was used, as appropriate, depending on the size of each myoma. The former was directly inserted through the 12-mm umbilical trocar, while the latter was used after removal of the 12-mm trocar. To ensure safety, the inguinal trocar was replaced with the flexible scope to monitor the blade edge of the morcellator during the retrieval procedure.

Interseed (Ethicon Endo-Surgery, Tokyo, Japan) was applied to the uterine wound to prevent adhesion. Finally, an abdominal drain was inserted from the 5-mm inguinal wound before the surgery was completed.

An example of TLM by the 2-port technique is presented. The photos shown were taken at the time of incising the myometrium, performing an enucleation, continuous interlock suture, making an Aberdeen knot, and finishing the surgery (**Figure 2**).

Statistical Analysis

The duration of surgery, estimated blood loss, and specimen weight of each case were recorded.

The mean duration of the operations was calculated for comparison with the surgical times of each individual operation, thereby allowing determination of the first operation whose surgical time fell below 2 times of the standard deviation added to the mean. Those after this operation, including the operation itself, were regarded as late cases and those before this operation as early cases.

The times of the following 5 surgical phases were calculated with a DVD time counter for each surgery.

- 1) Entry: From the start of insertion of the second trocar into the inguinal region until the start of vasopressin injection.
- 2) Enucleation: From the start of vasopressin injection through the incision with a monopolar needle until the start of suturing (insertion of needle).
- 3) Suturing: From the start of suturing (insertion of needle) until the completion of all-layer suturing (final string cutting) (for multiple myomas, until the completion of suturing of the myomectomized site of the largest myoma).
- 4) Collection of resected specimen with electric morcellator: From the insertion of the morcellator until the end of specimen collection and removal of the morcellator.
- 5) Confirmation of hemostasis: From the removal of the morcellator until confirmation of hemostasis, application

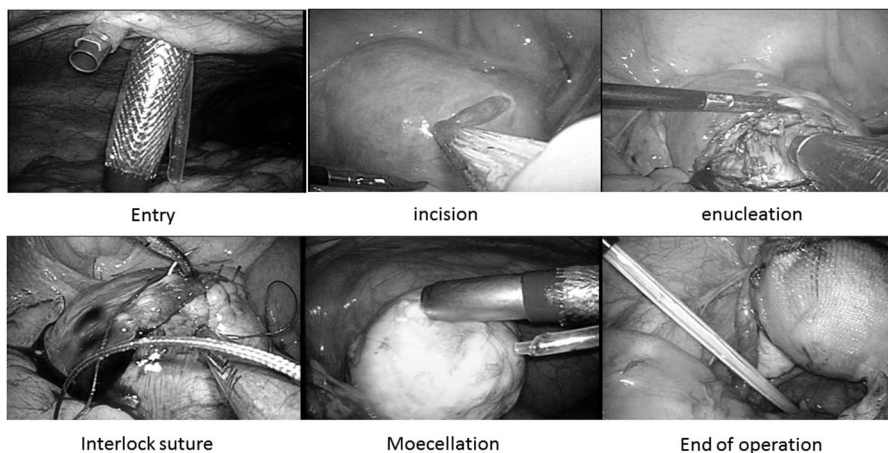


Figure 2. This figure describes the procedure of TLM using the 2-port technique. The photos shown were taken at the time of setting the trocars, incising the myometrium, performing an enucleation, continuous interlock suture, making an Aberdeen knot, collecting of resected specimen with electric morcellator, and finishing the surgery.

of the adhesion preventing agent, and drain insertion (including the time for additional suturing for hemostasis).

The time required to perform each phase was measured with the DVD time counter and then examined. The times of each phase were compared between the early and late cases to determine which phase was most influenced by technical improvement.

SPSS15 statistical software (SPSS Japan, Tokyo) was used for all statistical analyses. Nonparametric tests (Kruskal Wallis and Mann-Whitney tests) were used, because of the small number of subjects.

RESULTS

The first author treated 135 of 457 patients undergoing TLM at our institution during the study period. Thirty of these patients met the protocol criteria and were included in the present analysis. The mean duration of surgery was 82.5 ± 5.2 minutes, mean estimated blood loss was 42.1 ± 7.5 mL, and mean weight of resected specimens was 65.3 ± 13.3 g.

None of the 30 operations required blood transfusion either during or after surgery. None required intraopera-

tive conversion to the conventional 4-puncture method. The endometrium was opened in 7 cases and could be closed by suturing in all of them.

The ninth intercostal approach¹³ was used in 4 patients with a history of open abdominal surgery, including caesarean delivery in 3 and abdominal myomectomy in one. None of the 4 patients had any adhesions of intraperitoneal organs to the umbilicus, as confirmed with a 3-mm thin scope inserted through the ninth intercostal space, and therefore none required adhesiolysis. No adhesions of the intestine to the uterus or adnexa that might interfere with TLM were observed. Based on these results, all 4 cases were considered evaluable. But 2 other operations were excluded from evaluation, because degenerative myoma (asterisk cases in the figure) required greatly prolonged surgical time (**Figure 3-1**).

Examination of the duration of surgery revealed the eighth operation to be the first in which surgical time fell below the mean+2SD duration of surgery. Therefore, the seventh operation after this including the operation itself and those that followed it were regarded as late cases and those before this operation as early cases (**Figure 3-2**). The calculated mean times for each surgical phase were

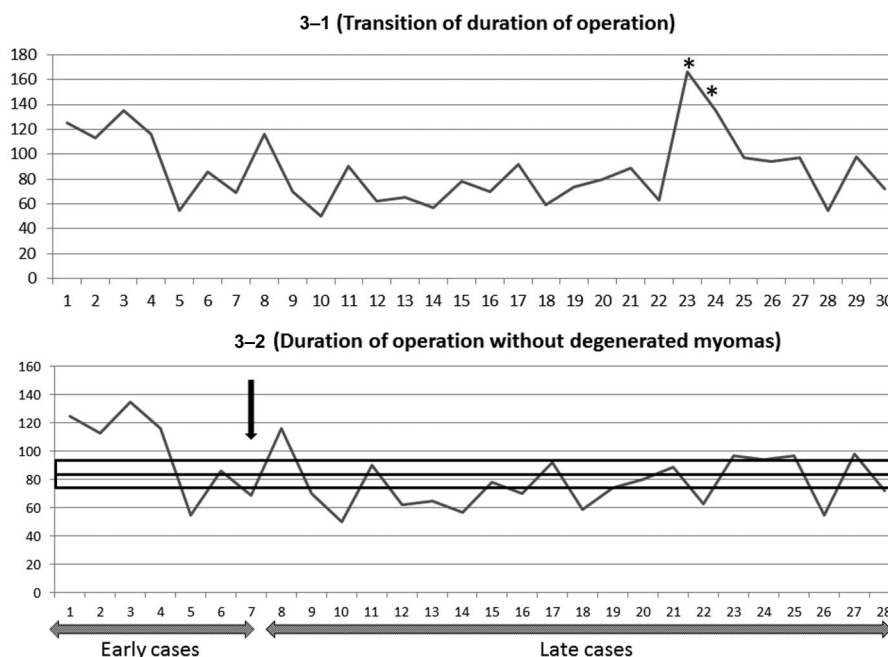


Figure 3. (3-1) The graph shows the duration of surgeries. The cases with the asterisks greatly exceeded the average operation time. They were the cases of degeneration myomas (**3-2**). The graph shows the duration of operations with the 2 cases removed that greatly exceeded the average in **Figure 3-1**. The square shows the average +2SD. A black arrow shows the seventh case falling below the average +2SD, which is the first case to do so. Therefore, the seventh operation and those after it, including the operation itself, were regarded as late cases and those before this operation as early cases.

as follows: 4 minutes and 35 ± 17 seconds for entry, 5 minutes and 31 seconds ± 1 minute and 12 seconds for enucleation, 33 minutes and 16 seconds ± 3 minutes for suturing, 10 minutes 24 seconds ± 1 minute and 14 seconds for morcellation, and 6 minutes and 24 seconds ± 1 minute and 6 seconds for hemostasis. Comparison of the time required for each phase between the 7 early cases and the subsequent (late) cases revealed a significant difference in the time taken for suturing for the third phase (**Figure 4**).

DISCUSSION

Specificity of Uterine Myomectomy

Uterine myomectomy is intended to conserve uterine function.^{10,11,16} It is the most appropriate technique for conserving fertility among the treatment options for uterine myomas. Patients undergoing myomectomy can still expect to become pregnant after the operation. Like other surgical techniques, uterine myomectomy is performed abdominally and laparoscopically. Laparoscopic myomectomy is considered superior due to its low invasiveness and reduced postoperative adhesion risk.¹⁶

We formerly used the 4-puncture method for all laparoscopic uterine myomectomy procedures. Our patients thus treated became pregnant and delivered vaginally.^{10,11} There is an increased risk of uterine rupture during pregnancy and delivery after uterine myomectomy due to weakening of the myomectomized areas.¹⁷ Definitive wound closure achieved by appropriately suturing multiple layers of the myometrium during surgery is therefore essential to minimize the risk and ensure the safety of pregnancy and delivery.^{10,11} To achieve this closure, it is not enough to simply suture a wound: rather, an excellent technique and high skill are required. TLM must be performed in a low-invasive manner and with the surgeon having a strong command of the suturing technique. The conventional 4-puncture TLM is excellent in terms of providing secure suturing. In the adaptation, this 2-port technique was thought to allow suturing that was similar to a conventional 4-puncture method.

Usefulness of 2-Port Technique

The 2-port technique allows TLM with a smaller number of wounds than the conventional 4-puncture technique. Two wounds are required, one is made in the umbilical area, and the other is a 5-mm inguinal wound. No wound is required on the side of the umbilicus. It is therefore

considered a low-invasive, aesthetically favorable technique.⁸ Minimal invasiveness may lead to higher technical difficulty. However, the 2-port technique did not add technical difficulty compared to the conventional technique and allowed us to securely suture 2 to 4 layers of the myometrium as long as the myomas being removed were within the indications specified in the protocol. The endometrium was opened in a few cases but could be securely closed by suturing. These results indicate the 2-port technique to be a useful option for TLM, which, as discussed above, requires an excellent technique and high skill in suturing. In addition, insertion of a drain via the 5-mm wound is possible.

Furthermore, the 2-port technique provided a far higher degree of freedom in handling forceps and adjusting the surgical field of view than the single-port technique.

Discussion of Learning Curve

We did not compare the learning curve of a conventional 4-port method with a 2-port method; moreover, we did not compare the postoperative courses of each of those methods. So we cannot compare, in detail, the 2-port and conventional method. However, it is thought that the learning curve is important.

The technical difficulty of TLM is markedly increased in patients with multiple or huge uterine myomas. The surgical results of TLM are highly dependent on technical difficulty. In the present study, restrictions were set as to the number and size of myomas to reduce the differences in technical difficulty among subjects.

The analysis of the surgical phases using the DVD movie of each surgery showed significant differences in suturing time between the early and late cases. The surgeon attempted to suture multiple layers of the myometrium even if it was time-consuming to ensure secure suturing. The reduced suturing time in the late cases compared to the 7 early cases is probably attributable to technical improvement. No time reduction was noted for the other surgical phases between the early and late cases. This indicates that the surgical manipulations other than suturing could be smoothly performed when the 2-port technique was introduced for the first time. Also this study was the experience of only one surgeon, which certainly is not enough. But this study suggests the ease of introducing this technique and supports its usefulness.

CONCLUSION

TLM is intended to conserve uterine function and therefore must ensure that the postoperative uterus can with-

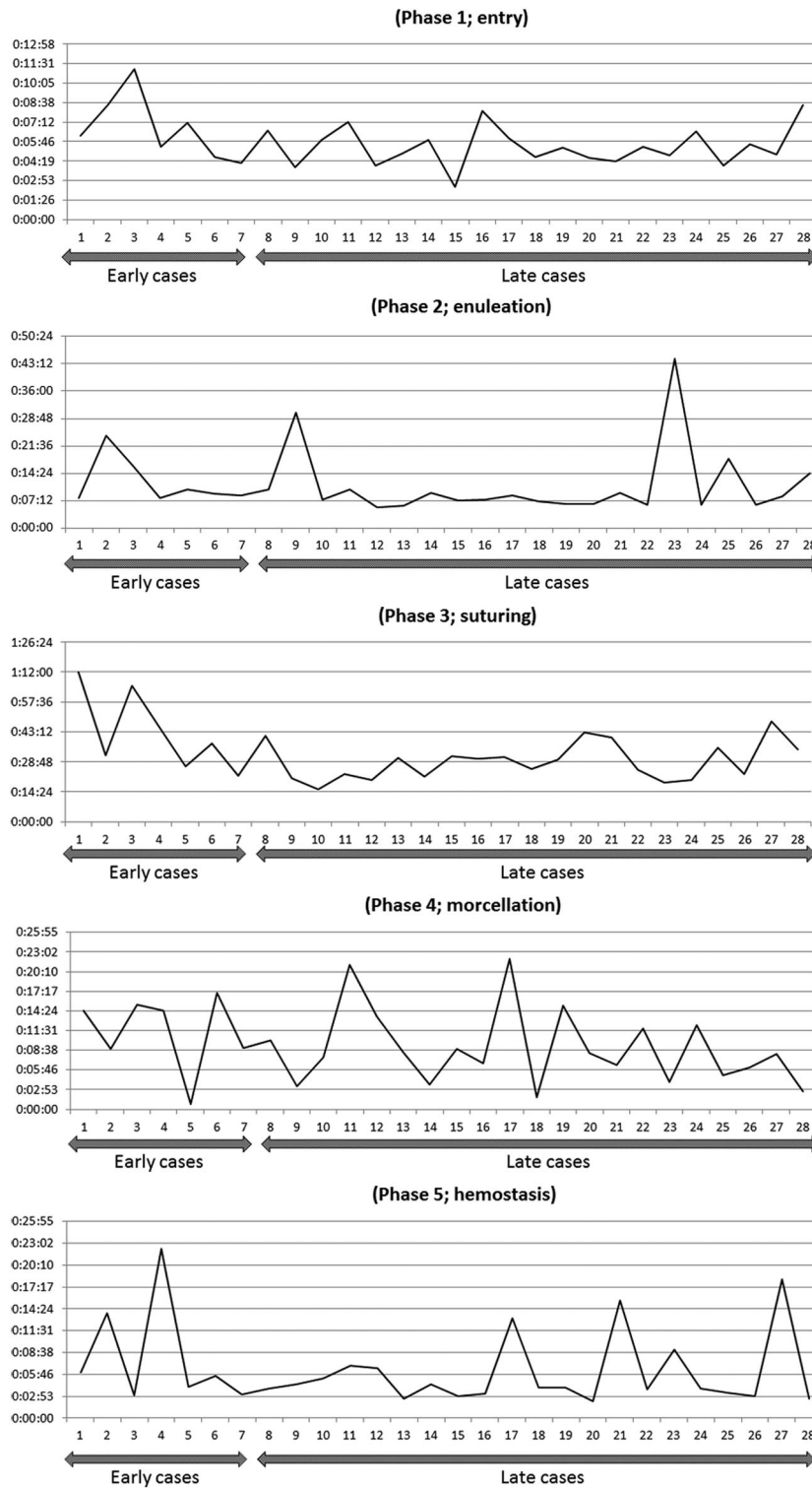


Figure 4. These graphs show each phase of the operation. Only at the suturing phase was a significant difference noted in the comparison between the early and late cases ($P=0.021$; Mann-Whitney U test).

stand pregnancy. The 2-port technique provided secure suturing of multiple layers of the myometrium, while maintaining low invasiveness. Analysis of the learning curve showed that this technique could be mastered by performing 7 cases. No time reduction was noted for the other surgical phases including entry, myomectomy, and collection of resected specimens between the early and late cases. The techniques other than the suturing were executed at the beginning of the introduction as well as the conventional technique. Also although this is a feasibility study, it suggests that this technique can be mastered after 7 cases.

References:

1. Romanelli JR, Earle DB. Single-port laparoscopic surgery: an overview. *Surg Endosc*. 2009;23:1419–1427. Epub 2009 Apr 4. Review.
2. Chamberlain RS, Sakpal SV. A comprehensive review of single-incision laparoscopic surgery (SILS) and natural orifice transluminal endoscopic surgery (NOTES) techniques for cholecystectomy. *J Gastrointest Surg*. 2009;13(9):1733–1740. Epub 2009 May 2. Review.
3. Lim MC, Kim TJ, Kang S, et al. Embryonic natural orifice transumbilical endoscopic surgery (E-NOTES) for adnexal tumors. *Surg Endosc*. 2009 Nov;23(11):2445–2449.
4. Merchant AM, Cook MW, White BC, et al. Transumbilical Gelpport access technique for performing single incision laparoscopic surgery (SILS). *J Gastrointest Surg*. 2009;13(1):159–162.
5. Nguyen NT, Reavis KM, Hinojosa MW, et al. A single-port technique for laparoscopic extended stapled appendectomy. *Surg Innov*. 2009 Mar;16(1):78–81.
6. Tacchino R, Greco F, Matera D. Single-incision laparoscopic cholecystectomy: surgery without a visible scar. *Surg Endosc*. 2009 Apr;23(4):896–899.
7. Yi SW, Park HM, Lee SS, et al. Two-port total laparoscopic hysterectomy with a multichannel port. *J Laparoendosc Adv Surg Tech A*. 2009 Apr;19(2):223–228.
8. Kikuchi I, Kumakiri J, Kuroda K, et al. A novel modification of traditional 2-port laparoscopic surgery using a 5-mm flexible scope. *J Minim Invasive Gynecol*. 2009 Nov–Dec;16(6):734–8.
9. Takeuchi H, Kinoshita K. Laparoscopic myomectomy: indications, surgical technique and limitation. *JSLs*. 2003;7:89–95.
10. Kumakiri J, Takeuchi H, Kitade M, et al. Pregnancy and delivery after laparoscopic myomectomy. *J Minim Invasive Gynecol*. 2005;12:241–246.
11. Kumakiri J, Takeuchi H, Itoh S, et al. Prospective evaluation for the feasibility and safety of vaginal birth after laparoscopic myomectomy. *J Minim Invasive Gynecol*. 2008;15:420–424.
12. Takeuchi H, Kitade M, Kikuchi I, et al. Influencing factors of adhesion development and the efficacy of adhesion-preventing agents in patients undergoing laparoscopic myomectomy as evaluated by a second-look laparoscopy. *Fertil Steril*. 2008;89:1247–1253.
13. Kumakiri J, Takeuchi H, Itoh S, et al. A novel method of ninth-intercostal microlaparoscopic approach for patients with previous laparotomy. *Acta Obstetricia et Gynecologica*. 2006;85:977–981.
14. Shaw A, Duthie GS. A simple assessment of surgical sutures and knots. *J R Coll Surg Edinb*. 1995;40:388–3891.
15. Stott PM, Ripley LG, Lavelle MA. The ultimate Aberdeen knot. *Ann R Coll Surg Engl*. 2007;89:713–717.
16. Dubuisson JB, Fauconnier A, Deffarges JV, et al. Pregnancy outcome and deliveries following laparoscopic myomectomy. *Hum Reprod*. 2000;15:869–873.
17. Friedmann W, Maier RF, Luttkus A. Uterine rupture after laparoscopic myomectomy. *Acta Obstet Gynecol Scand*. 1996;75:683–684.