

Case Report

Open acetabular fracture: Case report and literature review[☆]Sarah J. Shiels^{*}, Jarrad M. Stevens, Timothy J.S. Chesser*Department of Orthopaedic and Trauma Surgery, Southmead Hospital, Bristol, United Kingdom of Great Britain and Northern Ireland*

ARTICLE INFO

Keywords:

Open acetabular
Fracture
Outcomes

ABSTRACT

Acetabular fractures are a rare injury, with a reported annual incidence of 3 patients per 100,000 per year. Open fractures of the acetabulum are extremely rare, with only explosive penetrating trauma (blast or gunshot injury) being previously reported. An open acetabular fracture as a result of blunt trauma is presented, in which the only indication was a wound in the buttock, in which early definitive surgical management of the injury provided a good clinical outcome.

Introduction

Acetabular fractures are rare with a reported annual incidence of 3 patients per 100,000 per year [1]. While pelvic fractures have an estimated incidence of 2–4% the incidence of open acetabular fractures are not known. Most displaced acetabular fractures are appropriate for open reduction and internal fixation to restore anatomical reduction of the hip joint. Urgency in management of these fractures are typically determined by the presence of the associated dislocation of the hip or neurovascular compromise. An open injury presents a secondary set of challenges in the form of potential contamination and associated soft tissue injury.

A case of an open acetabular fracture, after blunt trauma, is presented demonstrating how the incorporation of the open wound with the surgical approach, led to a good clinical outcome for the patient.

Case presentation

A 24-year old male was transferred to our tertiary trauma centre following a road traffic accident. Travelling at approximately 40 mph he was the rider of a moped which lost control and collided head on with a stationary van. He was wearing a fitted helmet with no other specific protective devices. There was no loss of consciousness. He was retrieved by road ambulance in a timely manner to the regional major trauma centre. While full spinal precautions were instituted the only identifiable injury was an open wound to his left buttock.

Emergency department primary survey revealed a hemodynamically stable patient. An open wound on his left buttock measured 6 × 6 cm (Fig. 1) and the underlying suspicion of fracture dislocation of the hip lead to pelvic radiographs and CT scans. Trauma series CT scans revealed an isolated posterior wall posterior column acetabular fracture with subluxation of the femoral head (Fig. 2).

Full secondary survey did not reveal any other injuries and both sensory and motor branches of the sciatic nerve were clinically intact. The Injury Severity score was calculated as 16. Our patient received intravenous flucloxacillin and gentamicin antibiotic therapy as per the BOAST Open Fracture guidelines [2].

Plain films of his pelvis with pelvic binder removed, including Judet views, were obtained. This confirmed the CT findings of a left posterior column fracture and posterior wall fracture with an associated inferior pubic rami fracture on the left.

[☆] The patient has consented to the publication of the case report including the anonymised photographs.

^{*} Corresponding author.

E-mail address: sshiels@tcd.ie (S.J. Shiels).

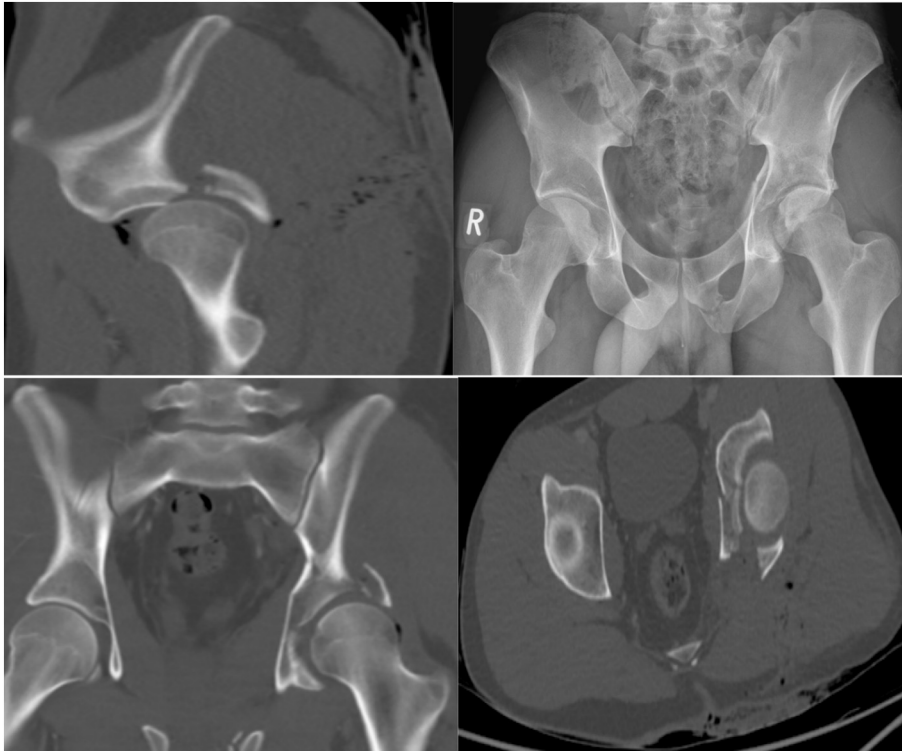


Fig. 1. A: AP x-ray binder off in ED, B: coronal CT, C: sagittal CT, D: axial CT.

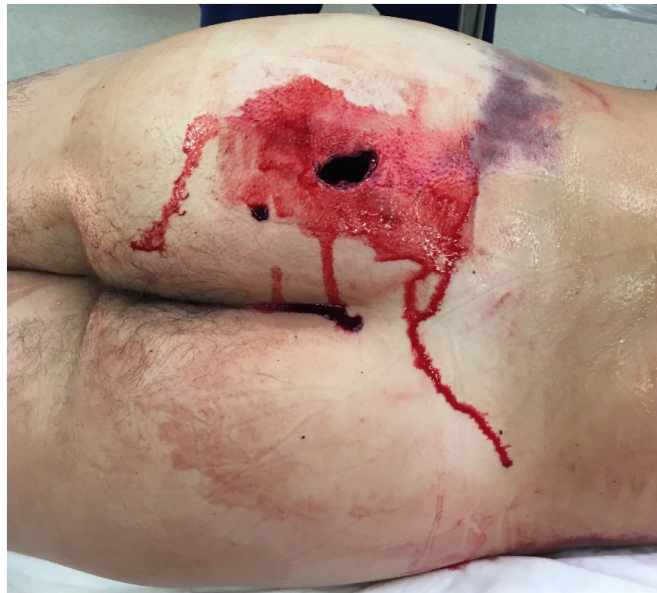

Fig. 2. Traumatic wound in ED.

The patient was taken to theatre within 24 h of injury, where he was positioned semi prone on a radiolucent table.

The open buttock wound was excised followed by sequential debridement from superficial to deep of all devitalised tissues. The wound was then extended in keeping with a Kocher-Langenbeck incision to enable access for surgical fixation of the acetabulum. It was noted that the open wound directly communicated with the hip joint, with a large posterior wall fragment sitting on the sciatic nerve (Fig. 3). The femoral head was sitting subluxed with a 3x3cm area of dome denude of cartilage. Attention turned to the posterior wall with reduction held with two 2-hole spring plates, followed by fixation of the posterior column with a 5-hole plate. A second 6-hole plate was fixed overlying the spring plates. Further washout and debridement were performed before final closure in

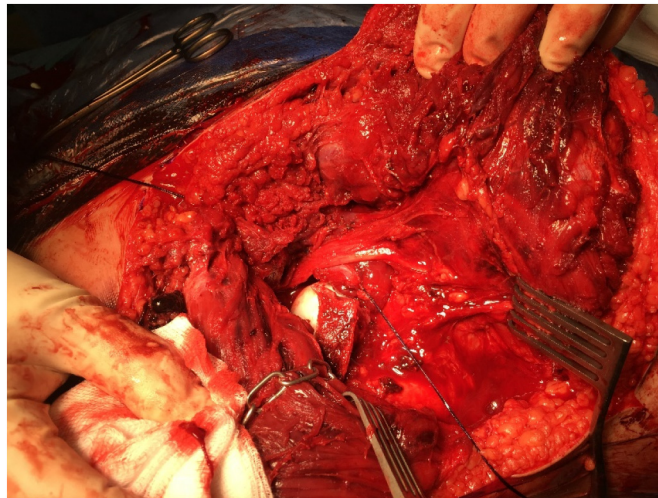


Fig. 3. Intraoperative image showing femoral head.

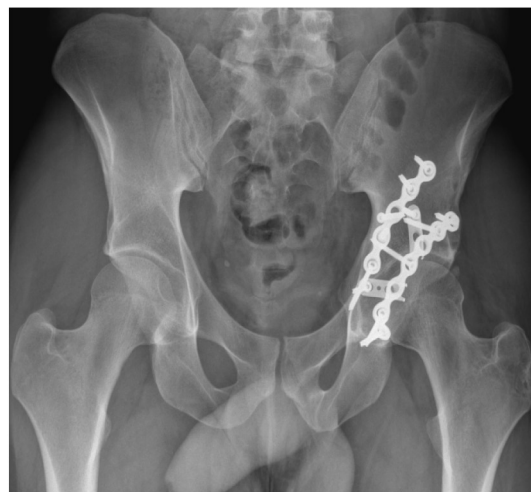
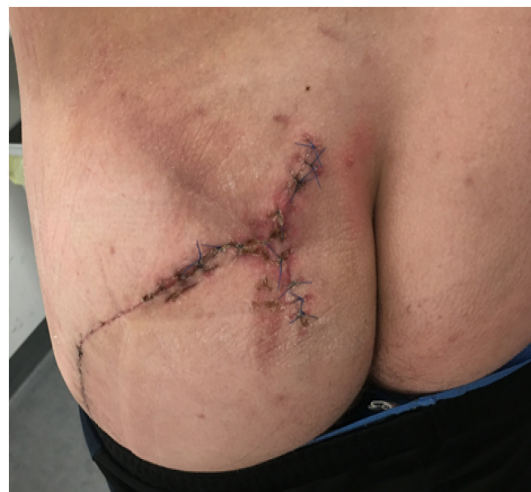
Fig. 4. Post op surgical wound at 2 weeks and AP Pelvic XR at 6 weeks.

layers of the wound.

Antibiotics were continued for 72 h post operatively. He was encouraged to lie on his right side to protect his wound and CPM was commenced by the physiotherapists to achieve hip flexion of 90°.

He was mobilised, touch weight bearing on his left side, with progression to partial weight bearing at six weeks progressing to full weight bearing at twelve weeks.

Follow-up radiographs showed a united fracture at one year with associated Brooker grade 1 heterotopic ossification. Oxford Hip Score was 42 out of 48 and EQ-5D-5L scores were 1 for mobility, 1 for self-care, 2 for usual activities, 1 for pain/discomfort and 1 for anxiety/depression with a rating of 80% for overall health. This resulted in an overall VAS score of 0.8. He returned to his usual employment in a factory six months post-surgery (Fig. 4).

Discussion

There were 466 acetabular fractures treated at our trauma centre over a 6-year period. On review of our data set this report was the only case of open acetabular fracture. A search of three online databases (PubMed, Cochrane, Medline) using the terms “open” and “acetabular” or “open” and “fracture” and “acetabular” revealed only two previous case reports on the subject [3,4]. In the case report described by Georgiadis, a similar mechanism of injury also resulted in an open acetabular and pelvic fracture which was successfully managed by early debridement and immediate open reduction and internal fixation.

Purcell et al. published on outcomes of closed vs open combat-related acetabular fractures [5]. The group of patients reported on in this series were combat related open acetabular fractures as a result of blast injuries. The cohort represents a unique injury pattern often with devastating associated injuries. The infection rate for open acetabular fractures was reported as high as 47% with 28% of patients with an open fracture contracting angio-invasive fungal infections. Najibi et al. [6] reported on outcomes of gunshot wounds to the acetabulum. They note the multiple associated injuries with this cohort, which makes objective measurements of functional outcome difficult. While gunshot wounds and blast injuries may fracture the acetabulum as a part of a diffuse injury pattern, we did not encounter either mechanism in 466 acetabular fractures treated at our tertiary trauma centre. Vehicle road traffic accident, cyclist, motorbike accident and fall from standing height were the most common mechanisms of injury. We think this is a very rare presentation of an open acetabular fracture where the femoral head had been extruded through the buttock as a result of blunt trauma.

Conclusion

This case report alerts the surgeon that wounds over the buttock could represent an open acetabular fracture, which requires early debridement and assessment. Open acetabular fractures can occur due to extrusion of the femoral head through the buttock.

Conflict of interest

The authors declare no potential conflict of interests.

References

- [1] J.F. Keating, A. Laird, Acetabular fractures: a 16-year prospective epidemiological study, *J. Bone Joint Surg. (Br.)* 87 (7) (2005) 969–973.
- [2] BOAST Open Fracture Guidelines, <https://www.boa.ac.uk/wp-content/uploads/2017/12/BOAST-Open-Fractures.pdf>.
- [3] G.M. Georgiadis, The displaced open acetabular fracture: treatment with immediate open reduction and internal fixation, *J. Trauma: Injury, Infection and Critical Care* 47 (2) (1999) 389–392.
- [4] S.Y. Clutter, J.M. Steven, M. Erickson, W.R. Smith, P.F. Stahel, Management of an open acetabular fracture in a skeletally immature patient, *Open Orthop. J.* 1 (2007) 9–12.
- [5] R.L. Purcell, M.A. Donohue, Combat-related acetabular fractures: outcomes of open versus closed injuries, *Injury* 49 (2) (2018) 290–295.
- [6] S. Najibi, J.M. Matta, P.J. Dougherty, M. Tannast, Gunshot wounds to the acetabulum, *J. Orthop. Trauma* 26 (8) (2012) 451–459.