

# Management of chronic pain in Ehlers–Danlos syndrome

## Two case reports and a review of literature

Zhengyang Zhou, BHSc<sup>a</sup>, Abhitej Rewari, MD, BHSC<sup>b</sup>, Harsha Shanthanna, MD, MSc, FRCPC<sup>c,\*</sup>

### Abstract

**Rationale:** Ehlers–Danlos syndromes (EDSs) are a heterogeneous group of heritable connective tissue disorders involving defective collagen synthesis. Patients with EDS are prone for chronic myofascial pain, apart from other comorbidities. Although the initial pathology is commonly nociceptive, progression of EDS leads to neuropathies and central sensitization of pain signals. Overall, approximately 90% or more EDS patients suffer from chronic pain. There are no existing guidelines to manage chronic pain in EDS patients. In this article, we illustrate 2 case reports of EDS patients with chronic pain and review the relevant literature regarding the pathological considerations and management of chronic pain in EDS.

**Patient concerns:** Our first patient had worsening multiple joint pains despite treatment with medications and a recent diagnosis of EDS-type 3. The second patient had a complicated history including longstanding EDS and multiple previous surgeries. She was referred due to concern about complex regional pain syndrome (CRPS) in her upper extremity.

**Diagnoses:** For the first patient, apart from chronic pain due to her EDS, her history also revealed that she suffered from kinesiophobia. For the second patient, a detailed clinical assessment revealed no signs of CRPS but instead a generalized worsening of EDS symptoms.

**Interventions:** Both patients were evaluated by the multidisciplinary team consisting of a pain physician, nurse, pain psychologist, and a kinesiologist. Their treatment involved optimization of daily medications, participation in pain self-management sessions that included cognitive behavioral therapy, graded exercises, coping, and relaxation strategies.

**Outcomes:** Both patients demonstrated significantly better pain control and achieved overall improvement in daily living.

**Lessons:** EDS is a complex illness with a multitude of symptoms. As in our patients, EDS patients also suffer from panic and anxiety disorders that increase the burden of pain. Apart from optimization of medications, EDS patients are best managed by a multidisciplinary approach that includes pain education and life style changes. The caution that they are resistant to local anesthetics is unwarranted. Appropriate pain interventions in selected patients may have a role to decrease pain intensity.

**Abbreviations:** CBT = cognitive behavioral therapy, CRPS = complex regional pain syndrome, CS = central sensitization, EDS = Ehlers–Danlos syndrome, JHS = joint hypermobility syndrome, NP = neuropathic pain, NSAIDs = nonsteroidal anti-inflammatory medications, PDI = pain disability index, TMJ = tempo-mandibular joints, VAS = visual analog scale.

**Keywords:** chronic pain, Ehlers–Danlos Syndrome, myofascial pain, multidisciplinary treatment

Editor: N/A.

The authors have no funding and conflicts of interest to disclose.

Harsha Shanthanna is supported by the Canadian Anesthesia Research Foundation as Career Scientist Award 2018–2020.

<sup>a</sup> Michael DeGroote School of Medicine, <sup>b</sup> Department of Anesthesia,

<sup>c</sup> Department of Anesthesia, St. Joseph's Hospital, McMaster University, Hamilton, Ontario, Canada.

\* Correspondence: Harsha Shanthanna, Associate Professor Anesthesiology, Department of Anesthesia, St. Joseph's Healthcare, McMaster University, 50, Charlton Avenue East, Hamilton, Ontario, Canada L8N 4A6 (e-mail: shanthh@mcmaster.ca).

Copyright © 2018 the Author(s). Published by Wolters Kluwer Health, Inc. This is an open access article distributed under the terms of the Creative Commons Attribution-Non Commercial License 4.0 (CCBY-NC), where it is permissible to download, share, remix, transform, and buildup the work provided it is properly cited. The work cannot be used commercially without permission from the journal.

Medicine (2018) 97:45(e13115)

Received: 8 July 2018 / Accepted: 10 October 2018

<http://dx.doi.org/10.1097/MD.00000000000013115>

## 1. Introduction

The Ehlers–Danlos syndromes (EDSs) are a heterogeneous group of heritable connective tissue disorders characterized by joint hypermobility, skin hyperextensibility, and tissue fragility.<sup>[1–3]</sup> Joint hypermobility range of joint movement that exceeds normal for the individual's age, gender, and ethnicity can be restricted to some joints or generalized. The generalized condition is referred to as joint hypermobility syndrome (JHS). Per se, JHS is itself not considered a disease as it has a relatively benign prognosis and is considered a multifactorial trait with possible genetic basis, without specific genetic markers.<sup>[4]</sup> In EDS, however, specific genetic mutations affecting collagen or other components of the extracellular matrix lead to the above characteristics and ultimately result in its clinical manifestations, including chronic pain.

### 1.1. Epidemiology

Although EDS has been traditionally considered a rare disease, it is possibly more common. Some have observed a prevalence of 1 in 150,000 (southern English population)<sup>[5]</sup> to 1 in 5000.<sup>[5]</sup>

Others consider the prevalence to be as high as 0.75% to 2%.<sup>[6]</sup> But most agree that its frequency is probably ranges from 1% to 1 in 5000. In Ontario, 1 in 5000 people live with EDS and based on 2015 population estimates there are 2762 individuals in Ontario are affected by EDS.<sup>[3]</sup> It affects men and women of every race and ethnicity but is known to be more common among non-White populations and women.<sup>[2,7]</sup>

## 1.2. Etio-pathology of EDS

EDS is inherited, mostly as an autosomal dominant pattern, with an underlying genetic mutation affecting fibrillary collagens. This leads to a qualitative defect within the collagen causing disorderly arrangement and abnormal mechanical integrity. This fundamental defect in collagen affects all organs with the presence of collagen including joints, ligaments, skin, tendons, internal organ walls such as in blood vessels and gastrointestinal tract.<sup>[1,7]</sup> Defects in the collagen results in weakness and increased elasticity leading to the above characteristics resulting in chronic pain issues.<sup>[1,7]</sup> Depending upon the EDS type the manifestations and their consequences on individual patients vary. Major morbidity and death are commonly as a result of arterial rupture.

## 1.3. Classification

The initial classification of EDS included 6 types. More recent gene sequencing techniques have led to a revision in 2017<sup>[8]</sup> that includes 13 subtypes of EDS. Classic (Types 1 and 2) and hypermobility (Type 3) types account for almost 80% of the EDS population.<sup>[3]</sup> Since many previous literature still refer to the older Villefranche classification,<sup>[9]</sup> we present both in Table 1. Although molecular defects have been identified in 19 different genes, accounting for 12 of the 13 subtypes, the genetic basis of the most prevalent EDS (hypermobility type) has not been explained.<sup>[4]</sup> The overlapping clinical features between EDS and JHS include generalized joint hypermobility, abnormal skin signs, reoccurring joint dislocations, chronic joint/extremity pain, and a positive family history (Fig. 1).<sup>[1,2,10]</sup>

**Table 1**  
**Classification of EDS.**

Villefranche classification (genetic basis): defective collagen	2017 EDS classification
Classical (AD): Type V collagen	Classical EDS (cED) AD Classical-like EDS (clEDS) AR
Hypermobility (AD): unknown	Cardiac-valvular EDS (cvEDS) AR Vascular EDS (vEDS) AD
Vascular (AD): Type III collagen	Hypermobility EDS (hEDS) AD Arthrochalasia EDS (aEDS) AD Dermatosparaxis EDS (dEDS) AR
Kyphoscoliosis (AR): deficiency of lysyl hydroxylase	Kyphoscoliotic EDS (kEDS) AR
Arthrochalasia (AD): Type I collagen	Brittle cornea syndrome (BCS) AR Spondylodysplastic EDS (spEDS) AR Musculocontractural EDS (mcEDS) AR
Dermatosparaxis (AR): Type I collagen processing	Myopathic EDS (mEDS) AD or AR Periodontal EDS (pEDS) AD

AD = autosomal dominant, AR = autosomal recessive, EDS = Ehlers–Danlos syndrome.

## 1.4. Diagnosis

The diagnosis of EDS can be challenging. Because it is based mostly on patient's history, subtle clinical findings and a family history, a clinician must have a high degree of suspicion.<sup>[9]</sup> Most subtypes of EDS are inherited as an autosomal dominant disorder (Table 1; EDS classification/types). It is suggested that screening questions such as the mnemonic E (Ehlers) Danlos S (syndromes) (extensible skin [such as on the back of the hand]; double jointed; arm bending; nodules [typically on the extensor aspects of knees or elbows]; laxity of joints [history of joint dislocation]; odd body positions; scarring; siblings [others in the family]) are helpful.<sup>[9]</sup> The presence of joint hypermobility could be common to many heritable connective tissue diseases, including Marfan syndrome and EDS.<sup>[6]</sup> The final diagnosis relies on genetic testing. The Beighton scale is commonly used to assess the joint hypermobility in patients with EDS/JHS (Table 2).<sup>[4]</sup>

## 1.5. EDS and chronic pain

Patients with EDS can suffer from chronic pain and also be susceptible to physical trauma and stress.<sup>[2]</sup> Since this is a relatively uncommon condition affecting all over the body, management of chronic pain in these patients can be challenging. It needs careful evaluation and consideration for multidisciplinary management of pain as localized pain interventions may not be entirely helpful.<sup>[1]</sup> In this article, we highlight case history and successful pain management in 2 patients with EDS, and also review the relevant literature from the perspective of chronic pain in EDS patients and highlight the role of multidisciplinary treatment.

## 2. Case reports

Informed written consent was obtained from the patients for publication of this case report.

### 2.1. Case 1

A 41-year-old female patient was referred to our pain clinic for management of chronic multiple joint pains with a recent diagnosis of EDS-type 3. The patient worked as a laboratory technician and suffered from chronic joint pains for more than 5 years. Although she was under treatment she reported worsening pain and an inability to function. She had worse pain in both knee joints, followed by hands and wrists, and shoulders. Intensity of pain was assessed by 0 to 10cm visual analog scale (VAS) and pain interference was assessed using pain disability index (PDI).<sup>[11]</sup> Her baseline intensity of pain was 4 to 5 cm in and could get as high as 7 to 8 cm on activity. Any activity, including walking, standing, or folding laundry, would trigger increase in pain. She indicated more disability in the domains of social activity and family/home responsibilities. Her pain was worse in the mornings associated with stiffness. A genetic testing in 2016 had confirmed a diagnosis of EDS-type 3. Further elicitation of her history confirmed that she had hypermobile joints since her childhood with easy bruising on her legs, without any provocation. But she did not have a history of epistaxis, or bleeding from the gums or intra-articular bleeding. She had sustained musculoskeletal injuries before including an ankle, elbow, and humeral fracture and also had undergone ulnar nerve transposition at the age of 19. Her history revealed that she did have kinesiophobia concern about movement-related injuries as she was prescribed with exercises. Her profile did not reveal any

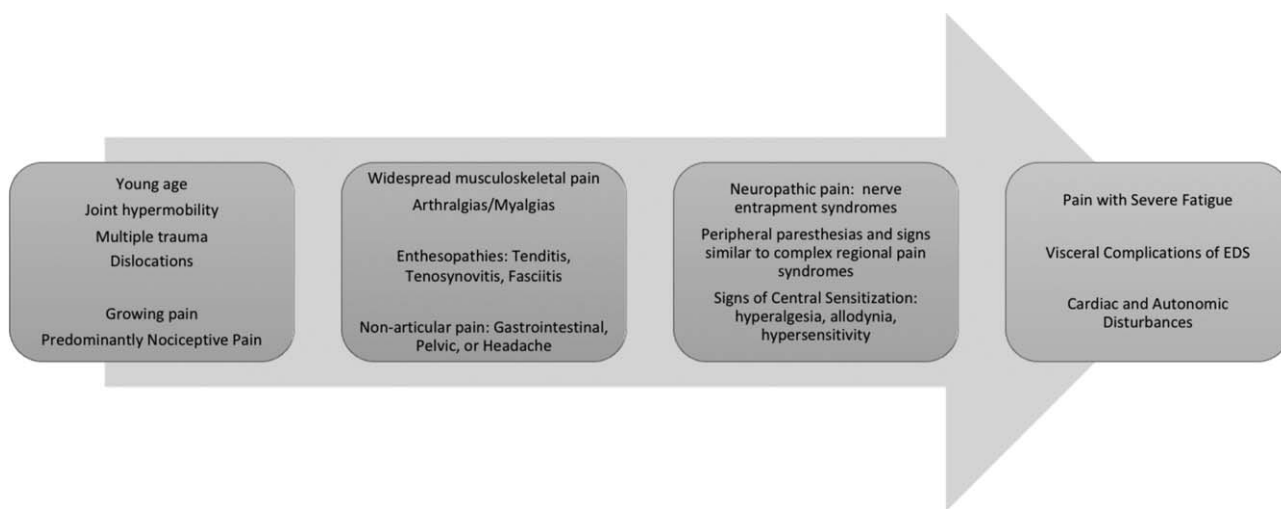


Figure 1. Characteristics of pain in Ehlers–Danlos Syndrome that progress in clinical stages.

obvious contributory psychological factors such as anxiety, depression, or high catastrophizing. She was being treated with long acting tramadol 200mg once a day along with celecoxib as a rescue medication daily. Overall, she felt that her pain relief was not better than 30% to 40% with these interventions. Her comorbidities included hypertension for which she was on medications. Her examination revealed that she had lax skin at the neck and upper chest area. No signs of swelling or injury to the joints were observed. She was not using any braces for her symptom control. We did not engage in an extended range of joint mobility for fear or possibility of subluxation.

**2.1.1. Pain clinic management.** From the very beginning, patient was assessed by a team, which included a pain physician and a nurse, a pain psychologist, and a kinesiologist (with special training in pain management), as part of our multidisciplinary pain program, as a part of pain evaluation and treatment. As a treatment strategy, the group agreed that the patient will need measures to better control her pain, improve her coping skills and decrease her kinesiophobia along with measures to stabilize her musculoskeletal symptoms. Although we considered treatment with baclofen to reduce her morning symptoms, we decided it was more appropriate to start her on a tricyclic antidepressant to decrease her pain and desensitize her symptoms. She was started

on nortriptyline 20mg bed time dose and patient was asked to continue with her tramadol in the morning and use celecoxib on as needed basis. She was provided with self-management strategies to improve her coping and use appropriate pacing techniques. She was also provided education around postural awareness and improved body mechanics, during work and relaxation. The appropriate use of kinesio-taping measures was suggested to stabilize her joints. An exercise prescription with graded exercises, including pool activity was also provided. A follow-up visit after 2 months revealed that the patient expressed significant decrease in pain intensity (VAS of 2 cm at rest and 4 cm on activity) and improvement in her ability to engage in family responsibilities and social activity. Presently, more than 18 months after the initial visit, the patient continues to be on good pain control with nortriptyline and tramadol only on a daily basis and is confident of managing her symptoms using her self-management tools.

**2.2. Case 2**

A 23-year-old, Caucasian female, with a longstanding diagnosis of EDS was referred to our pain clinic with a 6-month history of chronic right-hand and wrist pain since her last shoulder surgery. Her postoperative course was complicated by a right elbow ulcer needing to continue with the splinting for more than 6 weeks. She had moderate to severe pain, reported as 6 cm at rest and 9 cm on activity in a 0 to 10 cm VAS. She reported experiencing reduced mobility in her right wrist and associated color changes that were inconsistent. A diagnosis of complex regional pain syndrome (CRPS) was entertained in the referral based on the history of surgery and pain symptoms and was referred to our clinic for further assessment and management. Her alleviating factors included rest, hot showers, and heat or compression towels. Within PDI, she expressed significant disability in the domains of self-care, home responsibilities, social activity, and recreation. She was not on any analgesics as she would not tolerate most medications. She denied any obvious autonomic, sudomotor, or vasomotor changes. She also denied any associated tingling or burning. However, her neuropathic S-LANSS (Self-reported version-Leeds Assessment of Neuropathic Symptoms and Signs) score was 0, indicative of non-neuropathic pain (non-NP).

**Table 2**  
The Beighton Scale for assessing joint hypermobility in patients with Ehlers–Danlos syndrome.

Clinical finding	Points	Total points
Forward flexion of the trunk with knees fully extended so that the palms of the hand rest flat on the floor	1 point	1
Hyperextension of the elbows beyond 10°	1 point each elbow	2
Hyperextension of the knees beyond 10°	1 point each knee	2
Passive dorsiflexion of the little fingers beyond 90° with the arm flat on a table	1 point each finger	2
Passive apposition of the thumbs to the flexor aspect of the forearm	1 point each thumb	2

A score of 5/9 or greater defines hypermobility.

Patient's history also included chronic musculoskeletal pain in other parts of the body with hypermobility of joints and recurrent dislocations over the last 10 years. The patient reported that her pain predominantly occurred over bilateral tempo-mandibular joints (TMJ), right knee, right foot, both shoulders, hands, arms, and lower back. She described constant aching pain, with a baseline VAS score of 5 in a 0 to 10 scale, which increased to 7 on activity. Any kind of standing, walking, lifting, riding or driving or sitting in an uncomfortable position could flare up the pain. As part of her musculoskeletal management she had multiple surgeries in the past. These included bilateral shoulder repairs, the latest being the right shoulder 6 months prior to her visit to our clinic. Additionally, she had left elbow surgery, bilateral elbow ulnar nerve intramuscular transpositions. Due to the complex and widespread nature of her pain she was also seeing other healthcare professionals, including a chiropractor, neurologist, foot orthopedic surgeon, and physiotherapist on a regular basis. She had also been seeing a dental specialist due to her ongoing TMJ pain issues. Interestingly, the patient had undergone a pulsed radiofrequency procedure 6 weeks ago for ongoing right foot and ankle pain. Patient reported that this resulted in flare up of her aching pain in the ankle with new radiating pain to bottom of the foot. She was currently using orthotics and air-cast to manage her foot pain. Patient requested that we also assess her to manage her generalized musculoskeletal pain besides her hand pain for which she was referred.

On examination, the patient was found to be obese and we did not see any color changes in her affected hand. There was no evidence of swelling or tremors. There was joint laxity of her extremities. No other extra-articular features or signs were noted. Examination was limited due to patients concerns for worsening pain with movement. Evidence of scars from multiple previous surgeries was visible with appropriate healing. As no obvious signs of CRPS were visible, the patient did not meet the criteria for CRPS at the time of the visit.

**2.2.1. Pain clinic management.** Similar to our previous patient, she was evaluated as part of our multidisciplinary pain program. We initiated our treatment with simple measures for pain control using conventional analgesics including round the clock acetaminophen 650mg TID and anti-inflammatory medication in the form of Celecoxib 100mg on as needed basis. Patient was motivated to join our self-management group that involves attending 6 dedicated sessions on cognitive behavioral therapy and exercise program. Her participation in the program provided her with pain education, self-management tools for symptom control, and improved her coping strategies. Patient was also provided with tools for physical and mental relaxation including mindfulness. Since patient's clinical findings did not suggest CRPS, no sympathetic blocks were offered. After completing the self-management program, patient indicated significant improvement in her pain symptoms, with her pain intensity decreased to 3 cm at rest and 4cm on activity and to allow her to engage in appropriate physical activities.

### 3. Discussion

#### 3.1. Chronic pain and EDS

Chronic pain is common in EDS, particularly in the hypermobility type.<sup>[12]</sup> As seen in our case report, it is strongly related to reduced quality of life and physical disability.<sup>[5,13]</sup> According to 1 study, nearly 90% of patients report some form of chronic pain.<sup>[5]</sup> Pain issues are usually the presenting symptoms of this

illness. For example, Ontario's new EDS clinic at University Health Networks reports receiving 80% of its referrals from chronic pain clinics in the Greater Toronto area. The common characteristics of chronic pain in EDS and sequence of symptom changes are summarized in Fig. 1. Mechanisms involved include nociceptive, neuropathic, central sensitization (CS), and associated psychological traits, all of which were present in the case reports. We looked at studies reporting pain due to EDS in Medline and summarize the types of pain and their possible incidence in Table 3.

**3.1.1. Musculoskeletal pain.** Nociceptive, joint pain is usually the first manifestation of pain in EDS.<sup>[1,2]</sup> Patients most commonly report their very first painful sensations acutely, as a result from joint traumas such as dislocations and sprains as well as "growing pains."<sup>[1,2]</sup> The most commonly involved joints are the shoulder (80%), hands (75%), and knees (71%).<sup>[5]</sup> As in our patient, foot pain is an additional strongly debilitating pain.<sup>[2]</sup> Hands (especially thumb) and arm pain results in significant disability with writing and holding objects. Patients with EDS describe themselves as "Klutzy" often dropping objects and falling.<sup>[26]</sup> TMJ pain can also be a significant source in disability in 70% of Ehlers–Danlos patients as in the second case report. The recurrent dislocations due to joint laxity and associated trauma are further amplified by poor proprioception.<sup>[1,2,5]</sup> The fear of falling and kinesiophobia are common complaints.<sup>[2,5,13,27]</sup> Severe chronic fatigue is now considered a common accompanying feature of EDS. It is reported in up to 95% of patients and in many cases was reported by patients to be more debilitating than pain.<sup>[5]</sup> The frequency of fatigue is influenced by age with a rate of 28% in the first decade of life to 90% in adults over 40 years of age.<sup>[2]</sup>

**3.1.2. Neuropathic pain and central sensitization.** Approximately 68% of chronic pain patients with EDS can be considered to have NP.<sup>[5]</sup> Compression and axonal neuropathies have been suggested as a potential cause of paresthesia, numbness, and dysesthesia in EDS patients.<sup>[1,2,5,12]</sup> Additionally, subluxation of the ulnar nerve occurs more commonly in EDS.<sup>[1]</sup> Many patients describe NP also at rest and with strongly bilateral presentation which is not usually in keeping with compression neuropathies. This could be due to generalized small fiber neuropathy or evidence of CS. Cazzato et al<sup>[21]</sup> demonstrated that, irrespective of EDS subtype, patients with clinical features suggestive of NP may show decreased intraepidermal nerve fiber density indicative of small fiber neuropathy. Development of CS is usually at a later stage due to the persistent nociceptive input caused by joint abnormalities<sup>[28,29]</sup> or changes within the extracellular matrix due to repeated injuries.<sup>[30]</sup> Features suggestive of CS include generalized hyperalgesia, low sensory thresholds, and increased wind-up to repeated stimuli.<sup>[7]</sup> Fibromyalgia, a widespread musculoskeletal pain syndrome commonly associated with CS, occurs in 42% of adults EDS.<sup>[1,2]</sup> Our patient had been referred for query CRPS. Stoler and Oaklander<sup>[31]</sup> reporting 4 such cases, postulate that EDS can predispose to the development of CRPS due to stretch injury to nerves, increased fragility of nerve connective tissue, or nerve trauma from more frequent surgeries.

**3.1.3. Pain and psychological issues.** Psychological distress, fatigue, and sleep disturbances are common comorbidities and their presence may negatively affect pain manifestations and evolution, and ultimately contributing to chronic pain and disability.<sup>[5]</sup> The literature review conducted by the international



**Table 3****Reported manifestations of pain in Ehlers–Danlos syndrome and their incidences reported in studies published in Medline between 2010 and 2018.**

Manifestations	No. of patients studied	Prevalence, %	Type of study	Author (year)
Generalized pain	246	90	Cross-sectional	Voermans (2010) <sup>[12]</sup>
	52	96	Cross-sectional	Johannessen (2016) <sup>[14]</sup>
	33	100	Case–control	Rombaut (2015) <sup>[15]</sup>
Temporomandibular disorders	14	92.9	Case–control	Diep (2016) <sup>[16]</sup>
Headache	250	48	Cross-sectional	Maeland (2011) <sup>[17]</sup>
	27	29.6	Cross-sectional	Rombaut (2010) <sup>[18]</sup>
Dislocations	273	70.7	Cross-sectional	Voermans (2010) <sup>[12]</sup>
	27	96.3	Cross-sectional	Rombaut (2010) <sup>[18]</sup>
Musculoskeletal pain	250	Leg (64.4)	Cross-sectional	Maeland (2011) <sup>[17]</sup>
		Lower back (62.4)		
		Neck (61.6)		
		Upper back (52.8)		
		Shoulder (52.4)		
		Arm (46)		
		Joint pain (100)	Cross-sectional	Rombaut (2010) <sup>[18]</sup>
		Muscular pain (29.6)		
		Vertebral (38.5)	Cross-sectional	Mazziotti (2016) <sup>[19]</sup>
		Fractures	52	68
Neuropathic pain	44	48	Case–control	Rombaut (2015) <sup>[15]</sup>
	33	95	Cohort/experimental	Cazzato (2016) <sup>[21]</sup>
	29	30.9	Retrospective chart review	Nelson (2015) <sup>[22]</sup>
Abdominal pain	687	31.6	Cross-sectional	Maeland (2011) <sup>[17]</sup>
	250	43	Cross-sectional	Fikree (2016) <sup>[23]</sup>
	74	77	Cross-sectional	Voermans (2010) <sup>[12]</sup>
Fatigue	273	78.4	Cross-sectional	Maeland (2011) <sup>[17]</sup>
	250	25.9	Cross-sectional	Robaut (2010) <sup>[18]</sup>
	27	92.5	Cross-sectional	Hurst (2014) <sup>[24]</sup>
Dysmenorrhea	1125	72	Cross-sectional	Hugon-Rodin (2016) <sup>[25]</sup>
Vulvodynia, dyspareunia	386	77	Cross-sectional	Hurst (2014) <sup>[24]</sup>
	1125	43	Cross-sectional	Hugon-Rodin (2016) <sup>[25]</sup>
	386			

consortium for EDS highlights a high prevalence of anxiety (70%) and panic disorder in patients with EDS.<sup>[32]</sup> In a recent study, the overall use of psychotropic drugs to treat these conditions was 41.4% in EDS subjects compared with 13.9% in controls.<sup>[32]</sup> There is also growing evidence to suggest its association with depression and demonstrate a statistically significant link with bipolar disorder, autism spectrum disorder, and attention deficit hyperactivity disorder.<sup>[2,13,32]</sup> The underlying mechanisms behind this association include genetic risks, autonomic nervous system dysfunction, and decreased proprioception. Maladaptive behaviors such as pain catastrophizing, kinesiophobia, and fear avoidance are also prevalent in this population and can be a barrier to effective pain control as was present in Case 1.<sup>[1,2,5,26]</sup>

### 3.2. Management

Most cases of chronic pain in EDS are a mix of nociceptive and NP.<sup>[5]</sup> Considering the overlay of other issues, multidisciplinary approach is often necessary for these complex patients.<sup>[2]</sup> As symptoms vary based on the diseases phase and in individuals of EDS, broad recommendations in a patient with EDS or JHS include prevention of joint and muscle injury; treatment of acute pain; preventing persistent or chronic pain; treating chronic pain; and optimization of overall health and improvement in fatigue. Specific to chronic pain, 1 can consider the management from following perspectives: pain medications, psychotherapy, physi-

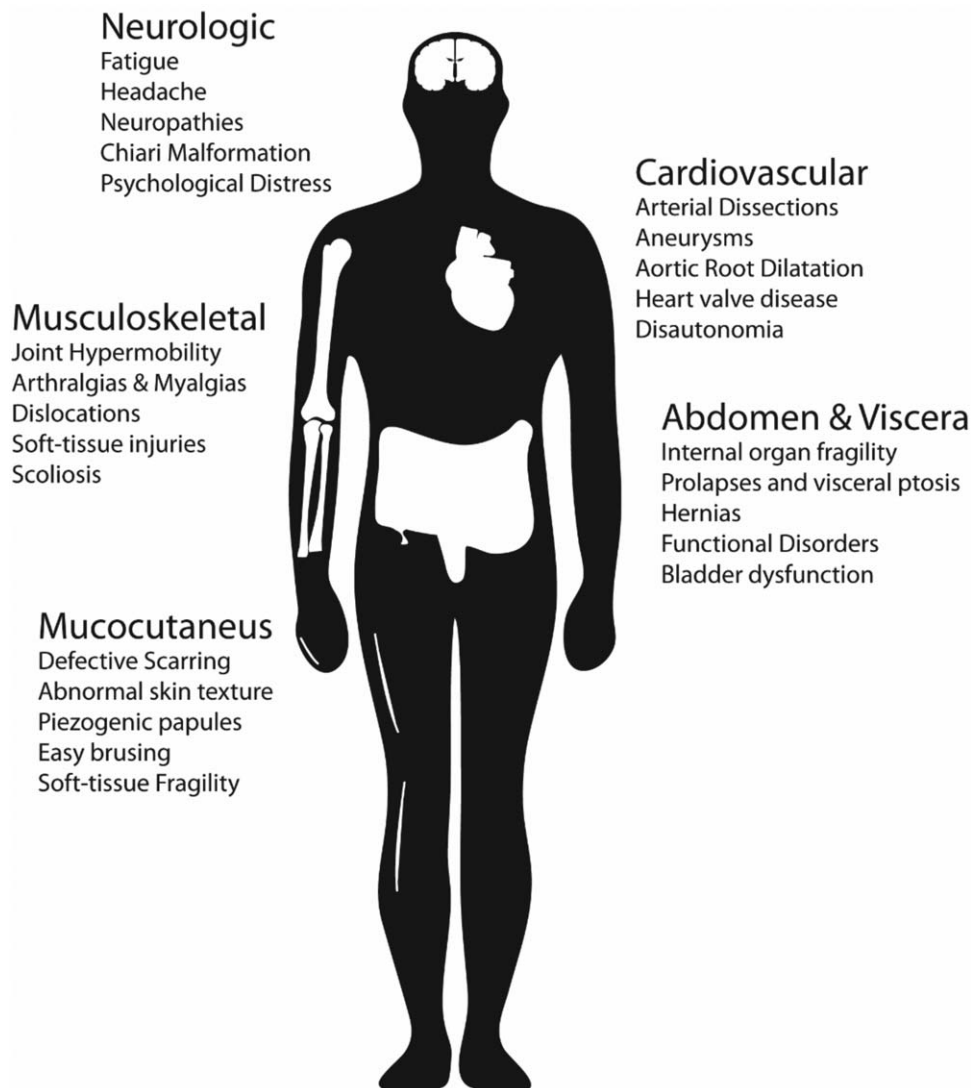
cal therapy, pain interventions and surgery, education and life style changes, and management of comorbidities.<sup>[2]</sup>

**3.2.1. Medications.** Recommendations based on the efficacy of pain medications for use in the treatment of EDS patients are limited by the lack of evidence. International consortium has published recent literature on commonly used medication strategies. Tylenol and nonsteroidal anti-inflammatory medications (NSAIDs) are suggested for mild to moderate pain.<sup>[5]</sup> They are especially useful in the presence of inflammatory pain and can be quite effective, as with our patient. However, the use of NSAIDs is limited due to poor tolerance secondary to comorbid gastrointestinal issues in EDS patients.<sup>[2,5]</sup> Opioids may be an option, but only for a short duration. There is good evidence that long-term treatment with opiates is not a viable option and may lead to central pain sensitization.<sup>[5]</sup> Tramadol with its opioid and serotonergic effects could be considered as an alternative. Tramadol was successful in controlling pain symptoms and improve physical capacity in children with EDS.<sup>[33]</sup> Steroids have been found to be helpful in acute exacerbation of joint pains. However, care must be taken to avoid long-term use to prevent steroid-related side effects. No trials have been conducted to test medications for NP in EDS patients. Usual options such as tricyclic antidepressants, anticonvulsants, serotonin and norepinephrine reuptake inhibitors, and other antidepressants may be used with caution given increased risk of dysautonomia in EDS.<sup>[13,28]</sup> Muscle relaxants such as baclofen can be helpful for

painful muscle spasms, but are discouraged for routine use due to theoretical risk of increasing joint instability and consequently worsening pain.<sup>[26]</sup> No evidence exists regarding the use of medical marijuana in the treatment of EDS patients. Anecdotally it works better than opioids. Further research is needed to clarify the role of ever-increasing medical marijuana in these patients.<sup>[26]</sup> Overall expert consensus indicates that pharmacological treatments are often not effective in the long-term treatment.<sup>[1,2,5,13,26,34]</sup>

**3.2.2. Physical therapy.** Within the multidisciplinary team, physical therapy plays a central role in management of individuals with EDS.<sup>[1,2,5,10,26,27,34]</sup> However, many physical therapists are not familiar with the diagnostic criteria, prevalence, common clinical presentation, and management of EDS.<sup>[27]</sup> The main objective of rehabilitation is to reduce disability and to improve quality of life. As per the international consortium the current evidence-basis for physical therapy assessment and management of EDS is limited and of poor quality. As a general recommendation, therapists should be guided by clinical

reasoning and assessment and treatment should be tailored to the individual patient's needs.<sup>[27]</sup> Although scientific data are not yet available, EDS patients perceive the use of splints and braces, and massage therapies efficacious for the management of acute and chronic pain.<sup>[2,3,26]</sup> Techniques that have been used in treating EDS pain include manual therapy for overactive muscles, trunk stabilization, posture re-education, joint awareness using biofeedback, and joint mobilization with muscle release.<sup>[5,27]</sup> Treating the underlying proprioceptive disorder with compressive clothing, physiotherapy, and proprioceptive shoe inserts has also been shown to be of benefit.<sup>[5]</sup> As a rule, stretching exercises should be limited to gentle stretching to avoid any risks of subluxations or dislocations.<sup>[5,27]</sup> Neuromuscular Taping (Kinesio) of any joint involved can be undertaken by a trained physiotherapist. The mechanism underlying the improvement proprioception and joint stability with taping is unclear but may involve stimulation of receptors in the skin with movement. Subjectively many EDS patients report positive outcomes with neuromuscular taping as did our patient.<sup>[26]</sup> TMJ pain is prevalent in EDS patient and requires referral to orthodontist



**Figure 2.** Systemic comorbidities in Ehlers–Danlos Syndrome.

with current suggestion of avoidance of over the counter mouth guards.<sup>[5]</sup> Foot pain requires referral to chiroprapist for custom made orthotics in addition to appropriate exercises.<sup>[26]</sup>

**3.2.3. Psychotherapy.** The prevalence of comorbid psychiatric, sleep, and fatigue disorder is clear in EDS. The psychiatric and psychosocial issues have to be explored and properly evaluated in these patients. Pain, negative feelings, and poor emotion regulation are frequently associated with this condition.<sup>[32]</sup> The international consortium recommends utilizing cognitive behavioral therapy (CBT) in EDS patients.<sup>[5,32]</sup> To date, there have been no clinical trials to demonstrate its efficacy in EDS.<sup>[32]</sup> However, the CBT approach is applicable to all patients especially those whose pain is intractable, life dominating, and unresponsive to analgesics or other physical interventions.<sup>[2,5,32]</sup> CBT has proven efficacy in EDS-related disorders such as anxiety, depression, and fibromyalgia. In the setting of EDS, CBT can help patients in learning how to live with their untreatable disorder. As with our patient, this key component of treatment had been overlooked, which was subsequently incorporated by our psychologist led group therapy program.

**3.2.4. Education and life style changes.** Despite the lack of major studies physical therapy and lifestyle modifications are considered one of the most successful strategies for managing pain in EDS. There is lack of understanding about the disease and its progression among many families. Patients need to be provided genetic counseling. Education should also include information on strategies to prevent joint injury, improved work ergonomics, improving muscle tone and function without overuse, avoid smoking, and weight control and sleep hygiene.<sup>[2,5,32]</sup>

**3.2.5. Pain interventions and surgery.** Pain interventions frequently involve nerve blocks and neuromodulatory procedures such as radiofrequency interventions. EDS patients are traditionally recognized to have resistance to local anesthetic agents.<sup>[35,36]</sup> However, recent reports state that this generalized caution is unwarranted.<sup>[37]</sup> Potentially, radiofrequency treatments can improve pain and function by targeting nerves supplying major joints. However, their long-term efficacy and safety are not established.<sup>[38]</sup> Patients with EDS can be considered for orthopedic peripheral joint reconstruction surgeries. Presently, there is mixed evidence on the efficacy of orthopedic surgery to treat moderate to severe joint pain symptoms.<sup>[39,40]</sup>

**3.2.6. Management of comorbidities.** EDS patients are known to suffer from comorbidities involving gastrointestinal, genitourinary, neurological, cardiovascular, and psychological comorbidities that can secondarily affect their chronic pain issues or symptoms (Fig. 2). Multidisciplinary care involving a team approach allows for better identification of these issues and appropriate physician referral and management.

#### 4. Conclusion

Chronic pain in patients with EDS is complex with poorly understood underlying pathophysiology. Pharmacological management is limited by lack of evidence and current treatments are supported by extrapolation of data from studies in non-EDS patients. Although physical and psychological therapies are considered effective, therapeutic standards are missing. Proper training for healthcare professionals to deliver these therapies is

still lacking. Early diagnosis and education are important to improve quality of life and limit the progression of EDS. Healthcare professionals working predominantly in pain medicine have the important responsibility of identifying and referring patients with suspicion for EDS to an appropriate neuromuscular clinic. The variety and complexity of symptoms in EDS requires emphasis on the multidisciplinary approach which requires added resources. Our understanding and management of the often severe, evolving, debilitating pain in patients with EDS is currently insufficient and requires further research.<sup>[5]</sup>

#### Author contributions

**Conceptualization:** Abhitej Rewari, Harsha Shanthanna.

**Data curation:** Zhengyang Zhou, Harsha Shanthanna.

**Investigation:** Zhengyang Zhou, Abhitej Rewari, Harsha Shanthanna.

**Methodology:** Zhengyang Zhou.

**Supervision:** Harsha Shanthanna.

**Validation:** Harsha Shanthanna.

**Visualization:** Zhengyang Zhou.

**Writing – original draft:** Abhitej Rewari.

**Writing – review & editing:** Zhengyang Zhou, Harsha Shanthanna.

#### References

- Castori M, Morlino S, Celletti C, et al. Management of pain and fatigue in the joint hypermobility syndrome (a.k.a. Ehlers–Danlos syndrome, hypermobility type): principles and proposal for a multidisciplinary approach. *Am J Med Genet A* 2012;158A:2055–70.
- Castori M. Pain in Ehlers–Danlos syndromes: manifestations, therapeutic strategies and future perspectives. *Expert Opin Orphan Drugs* 2016;4:1145–58.
- Critical Care Services Ontario Ehlers–Danlos Expert Panel Report: Final Report: Report to the Ministry of Health and Long-Term Care. Toronto, Ontario: Ontario Ministry of Health and Long-Term Care; 2015.
- Syx D, De Wandele I, Rombaut L, et al. Hypermobility, the Ehlers–Danlos syndromes and chronic pain. *Clin Exp Rheumatol* 2017;35:116–22.
- Chopra P, Tinkle B, Hamonet C, et al. Pain management in the Ehlers–Danlos syndromes. *Am J Med Genet C Semin Med Genet* 2017;175:212–9.
- Hakim AJ, Sahota A. Joint hypermobility and skin elasticity: the hereditary disorders of connective tissue. *Clin Dermatol* 2006;24:521–33.
- Tewari S, Madabushi R, Agarwal A, et al. Chronic pain in a patient with Ehlers–Danlos syndrome (hypermobility type): the role of myofascial trigger point injections. *J Bodyw Mov Ther* 2017;21:194–6.
- Brady AF, Demirdas S, Fournel-Gigleux S, et al. The Ehlers–Danlos syndromes, rare types. Paper presented at: American Journal of Medical Genetics Part C: Seminars in Medical Genetics; 2017.
- Joseph AW, Joseph SS, Francomano CA, et al. Characteristics, diagnosis, and management of Ehlers–Danlos syndromes: a review. *JAMA Facial Plast Surg* 2018;20:70–5.
- Strunk RG. Multimodal chiropractic care for pain and disability in a patient diagnosed with Ehlers–Danlos syndrome-hypermobility type: a case report. *J Chiropr Med* 2017;16:147–55.
- Tait RC, Chibnall JT, Krause S. The pain disability index: psychometric properties. *Pain* 1990;40:171–82.
- Voermans NC, Knoop H, Bleijenberg G, et al. Pain in Ehlers–Danlos syndrome is common, severe, and associated with functional impairment. *J Pain Symptom Manage* 2010;40:370–8.
- Scheper MC, de Vries JE, Verbunt J, et al. Chronic pain in hypermobility syndrome and Ehlers–Danlos syndrome (hypermobility type): it is a challenge. *J Pain Res* 2015;8:591–601.
- Johannessen EC, Reiten HS, Lovaas H, et al. Shoulder function, pain and health related quality of life in adults with joint hypermobility syndrome/Ehlers–Danlos syndrome-hypermobility type. *Disabil Rehabil* 2016;38:1382–90.

- [15] Rombaut L, Scheper M, De Wandele I, et al. Chronic pain in patients with the hypermobility type of Ehlers–Danlos syndrome: evidence for generalized hyperalgesia. *Clin Rheumatol* 2015;34:1121–9.
- [16] Diep D, Fau V, Wdowik S, et al. Temporomandibular disorders and Ehlers–Danlos syndrome, hypermobility type: a case-control study. *Rev Stomatol Chir Maxillofac Chir Orale* 2016;117:228–33.
- [17] Maeland S, Assmus J, Berglund B. Subjective health complaints in individuals with Ehlers–Danlos syndrome: a questionnaire study. *Int J Nurs Stud* 2011;48:720–4.
- [18] Rombaut L, Malfait F, Cools A, et al. Musculoskeletal complaints, physical activity and health-related quality of life among patients with the Ehlers–Danlos syndrome hypermobility type. *Disabil Rehabil* 2010;32:1339–45.
- [19] Mazziotti G, Dordoni C, Doga M, et al. High prevalence of radiological vertebral fractures in adult patients with Ehlers–Danlos syndrome. *Bone* 2016;84:88–92.
- [20] Camerota F, Celletti C, Castori M, et al. Neuropathic pain is a common feature in Ehlers–Danlos syndrome. *J Pain Symptom Manage* 2011;41:e2–4.
- [21] Cazzato D, Castori M, Lombardi R, et al. Small fiber neuropathy is a common feature of Ehlers–Danlos syndromes. *Neurology* 2016;87:155–9.
- [22] Nelson AD, Mouchli MA, Valentin N, et al. Ehlers–Danlos syndrome and gastrointestinal manifestations: a 20-year experience at Mayo Clinic. *Neurogastroenterol Motil* 27:1657–66.
- [23] Fikree A, Aktar R, Morris JK, et al. The association between Ehlers–Danlos syndrome-hypermobility type and gastrointestinal symptoms in university students: a cross-sectional study. *Neurogastroenterol Motil* 2017;29:e12942.
- [24] Hurst BS, Lange SS, Kullstam SM, et al. Obstetric and gynecologic challenges in women with Ehlers–Danlos syndrome. *Obstet Gynecol* 2014;123:506–13.
- [25] Hugon-Rodin J, Lebegue G, Becourt S, et al. Gynecologic symptoms and the influence on reproductive life in 386 women with hypermobility type Ehlers–Danlos syndrome: a cohort study. *Orphanet J Rare Dis* 2016;11:124.
- [26] Chopra P. Pain Management in Ether Danlos. In: Brown University. Providence, Rhode island; 2015.
- [27] Engelbert RH, Juul-Kristensen B, Pacey V, et al. The evidence-based rationale for physical therapy treatment of children, adolescents, and adults diagnosed with joint hypermobility syndrome/hypermobility Ehlers–Danlos syndrome. *Am J Med Genet C Semin Med Genet* 2017;175:158–67.
- [28] Di Stefano G, Celletti C, Baron R, et al. Central sensitization as the mechanism underlying pain in joint hypermobility syndrome/Ehlers–Danlos syndrome, hypermobility type. *Eur J Pain* 2016;20:1319–25.
- [29] Nijs J, Paul van Wilgen C, Van Oosterwijck J, et al. How to explain central sensitization to patients with “unexplained” chronic musculoskeletal pain: practice guidelines. *Man Ther* 2011;16:413–8.
- [30] Tajerian M, Clark JD. The role of the extracellular matrix in chronic pain following injury. *Pain* 2015;156:366–70.
- [31] Stoler JM, Oaklander AL. Patients with Ehlers–Danlos syndrome and CRPS: a possible association? *Pain* 2006;123:204–9.
- [32] Bulbena A, Baeza-Velasco C, Bulbena-Cabre A, et al. Psychiatric and psychological aspects in the Ehlers–Danlos syndromes. *Am J Med Genet C Semin Med Genet* 2017;175:237–45.
- [33] Brown SC, Stinson J. Treatment of pediatric chronic pain with tramadol hydrochloride: siblings with Ehlers–Danlos syndrome—hypermobility type. *Pain Res Manage* 2004;9:209–11.
- [34] Bem-Haja PL, Canga JC, Abreu YLd, et al. Síndrome de Ehlers–Danlos em paciente com dor crônica. Relato de caso. *Revista Dor* 2016;17:152–4.
- [35] Arendt-Nielsen L, Kaalund S, Bjerring P, et al. Insufficient effect of local analgesics in Ehlers Danlos type III patients (connective tissue disorder). *Acta Anaesthesiol Scand* 1990;34:358–61.
- [36] Arendt-Nielsen L, Kaalund S, Hogsaa B, et al. The response to local anaesthetics (EMLA-cream) as a clinical test to diagnose between hypermobility and Ehlers Danlos type III syndrome. *Scand J Rheumatol* 1991;20:190–5.
- [37] Patzkowski MS. Peripheral nerve blocks in patients with Ehlers–Danlos syndrome, hypermobility type: a report of 2 cases. *J Clin Anesth* 2016;29:50–3.
- [38] Hernandez-Gonzalez L, Calvo CE, Atkins-Gonzalez D. Peripheral nerve radiofrequency neurotomy: hip and knee joints. *Phys Med Rehabil Clin N Am* 2018;29:61–71.
- [39] Rombaut L, Malfait F, De Wandele I, et al. Medication, surgery, and physiotherapy among patients with the hypermobility type of Ehlers–Danlos syndrome. *Arch Phys Med Rehabil* 2011;92:1106–12.
- [40] Hammarstedt JE, Redmond JM, Gupta A, et al. Arthroscopic ligamentum teres reconstruction of the hip in Ehlers–Danlos syndrome: a case study. *Hip Int* 2015;25:286–91.