

Recent classifications of the common bile duct injury

Kwangsik Chun

Department of Surgery, Chungnam National University Hospital, Daejeon, Korea

Laparoscopic cholecystectomy is now a gold standard treatment modality for gallstone diseases. However, the incidence rate of bile duct injury has not been changed for many years. From initial classification published by Bismuth, there have been many classifications of common bile duct injury. The initial classification, levels and types of bile duct injury, and currently combined vascular injuries are reviewed here. ([Korean J Hepatobiliary Pancreat Surg 2014;18:69-72](#))

Key Words: Bile duct injury; Classification; Laparoscopic cholecystectomy

INTRODUCTION

Since its introduction, laparoscopic cholecystectomy has become the gold standard treatment for gallstone disease.¹ However, the incidence rate of bile duct injury (BDI) has risen from 0.06% to 0.3%. Open cholecystectomy has risen from 0.5% to 1.4% when gallbladder removal is performed laparoscopically.²⁻¹² In initial studies on the removal of laparoscopic gallbladder, complications such as bleeding, wound infection, respiratory insufficiency, trocar injury to the intra-abdominal viscera, major vascular injury, and bile leaking accounted for reported morbidity rate ranging from 1.0% to 8.0%.²⁻⁸ Despite the completion of the learning curve and the recognition of preventive maneuvers to avoid ductal injury during laparoscopic cholecystectomy, the incidence rate of BDI remains unchanged.¹³ In addition, injuries of the bile duct system after laparoscopic cholecystectomy are more complex than that after an open approach, causing significant morbidity and even death. Associated vascular lesions, particularly injuries to the right hepatic artery or longitudinal strictures of the common bile duct due to failed repair attempts, are not uncommon. Various classifications of bile duct injuries after laparoscopic cholecystectomy were reviewed in this article.

CLASSIFICATION OF BILE DUCT INJURY

Bismuth classification

The first classification of bile duct injury is authored by H. Bismuth in 1982. Up to now, a number of classifications have been proposed by different authors. The Bismuth classification is a simple classification based on the location of the injury in the biliary tract. This classification is very helpful in prognosis after repair. This classification included five types of bile duct injuries according to the distance from the hilar structure especially bile duct bifurcation, the level of injury, the involvement of bile duct bifurcation, and individual right sectoral duct.¹⁴ Type I involves the common bile duct and low common hepatic duct (CHD) >2 cm from the hepatic duct confluence. Type II involves the proximal CHD <2 cm from the confluence. Type III is hilar injury with no residual CHD confluence intact. Type IV is destruction of the confluence when the right and left hepatic ducts become separate. Type V involves the aberrant right sectoral hepatic duct alone or with concomitant injury of CHD. However, the Bismuth classification does not include the wide spectrum of possible biliary injuries.

Received: July 14, 2014; **Revised:** August 11, 2014; **Accepted:** August 13, 2014

Corresponding author: Kwangsik Chun

Department of Surgery, Chungnam National University Hospital, 282 Munwharo, Jung-gu, Daejeon, Korea
Tel: +82-42-280-7185, Fax: +82-42-257-8024, E-mail: oxali@hanmail.net

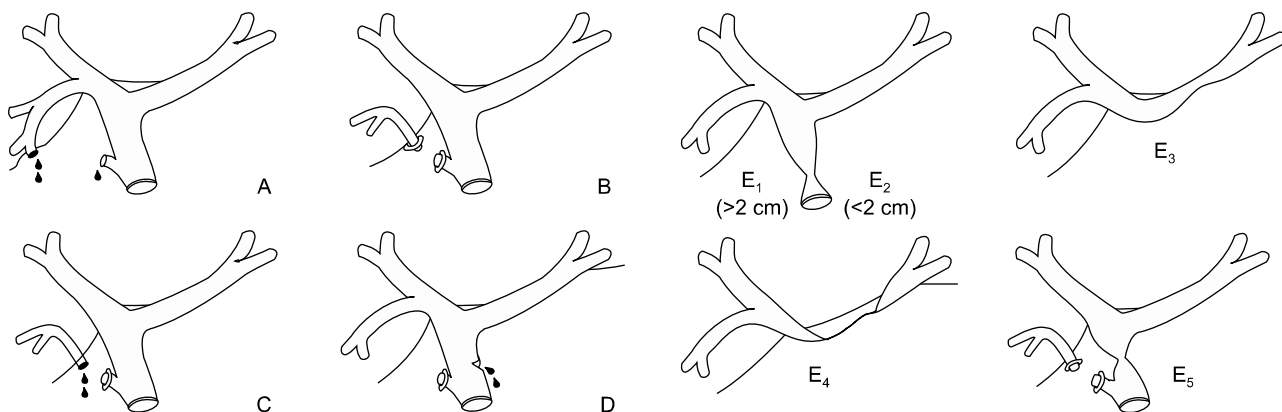


Fig. 1. Strasberg classification.^{3,22} (A) Bile leak from cystic duct stump or minor biliary radical in gallbladder fossa. (B) Occluded right posterior sectoral duct. (C) Bile leak from divided right posterior sectoral duct. (D) Bile leak from main bile duct without major tissue loss. (E₁) Transected main bile duct with a stricture more than 2 cm from the hilus. (E₂) Transected main bile duct with a stricture less than 2 cm from the hilus. (E₃) Stricture of the hilus with right and left ducts in communication. (E₄) Stricture of the hilus with separation of right and left ducts. (E₅) Stricture of the main bile duct and the right posterior sectoral duct.

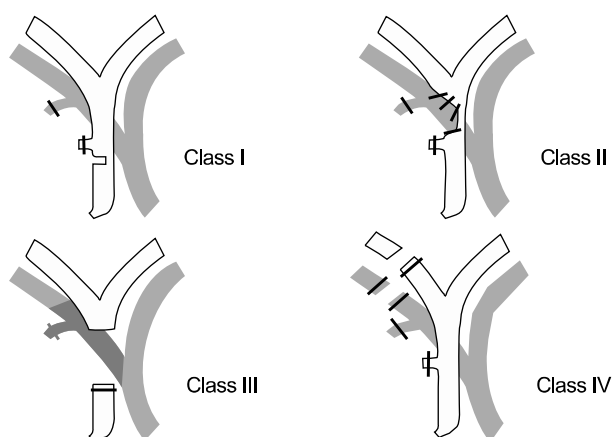


Fig. 2. Stewart-Way classification.¹⁵

Strasberg classification

The Strasberg classification is a modification of the Bismuth classification, but allows differentiation between small (bile leakage from the cystic duct or aberrant right sectoral branch) and serious injuries performed during laparoscopic cholecystectomy as type A to D. Type E of the Strasberg classification is an analogue of the Bismuth classification.³ The Strasberg classification, summarized in Fig. 1, is very simple which can be easily applied to bile duct injuries. The major disadvantage of the Strasberg classification is that it does not describe additional vascular involvement at all. For this reason, the Strasberg classification could not demonstrate a significant association between the discrimination of specific injury patterns

and the resection of liver tissues.

McMahon classification

McMahon et al. proposed another classification of bile duct injuries after laparoscopic cholecystectomy. They classified the injury by the width of bile duct injury. Based on the McMahon classification, lacerations under 25% of the common bile duct (CBD) diameter or cystic-CBD junction was classified as minor injury, whereas transection or laceration over 25% of CBD diameter and postoperative bile duct stricture were classified as major injury.²

Stewart-Way classification

Bile duct injuries fall into four classes based on the Stewart-Way classification.¹⁵ Class I injury occurs when CBD is mistaken for the cystic duct, but the error is recognized before CBD is divided. Class II injuries involve damage to CHD from clips or cautery used too close to the duct. This often occurs in cases where visibility is limited due to inflammation or bleeding. Class III injury, the most common type, occurs when CBD is mistaken for the cystic duct. The common duct is transected and a variable portion including the junction of the cystic and common duct is excised or removed. Class IV injuries involve damage to the right hepatic duct (RHD), either because this structure is mistaken for the cystic duct, or because it is injured during dissection (Fig. 2). Both complex bile

duct and vascular injuries were included in the Stewart-Way classification.

Hannover classification

Bektas et al. proposed a new classification system named Hannover classification after comparing the classification of bile duct injury for consecutive 72 iatrogenic bile injuries after laparoscopic cholecystectomy. In the Hannover, bile duct injuries were divided into five types from A to E.¹⁶ Type A is peripheral bile leakage. Type B is stricture of CHD or CBD without injury. Type C is lateral CHD or CBD injury. Type D is total transection of CHD. Type E is bile duct stricture of the main bile duct without bile leakage at postoperative state. Vascular injuries are included in Type C and Type D (Fig. 3). The

Hannover classification distinguished a total of 21 injury patterns in a small group of patients. The advantage of the Hannover classification is that it has a high level of statistical significance to demonstrate the association between the discrimination of classifiable injury patterns and the surgical treatments chosen. Other classification systems could only distinguish fewer injury patterns. Furthermore, with the Hannover classification, there were significant associations between the discrimination of specific injury patterns and the resection of liver tissue as well as resection of the bifurcation of the hepatic duct. The advantage of the Neuhaus' classification may be the ability to discriminate different injury patterns and recurrent cholangitis in the long-term. This Hannover classification provides discriminators for the localization of tan-

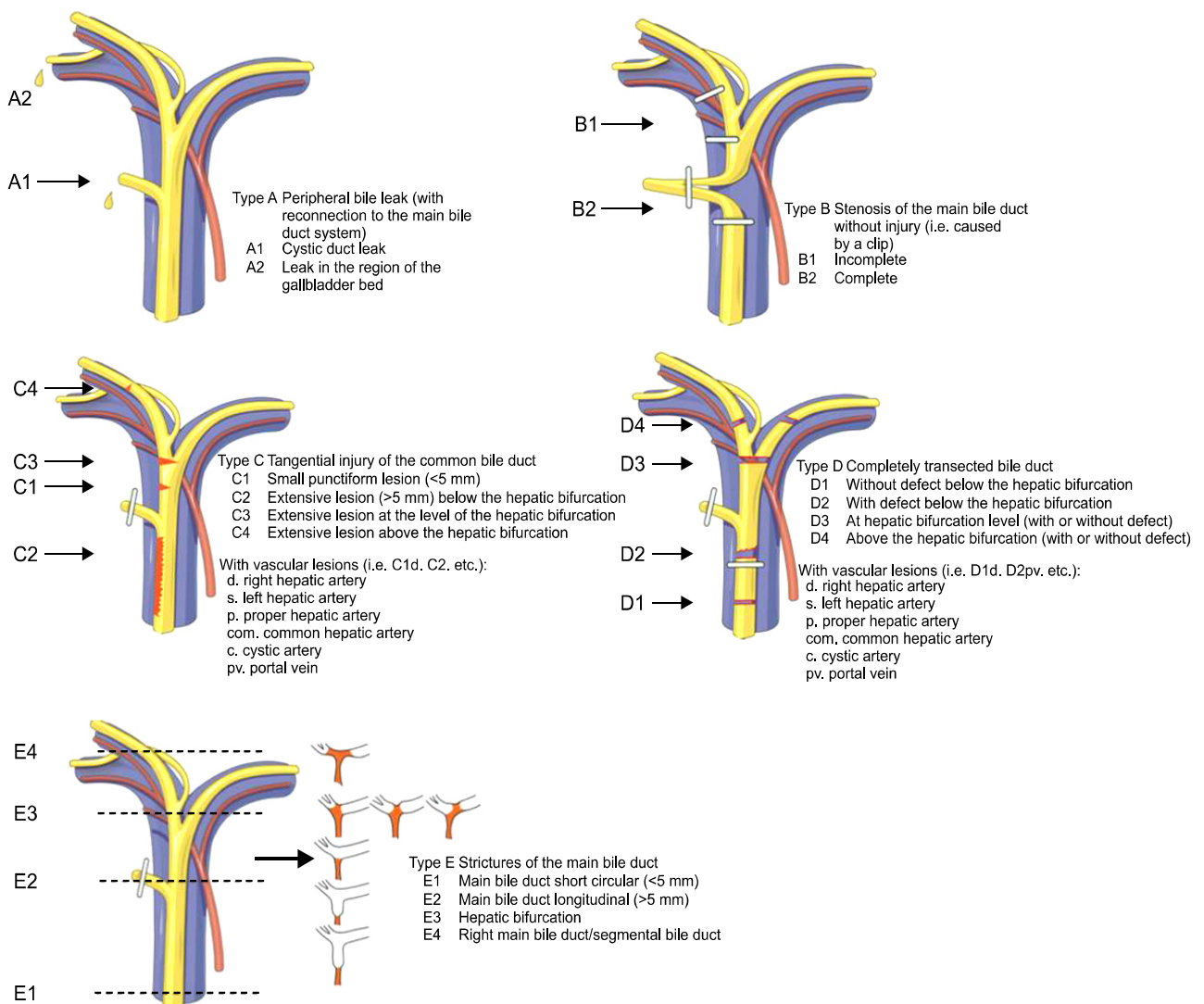


Fig. 3. Hannover classification.¹⁶

gentially or completely transected bile ducts above or below the bifurcation of the hepatic duct, which is a major drawback of other classification systems.

Mattox classification

The Mattox classification of BDI takes into consideration the types of injuring factors (contusion, laceration, perforation, transection, diversion or interruption of the bile duct or the gallbladder).¹⁷ There are several classifications in the literature for induced BDI during laparoscopic cholecystectomy (Schmidt et al.,¹⁸ Bergman et al.,¹⁹ Csencdes et al.,²⁰ and Lau et al.²¹).

CONCLUSIONS

There are a number of classifications for BDI. The description and classification of iatrogenic bile duct injuries after cholecystectomy should always include all clinically relevant data on each injury pattern, which will have an impact on surgical treatment and outcome.

REFERENCES

- Sicklick JK, Camp MS, Lillemoe KD, Melton GB, Yeo CJ, Campbell KA, et al. Surgical management of bile duct injuries sustained during laparoscopic cholecystectomy: perioperative results in 200 patients. *Ann Surg* 2005;241:786-792.
- McMahon AJ, Fullarton G, Baxter JN, O'Dwyer PJ. Bile duct injury and bile leakage in laparoscopic cholecystectomy. *Br J Surg* 1995;82:307-313.
- Strasberg SM, Hertl M, Soper NJ. An analysis of the problem of biliary injury during laparoscopic cholecystectomy. *J Am Coll Surg* 1995;180:101-125.
- Shea JA, Healey MJ, Berlin JA, Clarke JR, Malet PF, Staroscik RN, et al. Mortality and complications associated with laparoscopic cholecystectomy. A meta-analysis. *Ann Surg* 1996;224:609-620.
- Targarona EM, Marco C, Balagué C, Rodriguez J, Cugat E, Hoyuela C, et al. How, when, and why bile duct injury occurs. A comparison between open and laparoscopic cholecystectomy. *Surg Endosc* 1998;12:322-326.
- Lillemoe KD, Melton GB, Cameron JL, Pitt HA, Campbell KA, Talamini MA, et al. Postoperative bile duct strictures: management and outcome in the 1990s. *Ann Surg* 2000;232:430-441.
- Gazzaniga GM, Filauo M, Mori L. Surgical treatment of iatrogenic lesions of the proximal common bile duct. *World J Surg* 2001;25:1254-1259.
- Savar A, Carmody I, Hiatt JR, Busuttill RW. Laparoscopic bile duct injuries: management at a tertiary liver center. *Am Surg* 2004;70:906-909.
- Moore DE, Feurer ID, Holzman MD, Wudel LJ, Strickland C, Gorden DL, et al. Long-term detrimental effect of bile duct injury on health-related quality of life. *Arch Surg* 2004;139:476-481.
- Misra S, Melton GB, Geschwind JF, Venbrux AC, Cameron JL, Lillemoe KD. Percutaneous management of bile duct strictures and injuries associated with laparoscopic cholecystectomy: a decade of experience. *J Am Coll Surg* 2004;198:218-226.
- Gentileschi P, Di Paola M, Catarci M, Santoro E, Montemurro L, Carlini M, et al. Bile duct injuries during laparoscopic cholecystectomy: a 1994-2001 audit on 13,718 operations in the area of Rome. *Surg Endosc* 2004;18:232-236.
- Kaman L, Sanyal S, Behera A, Singh R, Katariya RN. Comparison of major bile duct injuries following laparoscopic cholecystectomy and open cholecystectomy. *ANZ J Surg* 2006;76:788-791.
- Ahrendt SA, Pitt HA. Surgical therapy of iatrogenic lesions of biliary tract. *World J Surg* 2001;25:1360-1365.
- Bismuth H, Majno PE. Biliary strictures: classification based on the principles of surgical treatment. *World J Surg* 2001;25:1241-1244.
- Stewart L, Domingez CO, Way LW. Bile duct injuries during laparoscopic cholecystectomy: a sensemaking analysis of operative reports. Mosier K, Fischer U, editors. *Proceedings of the 8th International NDM Conference; 2007 Jun; Pacific Grove, CA: [publisher unknown]; 2007.*
- Bektas H, Schrem H, Winny M, Klempnauer J. Surgical treatment and outcome of iatrogenic bile duct lesions after cholecystectomy and the impact of different clinical classification systems. *Br J Surg* 2007;94:1119-1127.
- Mattox KL, Feliciano DV, Moore EE. *Trauma*. 3rd ed. Stamford, CT: Appleton & Lange, 1996:515-519.
- Schmidt SC, Settmacher U, Langrehr JM, Neuhaus P. Management and outcome of patients with combined bile duct and hepatic arterial injuries after laparoscopic cholecystectomy. *Surgery* 2004;135:613-618.
- Bergman JJ, van den Brink GR, Rauws EA, de Wit L, Obertop H, Huibregtse K, et al. Treatment of bile duct lesions after laparoscopic cholecystectomy. *Gut* 1996;38:141-147.
- Csencdes A, Navarrete C, Burdiles P, Yarmuch J. Treatment of common bile duct injuries during laparoscopic cholecystectomy: endoscopic and surgical management. *World J Surg* 2001;25:1346-1351.
- Lau WY, Lai EC. Classification of iatrogenic bile duct injury. *Hepatobiliary Pancreat Dis Int* 2007;6:459-463.
- Sahajpal AK, Chow SC, Dixon E, Greig PD, Gallinger S, Wei AC. Bile duct injuries associated with laparoscopic cholecystectomy: timing of repair and long-term outcomes. *Arch Surg* 2010;145:757-763.