

Original Article

Evaluation of potential activity of luseogliflozin on vascular proliferation in the mesenteric lymph node with or without vascular tumors in Sprague-Dawley rats in a carcinogenicity study

Minoru Sasaki^{1*}, Takanoobu Sakurai¹, Aiko Ishii¹, Kenta Matsue¹, Yutaka Nakanishi¹, Shunsuke Tsutsumi¹, and Yasushi Sato¹

¹ Drug Safety, Drug Safety and Pharmacokinetics Laboratories, Taisho Pharmaceutical Co., Ltd., 1-403 Yoshino-cho, Kita-ku, Saitama-shi, Saitama 331-9530, Japan

Abstract: The incidence of mesenteric lymph node vascular tumors can vary in rats, and appropriate assessment of potential risk of tumorigenicity is needed when the incidence is higher in treated groups than in a control group. In a 2-year rat carcinogenicity study of luseogliflozin, a selective sodium-dependent glucose co-transporter 2 inhibitor for the treatment of type 2 diabetes mellitus, there was a slight but statistically significant increase in the total number of hemangiomas and hemangiosarcomas in the mesenteric lymph nodes in males at a high-dose. As part of the risk assessment for luseogliflozin, its effect on the vascular proliferation potential in the mesenteric lymph nodes was examined in a rat carcinogenicity study by performing an image analysis using specimens with double immunohistochemical staining for PCNA and CD34 in control and high-dose males. In addition, immunohistochemical staining for VEGF was performed to detect enhanced angiogenesis. In the high-dose males that did not have a hemangioma/hemangiosarcoma, neither an increased number of PCNA/CD34-positive cells nor changes in the expression pattern of VEGF was observed. On the other hand, in the high-dose males that had a hemangioma/hemangiosarcoma, the number of PCNA-positive cells was increased in the tumor areas, and the number in the hemangioma/hemangiosarcoma was approximately one-half of that in the hemangiosarcoma in the control male. In conclusion, no potential change leading to vascular proliferation/tumors was detected in the mesenteric lymph nodes of high-dose males receiving luseogliflozin. (DOI: 10.1293/tox.2015-0054; *J Toxicol Pathol* 2016; 29: 85–93)

Key words: vascular tumors, luseogliflozin, SGLT2, mesenteric lymph node, carcinogenicity, risk assessment

Introduction

Vascular tumors of the mesenteric lymph nodes are generally regarded as uncommon in Sprague-Dawley rats. However, the spontaneous incidence of lymph node vascular tumors in Sprague-Dawley male rats can vary over time, and these tumors occur more commonly and with a higher incidence in male rats, with the incidence varying from rare to common^{1, 2}. In studies performed from 1983 to 2001, historical data compiled from the Registry of Industrial Toxicology Animal-Data (RITA, unpublished data) shows that the incidence ranged from 0% to 6%². When the incidences of vascular tumors of lymph nodes are increased compared with those in control rats in carcinogenicity stud-

ies, it is important to perform additional risk assessment of tumorigenicity for humans to explore the possible vascular proliferation potential of the test agents.

In a rat carcinogenicity study of luseogliflozin, a potent non-genotoxic oral hypoglycemic agent that selectively inhibits the activity of sodium-dependent glucose co-transporter 2 (SGLT2) present in the proximal tubule of the kidney and facilitates urinary excretion of excessive glucose in the blood, thereby lowering the plasma glucose level^{3, 4}, a statistically significant increase in the total number of hemangiomas (benign) and hemangiosarcomas (malignant) was observed in the mesenteric lymph nodes of males at 100 mg/kg/day⁵. The present study was conducted to evaluate the vascular proliferation potential of luseogliflozin in the mesenteric lymph nodes in a 2-year rat carcinogenicity study using image analysis of specimens stained immunohistochemically for PCNA, CD34 and VEGF as part of a risk assessment for humans. In addition to evaluating the histomorphological and biological features of the mesenteric lymph nodes without vascular tumors, the proliferation activities of hemangioma and hemangiosarcoma tumor areas were also evaluated.

Received: 11 September 2015, Accepted: 24 November 2015

Published online in J-STAGE: 18 January 2016

*Corresponding author: M Sasaki

(e-mail: mino-sasaki@so.taisho.co.jp)

©2016 The Japanese Society of Toxicologic Pathology

This is an open-access article distributed under the terms of the Creative Commons Attribution Non-Commercial No Derivatives (by-nc-nd) License <<http://creativecommons.org/licenses/by-nc-nd/4.0/>>.

Table 1. Number of Animals with Hemangioma/hemangiosarcoma in the Mesenteric Lymph Nodes

Sex Dosage (mg/kg/day)	Male				Female			
	0	4	20	100	0	4	20	100
Number of animals	55	55	55	55	55	55	55	55
Mortality	32	26	30	29	42	37	33	31
Survival rate (%)	41.8	52.7	45.5	47.3	23.6	32.7	40.0	43.6
Hemangioma + Hemangiosarcoma	1 ^s	1	0	5	1	0	0	0
Hemangioma (benign)	0	1	0	2	1	0	0	0
Hemangiosarcoma (malignant)	1	0	0	3	0	0	0	0

^sP ≤ 0.025 (significant difference with trend test, rare tumor, Peto's test)

Materials and Methods

Chemicals

Luseogliflozin, (1S)-1,5-anhydro-1-[5-(4-ethoxybenzyl)-2-methoxy-4methylphenyl]-1-thio-D-glucitol, is a potent non-genotoxic oral hypoglycemic agent that selectively inhibits the activity of SGLT2⁴ and was synthesized by Chemistry Laboratories, Taisho Pharmaceutical Co., Ltd. (Saitama, Japan).

Samples used for histomorphological analysis and animal study information

Samples of lymph nodes were obtained from male rats in a 2-year rat carcinogenicity study of luseogliflozin. In the carcinogenicity study, luseogliflozin was orally administered to 55 male and 55 female Sprague-Dawley rats per group as repeated doses of 0 (control), 4, 20 and 100 mg/kg/day for 24 months (105 weeks) to investigate its carcinogenicity. The control group was given a 0.5% sodium carboxymethylcellulose aqueous solution in the same manner. The survival rates of males and females in each test group were not different from those in the control group throughout the study period. The respective survival rates in the control, 4, 20 and 100 mg/kg/day groups at scheduled necropsy (Week 105) were 41.8%, 52.7%, 45.5% and 47.3% for the males and 23.6%, 32.7%, 40.0%, and 43.6% for the females. Hemangiosarcoma was histopathologically diagnosed in the mesenteric lymph nodes of one control male and three high-dose males, and hemangioma was diagnosed in the mesenteric lymph nodes of two high-dose males. Among the mesenteric lymph nodes, the incidence of hemangioma or hemangiosarcoma was not significantly different from the control in either trend or pairwise comparison. However, the combined incidence of hemangioma and hemangiosarcoma was marginally higher in males at 100 mg/kg/day than in the control, and the trend test showed statistical significance, but the pairwise comparison showed no significant difference (Table 1). The hemangioma appeared as a nonencapsulated proliferation of a single layer of uniform endothelial cells without pronounced pleomorphism or atypia. Mitoses were seldom seen (Figs. 1A and B). The hemangiosarcoma, in contrast, was characterized by moderate pleomorphism to atypia of the lining endothelium, which was either multilayered or solid. Undifferentiated areas of sarcomatous tissue

or local invasion were sometimes observed. Mitoses, when present, were variable (Figs. 1C and D). The other control and high-dose males did not have any changes suggesting vascular proliferation or tumors in the mesenteric lymph nodes. In females, one control animal had a hemangioma, but hemangioma or hemangiosarcoma was not observed in any of the treated animals.

Paraffin sections of mesenteric lymph nodes from 23 surviving control males and 27 surviving or early sacrificed high-dose (100 mg/kg/day) males with or without vascular tumors were prepared for immunohistochemical staining.

Double immunohistochemical staining for proliferating cell nuclear antigen (PCNA) and surface antigen (CD34) in the vascular endothelium of rat mesenteric lymph nodes

Double immunostaining of mesenteric lymph nodes in 10% formalin-fixed specimens was performed on paraffin-embedded sections for the detection of PCNA (proliferation marker) and CD34 (endothelial cell marker). CD34 is cell surface antigen expressed on hematopoietic stem cells and bone marrow-derive endothelial progenitor cells (EPCs). CD34 was selected as the endothelial cell marker in this study because expression of CD34 is expected to be present in hematopoietic stem cells, EPCs and mature endothelial cells (ECs) in rodents and because it appears to be more effective in detecting immature vascular epithelia for detection of vascular proliferation activity rather than use of a mature EC marker such as CD31 or Factor VIII^{6, 7}. After deparaffinization of the sections, heat-induced epitope retrieval was performed in 10 mM citrate buffer (pH 6.0) (00-5000, Invitrogen, Frederick, MD, USA) for 40 minutes. The specimens were then reacted with the primary antibody (monoclonal mouse anti-rat PCNA antibody, M0879, 0.008 µg/mL, Dako Japan, Tokyo, Japan) overnight at 4°C. Then, the secondary antibody, biotin-conjugated horse anti-mouse IgG (BA-2001, 5 µg/mL, Vector Laboratories, Burlingame, CA, USA) was applied for 1 hour at room temperature. The slides were exposed to 0.3% H₂O₂ for 30 minutes to quench endogenous peroxidase. The sections were incubated using the ABC method⁸ (PK-6100, Vector Laboratories). Positive reactions resulted in brown nuclear staining with a DAB substrate (349-00903, Dojindo Laboratories, Kumamoto, Japan). After washing with PBS, the sections were incubated

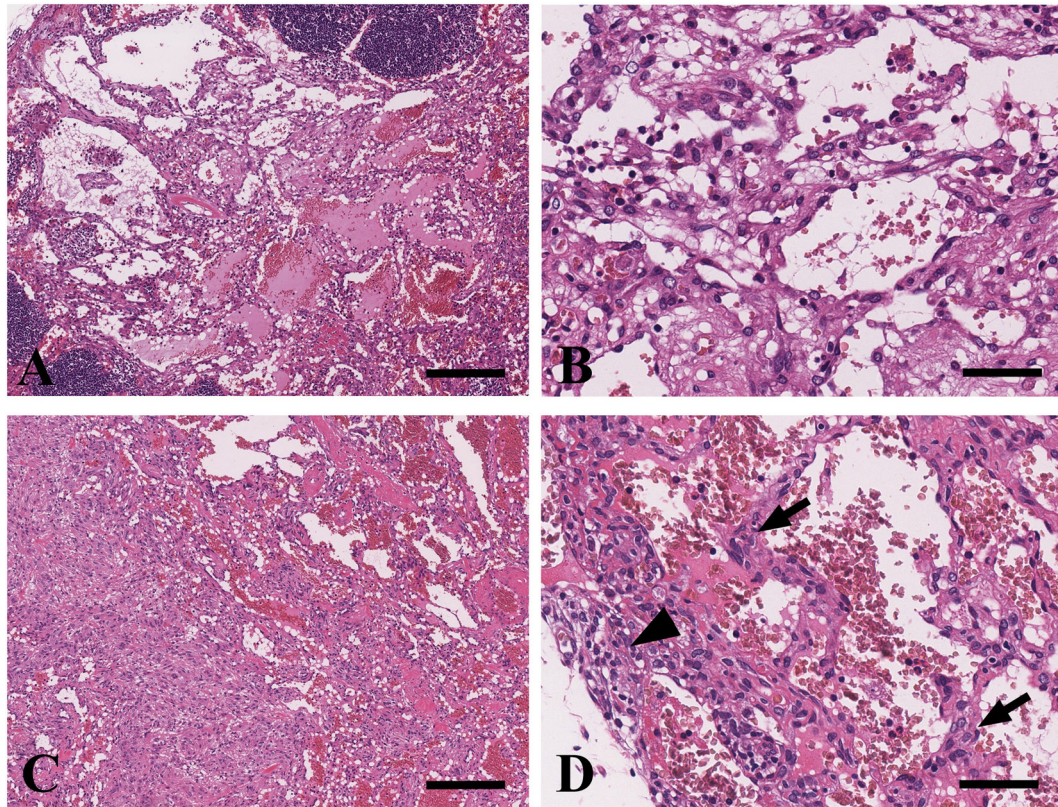


Fig. 1. Representative histopathological findings of hemangiomas (A, B) and hemangiosarcomas (C, D) of the mesenteric lymph node in male SD rats. Hemangioma was characterized by a nonencapsulated proliferation of a single layer of uniform endothelial cells without pronounced pleomorphism or atypia. Mitoses were seldom seen. B shows a higher magnification of A. Hemangiosarcoma was characterized by moderate pleomorphism to atypia of the lining endothelium, which was multilayered and solid (arrows). Undifferentiated areas of sarcomatous tissue or local invasion were sometimes visible (arrowhead). D shows a higher magnification of C. H&E stain. Bar = 200 μm (A, C) or 50 μm (B, D).

with an Avidin Biotin Blocking Kit (SP-2001, Vector Laboratories) to quench the unreacted biotin remaining from the previous procedure for 1 hour at room temperature and then with a polyclonal goat anti-rat CD34 antibody (AF4117, 1 $\mu\text{g}/\text{mL}$, R&D Systems, Minneapolis, MN, USA) overnight at 4°C. The secondary antibody, biotin-conjugated horse anti-goat IgG (BA-9500, 10 $\mu\text{g}/\text{mL}$, Vector Laboratories), was then applied for 1 hour at room temperature. The slides were exposed to 0.3% H_2O_2 for 30 minutes to quench the biotinylated peroxidase from the first step. The ABC method used for endothelial cells resulted in red cytoplasmic staining with 3-amino-9-ethylcarbazole (AEC-101, Sigma-Aldrich, St. Louis, MO, USA). Slides were then counterstained with hematoxylin, dehydrated, cleared and mounted.

Immunohistochemical staining for vascular endothelial growth factor (VEGF) on rat mesenteric lymph nodes

VEGF, a specific endothelial cell mitogen, if sustained, provides a milieu that can lead to hemangiosarcoma formation⁹, and a high level of VEGF reportedly induced hemangiomas¹⁰. After deparaffinization of the sections, slides were heated by microwave for 18 minutes in 10 mM citrate buffer

(pH 6.0) (00-5000, Invitrogen) for antigen retrieval.

The specimens were then reacted with the primary antibody, polyclonal goat anti-rat VEGF antibody (AF564, 0.5 $\mu\text{g}/\text{mL}$, R&D Systems), overnight at 4°C. Then the secondary antibody, biotin-conjugated horse anti-goat IgG (BA-9500, 10 $\mu\text{g}/\text{mL}$, Vector Laboratories), was applied for 1 hour at room temperature. The slides were exposed to 0.3% H_2O_2 for 30 minutes to quench endogenous peroxidase. The sections were incubated using the ABC method, and positive reactions resulted in red cytoplasmic staining with 3-amino-9-ethylcarbazole (AEC-101, Sigma-Aldrich). For negative controls, normal goat IgG (PP500P, Acris Antibodies, Herford, Germany) was used as the primary antibody in representative samples.

Image analysis of vascular proliferation in mesenteric lymph nodes

Histology slides of double immunohistochemical staining with PCNA and CD34 were scanned with a ScanScope XT (Leica Microsystems, Heidelberg, Germany) using bright-field imaging at 20x magnification. Specimen areas were selected, and individual images were saved in a 24-bit RGB TIFF file format with a resolution of 1 $\mu\text{m}/\text{pixel}$ using

Table 2. Number of PCNA and CD34 Double-positive Cell in the Mesenteric Lymph Nodes without a Hemangioma or Hemangiosarcoma

Group		Control	Luseogliflozin 100 mg/kg/day
Number of animals		n = 22	n = 22
Number of PCNA and CD34 double-positive cells ^a	Per section	2.1 ± 2.4	1.3 ± 1.4
	Per mm ² of tissue	0.30 ± 0.43	0.13 ± 0.13

^aValues are shown as the mean ± SD. Data were analyzed using the F-test followed by the Aspin-Welch *t*-test.

the ImageScope software (Leica Microsystems). An automated analysis of the TIFF image files was performed using the programming language IDL 6.3 (ITT Visual Information Solutions, Exelis VIS KK, Tokyo, Japan).

To evaluate the vascular proliferation potential in mesenteric lymph nodes without a hemangioma or hemangiosarcoma in the carcinogenicity study in rats, specimens for double immunohistochemical staining for PCNA and CD34 in control males (n = 22) and high-dose males (n = 22) were analyzed by counting the total number of cells that were positive for both antibodies per section. The total number of PCNA and CD34 double-positive cell per mm² tissue was also calculated for normalizing the value by tissue area. In addition, five imaging fields (at 20× magnification) of hemangioma and hemangiosarcoma areas in the mesenteric lymph nodes of control (hemangiosarcoma, n = 1) and high-dose males (hemangioma, n = 2; hemangiosarcoma, n = 3) were randomly selected, and all the PCNA-positive cells were counted; the average number of PCNA-positive cells per field was then calculated. In cases where the tumor area was too small to select five fields at 20× magnification, we selected as much of the field as possible, and the average number of PCNA-positive cells per imaging field was calculated.

Histomorphological evaluation of enhanced angiogenesis in mesenteric lymph nodes

Histology slides of immunohistochemical staining with VEGF were scanned with a ScanScope XT (Leica Microsystems) in the same manner as mentioned above. To detect enhanced angiogenesis in the mesenteric lymph nodes with or without vascular tumors in the rat carcinogenicity study, specimens for immunohistochemical staining for VEGF in control males (n = 23) and high-dose males (n = 27) were microscopically evaluated by observing the stainability of positive cells and their distribution in the tissues.

Statistical analysis

The statistical analysis was performed using the MITOX, Ver. 8, software (QualitySoft Corporation, Tokyo, Japan). All values were reported as the mean ± standard deviation (SD). The PCNA/CD34 double-positive cells of mesenteric lymph nodes without a hemangioma or hemangiosarcoma were analyzed using the F-test followed by the Aspin-Welch *t*-test. Values represent the results of the *t*-test, with *P* < 0.05 considered statistically significant.

A statistical analysis of the PCNA-positive cells in

the vascular tumor areas of mesenteric lymph nodes with a hemangioma or hemangiosarcoma was not performed because there was only one sample from a control male with a vascular tumor.

Results

Image analysis of vascular proliferation in mesenteric lymph nodes by immunostaining for PCNA and/or CD34

In male rats without a hemangioma or hemangiosarcoma in their mesenteric lymph nodes, the mean number of PCNA/CD34 double-positive cells was 1.3 ± 1.4 in the high-dose group and 2.1 ± 2.4 in the control group. The value normalized by tissue area (mm²) was 0.13 ± 0.13 in the high-dose group and 0.30 ± 0.43 in the control group (Table 2). Since there were no significant differences in the number of double-positive cells in the mesenteric lymph nodes between high-dose males and control males, no increases in PCNA-positive cells in the vascular endothelium, which would suggest the potential development of vascular proliferation, were detected (Fig. 2).

An image analysis of PCNA-positive cells in the areas of vascular tumors in mesenteric lymph nodes revealed that the number of PCNA-positive cells was 111.8 cells/imaging field at 20× in the hemangiosarcoma of a control male and 50.4 and 51.4 cells/imaging field at 20× in hemangiomas (n = 2) or hemangiosarcomas (n = 3), respectively, in high-dose males (Table 3). The number of PCNA-positive cells/imaging field at 20× in the control male rat with a hemangiosarcoma was approximately twice the number in high-dose males with a hemangioma or hemangiosarcoma (Fig. 3). Furthermore, no clear difference in the number of PCNA-positive cells was observed between the animals with a hemangioma and those with a hemangiosarcoma of the mesenteric lymph node in high-dose males.

Histomorphological evaluation of mesenteric lymph nodes using immunostaining for VEGF

There were no clear differences in the expression pattern and stainability of VEGF in high-dose male rats that did not have a hemangioma or hemangiosarcoma, compared with the observations in control male rats. The VEGF-positive reaction was generally more prominent in the vascular endothelium of the tumor areas of hemangiomas or hemangiosarcomas of mesenteric lymph nodes in the control and high-dose groups, and no clear difference in the expression

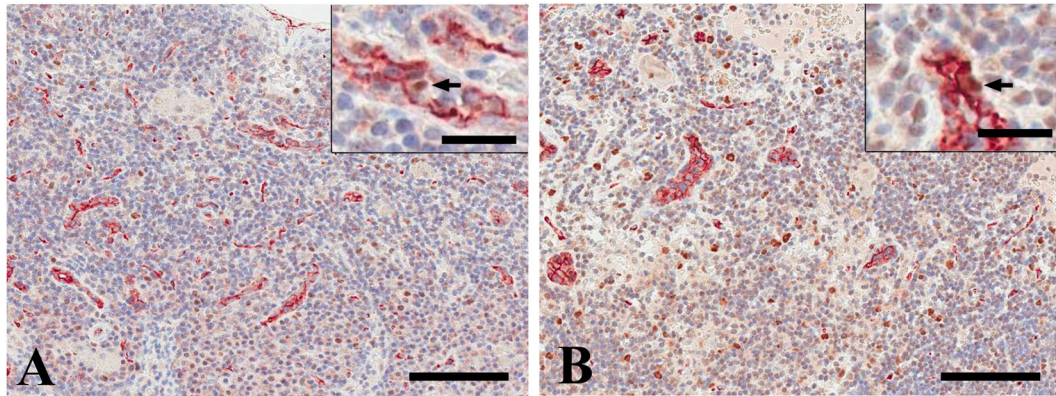


Fig. 2. Double immunostaining for PCNA (brown) and CD34 (red) in nuclei and endothelial cytoplasm, respectively, in mesenteric lymph nodes that did not have a hemangioma or hemangiosarcoma in the control (A) and high-dose (B) groups. No differences were noted. Bar = 100 µm. The arrows indicate PCNA/CD34 double-positive cells (inset, bar = 20 µm).

Table 3. Number of PCNA-positive Cells in Areas of Vascular Tumors in the Mesenteric Lymph Nodes

Group	Luseogliflozin 100 mg/kg/day		
	Control	Hemangioma	Hemangiosarcoma
Histomorphological diagnosis	Hemangiosarcoma	Hemangioma	Hemangiosarcoma
Number of animals	n = 1	n = 2	n = 3
Number of PCNA-positive cells per imaging field at 20× (0.5 mm ²) ^a	111.8	50.4 ± 23.5	51.4 ± 15.4

^aValues are shown as the mean ± SD.

pattern was noted between the control and high-dose groups (Fig. 4).

Discussion

In a 2-year rat carcinogenicity study of luseogliflozin, an oral hypoglycemic agent, a slight but statistically significant increase in the total number of hemangiomas and hemangiosarcomas in the mesenteric lymph nodes was observed in high-dose males. The incidence of vascular tumors was 9.1%, and the incidences of hemangioma and hemangiosarcoma were 5.5% and 3.6%, respectively, in high-dose males. The effects of this agent on vascular proliferation potential in the mesenteric lymph nodes was studied by performing an image analysis of specimens with immunohistochemical staining for PCNA, CD34 and VEGF.

In the present study, image analysis and/or histomorphological evaluation of the mesenteric lymph nodes that did not contain a hemangioma or hemangiosarcoma revealed no increases in the number of PCNA/CD34 double-positive cells per mm² tissue area or changes in the expression pattern of VEGF in the high-dose males compared with the control males. These results suggest that there were no potential changes leading to vascular proliferation or the development of vascular tumors in the mesenteric lymph nodes of the high-dose male rats.

Hemangioma in rodents is histopathologically characterized by the proliferation of blood vessels lined with a

single layer of uniform endothelial cells with little atypia and rare mitotic figures^{11, 12}. On the other hand, hemangiosarcoma in rodents is histopathologically characterized by the proliferation of a single or multiple layers of atypical/polymorphic vascular endothelial cells with frequent mitoses forming an irregular vascular lumen and infiltrating and/or metastasizing to surrounding tissues. Biological behavior, including distal metastasis, is reported to be helpful in classifying these tumors¹¹. Another report recommends that even vascular tumors with atypia should be diagnosed as benign tumors (hemangiomas) when distal metastasis is not present¹³.

Vascular tumors of the mesenteric lymph nodes often have overlapping morphological features that can make it difficult to determine whether they are benign or malignant. The results of image analysis for the mesenteric lymph nodes containing a hemangioma or hemangiosarcoma showed that the number of PCNA-positive cells (111.8 cells/imaging field at 20×) was largest in the control male rat with a hemangiosarcoma. This finding was consistent with the results of our histomorphological evaluation, which showed that the most pronounced solid hemangiosarcoma was found in the same control. The hemangiosarcomas observed in the high-dose males contained approximately half the number of PCNA-positive cells as the control with a hemangiosarcoma, and no clear difference in the number of PCNA-positive cells was seen between the animals with a hemangioma and those with a hemangiosarcoma of the mesenteric lymph node in

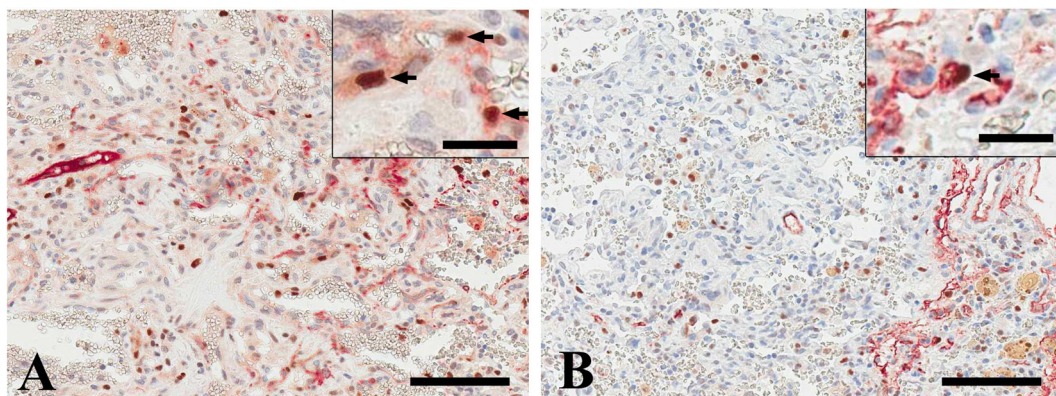


Fig. 3. Immunohistochemistry for PCNA (brown nuclei) in hemangiosarcoma areas of the mesenteric lymph nodes in the control (A) and high-dose (B) groups. Bar = 100 µm. The arrows indicate PCNA-positive cells. PCNA-positive cells were more frequently noted in the hemangiosarcoma in the control male (inset, bar = 20 µm).

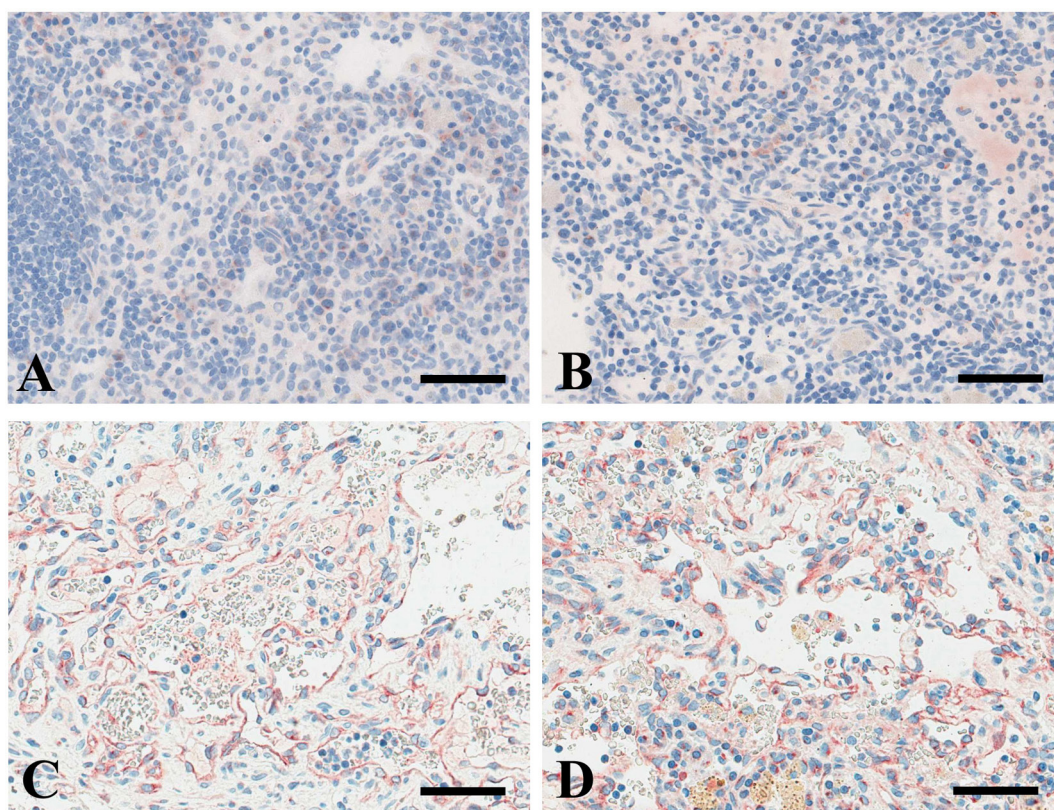


Fig. 4. Immunohistochemistry for VEGF (red) in mesenteric lymph nodes that did not have vascular tumors in the control (A) and high-dose (B) groups. No clear difference in the expression pattern was observed between the control and high-dose groups. In the vascular tumor areas of mesenteric lymph nodes that had a hemangiosarcoma, the endothelial cells were positive for VEGF, and no clear difference in the expression pattern was noted between the control (C) and high-dose (D) groups. Bar = 50 µm.

high-dose males. These results suggest that even when malignancies are diagnosed histologically according to a certain set of criteria for morphologic features, some diagnoses may be borderline, and some of the lesions may be biologically benign. Since such uncertain differentiation in rodents could affect statistical analyses of benign and malignant

vascular tumors, combined evaluation of benign and malignant vascular tumors is useful for evaluating carcinogenicity studies and for risk assessment.

In addition to evaluating the results of the present study, a detailed review and assessment of repeated dose toxicity and/or carcinogenicity studies of luseogliflozin were con-

ducted to identify the relationship between the tumor and the plasma exposure/tissue concentrations of the agent, the histological findings leading to either dysregulated angiogenesis and/or erythropoiesis that results from direct vaso-stimulation, hemolysis^{14–16}, hypoxia^{17, 18} and macrophage activation¹⁹ and the recent incidence of vascular tumors in the mesenteric lymph nodes of rats in a study facility.

When evaluating the relationship between the occurrence of vascular tumors in the mesenteric lymph nodes and the plasma level of luseogliflozin, neither hemangioma nor hemangiosarcoma was observed in female rats and other animal species exposed to luseogliflozin at higher levels than those in the male rats, indicating a poor relationship between hemangioma or hemangiosarcoma and the plasma level of luseogliflozin⁵.

Dronedarone, an antiarrhythmic agent, has been reported^{20, 21} to cause vascular tumors because the active ingredient is distributed specifically to the mesenteric lymph nodes. To examine this possibility, the tissue concentrations of luseogliflozin in the mesenteric lymph nodes were reviewed. The radioactivity concentration in the mesenteric lymph nodes of rats after a single dose of [¹⁴C] luseogliflozin to male rats was equivalent to that in the blood or plasma and was not particularly higher than the levels in other tissues, and the radioactivity rapidly disappeared from the mesenteric lymph nodes²². Therefore, neither a specific distribution nor accumulation of luseogliflozin was observed in the mesenteric lymph nodes, suggesting a weak correlation between hemangioma/hemangiosarcoma and the tissue concentrations of luseogliflozin.

Dronedarone reportedly caused hemangioma, and the possible mechanism for the onset was reported to be related to blood flow alterations in the mesenteric lymph nodes secondary to the aggregation of foam cells^{20, 21}. Both no relevant tissue injury suggesting the direct involvement of luseogliflozin and the absence of any lesions known to lead to vascular endothelial proliferation, such as erythropoiesis, hemolysis, hypoxia, and macrophage activation⁸, in the occurrence of hemangioma and hemangiosarcoma in the mesenteric lymph nodes were noted in the rat carcinogenicity study and repeated-dose toxicity studies of luseogliflozin in rats⁵.

The incidence of lymph node angioma is known to vary markedly over time and appears to be higher in some other rat strains than in the CrI:CD strain^{1, 2}, and a broader range of angiomatous lesions may occur in lymph nodes. It has been reported that mesenteric lymph node angiomas occur more commonly and at a higher incidence in male rats, with the incidence varying from rare to common in Sprague-Dawley rats (0%–8.6%)^{2, 16}, and these benign angiomas in different strains have always been more common in male rats than in female rats^{1, 2, 23, 24}. Tennekes *et al.* reported that changes in tumor incidence over time in male Sprague-Dawley rats were primarily caused by genetic drift²⁵. Based on this information, a review of the historical incidences of tumors in rats at the testing facility was considered to be useful when evaluating such a marginal increase in vascular

tumors of the mesenteric lymph node in rats.

The total number of spontaneous occurrences of hemangiomas and hemangiosarcomas in the mesenteric lymph nodes at the testing facility in 2010 and 2011, when the rat carcinogenicity study was conducted, tended to be slightly elevated, compared with that in other years. For the past 10 years, the incidence of each event tended to be higher in males than in females. Thus such a tendency for an increased incidence of spontaneous mesenteric lymph node vascular tumors in the testing facility might have affected the marginal increase in vascular tumors noted in the high-dose males in the rat carcinogenicity study.

Vascular tumors are known to occur mainly in the liver, spleen, heart and subcutaneous adipose tissues in rodents⁹, but no such tumors were observed in these organs in the carcinogenicity study of luseogliflozin in rats. Furthermore, a carcinogenicity study of luseogliflozin in mice showed no evidence of increased occurrence of hemangioma/hemangiosarcoma⁵.

Based on the analysis performed and information mentioned above, the marginally increased incidence of vascular tumors of the mesenteric lymph node of males in the rat carcinogenicity study of luseogliflozin was likely to be of low relevance to the test article.

Hemangioma in humans is a pathological condition, and it can be difficult to distinguish whether the lesion is a true tumor or tissue malformation (hamartoma)²⁶. Such tumors are not believed to become malignant^{2, 9}. Hemangiosarcoma in humans represents the formation of an irregular vascular lumen consisting of large and small cells or the proliferation of atypical endothelial cells in the form of a mass. It is a highly malignant pathological condition with the papillary protrusion of tumor cells into the vascular lumen²⁷. Furthermore, in humans, hemangioma appears more commonly on the surface of the head and neck region and liver²⁷, and lymph node angioma (lymphangioma and hemangioma) is extremely rare². The incidence of hemangiosarcoma has recently been estimated to be 0.00021%²⁸. With the exception of known genotoxic substances, no cases of drug-induced hemangioma or hemangiosarcoma in the mesenteric lymph nodes have been reported in humans². When taking all the information mentioned above into consideration, extrapolating vascular tumors of rat mesenteric lymph nodes to risk assessments for humans may not be suitable because of the differences in diagnostic criteria, pathological nature and condition and incidence of hemangioma and hemangiosarcoma between rats and humans.

In summary, image analysis and/or histomorphological evaluation of mesenteric lymph nodes using immunohistochemical staining with PCNA, CD34 and VEGF revealed that there was neither an increased number of PCNA/CD34 double-positive cells per tissue area nor changes in the expression pattern of VEGF in the high-dose males compared with control males in the rat carcinogenicity study of luseogliflozin, an oral hypoglycemic agent. This result suggested that there were no potential changes leading to vascular proliferation or the development of vascular tumors in the

mesenteric lymph nodes in the rat carcinogenicity study, in which a marginal increase in the combined number of hemangiomas and hemangiosarcomas of the mesenteric lymph node was noted in the high-dose males.

Acknowledgments: We thank Mieko Ono, Yuko Yoneyama and Tomoyo Otsuka for laboratory assistance and Bunichiro Ogawa for image analysis support.

Disclosure of Potential Conflicts of Interest: All authors are employees of Taisho Pharmaceutical Co., Ltd., and there are no known conflicts of interest associated with this publication.

References

- Tucker MJ. The haematopoietic and lymphatic systems. In: Diseases of the Wistar Rat. MJ Tucker (ed). Taylor & Francis Inc. Bristol, PA. 135–136. 1997.
- Radi ZA, and Morton D. Human safety risk assessment of lymph node angiomas observed in 2-year carcinogenicity studies in rats. *Regul Toxicol Pharmacol.* **64**: 435–441. 2012. [Medline] [CrossRef]
- Wright EM, Hirayama BA, and Loo DF. Active sugar transport in health and disease. *J Intern Med.* **261**: 32–43. 2007. [Medline] [CrossRef]
- Kakinuma H, Oi T, Hashimoto-Tsuchiya Y, Arai M, Kawakita Y, Fukasawa Y, Iida I, Hagima N, Takeuchi H, Chino Y, Asami J, Okumura-Kitajima L, Io F, Yamamoto D, Miyata N, Takahashi T, Uchida S, and Yamamoto K. (1S)-1,5-anhydro-1-[5-(4-ethoxybenzyl)-2-methoxy-4-methylphenyl]-1-thio-D-glucitol (TS-071) is a potent, selective sodium-dependent glucose cotransporter 2 (SGLT2) inhibitor for type 2 diabetes treatment. *J Med Chem.* **53**: 3247–3261. 2010. [Medline] [CrossRef]
- Pharmaceuticals and Medical Devices Agency of JAPAN (PMDA) Luseogliflozin CTD part2. 2014, from PMDA website: <http://www.pmda.go.jp/drugs/2014/P201400033/index.html>.
- Weiss SW, and Goldblum JR. Malignant vascular tumors. In: Enzinger and Weiss's Soft Tissue Tumors. 5th ed. SW Weiss, and JR Goldman (eds). Mosby Elsevier. St. Louis, MO. 703–732. 2008.
- Kakiuchi-Kiyota S, Crabbs TA, Arnold LL, Pennington KL, Cook JC, Malarkey DE, and Cohen SM. Evaluation of expression profiles of hematopoietic stem cell, endothelial cell, and myeloid cell antigens in spontaneous and chemically induced hemangiosarcomas and hemangiomas in mice. *Toxicol Pathol.* **41**: 709–721. 2013. [Medline] [CrossRef]
- Hsu SM, Raine L, and Fanger H. Use of avidin-biotin-peroxidase complex (ABC) in immunoperoxidase techniques: a comparison between ABC and unlabeled antibody (PAP) procedures. *J Histochem Cytochem.* **29**: 577–580. 1981. [Medline] [CrossRef]
- Cohen SM, Storer RD, Criswell KA, Doerr NG, Dellarco VL, Pegg DG, Wojcinski ZW, Malarkey DE, Jacobs AC, Klaunig JE, Swenberg JA, and Cook JC. Hemangiosarcoma in rodents: mode-of-action evaluation and human relevance. *Toxicol Sci.* **111**: 4–18. 2009. [Medline] [CrossRef]
- Ozawa CR, Banfi A, Glazer NL, Thurston G, Springer ML, Kraft PE, McDonald DM, and Blau HM. Microenvironmental VEGF concentration, not total dose, determines a threshold between normal and aberrant angiogenesis. *J Clin Invest.* **113**: 516–527. 2004. [Medline] [CrossRef]
- Carlton WW, Ernst H, Faccini JM, Greaves P, Krinke GJ, Long PH, Maekawa A, Newsholme SJ, and Weisse G. Soft tissue and musculoskeletal system. In: International Classification of Rodent Tumors, part I the Rat. U Mohr (ed). IARC Scientific Publications, Lyon. 3-4. 1992.
- Squire RA, Goodman DG, Valerio MG, Fredrickson TN, Strandberg JD, and Levitt MH. Chapter 12, tumors. In: Pathology of Laboratory Animals Volume II. K Benirschke, FM Garner, and TC Jones (eds). Springer-Verlag, New York. 1083–1091. 1978.
- Reindel JF, Dominick MA, and Gough AW. Mesenteric lymph node hemangiomas of Wistar rats. *Toxicol Pathol.* **20**: 268–273. 1992. [Medline] [CrossRef]
- Nyska A, Haseman JK, Kohen R, and Maronpot RR. Association of liver hemangiosarcoma and secondary iron overload in B6C3F1 mice—the National Toxicology Program experience. *Toxicol Pathol.* **32**: 222–228. 2004. [Medline] [CrossRef]
- Corthals SM, Kamendulis LM, and Klaunig JE. Mechanisms of 2-butoxyethanol-induced hemangiosarcomas. *Toxicol Sci.* **92**: 378–386. 2006. [Medline] [CrossRef]
- Abdo KM, Johnson JD, and Nyska A. Toxicity and carcinogenicity of Elmiron in F344/N rats and B6C3F1 mice following 2 years of gavage administration. *Arch Toxicol.* **77**: 702–711. 2003. [Medline] [CrossRef]
- Herman JR, Dethloff LA, McGuire EJ, Parker RF, Walsh KM, Gough AW, Masuda H, and de la Iglesia FA. Rodent carcinogenicity with the thiazolidinedione antidiabetic agent troglitazone. *Toxicol Sci.* **68**: 226–236. 2002. [Medline] [CrossRef]
- Pegg DG, Wojcinski Z, Criswell K, Herman J, and Anderson T. Epigenetic mode of action associated with induction of hemangiosarcoma in mice. *Toxicologist.* **90**: 334. 2006.
- Bigot-Lasserre D, Chuzel F, Debruynne E, Urtizbera M, and Carmichael N. Tumorigenic potential of carbaryl in the P53 knockout mouse model. *Toxicologist.* **54**: 1038. 2000.
- European Medicines Agency (EMA). Withdrawal Public Assessment Report of the Marketing Authorisation Application for Multaq (Dronedarone). EMA/CHMP/370798, London. 2006, from European Medicines Agency (EMA) website: http://www.ema.europa.eu/docs/en_GB/document_library/Application_withdrawal_assessment_report/2010/01/WC500069271.pdf.
- Sanofi Canada Multaq Product monograph, Dronedarone Tablets. 2014, from Sanofi Canada website: <http://products.sanofi.ca/en/multaq.pdf>.
- Hasegawa M, Chino Y, Horiuchi N, Hachiuma K, Ishida M, Fukasawa Y, Nakai Y, and Yamaguchi J. Preclinical metabolism and disposition of luseogliflozin, a novel antihyperglycemic agent. *Xenobiotica.* **45**: 1105–1115. 2015. [Medline] [CrossRef]
- Zwicker GM, Eyster RC, Sells DM, and Gass JH. Spontaneous vascular neoplasms in aged Sprague-Dawley rats. *Toxicol Pathol.* **23**: 518–526. 1995. [Medline] [CrossRef]
- Deerberg F, Rapp K, Rehm S, and Pittermann W. Genetic and environmental influences on lifespan and diseases in Han:Wistar rats. *Mech Ageing Dev.* **14**: 333–343. 1980.

- [\[Medline\]](#) [\[CrossRef\]](#)
25. Tennekens H, Kaufmann W, Dammann M, and van Ravenzwaay B. The stability of historical control data for common neoplasms in laboratory rats and the implications for carcinogenic risk assessment. *Regul Toxicol Pharmacol.* **40**: 293–304. 2004. [\[Medline\]](#) [\[CrossRef\]](#)
 26. Guidelines for the Treatment of Hemangioma/Vascular Malformation Committee. Guidelines for the Treatment of Hemangioma/Vascular Malformation. 2013. In Japanese.
 27. Tsutsumi A. Chapter 11, Soft Tissues. In: *Color atlas of Histopathology and Differential Diagnosis*. 3rd ed. K Ogawa, T Akagi, Y Onishi, and N Sasano (eds). Ishiyaku Publishers, Tokyo. 403–436. 1997. In Japanese.
 28. Criswell KA, Cook JC, Wojcinski Z, Pegg D, Herman J, Wesche D, Giddings J, Brady JT, and Anderson T. Mode of action associated with development of hemangiosarcoma in mice given pregabalin and assessment of human relevance. *Toxicol Sci.* **128**: 57–71. 2012. [\[Medline\]](#) [\[CrossRef\]](#)