

Magnetic resonance imaging and clinically controlled improvement of a combined autologous conditioned plasma combined with rh collagen type I injections in lateral epicondylitis

Axel W.A. Baltzer,¹
Martin S. Ostapczuk²

¹Königsallee, Centre for Molecular Orthopaedics Düsseldorf; ²Clinic for Orthopaedics and Trauma Surgery, St. Josef Hospital Moers, Germany

Abstract

The purpose of the study was to investigate the effect of combined autologous conditioned plasma and recombinant human collagen type I injections on lateral epicondylitis. Outcome was measured in 5 patients before the single application of ACP+rhCollagen type I (Arthrex ACP® Tendo) and after 10.60±3.58wks by means of (i) the Visual Analogue Scale for pain, (ii) range of motion for wrist extension/flexion as well as supination/pronation, and (iii) MRI-scans. VAS-scores significantly decreased from 6.40±1.14 at baseline to 1.80±2.49 at follow-up, and the effect was very large ($p=0.04$, $d_z=2.22$). In addition, range of motion either improved or remained unrestricted, and MRI-scans showed healing of the extensor carpi radialis brevis tendon in most cases. A combined ACP+rhCollagen-injection successfully reduces pain in lateral epicondylitis. Due to the small sample size, however, these promising preliminary results need further investigation in future research.

Introduction

Lateral epicondylitis (LEP) is a common orthopaedic condition affecting almost 2% of the general adult population.¹ It is mainly caused by repetitive microtraumatic injuries of the extensor carpi radialis brevis (ECRB) tendon and other extensor muscles of the forearm resulting from chronic overload.^{2,3} In spite of being known as a tendonitis suggesting an underlying inflammation process, recent histopathologic studies point out that the degenerative changes of the tendon in LEP seem rather associated

with disorganized collagen, hypertrophy of fibroblasts and vascular elements, apoptosis and extracellular matrix breakdown in terms of a tendinopathy.⁴⁻⁶ Typical LEP symptoms include lateral epicondyle tenderness radiating along the forearm and painful (restriction of) wrist extension. Although LEP is usually self-limiting, special populations, e.g., manual workers or tennis players, tend to a refractory course of disease,^{1,2} and even in the general population, approximately one quarter of patients report severe difficulties concerning common activities of daily living with 5% taking prolonged sick leave.³

In the past, different non-surgical LEP treatments, such as non-steroidal anti-inflammatory drugs, physical therapy, orthoses, low-level laser and shock-wave therapy or steroid injections, have been applied.^{1,7-11} Treatment effect sizes, however, tend to be small, and recommendations – even regarding surgery as the ultima ratio – have repeatedly vary.^{8,9,11}

Studies within the realm of biologics recently yielded positive results using platelet rich plasma (PRP)/autologous conditioned plasma (ACP) injections for the treatment of LEP.^{1,10,12} It is known that tendons generally heal more slowly than other tissues in the human body due to their lower vascularization, among others.^{1,13} As PRP demonstrably contains high levels of growth factors and cytokines released by platelets, it is hypothesized to promote the healing process by delivering growth factors and nutrients on the one hand, and by initiating an inflammatory process on the other hand.^{1,14,16} Various in-vitro and in-vivo studies have shown growth factors to induce proliferation and differentiation of several cell types, to enhance matrix production (e.g., collagen and proteoglycan), and to stimulate angiogenesis and chemotaxis.^{5,16-19}

Despite promising results in the treatment of refractory LEP with PRP, little is known about long-term effects, and standardized preparation/injection protocols are missing.¹ Besides, there is evidence that the common practice of adding local anaesthetics (LA's) to PRP potentially compromises the beneficial PRP effects by decreasing platelet functionality and tenocyte proliferation, seemingly caused by the acidic milieu created by LA's.^{15,20}

In the present case series, we therefore used a combination of ACP and a collagen-scaffold supposedly allowing for a long-term ACP effect and simultaneous LA. The major advantage of adding collagen to ACP as a scaffold material is the resulting growth factor depot enabling a prolonged release of

Correspondence: Axel W.A. Baltzer, Associate Practice at Königsallee, Centre for Molecular Orthopaedics
Königsallee 53-55, 40212 Düsseldorf, Germany.
Tel.: +49.21182893710 - Fax: +49.21182893711.
E-mail: axel@baltzer.at

Contributions: AWAB conceptualized the study, treated the patients and revised the manuscript. MSO analyzed the data and wrote the manuscript.

Conflict of interest: The authors declare no potential conflict of interest.

Funding: None.

Ethical approval: The conduction and publication of the present case series were approved by the Institutional Review Board of the Centre for Molecular Orthopaedics Düsseldorf, Germany (study number 100/07/2017).

Received for publication: 14 November 2020.
Accepted for publication: 27 March 2021.

This work is licensed under a Creative Commons Attribution NonCommercial 4.0 License (CC BY-NC 4.0).

©Copyright: the Author(s), 2021
Licensee PAGEPress, Italy
Orthopedic Reviews 2021;13:9018
doi:10.4081/or.2021.9018

the factors to the injury site with only one injection.^{21,22} The mixture of ACP and collagen is rather viscous requiring large-bore needles and, preferably, LA's. Thanks to the collagen-scaffold, however, the detrimental effect of LA's on ACP can be alleviated: First, the vast majority of platelets are already being activated during the mixture process thereby avoiding the subsequent acidic milieu which decreases platelet activation.¹⁵ Second, the activated platelets and released growth factors are at least partially enclosed in the collagen-scaffold and thereby gradually released, thus surpassing the half-life of a short-acting LA. The collagen-scaffold used in the present study was a recombinant human Collagen (rhCollagen) extracted from tobacco plants which is identical with human collagen type I.²²⁻²⁴ The advantages of the plant-derived rhCollagen compared with bovine-extracted collagen are its non-allergenic properties and pure homogeneous structure increasing cell-binding.²¹⁻²⁵ To the best of our knowledge, there are no published reports on the combined effect of an ACP and collagen injection in humans.

Materials and Methods

Patients and Study Design

Treatment and data collection took place at an orthopaedic centre from April to August 2017. Inclusion criteria were clinical evidence of LEP as defined by the presence of typical symptoms for at least 4wks and by MRI-scans. Patients with previous surgical treatments of the respective elbow, rheumatoid arthritis, bacterial infection, cancerous lesions in immediate vicinity of the treated elbow, and poor general health were excluded. For the duration of the case series, patients received no other major treatments.

In total, 5 male patients (3 right elbows) aged 47.20 ± 4.87 yrs participated. Outcome was measured multi-dimensionally before the single application of ACP+rhCollagen type I and after 10.60 ± 3.58 wks by means of (i) the Visual Analogue Scale (VAS) for pain (0=no pain, 10=most severe pain),²⁶ (ii) range of motion (ROM) for wrist extension/flexion as well as supination/pronation, and (iii) MRI-scans.

ACP and rhCollagen (Arthrex ACP® Tendo)

To produce ACP, 15ml of whole venous blood were taken from each patient using a special syringe system (Arthrex Inc., Naples, FL, USA). The blood-filled syringe was then centrifuged at 1500rpm for 5min and the supernatant (approximately 2.7ml of ACP) was subsequently mixed with the lyophilized rhCollagen (Vergenix™ STR Soft Tissue Repair Device, CollPlant Ltd., Ness Ziona, Israel; EC Notified Body ID 0344). After homogenizing, the resulting Arthrex ACP® Tendo (approximately 3ml) was injected using a 19G needle in the vicinity of the ECRB insertion. Prior to injection, the application site was anaesthetized with 1ml scandicaine.

Statistical Analysis

The Statistical Package for the Social Sciences 23.0 was used for data analysis. Means and standard deviations are reported as $M \pm SD$. Due to the small sample size, non-parametric tests were used: The difference between pre- and post-treatment VAS-scores was assessed by Wilcoxon's signed-rank test, whereas correlations were examined by Spearman's rank-order correlation r_s . In all tests, $p < 0.05$ was considered statistically significant. Since p -values alone are not exhaustively informative, particularly when samples are very small as in the present case series, we additionally calculated effect sizes using G*Power 3.²⁷ In

Wilcoxon's test, $d_z \geq 0.80$ indicates a large, $d_z \geq 0.50$ a moderate, and $d_z \geq 0.20$ a small effect. Spearman's correlation coefficient r_s itself constitutes a measure of effect size, with $r_s \geq 0.50$ indicating a large, $r_s \geq 0.30$ a moderate, and $r_s \geq 0.10$ a small effect.²⁸

Results

Pooled Results

Overall, VAS-scores significantly decreased from 6.40 ± 1.14 at baseline to 1.80 ± 2.49 at follow-up, and the effect was very large ($p = 0.04$, $d_z = 2.22$, 2-tailed; Figure 1). There was no significant association between outcome and age ($r_s = 0.05$, $p = 0.94$, 2-tailed), duration of symptoms ($r_s = 0.36$, $p = 0.55$, 2-tailed), follow-up interval ($r_s = 0.62$, $p = 0.27$, 2-tailed) or laterality ($r_s = 0.29$, $p = 0.64$, 2-tailed).

Patient 1

The 52 yr-old office worker had been suffering from LEP of the right elbow for more than 6wks. Symptoms were lateral epicondyle tenderness and pain radiating along the forearm, especially when weight-lifting and lifting (heavy) files or typing (VAS=6). ROM was free. The MRI-scan showed a partial ECRB rupture and typical epicondylitis signs. 11wks after the ACP® Tendo-injection, the patient was pain-free (VAS=0) and resumed weight-lifting. ROM was still unrestricted. The MRI-scan at follow-up showed extensive defect healing of the partial rupture and residual epicondylitis signs.

Patient 2

The 49 yr-old had also been suffering from LEP of the right elbow with radial epi-

condyle tenderness for about 6wks. He was experiencing pain (VAS=6) at handshaking and grabbing or lifting even light objects of daily use. ROM was unrestricted. The initial MRI-scan showed no rupture of the extensor tendons, but extensive edema both in the tendinous origin and in the paratendinous soft tissue. 7wks post-treatment, pain only slightly decreased (VAS=4), and the patient was still complaining about stiffness of the elbow in the morning with radiating pain after warming-up. The MRI-scan showed no relevant improvement. ROM was still free. The patient consequently received additional shock-wave therapy without success. Finally, 3 more ACP injections (without rhCollagen) led to restitution ad integrum.

Patient 3

The third patient's (49 yrs old, right elbow) symptoms (tenderness, contractional pain, VAS=7, free ROM) had been resistant to extensive conservative treatment including an orthosis, physical therapy and acupuncture for 7mths. The initial MRI-scan showed typical tendinopathy signs at the ECRB insertion without rupture. At 15-wk-follow-up, the patient was completely pain-free (VAS=0), experienced no tenderness at palpation and demonstrated a full ROM. The accompanying MRI-scan showed complete healing of the tendons without any residual tendinopathy signs.

Patient 4

The 42 yr-old professional cook had been complaining about lateral epicondyle tenderness and painful terminal wrist extension for 6mths (VAS=8) as documented by a partial rupture of the left ECRB tendon with discrete accompanying effusion in the MRI. Previous treatments (shock-wave and

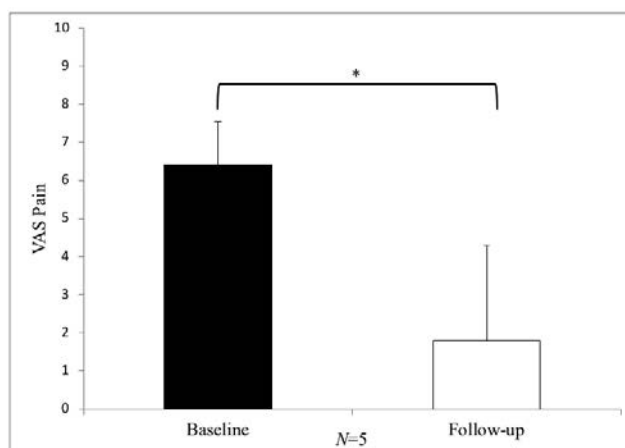


Figure 1. Mean VAS (Visual Analogue Scale) pain scores at baseline and 10.60wks after a single Arthrex ACP® Tendo injection. Error bars indicate standard deviations (SD). P-value was calculated by Wilcoxon's signed-rank test. * $p < 0.05$.

high-tone therapy, acupuncture) failed. At 13-wk-follow-up, pain slightly decreased (VAS=5), but the tenderness remained, and the patient was still not able to lift a pan, although ROM was free. Due to this unsatisfying clinical outcome, he decided for surgical treatment despite distinctly regressive signal alterations at the lateral epicondyle in the accompanying MRI-scan at follow-up.

Patient 5

The 51 yr-old had been suffering from typical LEP symptoms (lateral epicondyle tenderness, painful wrist extension) of the left elbow for 4wks (VAS=5 at full ROM). The MRI showed a partial ECRB rupture and a plica humero-radialis without impingement (Figure 2). At 7-wk-follow-up, the patient was pain-free (VAS=0 at full ROM) accompanied by an MRI-scan showing complete healing of the ECRB insertion (Figure 3).

Discussion

The present preliminary study demonstrates for the first time in literature positive subjective and objective short-term effects of a combined single-shot injection of ACP+rhCollagen (Arthrex ACP® Tendo) on LEP in 5 patients. Half of the patients may be regarded as chronic LEP patients that received all variety of standard therapeutic options that failed to cure the disease. All 5 patients reported lower pain scores at an average 10.60-wk-follow-up, and 4 patients showed improvement according to MRI including 2 cases of complete healing and 2 cases of defect healing or morphological regression of tendinopathy signs. Although the overall pain-reducing effect was both significant and large, patients benefited to a different extent: 3 patients showed both satisfactory clinical and MRI-results (Patients 1, 3, 5), one patient (no. 2) showed no relevant MRI-improvement and only slight clinical improvement requiring 3 additional ACP injections to attain complete healing, and another patient (no. 4) showed improved MRI-results, but no sufficient clinical improvement to resume his occupational duties (as a cook) which is why he decided to undergo surgery. The positive effect on Patient 3 (pre-treatment VAS=7 vs. post-treatment VAS=0 including restitution ad integrum according to MRI) seems particularly noteworthy, since the patient had already been extensively treated for 7mths without any clinical success. There was no effect of ACP+rhCollagen on ROM, as pre-treatment ROM was hardly restricted. None of the patients reported side effects. Positive outcome concerning pain was not signifi-

cantly associated with age, duration of symptoms, follow-up interval or laterality. With regard to follow-up interval, there was a descriptive association implying better outcome at longer follow-up intervals though. These results, however, should be interpreted with caution due to the small sample size and the restriction of range, especially with regard to age (42-52yrs). Interestingly, the 3 patients with partial ECRB ruptures benefited most (post-treatment VAS=0 in all 3 cases). This effect might be mediated by the properties of rhCollagen as a slow-releasing growth factor depot on the one hand, and as a scaffold for cell proliferation on the other hand, which could be particularly relevant in the healing process of a (partially) ruptured tendon. The possibility to combine the ACP+rhCollagen-injection with LA is another practical advantage of the slow-releasing system surpassing the half-life of LA's with their detrimental effect on autologous blood

preparations.^{15,20} This feature might be even more important when administering ACP+rhCollagen, since the combined fluid is more viscous than pure ACP, thus requiring large-bore, *i.e.*, more painful, needles. Further, the potential of the combined ACP+rhCollagen-injection to foster complete healing via a single injection offers another major advantage compared with other non-surgical LEP treatments, such as steroid injections for instance: although still popular in the treatment of multiple degenerative and tendon-related orthopaedic conditions in general and LEP in specific, steroid injections are only short-term effective (approximately 4wks) and even associated with adverse long-term effects (>6wks), such as decreased tenocyte replication and collagen production as well as increased risk of tendon rupture,¹ especially after repeated injections. Although still little is known about the long-term effects of

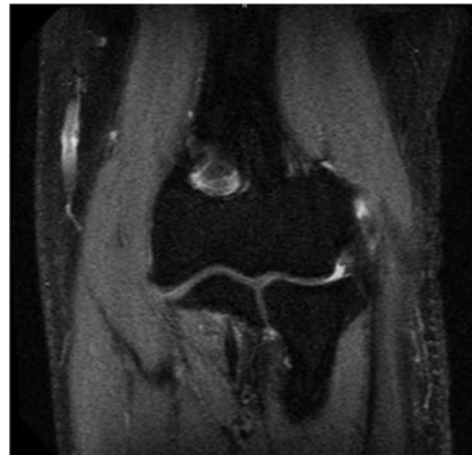

Figure 2. A coronal fat-suppressed T2-weighted pre-treatment MRI showing a partial rupture of the extensor carpi radialis brevis (ECRB) tendon and a plica humero-radialis without impingement in Patient 5.

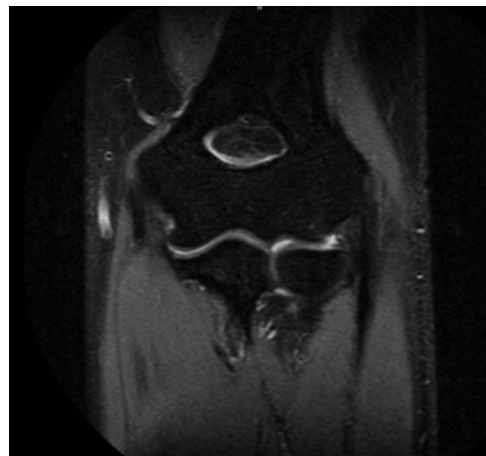


Figure 3. A coronal fat-suppressed T2-weighted MRI at 7-wk-follow-up showing complete healing of the insertion of the extensor carpi radialis brevis (ECRB) in Patient 5.

ACP+rhCollagen, the 5 present patients were examined at an average 10.60wk-follow-up without showing any adverse effects. Note, finally, that the encouraging lack of side effects might also be due to the favourable properties of the plant-derived – pure and non-allergenic – rhCollagen used in the present case series.²²⁻²⁵

The limitations of the present study are obvious: This study is of preliminary character including only 5 male patients at a relatively short follow-up without a control group. Our promising results, however, warrant future large-scaled, prospective, placebo-controlled, randomized clinical trials with longer follow-up intervals allowing to adequately examine the long-term effects of ACP+rhCollagen and to identify positive and negative outcome predictors.

Conclusions

A combined ACP+rhCollagen-injection seems to unite the advantages of autologous blood products with the benefits of scaffold materials in the treatment of LEP: The scaffold protects the growth factors from detrimental effects of LA's and enables a prolonged release of growth factors to the injury site potentially allowing a single injection to attain extensive long-term healing even in patients with chronic symptoms for some months. Due to the limitations of the present case series, however, these promising preliminary results need further investigation in future research.

References

- Kahlenberg CA, Knesek M, Terry MA. New Developments in the Use of Biologics and Other Modalities in the Management of Lateral Epicondylitis. *Biomed Res Int* 2015;2015:439309.
- Descatha A, Dale AM, Jaegers L, Herquelot E, Evanoff B. Self-reported physical exposure association with medial and lateral epicondylitis incidence in a large longitudinal study. *Occup Environ Med* 2013;70:670–3.
- Walker-Bone K, Palmer KT, Reading I, et al. Occupation and epicondylitis: a population-based study. *Rheumatology (Oxford)* 2012;51:305–10.
- Chen J, Wang A, Xu J, Zheng M. In chronic lateral epicondylitis, apoptosis and autophagic cell death occur in the extensor carpi radialis brevis tendon. *J Shoulder Elbow Surg* 2010;19:355–62.
- Borzini P, Mazzucco L. Tissue regeneration and in loco administration of platelet derivatives: clinical outcome, heterogeneous products, and heterogeneity of the effector mechanisms. *Transfusion* 2005;45:1759–67.
- Kraushaar BS, Nirschl RP. Tendinosis of the elbow (tennis elbow). Clinical features and findings of histological, immunohistochemical, and electron microscopy studies. *J Bone Joint Surg Am* 1999;81:259–78.
- Baltzer AWA, Stosch D, Seidel F, Ostapczuk MS. Low level laser therapy A narrative literature review on the efficacy in the treatment of rheumatic orthopaedic conditions. *Z Rheumatol* 2017;76:806–12.
- Bjordal JM, Lopes-Martins RA, Joensen J, et al. A systematic review with procedural assessments and meta-analysis of low level laser therapy in lateral elbow tendinopathy (tennis elbow). *BMC Musculoskelet Disord* 2008;9:75.
- Buchbinder R, Johnston RV, Barnsley L, et al. Surgery for lateral elbow pain. *Cochrane Database Syst Rev* 2011:CD003525.
- Krogh TP, Bartels EM, Ellingsen T, et al. Comparative effectiveness of injection therapies in lateral epicondylitis: a systematic review and network meta-analysis of randomized controlled trials. *Am J Sports Med* 2013;41:1435–46.
- Krosiak M, Murrell GAC. Surgical Treatment of Lateral Epicondylitis: A Prospective, Randomized, Double-Blinded, Placebo-Controlled Clinical Trial. *Am J Sports Med* 2018;363546517753385.
- Widstrom L, Slattengren A. Do autologous blood and PRP injections effectively treat tennis elbow? *J Fam Pract* 2016;65:635.
- van Hauten C, Ostapczuk MS, Baltzer AWA. Sonographic standard values for the patellar tendon in competitive athletes. *Z Orthop Unfall* 2013;151:142–8.
- Baltzer AWA, Ostapczuk MS, Stosch D, et al. A new treatment for hip osteoarthritis: clinical evidence for the efficacy of autologous conditioned serum. *Orthop Rev (Pavia)* 2013;5:59–64.
- Bausset O, Magalon J, Giraudo L, et al. Impact of local anaesthetics and needle calibres used for painless PRP injections on platelet functionality. *Muscles Ligaments Tendons J* 2014;4:18–23.
- Cho JW, Kim SA, Lee KS. Platelet-rich plasma induces increased expression of G1 cell cycle regulators, type I collagen, and matrix metalloproteinase-1 in human skin fibroblasts. *Int J Mol Med* 2012;29:32–6.
- Edwards DR, Murphy G, Reynolds JJ, et al. Transforming growth factor beta modulates the expression of collagenase and metalloproteinase inhibitor. *EMBO J* 1987;6:1899–904.
- Lynch SE, Nixon JC, Colvin RB, Antoniadou HN. Role of platelet-derived growth factor in wound healing: synergistic effects with other growth factors. *Proc Natl Acad Sci U S A* 1987;84:7696–700.
- Mazzocca AD, McCarthy MBR, Chowanec DM, et al. The positive effects of different platelet-rich plasma methods on human muscle, bone, and tendon cells. *Am J Sports Med* 2012;40:1742–9.
- Carofino B, Chowanec DM, McCarthy MB, et al. Corticosteroids and local anesthetics decrease positive effects of platelet-rich plasma: an in vitro study on human tendon cells. *Arthroscopy* 2012;28:711–9.
- Pollack SV. Silicone, fibrel, and collagen implantation for facial lines and wrinkles. *J Dermatol Surg Oncol* 1990;16:957–61.
- Stein H, Wilensky M, Tsafrir Y, et al. Production of bioactive, post-translationally modified, heterotrimeric, human recombinant type-I collagen in transgenic tobacco. *Biomacromolecules* 2009;10:2640–5.
- Shilo S, Roth S, Amzel T, et al. Cutaneous wound healing after treatment with plant-derived human recombinant collagen flowable gel. *Tissue Eng Part A* 2013;19:1519–26.
- Shoseyov O, Posen Y, Grynspan F. Human collagen produced in plants: more than just another molecule. *Bioengineered* 2014;5:49–52.
- Willard JJ, Drexler JW, Das A, et al. Plant-derived human collagen scaffolds for skin tissue engineering. *Tissue Eng Part A* 2013;19:1507–18.
- Freyd M. The graphic rating scale. *J Educ Psych* 1923;14:83–102.
- Cohen J. *Statistical power analysis for the behavioral sciences*. 2nd edition. New York: Psychology Press; 1988.
- Faul F, Erdfelder E, Lang A-G, Buchner A. G*Power 3: a flexible statistical power analysis program for the social, behavioral, and biomedical sciences.