



# Ulnar Collateral Ligament Repair With Suture Augmentation

David P. Trofa, M.D., Joseph M. Lombardi, M.D., Manish S. Noticewala, M.D., and Christopher S. Ahmad, M.D.

**Abstract:** Reconstruction of the ulnar collateral ligament (UCL) remains the gold standard for treating overhead throwing athletes with valgus instability secondary to UCL pathology. Although surgical techniques for reconstruction have evolved over time, current methods allow 90% of patients to return to their preinjury level of activity. Despite encouraging results with reconstruction, UCL repair remains a valuable treatment option for patients with UCL pathology fitting specific criteria. There are a number of advantages associated with a direct repair, and further, the development of collagen-coated sutures for ligament repair augmentation makes this procedure an attractive surgical option under the correct circumstances. This article provides a detailed description and video demonstration of the surgical steps used to perform a UCL repair with suture augmentation.

The primary restraint to valgus stress of the elbow is provided by the ulnar collateral ligament (UCL). A UCL injury was considered career-ending until Dr. Jobe described the first reconstruction technique in 1986.<sup>1</sup> Over the past 3 decades, as the incidence of UCL injuries has continued to rise, particularly among adolescents, treatment options have evolved.<sup>2</sup> Plausible options for UCL injury management includes rest, bracing, structured rehabilitation with graduated return to throwing, platelet-rich plasma injections, and operative treatment in the form of reconstruction or repair.<sup>2,3</sup>

Although reconstruction remains the gold standard surgical treatment for UCL pathology in overhead-throwing athletes, a direct repair has certain

advantages. These include restoration of normal anatomy, eliminating the need for an autograft and thus avoiding the various complications associated with graft harvest, and comparable return-to-sport rates as reconstruction with a more rapid postoperative recovery.<sup>4</sup> These advantages are largely based on proper patient selection. For instance, a repair may be indicated in patients sustaining either a proximal or distal avulsion tear. The ligament should not be damaged throughout its entire course, as is more common in professional athletes, and there should be no evidence of chronic attritional disease.<sup>5</sup> Indications of chronic disease may include calcifications on magnetic resonance imaging.

The purpose of this article is to provide a detailed description and video of the steps necessary to perform an anatomic repair of the UCL with augmentation using a collagen-coated suture tape. A muscle-splitting approach is employed as has been previously described.<sup>6</sup>

## Surgical Technique

### Patient Positioning and Anesthesia

A preoperative elbow examination should be performed on the day of surgery to confirm UCL pathology. The surgeon should also carefully evaluate for ulnar nerve symptoms or valgus extension overload that might necessitate either transposition or arthroscopic debridement, respectively. The procedure is typically performed under regional anesthesia with sedation. The patient is positioned supine with the operative extremity

*From the Department of Orthopaedics, New York Presbyterian, Columbia University Medical Center, New York, New York, U.S.A.*

*The authors report the following potential conflicts of interest or sources of funding: C.S.A. receives board membership fees from Baseball Health Network and the Sports Science Institute of America; is a paid consultant of Arthrex; receives royalties from Arthrex, Lead and Player Publishing; and receives basic science research support from Arthrex and Smith & Nephew. Full ICMJE author disclosure forms are available for this article online, as supplementary material.*

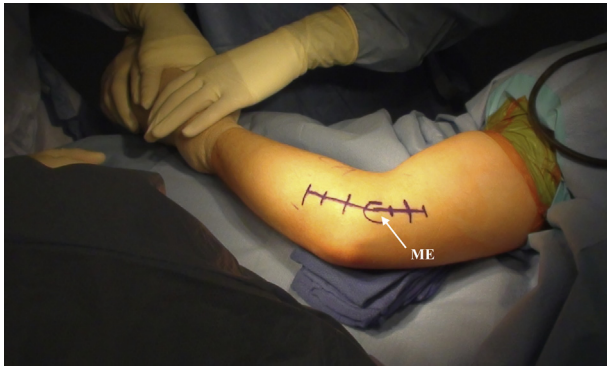*Received May 18, 2017; accepted August 10, 2017.*

*Address correspondence to David P. Trofa, M.D., Department of Orthopaedics, New York Presbyterian, Columbia University Medical Center, 622 West 168th St, PH 11-1130, New York, NY 10032, U.S.A. E-mail: davidtrofa@gmail.com*

© 2017 The Authors. Published by Elsevier Inc. on behalf of the Arthroscopy Association of North America. This is an open access article under the CC BY-NC-ND license (<http://creativecommons.org/licenses/by-nc-nd/4.0/>).

2212-6287/17690

<https://doi.org/10.1016/j.eats.2017.08.052>



**Fig 1.** The patient is placed in the supine position with the operative right extremity on a hand table. An 8- to 10-cm incision is marked over the medial elbow. The medial epicondyle (ME) is outlined.

on an arm table ([Video 1](#)). A nonsterile tourniquet is placed proximally around the upper arm.

### Incision and Exposure

After sterile prep and draping, an 8- to 10-cm incision is made over the medial epicondyle ([Fig 1](#)). The surgeon should note the course of the ulnar nerve and take care to avoid its path. Dissection is carried down through the subcutaneous tissues, and bipolar cautery can be used to coagulate any crossing superficial vessels. Care is taken to preserve any branches of the medial antebrachial cutaneous nerve encountered during dissection. These branches are usually found anterior and distal to the medial epicondyle. Next, an incision is made in the raphe of the flexi carpi ulnaris fascia in line with the skin incision ([Fig 2A](#)). Blunt dissection is then performed using a periosteal elevator to expose the UCL ([Fig 2B](#)). In this case, the superficial fibers of the UCL appear healthy and undamaged; however, if the UCL has any signs of attritional disease, the repair should be aborted in favor of a reconstruction. If the surgeon determines that the ligament can be repaired, it is incised from the sublime tubercle to the medial epicondyle in line with its fibers to expose the underlying joint ([Fig 2C](#)). In this case, once the ligament is incised, the distal avulsion off of the sublime tubercle is evident.

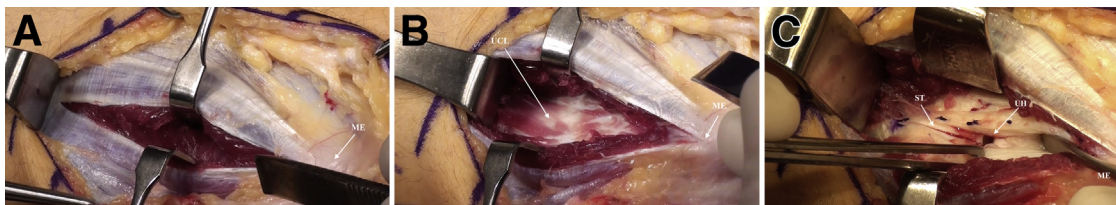
### UCL Repair

Periosteum and soft tissue are debrided from the distal footprint of the UCL at the sublime tubercle to stimulate healing for the repair. Next, a 3.5-mm nonabsorbable suture anchor (SwiveLock, Arthrex, Naples, FL) is placed by drilling and tapping a tunnel at the anatomic UCL origin on the sublime tubercle as this is the torn end of the native ligament ([Fig 3A](#)). This anchor is loaded with 2-mm FiberTape (Arthrex) that is collagen coated and a size 0 high-tensile nonabsorbable suture. After the anchor is inserted, individual limbs of the size 0 suture are passed through the distal aspects of the anterior and posterior limbs of the ligament and tied with the elbow reduced in varus. The suture knot is placed anteriorly so that it does not sit directly on the ligament and is away from the ulnar nerve to prevent any irritation posteriorly. This suture repairs the native ligament directly to bone at the site of the avulsion.

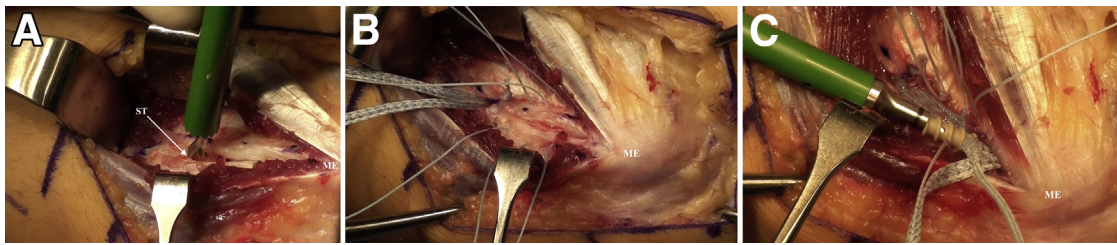
Next, the longitudinal UCL split is repaired from distal to proximal with size 0 high-tensile nonabsorbable sutures (Internal Brace, Arthrex). These sutures are placed in simple fashion with the needle passing from posterior to anterior to avoid iatrogenic injury to the ulnar nerve. In the example presented in [Video 1](#), a total of 3 simple sutures were placed ([Fig 3B](#)). These sutures are left untied until later in the case.

The isometric point of the UCL is then determined by tensioning the FiberTape on the medial epicondyle and adjusting its position so that it does not change length with elbow flexion and extension. A drill hole is created and tapped for a second 3.5-mm SwiveLock suture anchor at the identified isometric point in the medial epicondyle. Prior to placement of this anchor, all of the simple sutures used for the primary repair are tied except for the most proximal one. The FiberTape is then loaded into the second SwiveLock anchor and inserted into the medial epicondyle with appropriate tensioning as the elbow is held in 40° to 60° of flexion and reduced in varus with the forearm supinated ([Fig 3C](#)).

After the second anchor is inserted, the last and most proximal simple repair suture is tied over the FiberTape to incorporate the repair construct and native ligament together. The excess tape and sutures are cut and elbow



**Fig 2.** Supine position, right elbow, illustrating the muscle-splitting approach. After superficial dissection, the FCU fascia is incised longitudinally from distal to proximal toward the medial epicondyle (ME) and the muscle is dissected bluntly (A). After blunt dissection is carried through the FCU muscle, the UCL is exposed from the sublime tubercle to the medial epicondyle (ME) (B). The native UCL is then incised in line with its fibers from the sublime tubercle (ST) to the medial epicondyle (ME), exposing the underlying ulnohumeral (UH) joint (C). (FCU, flexor carpi ulnaris; UCL, ulnar collateral ligament.)



**Fig 3.** Supine position, right elbow. Identification of the UCL insertion on the sublime tubercle (ST) to prepare a drill hole for a suture anchor loaded with collagen-coated tape and a size 0 high-tensile nonabsorbable repair suture. The medial epicondyle (ME) is labeled for orientation (A). Appearance of the UCL after distal repair and placement of 3 simple sutures from distal to proximal (B). The collagen-coated tape is placed through the eyelet of a second suture anchor that is placed into the isometric point of the ME (C). (UCL, ulnar collateral ligament.)

motion is assessed. Finally, because the native insertional footprint of the UCL over the sublime is broad, the additional ligament distal to the anchor can be repaired with a simple suture. This final suture completes the UCL repair (Fig 4). The wound is then closed in layers. The repair is protected in a splint set in about 75° of flexion.

### Postoperative Rehabilitation

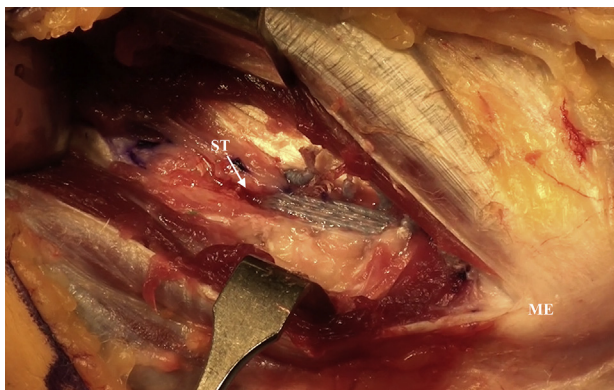
The patient is discharged home the same day. The splint is removed 5 to 7 days postoperatively to initiate ROM and strengthening in a protective hinged elbow brace. By 10 weeks postoperatively, a supervised throwing program is initiated with the goal of returning to competition by 6 months postoperatively.

### Discussion

The gold standard treatment for UCL injury in high-performance throwers is a UCL reconstruction, the technique of which has evolved significantly over time with varying degrees of success at returning athletes to sport. Of these various techniques, systematic reviews have suggested that the docking technique may have lower complications and higher return-to-play rates

compared with others, and a recent survey study found that this technique is the most preferred among Major League Baseball (MLB) team orthopaedic surgeons.<sup>7,8</sup> However, a nonanatomic treatment may not be necessary for all patients with UCL pathology. This manuscript presents a technique for UCL repair indicated in patients with tears isolated to either the proximal or distal aspect of the ligament.

The advantages of an anatomic repair are many and outlined in Table 1; nevertheless, as reviewed by Erickson et al.,<sup>4</sup> historically the results of UCL repair were inferior to reconstruction, which led to their early abandonment. For instance, in 1992 Conway et al.<sup>10</sup> reported a 50% successful return to prior activity level in 14 patients, with only 2 (29%) of 7 professional baseball players being able to return to their same levels of play. However, appropriate patient selection can lead to successful treatment as detailed in a case series by Savoie et al.<sup>5</sup> in 2008. This study found a 96.7%



**Fig 4.** Supine position, right elbow. Final appearance of the UCL repair with suture augmentation. The sublime tubercle (ST) and medial epicondyle (ME) are labeled for orientation. (UCL, ulnar collateral ligament.)

**Table 1.** Advantages and Disadvantages of Ulnar Collateral Ligament Repair

#### Advantages

- Avoids the need for a graft harvest, limiting potential graft site morbidity such as pain, wound infection, and/or damage to surrounding neurovascular structures.
- Preserves the patient's native anatomy and proprioception.
- Limited bone loss as the technique does not require bone tunnels.
- Comparable biomechanics to a UCL reconstruction in regard to ultimate failure strength, gap formation, and valgus stability.<sup>9</sup>
- Suture augmentation affords patients quicker return to play as a result of accelerated rehabilitation vs reconstruction.
- The largest series of UCL repairs found a high rate (96.7%) of return to throwing in properly indicated patients.<sup>5</sup>

#### Disadvantages

- Further investigations are necessary to fully evaluate the long-term functional benefits of a UCL repair; as such UCL reconstruction remains the gold standard treatment for medial instability in throwers given its long track record of success.
- Clinical application of UCL repair is limited to a select subset of patients with UCL pathology.
- There is a potential to overconstrain the elbow if the construct is placed too tightly.

UCL, ulnar collateral ligament.



**Table 2.** Surgical Pearls and Potential Pitfalls of Ulnar Collateral Ligament Repair

## Pearls

- There is no need for routine ulnar nerve exposure and/or transposition.
- The muscle-splitting approach avoids soft tissue damage.
- The first suture anchor should be placed at the torn end of the ligament so that the avulsed ligament can be directly repaired to bone.
- Identification of the isometric point on the medial epicondyle is essential for proper suture anchor placement. Anterior placement will result in tightness in extension whereas posterior placement will result in tightness with flexion.
- Tension the construct in 40°-60° of flexion, forearm supination, and varus.

## Pitfalls

- This technique is not meant to repair attenuated or chronically injured ligaments; as such, appropriate patient selection is paramount to success.
- Careful attention should be paid to the location of the ulnar nerve to prevent iatrogenic injury.
- A firm understanding of anatomic landmarks is necessary for appropriate anchor placement.
- Avoid overextension of the construct when placing the second suture anchor to prevent overconstraining the medial elbow.

return-to-play rate within 6 months of UCL repair in young players (average age 17.2 years) with injuries isolated to the proximal, distal, or both ends of the ligament. Despite being published nearly a decade ago, this case series represents the largest and most recent investigation of UCL repairs in the literature.

Augmentation with strong collagen-coated tape as described in the current study is a novel surgical technique. The theoretic advantage of augmentation is accelerated rehabilitation as the construct takes stress off of the repair while it heals, allowing quicker return to play. Additionally, this technique was proven in a recent biomechanical study to have less medial gaping and no differences in time-zero strength or ultimate failure load compared with UCL reconstruction.<sup>9</sup> At this time, there are no clinical comparative studies of UCL repair and reconstruction, although given the distinct surgical indications for these procedures, such an investigation may not be necessary.

In conclusion, UCL repair with augmentation is a powerful addition to the sports medicine physician's

armamentarium. It has the advantages of quicker return to play compared to reconstruction and equivalent success rates as reconstruction in appropriately selected patients, and it obviates the need for a graft and nonanatomic reconstruction. The pearls and pitfalls of our surgical procedure are outlined in Table 2.

## References

1. Jobe FW, Stark H, Lombardo SJ. Reconstruction of the ulnar collateral ligament in athletes. *J Bone Joint Surg Am* 1986;68:1158-1163.
2. Bruce JR, Andrews JR. Ulnar collateral ligament injuries in the throwing athlete. *J Am Acad Orthop Surg* 2014;22:315-325.
3. Dines JS, Williams PN, ElAttrache N, et al. Platelet-rich plasma can be used to successfully treat elbow ulnar collateral ligament insufficiency in high-level throwers. *Am J Orthop (Belle Mead NJ)* 2016;45:296-300.
4. Erickson BJ, Bach BR, Verma NN, Bush-Joseph CA, Romeo AA. Treatment of ulnar collateral ligament tears of the elbow. *Orthop J Sport Med* 2017;5. 232596711668221.
5. Savoie FH, Trenhaile SW, Roberts J, Field LD, Ramsey JR. Primary repair of ulnar collateral ligament injuries of the elbow in young athletes: A case series of injuries to the proximal and distal ends of the ligament. *Am J Sports Med* 2008;36:1066-1072.
6. Camp CL, Dines JS, Voleti PB, James EW, Altchek DW. Ulnar collateral ligament reconstruction of the elbow: The docking technique. *Arthrosc Tech* 2016;5:e519-e523.
7. Erickson BJ, Harris JD, Fillingham YA, et al. Treatment of ulnar collateral ligament injuries and superior labral tears by Major League Baseball team physicians. *Arthroscopy* 2016;32:1271-1276.
8. Chang ES, Dodson CC, Ciccotti MG. Comparison of surgical techniques for ulnar collateral ligament reconstruction in overhead athletes. *J Am Acad Orthop Surg* 2016;24:135-149.
9. Dugas JR, Walters BL, Beason DP, Fleisig GS, Chronister JE. Biomechanical comparison of ulnar collateral ligament repair with internal bracing versus modified jobe reconstruction. *Am J Sports Med* 2016;44:735-741.
10. Conway JE, Jobe FW, Glousman RE, Pink M. Medial instability of the elbow in throwing athletes. Treatment by repair or reconstruction of the ulnar collateral ligament. *J Bone Joint Surg Am* 1992;74:67-83.