

Sudden Atelectasis and Respiratory Failure in a Neutropenic Patient: Atypical Presentation of Pseudomembranous Necrotizing Bronchial Aspergillosis

Ji Yun Noh¹, Seok Jin Kim², Eun Hae Kang¹, Bo Kyoung Seo³, Kyoung Ho Rho⁴, Yang-Seok Chae⁵,
and Byung Soo Kim¹

¹Department of Internal Medicine, Korea University Medical Center; ²Department of Internal Medicine, Samsung Medical Center, Sungkyunkwan University School of Medicine; Departments of ³Radiology, ⁴Laboratory Medicine, and ⁵Pathology, Korea University Medical Center, Seoul, Korea

Pseudomembranous necrotizing bronchial aspergillosis (PNBA) is a rare form of invasive aspergillosis with a very poor prognosis. The symptoms are non-specific, and the necrotizing plugs cause airway obstruction. Atelectasis and respiratory failure can be the initial manifestations. Recently, we treated an immunocompromised patient with PNBA, who presented with a sudden onset of atelectasis and acute respiratory failure. There were no preceding signs except for a mild cough and one febrile episode. Bronchoscopy revealed PNBA, and *Aspergillus nidulans* was cultured from the bronchial wash.

Keywords: Aspergillosis; Pneumonia; Neutropenia

INTRODUCTION

Pseudomembranous necrotizing bronchial aspergillosis (PNBA) is a rare manifestation of *Aspergillus* infection. Since the first report of this condition in a patient with hemophilia and acquired immune deficiency syndrome [1], most cases have occurred in immunocompromised patients [2], and it is identified in an immunocompetent host only rarely [3]. The clinical manifestations are usually non-specific, and include fever, cough, chest pain, hemoptysis, and dyspnea [4]. On physical examination, wheezing may be a sign of PNBA, since the necrotizing material produced can cause airway obstruction. However, initial suspicion of PNBA

is uncommon since wheezing has many other possible causes. Clinicians might thus neglect consideration of PNBA and delay diagnosis, resulting in a poor treatment outcome [2]. Thus, a high index of suspicion and early diagnosis are important. We recently treated an immunocompromised patient with PNBA who presented with a sudden onset of atelectasis and acute respiratory failure.

CASE REPORT

A 39-year-old female with a diagnosis of acute myeloid leukemia with multi-lineage dysplasia was treated

Received : June 8, 2008

Revised : July 1, 2008

Accepted: July 23, 2008

Correspondence to Seok Jin Kim, M.D.

Department of Internal Medicine, Samsung Medical Center, Sungkyunkwan University School of Medicine, 81 Irwon-ro, Gangnam-gu, Seoul 135-710, Korea

Tel: 82-2-3410-1766, Fax: 82-2-3410-1754, E-mail: kstwoh@skku.edu

Copyright © 2012 The Korean Association of Internal Medicine

This is an Open Access article distributed under the terms of the Creative Commons Attribution Non-Commercial License (<http://creativecommons.org/licenses/by-nc/3.0/>) which permits unrestricted non-commercial use, distribution, and reproduction in any medium, provided the original work is properly cited.

with induction chemotherapy including idarubicin (12 mg/m² for 3 days) and cytarabine (100 mg/m² for 7 days). She failed to achieve complete remission, and was referred to our hospital for salvage chemotherapy, which was carried out with a FLAG-Ida regimen (fludarabine 30 mg/m² for 5 days, cytarabine 2 g/m² for 5 days, and idarubicin 12 mg/m² for 3 days, with granulocyte colony-stimulating factor support).

While the patient had neutropenia due to bone marrow suppression after chemotherapy, she had no episodes of febrile neutropenia. On the 21st day after chemotherapy, she complained of a mild cough. There was no fever and her breathing sounds were smooth on auscultation. Two days later the patient developed a fever of 38.3°C; however, her physical examination was unremarkable. We initiated empirical antibiotics, with cefepime 1 g q 12 hours and vancomycin 1 g q 12 hours for febrile neutropenia. Her chest X-ray showed a focal atelectasis (Fig. 1). The following morning, the patient complained of a sudden onset of dyspnea. Her vital signs were as follows: blood pressure 100/60 mmHg, heart rate 102 beats/min, respirations 32/min, and body temperature 37.0°C. By auscultation, breath sounds were nearly absent in the left-lung field. Laboratory findings, including arterial blood gas analysis, showed severe hypoxia and pancytopenia: pH 7.47, PaCO₂ 29.9 mmHg, PaO₂ 32.5 mmHg, HCO₃⁻ 21.3 mmol/L, saturation 67.7%, hemoglobin 7.4 g/dL, white blood cell count 100/μL, absolute neutrophil count 0/μL, and

platelet count 25,000/μL. Chest X-rays showed a diffuse radiopaque density with volume decrease of the entire left-lung field, suggesting the development of total left-lung atelectasis (Fig. 1). The patient was transferred to the intensive care unit and mechanical ventilator support was provided. Fiber-optic bronchoscopy revealed a large quantity of necrotic material at the distal trachea. The orifice of the left main bronchus was not visible because of a large quantity of grayish necrotic material covering the opening of the main bronchus (Fig. 2A). Bronchoscopic biopsy, at the necrotic membrane, was performed. Due to suspicion of PNBA, we started intravenous administration of amphotericin B (0.5 mg/kg/day for the first day, 0.75 mg/kg/day on the subsequent day, and 1 mg/kg/day for the following 8 days). Serum galactomannan was also positive, with a level of 2.0 (normal range, 0 to 0.5). Biopsy of the necrotic membrane revealed the presence of fungus with hyphae suggestive of *Aspergillus* (Fig. 2B). In spite of vigorous treatment in the intensive care unit for 5 days, the lung lesions rapidly progressed with worsening hypoxia. This infection was likely associated with the patient's persistent neutropenia, which was characterized by an absolute neutrophil count < 100/μL. We changed the antifungal agent to voriconazole due to the poor response to amphotericin B. Voriconazole was administered at 6 mg/kg q 12 hours for the loading dose and 4 mg/kg q 12 hours for the maintenance dose. However, respiratory distress progressed and the patient died 3 days later.

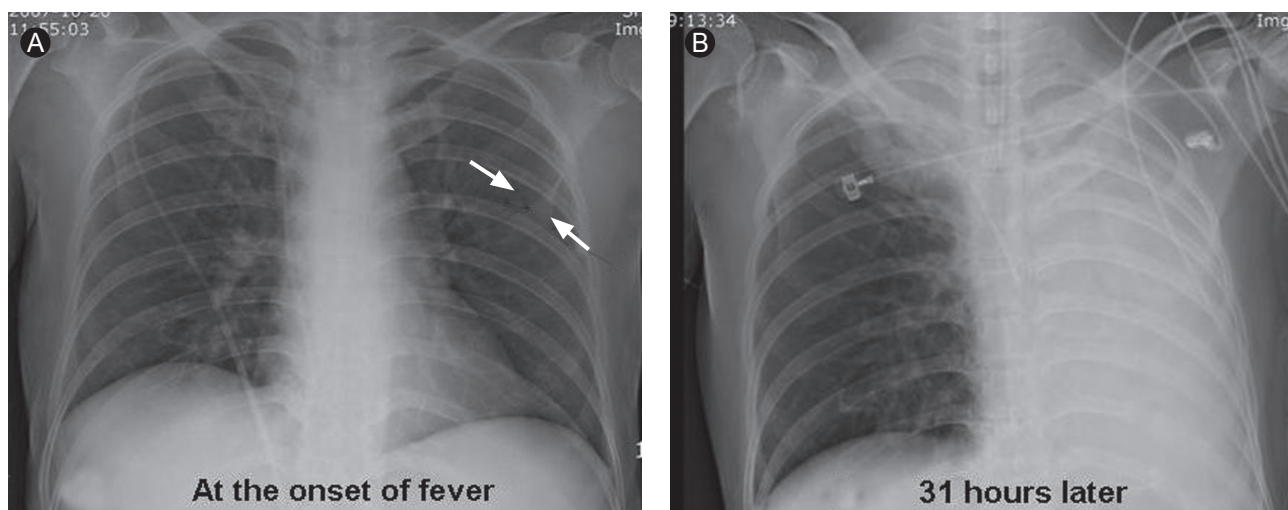


Figure 1. (A) Subsegmental atelectasis in the left mid-lung zone (arrows). (B) The atelectasis had rapidly progressed on the following day, together with development of left total lung atelectasis.

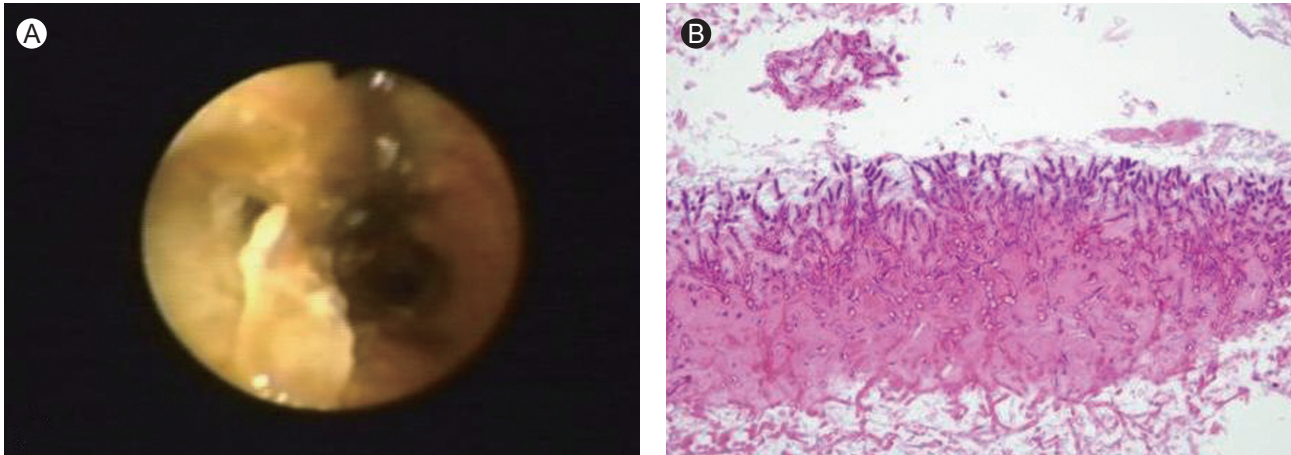


Figure 2. Bronchoscopic appearance of pseudomembranous *Aspergillus* tracheobronchitis. The opening of the left main bronchus was completely obliterated by mucosal necrotic inflammation; however, (A) the opening of the right main bronchus was intact. (B) Degenerated *Aspergillus* hyphae were observed (H&E, ×200).

Culture of the bronchial washing yielded *Aspergillus nidulans*.

DISCUSSION

Aspergillosis is a common opportunistic infection in immunocompromised patients; it is usually transmitted by the inhalation of spores [5]. Pulmonary aspergillosis is characterized by four major clinical syndromes, as follows: 1) invasive pulmonary aspergillosis, 2) chronic necrotizing aspergillosis, 3) aspergilloma, and 4) allergic bronchopulmonary aspergillosis [5]. PNBA is an unusual clinical form of invasive aspergillosis [4].

Most cases of PNBA occur in patients with a hematologic malignancy. However, some cases are associated with other chronic diseases, including chronic obstructive lung disease, diabetes, and lupus [2]. Therefore, the predisposing factors associated with the occurrence of PNBA include malignancy, AIDS, neutropenia for more than 3 weeks, transplant recipient status, and treatment with immune suppressive and cytotoxic drugs [4]. Acute leukemia and myelodysplastic syndrome with prolonged neutropenia are also risk factors for invasive aspergillosis. Thus, PNBA was a possible etiology, in this patient, from the first signs of respiratory failure and radiological abnormalities. However, her clinical presentation was atypical for PNBA due to the presence of only a mild cough and a small amount of whitish

sputum, and only a single febrile episode prior to acute respiratory failure. Thus, the presentation was abrupt and progressed rapidly with no prior signs. When we first noted her acute respiratory failure and abnormal X-ray findings, a massive pulmonary hemorrhage could not be excluded, because of her low platelet count. In a few previous reports of *Aspergillus* tracheobronchitis, chest radiographic findings showed atelectasis rather than infiltration [6,7]. However, the patients reported previously had preceding signs, including cough, dyspnea, and fever that persisted for a few days, and their clinical courses were not as rapid as that of our case. The present patient did not complain of dyspnea prior to acute respiratory failure. Bronchoscopy is the diagnostic procedure used for PNBA [2]. The most pathognomonic feature is the presence of a well-defined pseudomembrane covering the bronchial tree [8]. Thus, immediate bronchoscopy could facilitate early diagnosis of PNBA.

Among the PNBA cases reported previously, the most common *Aspergillus* species was *Aspergillus fumigatus* [2,4,7]. A few cases were associated with other *Aspergillus* spp.: *Aspergillus flavus* [8], *Aspergillus niger* [1], and *Aspergillus terreus* [6]. In our case, *A. nidulans* was cultured from the bronchial wash fluid. Infections by *A. nidulans* are relatively rare even in immunocompromised hosts. The standard treatment is aggressive antifungal therapy with amphotericin B, liposomal amphotericin B, voriconazole, or itraconazole [4]. One study reported topical amphotericin B application in

patients with bronchial aspergillosis [9]. Recently, novel strategies for the early treatment of invasive fungal infections have been reported [5]. Currently, voriconazole is considered for initial therapy of invasive aspergillosis [5]. *A. nidulans* and *A. terreus* are frequently resistant to amphotericin B [10]. Thus, amphotericin B-based treatment could result in failure of treatment for *A. nidulans* and *A. terreus* infections.

We used amphotericin B as the initial therapy, and changed to voriconazole due to the patient's poor response. *A. nidulans* was cultured after the patient died. Although the main treatment is an antifungal agent, penetration into the pseudomembranous necrotizing material is poor, so bronchoscopic removal might be an effective aid to treatment [6]. In this case, bronchoscopic removal was attempted, but failed.

Aspergillus tracheobronchitis is fatal in about 40% of cases despite appropriate therapy; a higher mortality rate, of above 90%, is reported in the PNBA subgroup. Another study reported an overall mortality rate of 80%, and 94% in ventilated patients [2]. This case report illustrates atypical manifestations of PNBA. When sudden atelectasis is found in an immunocompromised patient, especially in association with a hematologic malignancy, physicians should consider the possibility of PNBA, as this might be its initial manifestation.

Conflict of interest

No potential conflict of interest relevant to this article is reported.

REFERENCES

1. Pervez NK, Kleinerman J, Kattan M, et al. Pseudomembranous necrotizing bronchial aspergillosis: a variant of invasive aspergillosis in a patient with hemophilia and acquired immune deficiency syndrome. *Am Rev Respir Dis* 1985;131:961-963.
2. Tasci S, Glasmacher A, Lentini S, et al. Pseudomembranous and obstructive *Aspergillus* tracheobronchitis: optimal diagnostic strategy and outcome. *Mycoses* 2006;49:37-42.
3. Oh HJ, Kim HR, Hwang KE, et al. Case of pseudomembranous necrotizing tracheobronchial aspergillosis in an immunocompetent host. *Korean J Intern Med* 2006;21:279-282.
4. Patel N, Talwar A, Stanek A, Epstein M. Tracheobronchial pseudomembrane secondary to aspergillosis. *J Bronchology* 2006;13:147-150.
5. Zmeili OS, Soubani AO. Pulmonary aspergillosis: a clinical update. *QJM* 2007;100:317-334.
6. Routsis C, Kaltsas P, Bessis E, Rontogianni D, Kollias S, Rousos C. Airway obstruction and acute respiratory failure due to *Aspergillus* tracheobronchitis. *Crit Care Med* 2004;32:580-582.
7. Routsis C, Platsouka E, Prekates A, Rontogianni D, Paniara O, Rousos C. *Aspergillus* bronchitis causing atelectasis and acute respiratory failure in an immunocompromised patient. *Infection* 2001;29:243-244.
8. Arriero JM, Chiner E, Marco J, Mayol MJ, Serna M. Simultaneous obstructing and pseudomembranous necrotizing tracheobronchitis due to *Aspergillus flavus*. *Clin Infect Dis* 1998;26:1464-1465.
9. Boettcher H, Bewig B, Hirt SW, Moller F, Cremer J. Topical amphotericin B application in severe bronchial aspergillosis after lung transplantation: report of experiences in 3 cases. *J Heart Lung Transplant* 2000;19:1224-1227.
10. Kontoyiannis DP, Lewis RE, May GS, Osheroov N, Rinaldi MG. *Aspergillus nidulans* is frequently resistant to amphotericin B. *Mycoses* 2002;45:406-407.