

Received: 2019.03.03
Accepted: 2019.04.09
Published: 2019.06.25

Simultaneous Surgery for Inferior Vena Cava Leiomyosarcoma with Multiple Hepatic Metastases: A Justified Challenge

Authors' Contribution:
Study Design A
Data Collection B
Statistical Analysis C
Data Interpretation D
Manuscript Preparation E
Literature Search F
Funds Collection G

ABEF 1 **Hiroyuki Motodaka***
ABEF 1,2 **Bibek Aryal***
BEF 1 **Yoshiyuki Mizuta**
BF 1 **Nobuhiro Tada**
AB 1 **Kota Yoshikawa**
AB 1 **Mamoru Kaieda**
AB 3 **Yoshikazu Kawazu**
AB 3 **Tamahiro Kinjo**
ABEF 1 **Teruo Komokata**

1 Department of Surgery, Kagoshima Medical Center, National Hospital Organization, Kagoshima City, Kagoshima, Japan
2 Department of Cardiovascular and Gastroenterological Surgery, Graduate School of Medical and Dental Sciences, Kagoshima University, Kagoshima City, Kagoshima, Japan
3 Department of Cardiovascular Surgery, Kagoshima Medical Center, National Hospital Organization, Kagoshima City, Kagoshima, Japan

* Hiroyuki Motodaka and Bibek Aryal are Co-first authors

Corresponding Author: Teruo Komokata, e-mail: komokata@kagomc2.hosp.go.jp

Conflict of interest: None declared

Patient: Male, 42
Final Diagnosis: IVC leiomyosarcoma with multiple liver metastases
Symptoms: Abdominal pain
Medication: —
Clinical Procedure: IVC resection with hepatectomy
Specialty: Surgery

Objective: Unusual or unexpected effect of treatment

Background: Leiomyosarcoma of inferior vena cava (IVC), a rarely encountered malignancy originating from the smooth muscle cells of media of the IVC, frequently metastasize to the liver. The suggested treatment of choice of IVC leiomyosarcoma is radical en-bloc excision aimed to obtain a negative resection margin. There are a few reported cases of surgical management in patients with liver metastasis from IVC leiomyosarcoma.

Case Report: This report describes a simultaneous surgical approach for a case of IVC leiomyosarcoma with multiple liver metastases followed by chemotherapy.

Conclusions: Tumor volume reduction surgery of metastatic lesions combined with radical resection of the primary tumor may provide better survival benefit in patients with advanced IVC leiomyosarcoma.

MeSH Keywords: Leiomyosarcoma • Neoplasm Metastasis • Vena Cava, Inferior

Full-text PDF: <https://www.amjcaserep.com/abstract/index/idArt/915995>

1342 — 6 12



Background

Leiomyosarcoma of the inferior vena cava (IVC) is a rare variant of neoplasms that is most frequently encountered as a retroperitoneal soft tissue sarcoma. Vascular leiomyosarcomas comprises 1% to 2% of all soft tissue sarcomas and has poor prognosis as it often presents with intra or extra-luminal growth encroaching the surrounding tissues [1]. These rare neoplasms were initially considered inoperable and the use of chemotherapy targeted for these lesions was not encouraged. A pooled data analysis conducted from 1951 to 2013 recognized less than 400 reported cases of IVC leiomyosarcoma resection [2].

Current advances in surgical techniques, such as venous reconstruction and prosthetic replacement of the IVC, have enabled aggressive operative management. However, owing to the rarity of IVC leiomyosarcoma, there is no standard or overall effective chemo-radiotherapy regime that has been shown to improve overall survival. Keiffer et al., in their largest case series, suggested radical resection followed by adjuvant chemotherapy as the optimal therapeutic strategy for these tumors without metastasis at the time of initial diagnosis [3].

In this report, we present our experience in a patient with primary IVC leiomyosarcoma who presented with multiple liver metastases. This case-report discusses the usefulness of an extended surgical approach in delineating tumor burden, as well

as discusses the survival benefit of this approach in patients with advanced IVC leiomyosarcoma.

Case Report

A 42-year-old male visited a clinic with complaint of abdominal pain associated with loss of appetite that lasted for some weeks, he denied nausea or vomiting. On examination, an elastic hard mass could be felt in the epigastric region. Laboratory investigations, including hepatic function reserve, did not show any abnormalities. All the relevant tumor markers were negative (CEA: 0.7 ng/mL, CA19-9: 7.5 U/mL, AFP: 2.11 ng/mL). Computed tomography (CT) scans revealed a 9 cm tumor arising from the IVC at the junction of the right and left renal veins that compressed the horizontal portion of the duodenum (Figure 1). Multiple liver metastases were detected on segment 7 and 8 (Figure 2). The patient was then referred to our center for further evaluation and management. Fluorodeoxyglucose positron emission (FDG PET)/CT showed increase FDG in the IVC region (SUVmax=12.7) and relatively scanty accumulation in the liver lesions (Figure 3). Preoperative eco-guided endoscopic aspiration cytology of the primary lesion demonstrated fusiform cells with no atypia; the features were indicative of leiomyosarcoma. The Multidisciplinary Tumor Board at our hospital suggested resection of the tumor followed by chemotherapy.

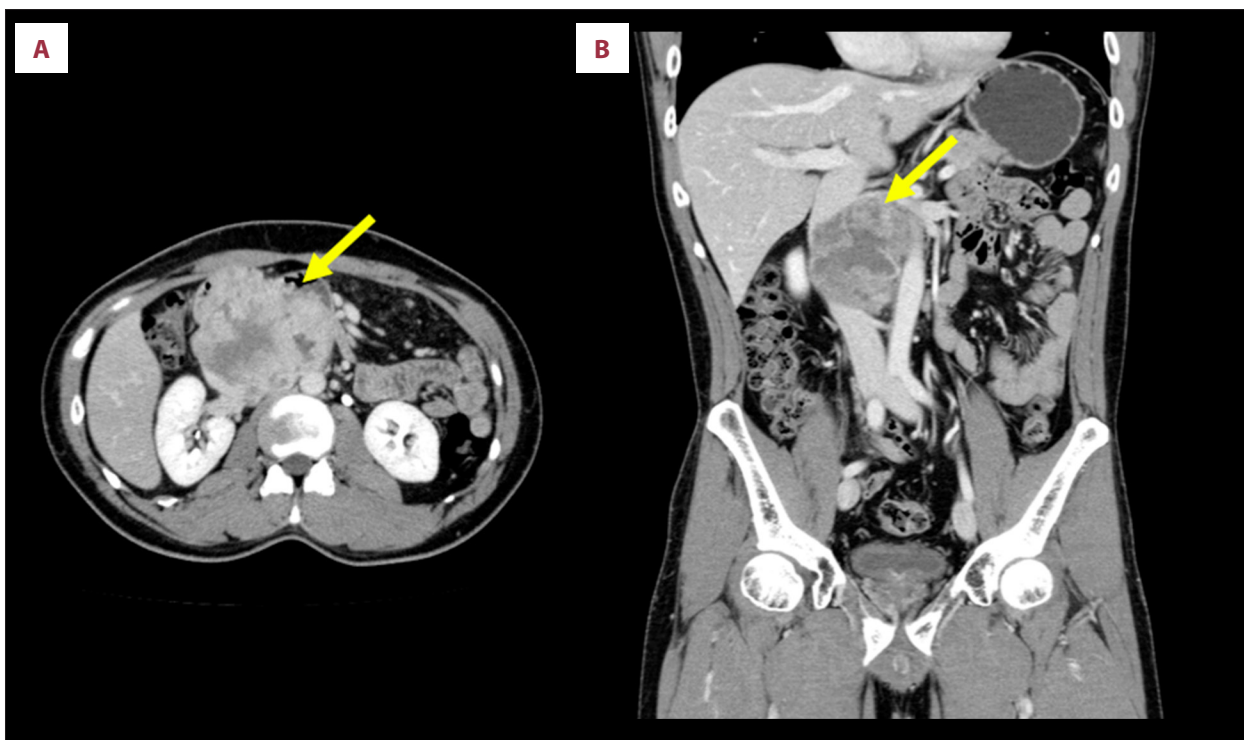


Figure 1. (A, B) Contrast-enhanced computed tomographic scans demonstrating a heterogeneous mass in the infrahepatic inferior vena cava (yellow arrows).

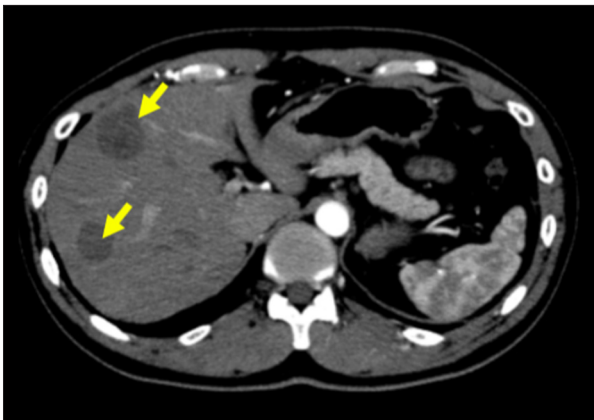


Figure 2. Contrast-enhanced computed tomographic scan showing metastatic lesions in the right lobe of the liver (yellow arrows).

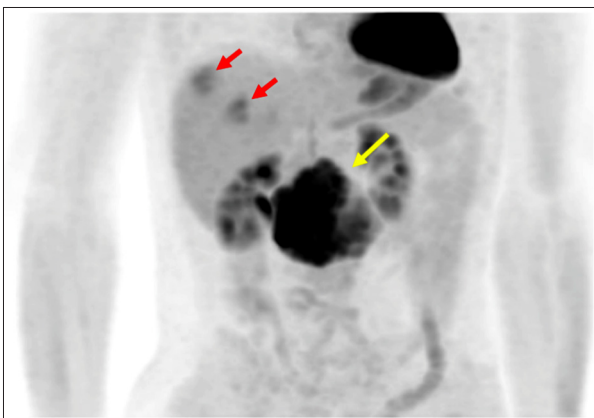


Figure 3. Positron emission tomographic image shows marked uptake in the inferior vena cava (yellow arrow) and 2 focal areas with relatively low standardized uptake value (SUV) in the liver suggestive of metastases (red arrows).

Laparotomy was performed via bilateral subcostal incision with an upper midline extension. The liver was mobilized and after Kocherization, the IVC tumor was explored (Figure 4) and dissected from the surrounding tissue. We opted for liver resection first in order to prevent bile contamination of the IVC graft and prevent the effect of heparinization in liver hemostasis during liver resection. We then performed partial resection of segment 7 followed by partial resection of segment 8–5. Several tiny small nodules were identified in the remnant liver, so at this point, we halted curative surgery and proceeded to tumor volume reduction surgery.

After systemic heparinization with 5000 units, the infrahepatic IVC was clamped at the caudal side above and below both renal veins, and the renal veins were then clamped. Complete resection of the IVC accompanied by division of the right and renal veins was performed. The caval reconstruction was

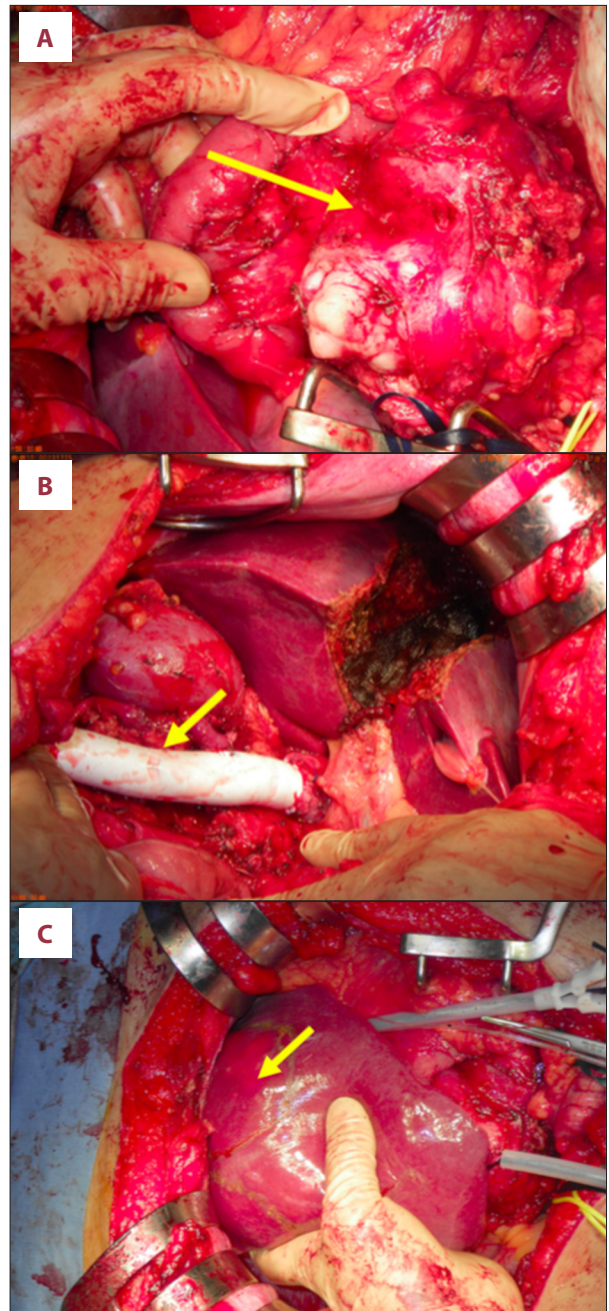


Figure 4. Intra-operative images: (A) macroscopic view of the inferior vena cava (IVC) tumor as seen after Kocher mobilization; (B) IVC reconstruction with PTFE graft; (C) metastatic lesion extending from segment 5 to 8.

performed via the interposition of a 15 mm ringed-PTFE tube graft after total vascular exclusion for 36 minutes. The right renal vein was reconstructed while the left renal vein was ligated and drained to the left adrenal vein, making the procedure less complex. Renal function remained intact after surgery. Postoperatively, in the intensive care unit (ICU), heparin anticoagulation was started on the first postoperative day (POD).

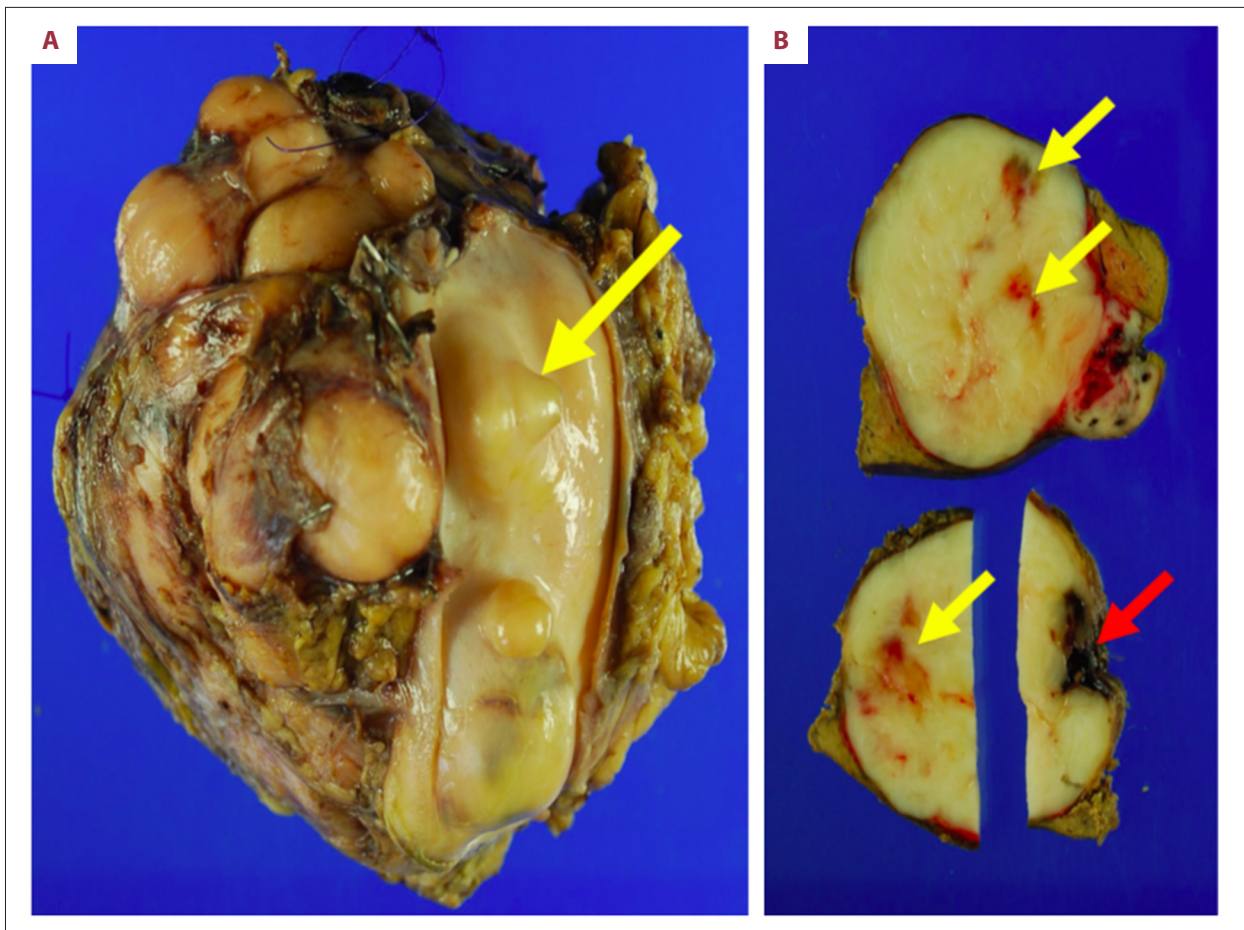


Figure 5. Images of the gross specimens: (A) inferior vena cava tumor with the lumen (tunica intima) (yellow arrow); (B) specimen of segment 7 of the liver. Cut-surfaces showing metastatic lesions. (yellow arrows) with macroscopic positive margin (red arrow).

An oral anti-platelet agent was started from the 3rd POD and heparin infusion was stopped on 10th POD.

The resected tumor-specimen weighed 330 g with expanded growth, hemorrhagic and black necrotic areas (Figure 5). Histopathological findings were consistent with leiomyosarcoma (Figure 6).

The postoperative period was characterized by no major surgical complications. The patient was discharged on the 29th POD. Doxorubicin and ifosfamide (AI) regimen was started as a first-line chemotherapy. The CT scan taken after 2 cycles of AI regimen revealed progressive disease of the metastatic lesion, and the regimen was switched to eribulin mesylate; the 4th cycle of eribulin was completed at the time this report was written. The last CT scan taken after introduction of eribulin showed stable disease, and we continued the same chemotherapy regimen. The patient's general condition was satisfactory at the 10th postoperative month.

Discussion

Leiomyosarcomas of the IVC are rare, slow-growing malignant tumors with a dismal prognosis. The 5-year survival rate is reported to range between 31% to 68% following complete macroscopic resection [2–7]. In cases with macroscopic positive margins (R2) resection, the survival is poor with ~0% in 5 years [8].

Liver metastasis accounted for ~21.5% of metastases, thus, representing a common site of metastases [3,5]. Although there have been some reported cases of concomitant hepatectomy and IVC resection and reconstruction [3,8,9], we could not find previously reported cases of simultaneous surgery for multiple liver metastases from IVC leiomyosarcoma. This would thus be the first reported case describing a simultaneous, aggressive and extended surgical approach in a patient with IVC leiomyosarcoma with multiple liver metastases. The aggressive surgical management used reduced the metastatic tumor load and was directed toward improving survival rather than having a curative intent.

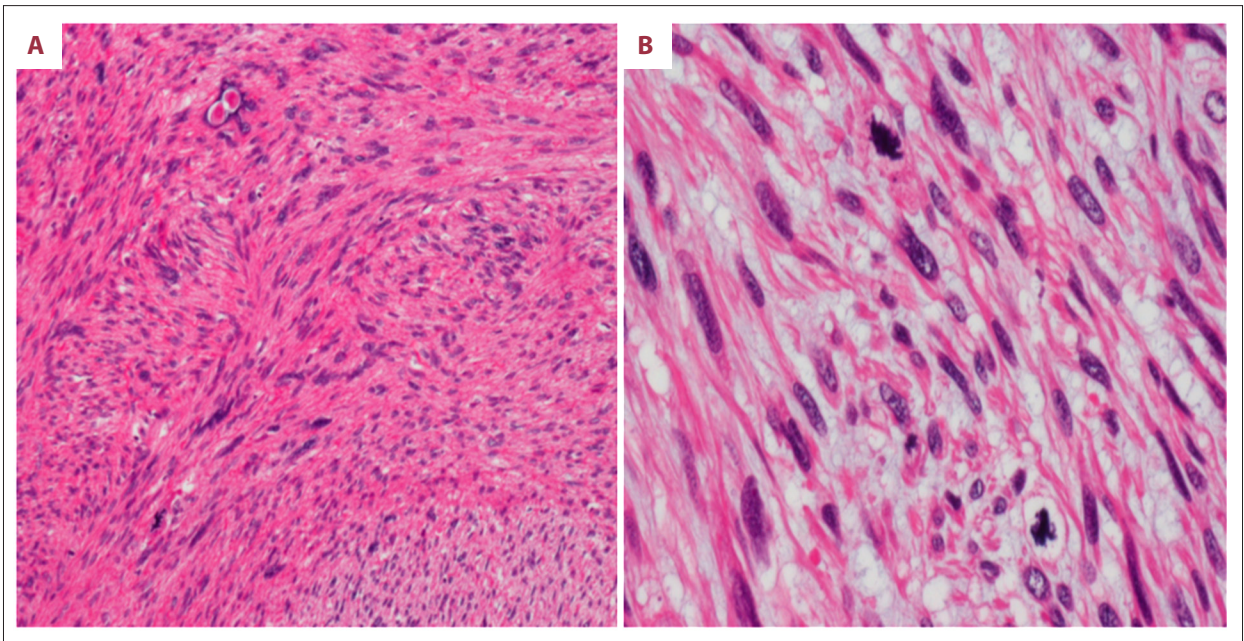


Figure 6. Histological images of leiomyosarcoma of the inferior vena cava: (A) hematoxylin and eosin (H&E) stain (200×) showing spindle cells; (B) H&E stain (400×) indicating smooth muscle lineage consistent with leiomyosarcoma. Marked nuclear pleomorphism can be seen.

Although survival rates appear to improve in patients treated with extended resection [1,5,10], no robust evidence has suggested that maximal resection of an advanced tumor offers the best chance for prolonged survival; the role of multi-visceral resection has not yet been established. Immune checkpoint inhibition has shown some promising results in patients with metastatic soft tissue sarcomas in some specific histologic subtypes [11]. The frequent metastases that develop despite local tumor control indicate that micro-metastases can often present at the time of primary tumor resection. Wisdom et al. suggested that the combination of immunotherapy and radiotherapy would likely elicit a systemic immune response and improve long-term survival in patients with soft tissue sarcomas by eradicating micro-metastases [11]. Despite results from some preclinical evidence, much remains to be explored regarding the potential of immunotherapies in treatment of soft tissue sarcomas. Similarly, clear evidence is still lacking on the role of radiotherapy or combining radiotherapy with immunotherapy. With no robust consensus on immunotherapy, and with immunotherapy not being covered by Japanese health insurance, it was not included in our consideration of treatment options for our patient. Although systemic chemotherapy, radiotherapy (neoadjuvant or adjuvant), or chemo- radiotherapy are considered, the role of these treatments is yet to be defined.

Previous publications have discussed the safety and advantages of radical and liberal excision for IVC leiomyosarcomas [3,5,8,12]. The surgical strategies can be tailored based on the extension of the tumor along the IVC. Despite advance surgical techniques

that allow extensive hepatic resection and concomitant IVC replacement, the morbid complexity associated with this kind of aggressive procedures warrants some attention.

In patients with an advanced stage of metastasis, overall survival is still unsatisfactory, thus this approach – using aggressive, liberal, and extended resection – should be given high-consideration as surgical resection still confers better prognosis for this condition, and these adopted techniques are now relatively safe. There is no previous evidence that has suggested an association between the extent of resection and survival in patients with advanced IVC leiomyosarcoma, which poses a challenge to identify the best surgical approach for these patients. Our patient was doing well on follow-up at 10 months of surgery; however, whether this approach to metastatic tumor volume reduction and radical resection of the primary tumor conferred a long-term survival benefit is not yet known.

Conclusions

Cytoreductive surgery, which is indicated in patients with various cancers, can also be a strategy for management of selected cases of retroperitoneal soft tissue sarcomas. Liberal and innovative surgical techniques such as concomitant liver and IVC resection and vessels reconstruction can be taken into consideration in patients with multiple liver metastases from IVC leiomyosarcomas.

References:

1. Mingoli A, Cavallaro A, Sapienza P et al: International registry of inferior vena cava leiomyosarcoma: Analysis of a world series on 218 patients. *Anticancer Res*, 1996; 16(5B): 3201–5
2. Wachtel H, Gupta M, Bartlett EK et al: Outcomes after resection of leiomyosarcomas of the inferior vena cava: A pooled data analysis of 377 cases. *Surg Oncol*, 2015; 24(1): 21–27
3. Kieffer E, Alaoui M, Piette JC et al: Leiomyosarcoma of the inferior vena cava: experience in 22 cases. *Ann Surg*, 2006; 244(2): 289–95
4. Hines OJ, Nelson S, Quinones-Baldrich WJ, Eilber FR: Leiomyosarcoma of the inferior vena cava: Prognosis and comparison with leiomyosarcoma of other anatomic sites. *Cancer*, 1999; 85(5): 1077–83
5. Hollenbeck ST, Grobmyer SR, Kent KC, Brennan MF: Surgical treatment and outcomes of patients with primary inferior vena cava leiomyosarcoma. *J Am Coll Surg*, 2003; 197(4): 575–79
6. Ito H, Hornick JL, Bertagnolli MM et al: Leiomyosarcoma of the inferior vena cava: Survival after aggressive management. *Ann Surg Oncol*, 2007; 14(12): 3534–41
7. Mann GN, Mann LV, Levine EA, Shen P: Primary leiomyosarcoma of the inferior vena cava: A 2-institution analysis of outcomes. *Surgery*, 2012; 151(2): 261–67
8. Teixeira FJR Jr., do Couto Netto SD, Perina ALF et al: Leiomyosarcoma of the inferior vena cava: Survival rate following radical resection. *Oncol Lett*, 2017; 14(4): 3909–16
9. Carvajal Lopez F, Garcia Domingo MI, Herrero Fonollosa E et al: [Inferior vena cava leiomyosarcoma with liver metastasis. Multi-organ resection with vascular reconstruction]. *Cir Esp*, 2013; 91(6): 394–95 [in Spanish]
10. Laskin WB, Fanburg-Smith JC, Burke AP et al: Leiomyosarcoma of the inferior vena cava: Clinicopathologic study of 40 cases. *Am J Surg Pathol*, 2010; 34(6): 873–81
11. Wisdom AJ, Mowery YM, Riedel RF, Kirsch DG: Rationale and emerging strategies for immune checkpoint blockade in soft tissue sarcoma. *Cancer*, 2018; 124(19): 3819–29
12. Dew J, Hansen K, Hammon J et al: Leiomyosarcoma of the inferior vena cava: surgical management and clinical results. *Am Surg*, 2005; 71(6): 497–501