


Intraductal fully covered self-expanding metal stents in the management of post-liver transplant anastomotic strictures: a UK wide experience

Wafaa Ahmed , Dave Kyle, Amardeep Khanna, John Devlin, David Reffitt, Zeino Zeino, George Webster, Simon Phillpotts, Robert Gordon, Gareth Corbett, William Gelson, Manu Nayar, Haider Khan, Matthew Cramp, Jonathan Potts, Waleed Fateen, Hamish Miller, Bharat Paranandi, Matthew Huggett, Simon M. Everett, Vinod S. Hegade, Rebecca O'Kane, Ryan Scott, Neil McDougall, Phillip Harrison and Deepak Joshi

Abstract

Background: Fully covered intraductal self-expanding metal stents (IDSEMS) have been well described in the management of post-liver transplant (LT) anastomotic strictures (ASs). Their antimigration waists and intraductal nature make them suited for deployment across the biliary anastomosis.

Objectives: We conducted a multicentre study to analyse their use and efficacy in the management of AS.

Design: This was a retrospective, multicentre observational study across nine tertiary centres in the United Kingdom.

Methods: Consecutive patients who underwent endoscopic retrograde cholangiopancreatography with IDSEMS insertion were analysed retrospectively. Recorded variables included patient demographics, procedural characteristics, response to therapy and follow-up data.

Results: In all, 162 patients (100 males, 62%) underwent 176 episodes of IDSEMS insertion for AS. Aetiology of liver disease in this cohort included hepatocellular carcinoma ($n=35$, 22%), followed by alcohol-related liver disease ($n=29$, 18%), non-alcoholic steatohepatitis ($n=20$, 12%), primary biliary cholangitis ($n=15$, 9%), acute liver failure ($n=13$, 8%), viral hepatitis ($n=13$, 8%) and autoimmune hepatitis ($n=12$, 7%). Early AS occurred in 25 (15%) cases, delayed in 32 (20%) cases and late in 95 (59%) cases. Age at transplant was 54 years (range, 12–74), and stent duration was 15 weeks (range, 3 days–78 weeks). In total, 131 (81%) had complete resolution of stricture at endoscopic re-evaluation. Stricture recurrence was observed in 13 (10%) cases, with a median of 19 weeks (range, 4–88 weeks) after stent removal. At removal, there were 21 (12%) adverse events, 5 (3%) episodes of cholangitis and 2 (1%) of pancreatitis. In 11 (6%) cases, the removal wires unravelled, and 3 (2%) stents migrated. All were removed endoscopically.

Conclusion: IDSEMS appears to be safe and highly efficacious in the management of post-LT AS, with low rates of AS recurrence.

Keywords: biliary stricture, ERCP, intra-ductal fully covered metal stent, liver transplant

Received: 15 May 2022; revised manuscript accepted: 24 July 2022.

Ther Adv Gastroenterol

2022, Vol. 15: 1–9

DOI: 10.1177/
17562848221122473

© The Author(s), 2022.
Article reuse guidelines:
[sagepub.com/journals-](https://sagepub.com/journals-permissions)
permissions

Correspondence to:

Wafaa Ahmed
Institute for Liver Studies,
King's College Hospital
NHS Foundation Trust,
Denmark Hill, London SE5
9RS, UK

Wafaa.ahmed@nhs.net

Dave Kyle
Amardeep Khanna
John Devlin
David Reffitt
Phillip Harrison
Deepak Joshi

Institute of Liver Studies,
King's College Hospital
NHS Foundation Trust,
London, UK

Zeino Zeino
Southmead Hospital/
North Bristol NHS Trust,
Bristol, UK

George Webster
Simon Phillpotts
Hepatopancreatobiliary
Unit, University College
Hospital, London, UK

Robert Gordon
Gareth Corbett
William Gelson
Cambridge Liver Unit,
Addenbrooke's Hospital,
Cambridge, UK

Manu Nayar
Freeman Hospital,
Newcastle upon Tyne, UK

Haider Khan
Matthew Cramp
Southwest Liver Unit
and Plymouth University
Peninsula Schools of
Medicine and Dentistry,
Plymouth, UK

Jonathan Potts
Waleed Fateen
Hamish Miller
Royal Free Sheila Sherlock
Liver Centre, Royal Free
Hospital and UCL Institute
of Liver and Digestive
Health, London, UK

Bharat Paranandi
Matthew Huggett
Simon M. Everett
Vinod S. Hegade
Leeds Teaching Hospitals
NHS Trust, Leeds, UK

Rebecca O'Kane
Ryan Scott
Neil McDougall
Belfast Health and Social
Care Trust, Belfast, UK

Introduction

Fully covered metal stents are increasingly used in the management of benign biliary disease.^{1–4} Biliary anastomotic strictures (ASs) affect 5–32% of patients post-liver transplant (LT).^{5,6} Established risk factors for AS include donor–recipient size discrepancy, length of donor duct, suture placement and bile leaks.⁵ They can develop at any point in the post-LT period and are primarily managed endoscopically with the placement of biliary stents with the aim to remodel the stricture with radial force.^{5,7,8} The insertion of side-by-side multiple plastic stents (MPSs) can be challenging with suboptimal numbers used, and they often require multiple endoscopic retrograde cholangiopancreatography (ERCP) procedures to achieve stricture resolution.^{9,10} Trans-papillary fully covered self-expanding metallic stents (FCSEMSs) have been used to manage post-LT AS and have been shown to require fewer interventions before achieving stricture resolution.^{10,11}

The Kaffes™ (Taewoong Niti-S™, Gyeonggi-do, South Korea) biliary covered stent is a fully covered intra-ductal self-expanding metal stent (IDSEMS).¹² This IDSEMS differs from conventional FCSEMS because they do not need to traverse the papilla. They are shorter in length with a tapered anti-migration waist and removal wires that are subsequently deployed into the duodenum, potentially reducing the risk of stent migration compared to FCSEMS.¹³ In small case series, they have been shown to be effective in treating post-LT AS.^{12,13} They may confer a lower risk of post-ERCP pancreatitis in comparison to FCSEMS in benign biliary strictures.^{12,14}

We report on the experience with IDSEMS across the UK in the management of AS.

Patients/material and methods

This was a retrospective, multicentre observational study across nine centres (Kings College Hospital NHS Foundation Trust, Southmead Hospital/North Bristol NHS Trust, University College Hospital London, Addenbrooke's Hospital Cambridge, Freeman Hospital Newcastle upon Tyne, Plymouth University Peninsula Schools of Medicine and Dentistry, Royal Free Hospital London, Leeds Teaching Hospitals NHS Trust, Belfast Health and Social Care Trust). Provisional data were presented at UEGW Virtual 2021.¹⁵ All patients undergoing deployment of IDSEMS in a transplant setting between

December 2016 and January 2021 were included. IDSEMS were selected for insertion over MPS of FCSEMS at the endoscopist's discretion. Indication for stenting was evidence of AS on cross-sectional imaging. All patients underwent written informed consent for ERCP at their respective institutions.

Patient demographics, procedural characteristics, response to therapy and follow-up data were obtained from patient records and endoscopy databases at the respective centres. Morbidity, endoscopic complications, disease recurrence and liver biochemistry were recorded pre- and post-stent insertion. All patient details were de-identified. Resolution of biliary pathology was assessed at the time of stent removal and on follow-up, and the need for subsequent surgical intervention, that is, hepaticojejunostomy, was included. This study was registered as a clinical audit and approved by the Kings College Hospital audit department. The reporting of this study conforms to the Strobe statement.¹⁶

Method of insertion

Diagnostic cholangiograms are obtained after cannulation of the recipient bile duct *via* the major papilla. Sphincterotomy, stricture dilatation and stent size were performed at the discretion of the endoscopist. All stents were inserted over a guide-wire. Radio-opaque markers at the midpoint of the stent as well as at the proximal and distal ends help guide placement over the area of interest and ideally 2 cm below the biliary hilum to avoid blocking the contralateral intrahepatic duct. The delivery mechanism unsheathes the stent, and retrieval wires were 'dropped' in the duodenum (Figure 1). Removal of stents is recommended at 12 weeks by the manufacturer using graspers or a snare, and a repeat cholangiogram was obtained to assess for resolution of the biliary pathology.

Definitions

For the ASs, early stricture occurrence was defined as stricture occurrence less than 30-day post-transplant; delayed stricture occurrence was between 30- and 90-day post-transplant and late stricture occurrence was after 90 days. Technical success was defined as the successful deployment of the stent at the index ERCP. Clinical success was defined as the resolution of the biliary pathology after removal of the IDSEMS at the time of the

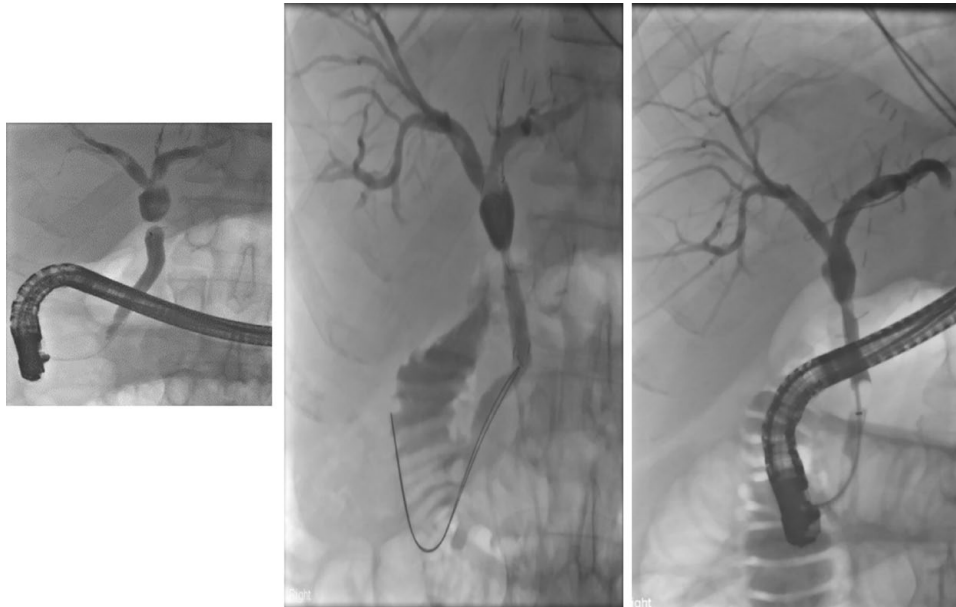


Figure 1. IDSEMS insertion in a post-LT setting with resolution of AS. (Three sequential images uploaded under the heading of Figure 1 on the upload portal.)

AS, anastomotic stricture; IDSEMS, intraductal self-expanding metal stent; LT, liver transplant.

follow-up ERCP as demonstrated by a cholangiogram showing no biliary strictures or as per the endoscopists interpretation. Stricture resolution was defined as fluoroscopic resolution at the time of stent removal. Follow-up and imaging interval post-stent removal were as per individual unit and clinician discretion. Stricture recurrence was defined as recurrence within the follow-up period, as demonstrated on cross-sectional imaging.

Statistical analysis

Continuous variables were expressed as median and interquartile range (IQR). Categorical variables were displayed as a number and percentage. Wilcoxon signed-rank test was used for paired samples. Binominal test was used for nominal data. Categorical variables were analysed using chi-squared test. Statistical significance was set at $p < 0.05$. Data were analysed with GraphPad Prism version 9.0.1 (151). Cases in the transplant setting were analysed separately from patients undergoing stenting in the non-transplant setting.

Results

In all, 162 patients (100 males, 62%) underwent 176 episodes of stent insertion. The median age at transplant was 54 years (range, 12–74 years).

Donor grafts were predominately donation after brain stem death ($n = 98$, 60%) followed by donation after circulatory death ($n = 34$, 21%). There were two (1%) living donor-LTs. No data were available for the type of graft in 28 (17%) cases. Demographic and procedural data are available in Table 1.

The underlying aetiologies were hepatocellular carcinoma ($n = 35$, 22%), alcohol-related liver disease ($n = 29$, 18%), non-alcoholic-related fatty liver disease (NAFLD) ($n = 20$, 12%), primary biliary cholangitis ($n = 15$, 9%), acute liver failure ($n = 13$, 8%), viral hepatitis ($n = 13$, 8%), autoimmune hepatitis ($n = 12$, 7%) and primary sclerosing cholangitis ($n = 5$, 3%). The median time to stricture occurrence was 24.9 weeks (range, 0.4–1395 weeks). Early AS occurred in 25 (15%) cases, delayed in 32 (20%) cases and late in 95 (59%) cases. Time to stricture was not available for 10 cases (6%).

Procedural data

In all, 56 (35%) cases had undergone previous biliary stenting, of which 42 (75%) were plastic, 12 (21%) were FCSEMS and 2 (4%) had both plastic and FCSEMS. The two most frequently used IDSEMS sizes were 40 mm \times 0 mm ($n = 91$,

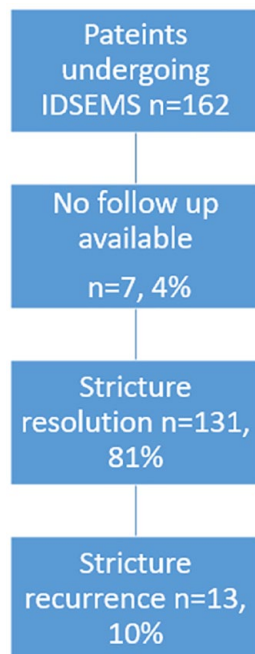


Figure 2. Resolution of AS with IDSEMS. AS, anastomotic stricture; IDSEMS, intraductal self-expanding metal stent.

52%) and 40 mm × 8mm ($n = 60$, 34%). Stricture dilatation before stent insertion was carried out in 73 (41%) cases. Sphincterotomy was carried out in 120 (74%) cases.

Improvement in liver biochemistry and stricture resolution

Follow-up data were available for 155 (96%) cases. Stents were in place for a median of 15 weeks (range, 3 days–78 weeks). The patient with a stent left *in situ* for 78 days failed to attend a planned appointment for removal.

There was an improvement in liver biochemistry after stent insertion: bilirubin (Bili) 30 (IQR, 8–34) $\mu\text{mol/L}$ versus 22 (IQR 7–20) $\mu\text{mol/L}$ ($p = 0.017$); alkaline phosphatase, 324 (IQR 131–421) IU/L versus 244 (IQR 110–312) IU/L ($p = 0.0089$); aspartate aminotransferase, 79 (IQR 27–85) IU/L versus 53 (IQR 22–53) IU/L ($p = 0.008$) and gamma glutamyl transferase 445 (IQR, 106–579) IU/L versus 258 (IQR, 67–386) IU/L ($p = 0.0001$).

Overall, 131 (81%) had stricture resolution at endoscopic re-evaluation (Figure 2). Of these, 13 (10%) had stricture recurrence, which occurred

after a median of 19 weeks (range, 4–88 weeks) after stent removal. Four (31%) reoccurred within 3 months and 9 (69%) within 12 months. In the patient group with recurrence, one was relisted for LT, and three underwent repeated stenting with IDSEMS. Data regarding the remaining patients 9/13 patients with recurrent strictures was not available.

In all, 106 had no previous episode of stenting before insertion of the IDSEMS. 85 (80%) of these patients had resolution of the AS at endoscopic re-evaluation, and 8 (10%) had recurrence at a median of 19 weeks (range, 4–88 weeks).

Of the 24 patients without resolution of strictures at stent removal, eight (33%) had previously been stented (five plastic and three FCSEMS). Seven (29%) patients underwent repeated stenting with IDSEMS, and four (17%) patients had repeated stenting with MPS. Two patients were re-transplanted, one with a Roux-en-Y for persistent AS and the other due to chronic rejection despite stricture resolution. One other remains on the transplant waiting list with a lack of resolution of their stricture. Two had biliary reconstructions, and one is awaiting repeat surgery. Data regarding the remaining patients without stricture resolution were not available.

Factors associated with stricture resolution

There was no statistically significant difference in resolution of strictures in cases with dilatation of strictures ($n = 69$) versus those who had no biliary dilatation ($n = 71$; $p = 0.6516$) or in those with previous sphincterotomy ($n = 96$) versus those with no sphincterotomy ($n = 35$; $p = 0.4411$). Similarly, there was no effect in those who had previous stents ($n = 45$) versus those who had no previous biliary stents ($n = 85$; $p = 1$).

Adverse events

There were 37 (21%) adverse events associated with stent insertion; 25 (14%) cases of cholangitis, 7 (2%) cases of post-ERCP pancreatitis, 5 (3%) failed stent deployment, one (1%) wire-guided perforation and one (1%) bleed. One patient transplanted for NAFLD with early AS died due to sepsis secondary to post-ERCP cholangitis 31 days after stent insertion. A computed tomography scan after insertion showed the stent occluding the left-sided system.

Overall, there were 21 (12%) adverse events at removal; 11 (6%) of the stent withdrawal mechanisms fractured or unravelled. Of these, 9 (82%) had been inserted during or after the first wave of the COVID-19 pandemic, potentially increasing time stents were *in situ*. All except one had been in for more than 12 weeks [median 18.85 weeks (range, 5–61 weeks)]. There were five (3%) episodes of cholangitis, two (1%) episodes of pancreatitis, two (1%) episodes of distal stent migration and one proximal stent migration. All patients with stent migrations were in the transplant cohort with stents in place for 2.2, 2.5 and 16 weeks. All stents were successfully removed endoscopically.

Discussion

Benign biliary strictures are conventionally managed by ERCP with a choice of plastic or FCSEMS. IDSEMS, particularly Kaffes™ stents, are being increasingly utilized in transplant patients with biliary strictures, with previous reports showing favourable outcomes.¹² To our knowledge, this is the largest real-world multicentre experience in AS. We demonstrate that these stents can be used effectively and safely with good clinical efficacy. Our results show a high stricture resolution rate following a single IDSEMS placement and a low stricture recurrence rate. The risk of adverse events also seems to be in keeping with published data.

Biliary AS can occur at any point in the post-transplant period. Patients are often asymptomatic and may only have abnormal liver graft function.⁶ Untreated biliary AS can lead to reduced patient and graft survival.⁶ Early AS are more responsive to endotherapy. However, in our study, most patients had delayed strictures, which in previous studies have been shown to need more episodes of sequential stenting (with plastic stents or FCSEMS) to achieve stricture resolution.^{17,18} The advantage of IDSEMS is the need for a single ERCP procedure to achieve complete stricture resolution in the majority of cases.

Biliary AS resolution rates have been reported to range from 63% to 100% for MPS and 53–100% with FCSEMS; however, fewer procedures are needed with FCSEMS (2 *versus* 5 ERCPs) to achieve stricture resolution.^{10,19,20} Overall, the duration of stenting with FCSEMS is unclear,

but a minimum of 3 months or more of stent duration is recommended.⁴ In our AS cohort, IDSEMS were placed for a median of 15 weeks. In keeping with previous studies using IDSEMS, our study showed there was high stricture resolution after index stenting.^{12,13} Similar to FCSEMS, IDSEMS may have a role when stricture resolution has not been achieved after plastic stenting.²¹ Although 35% of our cohort were stent experienced, in those that were stent naive, 80% had resolution of the AS at endoscopic re-evaluation.

AS recurrence after MPS and FCSEMS are comparable with rates between 3% and 37%.^{2,22} Recurrence in IDSEMS is reported between 19% and 24%.^{12,13} In our study, recurrence was seen in 10% of cases both in the stent experienced and stent-naive group.

The episodes of post-ERCP cholangitis are higher in our study than in previous reports, but higher rates are often seen in post-transplant patients, and our data are comparable with plastic stents use.^{1,10,23} Antibiotic prophylaxis is indicated for all post-LT patients as they are at increased risk of cholangitis.^{24,25} All patients received antibiotic prophylaxis according to their local units' antimicrobial policy. In conjunction with antibiotics, care should be taken to deploy the stent 2 cm below the hilum to avoid blocking the contralateral duct.

Dilatation of AS and biliary sphincterotomy is required before MPS, leading to an increased risk of adverse events, including bleeding during the ERCP.^{23,26} The IDSEMS have a narrow delivery sheath, and therefore dilatation of AS may not be needed. Similarly, the withdrawal mechanism also collapses the bottom of the stent to allow easy removal. Therefore, routine sphincterotomy may not be necessary during the insertion of IDSEMS.

In our cohort, stent migration was seen in only three cases. Two were within 3 weeks of stent insertion. This compares favourably to FCSEMS, where stent migration is reported at a rate of between 4% and 46% and around 10% with plastic stents, with a lower risk of migration with MPSs.^{27,28} Migration of FCSEMS used in post-transplant AS can occur in up to a third of cases.^{4,20} They may be prone to migration when the level of the AS lies closer to the hilum.²⁹

There were 11 cases where the retrieval wires unravelled. All but one were *in situ* for more than the 12 weeks recommended by the manufacturers. Although all were removed endoscopically, fractured wires can increase procedural time and risk other adverse events, including cholangitis.³⁰ The COVID-19 pandemic and cessation of all non-urgent endoscopy may have contributed to delays in removal, and centres utilizing these stents should be aware of this potential adverse event.³⁰ In addition to timely removal, steady downwards traction following the direction of the bile duct should be employed.

Overall, our study demonstrates that IDSEMS may have a role in managing post-liver transplantation biliary AS, including cases refractory to previous plastic stent or FCSEMS. In comparison to MPS, the advantages of IDSEMS appear to be the need for a single ERCP procedure to achieve stricture resolution, low risk of stricture recurrence and reduced risk of stent migration. However, the IDSEMS may be associated with higher adverse events, particularly cholangitis, especially at the time of removal.

Limitations

This was a retrospective study with a limited sample size and no control group. The multicentre nature of the study induced heterogeneity in patient management and follow-up. Data on the duration of previous episodes of stenting prior to IDSEMS were also limited.

The lack of homogeneous follow-up with interval imaging at defined time points makes it difficult to ascertain the exact time point of stricture recurrence. 35% of patients in the group were stent experienced, and although we did not find an impact of previous stenting on stricture resolution, this may be due to the low sample size. In addition, due to the nature of data acquisition, not all adverse events may have been captured.

Conclusion

In conclusion, IDSEMS appear to be safe and highly efficacious in the management of post-LT AS. Long-term outcomes appear good with low rates of AS recurrence. Randomized controlled studies are required directly comparing IDSEMS and FCSEMS in the transplant setting.

Table 1. Baseline characteristics of the patients and procedural characteristics.

Characteristics	Number (%)
Number of patients	162
Male gender, <i>n</i> (%)	100 (62)
Number of procedures, <i>n</i> (%)	176 (92)
Age at transplant (years), median (range)	54 (12–74)
Age range, <i>n</i> (%)	
0–20	4 (3)
21–30	13 (8)
31–40	23 (14)
41–50	23 (14)
51–60	62 (38)
>60	37 (23)
Graft received	
DBD	98 (61)
DCD	34 (21)
LD	2 (1)
Unknown	28 (17)
Time to stricture (weeks), median (range)	24.9 (0.4–1395)
Early stricture	25 (15)
Delayed stricture	32 (20)
Late stricture	95 (59)
Unavailable	10 (6)
Aetiology of liver disease	
HCC	35 (22)
ARLD	29 (18)
NASH/NAFLD	20 (12)
PBC	15 (9)
ALF	13 (8)
AIH	12 (7)
Other	11 (7)

(Continued)

Table 1. (Continued)

Characteristics	Number (%)
HCV	7 (4)
HBV	6 (4)
PSC	5 (3)
Budd Chiari	4 (3)
Cryptogenic	4 (3)
Previous stent for AS	56 (35)
Plastic	42 (75)
FCSEMS	12 (21)
Plastic and FCSEMS	2 (4)
Stent size (mm)	
40 × 6	1 (1)
40 × 8	60 (34)
40 × 10	91 (52)
60 × 8	4 (2)
60 × 10	4 (2)
Unknown	16 (9)
Stricture dilatation	73 (45)
Sphincterotomy	120 (74)
Duration of stenting (weeks), median (range)	15 (3 days–78 weeks)
Stricture resolution	131 (81)
Stricture recurrence	13 (10)
Stricture re recurrence (weeks), median (range)	19 (4–88)
Adverse events at stent insertion	37 (21)
Cholangitis	25 (14)
Pancreatitis	7 (2)
Failed deployment	5 (3)
Bleed	1 (1)
Wire-guided perforation	1 (1)
Adverse events at stent removal*	21 (12)

*(Continued)***Table 1.** (Continued)

Characteristics	Number (%)
Wires broken or unravelling	11 (6)
Cholangitis	5 (3)
Stent migration	3 (2)
Pancreatitis	2 (1)
Re-transplantation	3 (2)

AIH, autoimmune hepatitis; ALF, acute liver failure; ARLD, alcohol-related liver disease; AS, anastomotic stricture; DBD, donation after brain stem death; DCD, donation after circulatory death; FCSEMS, fully covered self-expanding metal stent; HBV, hepatitis B virus; HCC, hepatocellular carcinoma; HCV, hepatitis C virus; NAFLD, non-alcoholic-related fatty liver disease; NASH, non-alcoholic steatohepatitis; PBC, primary biliary cholangitis; PSC, primary sclerosing cholangitis.
*One death after stent insertion due to cholangitis.

Declarations

Ethics approval and consent to participate

This study was registered as a clinical audit and approved by the Kings College Hospital audit department. It was a retrospective study.

Consent for publication

Patient consent was not obtained for publication. All patients gave written informed consent to undergo the procedures.

Author contribution(s)

Wafaa Ahmed: Data curation; Formal analysis; Writing – original draft; Writing – review & editing.

Dave Kyle: Conceptualization; Resources; Writing – review & editing.

Amardeep Khanna: Investigation; Writing – review & editing.

John Devlin: Writing – review & editing.

David Reffitt: Writing – review & editing.

Zeino Zeino: Investigation; Writing – review & editing.

George Webster: Investigation; Writing – review & editing.

Simon Phillpotts: Investigation; Writing – review & editing.

Robert Gordon: Investigation; Writing – review & editing.

Gareth Corbett: Writing – review & editing.

William Gelson: Writing – review & editing.

Manu Nayar: Investigation; Writing – review & editing.

Haider Khan: Investigation; Writing – review & editing.

Matthew Cramp: Writing – review & editing.

Jonathan Potts: Writing – review & editing.

Waleed Fateen: Investigation; Writing – review & editing.

Hamish Miller: Investigation; Writing – review & editing.

Bharat Paranandi: Investigation; Writing – review & editing.

Matthew Huggett: Investigation; Writing – review & editing.

Simon M Everett: Investigation; Writing – review & editing.

Vinod S Hegade: Investigation; Methodology; Writing – review & editing.

Rebecca O’Kane: Investigation; Writing – review & editing.

Ryan Scott: Investigation; Writing – review & editing.

Neil McDougall: Investigation; Writing – review & editing.

Phillip Harrison: Methodology; Writing – review & editing.

Deepak Joshi: Conceptualization; Methodology; Project administration; Supervision; Visualization; Writing – review & editing.

Acknowledgements

Not applicable.

Funding

The authors received no financial support for the research, authorship and/or publication of this article.

Competing interests

The authors declare that there is no conflict of interest.

Availability of data and materials

Available upon reasonable request.

ORCID iD

Wafaa Ahmed  <https://orcid.org/0000-0003-4034-7570>

References

1. Devière J, Nageshwar Reddy D, Püspök A, *et al.* Successful management of Benign Biliary Strictures with fully covered self-expanding metal stents. *Gastroenterology* 2014; 147: 385–395.
2. Landi F, de’Angelis N, Sepulveda A, *et al.* Endoscopic treatment of anastomotic biliary stricture after adult deceased donor liver transplantation with multiple plastic stents versus self-expandable metal stents: a systematic review and meta-analysis. *Transpl Int* 2018; 31: 131–151.
3. Huszár O, Kokas B, Mátrai P, *et al.* Meta-analysis of the long term success rate of different interventions in benign biliary strictures. *PLoS One* 2017; 12: e0169618.
4. Kao D, Zepeda-Gomez S, Tandon P, *et al.* Managing the post-liver transplantation anastomotic biliary stricture: multiple plastic versus metal stents: a systematic review. *Gastrointest Endosc* 2013; 77: 679–691.
5. Sharma S, Gurakar A and Jabbour N. Biliary strictures following liver transplantation: past, present and preventive strategies. *Liver Transpl* 2008; 14: 759–769.
6. Keane MG, Devlin J, Harrison P, *et al.* Diagnosis and management of benign biliary strictures post liver transplantation in adults. *Transplant Rev* 2021; 35: 100593.
7. Graziadei IW, Schwaighofer H, Koch R, *et al.* Long-term outcome of endoscopic treatment of biliary strictures after liver transplantation. *Liver Transpl* 2006; 12: 718–725.
8. Larghi A, Tringali A, Rimbaş M, *et al.* Endoscopic management of benign biliary strictures after liver transplantation. *Liver Transpl* 2019; 25: 323–335.
9. Cantù P, Tarantino I, Baldan A, *et al.* Endotherapies for biliary duct-to-duct anastomotic stricture after liver transplantation: outcomes of a nationwide survey. *Liver Int* 2019; 39: 1355–1362.
10. Kaffes A, Griffin S, Vaughan R, *et al.* A randomised trial of a fully covered self-expandable metallic stent versus plastic stents in anastomotic biliary strictures after liver

- transplantation. *Therap Adv Gastroenterol* 2014; 7: 64–71.
11. Khan MA, Baron TH, Kamal F, *et al.* Efficacy of self-expandable metal stents in management of benign biliary strictures and comparison with multiple plastic stents: a meta-analysis. *Endoscopy* 2017; 49: 682–694.
 12. Warner B, Harrison P, Farman M, *et al.* A unique type of fully covered metal stent for the management of post liver transplant biliary anastomotic strictures. *BMC Gastroenterol* 2020; 20: 329.
 13. Aepli P, St John A, Gupta S, *et al.* Success and complications of an intra-ductal fully covered self-expanding metal stent (ID-FCSEMS) to treat anastomotic biliary strictures (AS) after orthotopic liver transplantation (OLT). *Surg Endosc* 2017; 31: 1558–1563.
 14. Martinez NS, Inamdar S, Firoozan SN, *et al.* Evaluation of post-ERCP pancreatitis after biliary stenting with self-expandable metal stents vs. plastic stents in benign and malignant obstructions. *Endosc Int open* 2021; 9: E888–E894.
 15. Nayar M, Webster G, Zeino Z, *et al.* Intraductal fully covered self-expanding metal stents in the management of post liver transplant anastomotic strictures; a UK wide experience. In: *UEG week virtual 2021*, 2021, <https://ueg.eu/library/intraductal-fully-covered-self-expanding-metal-stents-in-the-management-of-post-liver-transplant-anastomotic-strictures-a-uk-wide-experience/242754> (accessed 31 August 2022).
 16. von Elm E, Altman DG, Egger M, *et al.* The Strengthening the Reporting of Observational Studies in Epidemiology (STROBE) statement: guidelines for reporting observational studies. *Ann Intern Med* 2007; 147: 573–577.
 17. Villa NA and Harrison ME. Management of biliary strictures after liver transplantation. *Gastroenterol Hepatol* 2015; 11: 316–328.
 18. Verdonk RC, Buis CI, Porte RJ, *et al.* Anastomotic biliary strictures after liver transplantation: causes and consequences. *Liver Transpl* 2006; 12: 726–735.
 19. Lee DW, Jo HH, Abdullah J, *et al.* Endoscopic management of anastomotic strictures after liver transplantation. *Clin Endosc* 2016; 49: 457–461.
 20. Tal AO, Finkelmeier F, Filmann N, *et al.* Multiple plastic stents versus covered metal stent for treatment of anastomotic biliary strictures after liver transplantation: a prospective, randomised, multicenter trial. *Gastrointest Endosc* 2017; 86: 1038–1045.
 21. Traina M, Tarantino I, Barresi L, *et al.* Efficacy and safety of fully covered self-expandable metallic stents in biliary complications after liver transplantation: a preliminary study. *Liver Transpl* 2009; 15: 1493–1498.
 22. Zheng X, Wu J, Sun B, *et al.* Clinical outcome of endoscopic covered metal stenting for resolution of benign biliary stricture: systematic review and meta-analysis. *Dig Endosc* 2017; 29: 198–210.
 23. Dumonceau J-M, Kapral C, Aabakken L, *et al.* ERCP-related adverse events: European Society of Gastrointestinal Endoscopy (ESGE) guideline. *Endoscopy* 2020; 52: 127–149.
 24. Cotton PB, Connor P, Rawls E, *et al.* Infection after ERCP, and antibiotic prophylaxis: a sequential quality-improvement approach over 11 years. *Gastrointest Endosc* 2008; 67: 471–475.
 25. Khashab MA, Chithadi KV, Acosta RD, *et al.* Antibiotic prophylaxis for GI endoscopy. *Gastrointest Endosc* 2015; 81: 81–89.
 26. Johnson KD, Perisetti A, Tharian B, *et al.* Endoscopic retrograde cholangiopancreatography-related complications and their management strategies: a “scoping” literature review. *Dig Dis Sci* 2020; 65: 361–375.
 27. Bagul A, Pollard C and Dennison AR. A review of problems following insertion of biliary stents illustrated by an unusual complication. *Ann R Coll Surg Engl* 2010; 92: W27–W31.
 28. Arhan M, Odemiş B, Parlak E, *et al.* Migration of biliary plastic stents: experience of a tertiary center. *Surg Endosc* 2009; 23: 769–775.
 29. Côté GA, Slivka A, Tarnasky P, *et al.* Effect of covered metallic stents compared with plastic stents on benign biliary stricture resolution: a randomised clinical trial. *JAMA* 2016; 315: 1250–1257.
 30. Ahmed W, Joshi D, Harrison P, *et al.* Intraductal bile duct stents should be prioritised for removal during the pandemic. *Gut* 2021; 70: 2397.