

ULTRASONOGRAPHIC EVALUATION OF PERIODONTAL CHANGES DURING ORTHODONTIC TOOTH MOVEMENT - WORK IN PROGRESS

ADELA ZIMBRAN¹, DIANA DUDEA¹, CRISTINA GASPARIK¹,
SORIN DUDEA²

¹Propaedeutics and Esthetic Dentistry Department, Iuliu Hatieganu University of Medicine and Pharmacy, Cluj-Napoca, Romania

²Radiology Department, Iuliu Hatieganu University of Medicine and Pharmacy, Cluj-Napoca, Romania

Abstract

Background and aim. Orthodontic tooth movement (OTM) is a process whereby the application of a force induces bone resorption on the pressure side and bone apposition on the tension side of the lamina dura. However, only limited data are available on the in vivo behavior of the periodontal tissues. The aim of this study was to assess the changes of periodontal tissues, induced by the orthodontic canine retraction, using 40 MHz ultrasonography.

Methods. Ultrasonographic evaluation of periodontal tissues was conducted in 5 patients with indication for orthodontic treatment. The upper first premolars were extracted bilaterally due to severe crowding, and the canines were distalized using elastomeric chain with a net force of 100 cN. Ultrasonographic scans (US scans) were performed before, during and after retraction, in three distinct areas of the canines buccal surface: mesial, middle and distal. The reference point was the bracket, which appeared hyperechoic on the US scan. Four different dimensions were obtained: D1 (depth of the sulcus), D2 (thickness of the gingiva), D3 (length of the supracrestal fibers), D4 (width of periodontal space).

Results. An increase of D1 was observed in all three areas of the periodontium, during orthodontic treatment. D3 was strongly correlated before and immediately after force delivery only for the mesial area ($r=0.828$, $p<0.05$). In total, 228 variables were statistically analyzed using Pearson's correlation coefficients, in order to demonstrate the relationship between periodontal findings during orthodontic tooth movement.

Conclusion. High-resolution ultrasonography has the capability to obviate changes in periodontal ligament space and free gingiva during orthodontic tooth movement.

Keywords: ultrasonography, periodontal tissue, orthodontic tooth movement

Introduction

Tooth movement by orthodontic force application is characterized by remodeling changes in periodontal tissues, including, periodontal ligament (PDL), alveolar bone, and gingiva [1].

The response to applied orthodontic forces is bone formation (due to osteoblasts) on the tension side and bone

resorption on the compression side (due to osteoclasts) of the lamina dura [2-5].

However, this represents an oversimplification of the three dimensional changes that appear in the microarchitecture of the periodontium. Several studies used histological staining and light microscopy, scanning electron microscopy [6], finite element models [7,8], genetic modifications [9,10] in order to demonstrate the complexity of periodontal transformations. These methods need sophisticated procedures and animal sacrifice,

Manuscript received: 21.03.2016

Received in revised form: 23.04.2016

Accepted: 29.04.2016

Address for correspondence: dr.adelaz@gmail.com

and cannot be used to evaluate longitudinal changes of periodontium due to orthodontic forces [11].

A new technique aiming at observing real time, in vivo modifications induced by OTM in the morphology of PDL, alveolar bone and cementum would be beneficial in order to better conduct the treatment plan and to evaluate the tissue response to orthodontic forces.

Ultrasonography represents a new, accurate and noninvasive technique for evaluating periodontal tissues. Several studies [12,13] demonstrated that ultrasonography could be successfully used in assessing the cortical bone, sulcular depth, periodontal space, length of the anatomical crown and the characteristics of the gingiva.

The aim of the present study was to assess whether changes that appear during orthodontic tooth movement in the anatomical structures of the periodontium can be monitored using ultrasonography. To the best of our knowledge, this is the first attempt to understand the modifications that appear during OTM using ultrasonic measurements of periodontal tissues, especially the gingival characteristics.

The null hypothesis of the present study was that by using ultrasonic measurements, anatomic features of periodontal structures (gingival sulcus depth; free gingival thickness; distance between marginal gingiva and alveolar crest; and width of the periodontal space in most coronal position) of teeth subjected to OTM will indicate the same results, overtime.

Materials and methods result

The study was conducted on 5 patients, aged 14-25. In every case, maxillary canines were subjected to orthodontic retraction, as part of the orthodontic treatment plan; 8 teeth were measured as a result - all with typical dental anatomy (average root sizes, bone insertion, and shape). The research protocol was approved by the institutional Ethical Committee, and an informed consent was obtained from the subjects.

All patients were fitted with Alexander's prescription preadjusted edgewise appliance of .018 slot (MiniMaster American Orthodontics). Upper first premolars were extracted due to severe crowding (8 upper bicuspids - 5 first right premolars and 3 first left premolars) (Figure 1).

After leveling and aligning, the canines were distalized on 016 SS archwire, using elastomeric memory chain (AO) with a net force of approximately 100cN. The elastomeric chain delivering the force was measured with a dynamometer.

The average time for canine retraction was 5 months, which varied depending on the size of the initial space and bone density.

A commercially available ultrasound scanner (Ultrasonix SonoTouch) with a linear 1.5 cm footprint, 40MHz transducer was used in order to evaluate the periodontal structures of the canines. US scans were

performed in three distinct areas of the canine buccal surface: mesial, middle and distal, with a percutaneous transgenial approach.

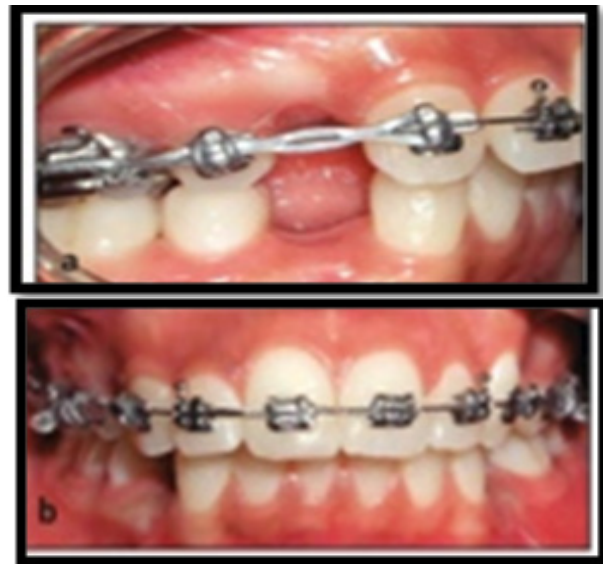

Figure 1. Treatment mechanics after extraction of the premolars: a. lateral view b. frontal view.

The reference point was the bracket, placed in the center of the canine, which appeared hyperechoic on the US scan. The images were obtained by positioning the transducer in a longitudinal plane in the lateral area of the maxillary alveolar process (Figure 2).

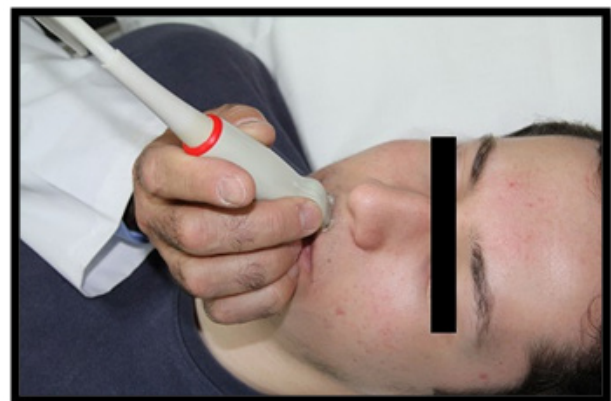


Figure 2. Position of the transducer.

The US scan revealed the cortical bone, the buccal surface of the tooth with the bracket placed in the center, the gingival sulcus and the periodontal space in the most coronal position (Figure 3). On the 40 MHz image, the following distances were measured at a micrometric level: D1 - gingival sulcus depth; D2 - free gingival thickness; D3 - distance between marginal gingiva and alveolar crest; D4 - width of the periodontal space in the most coronal position.

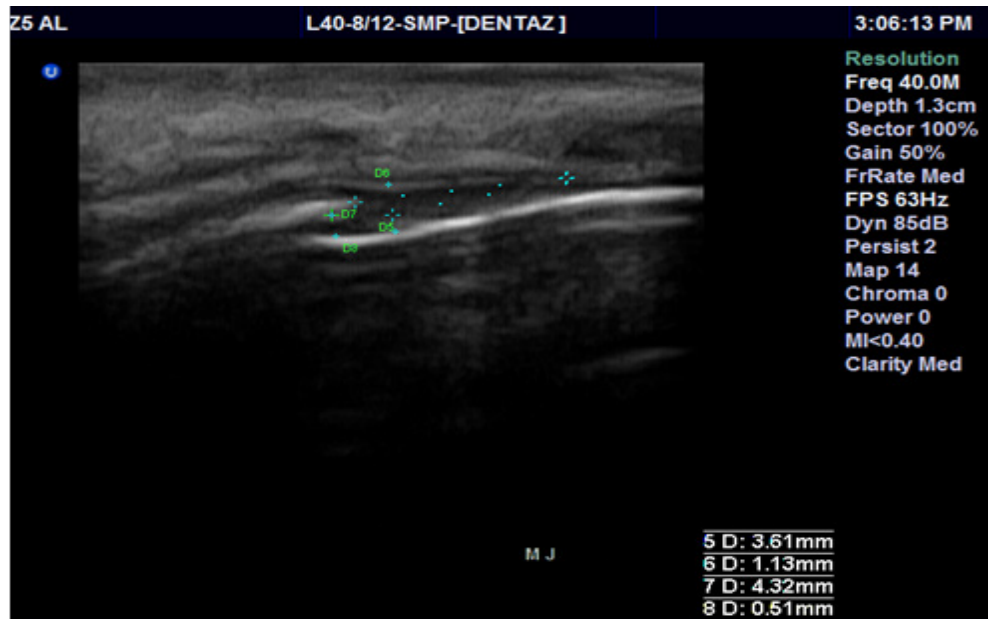


Figure 3. US image of tooth 1.3 during distal movement, middle area of the buccal surface. Periodontal space with the alveolar bone and tooth.

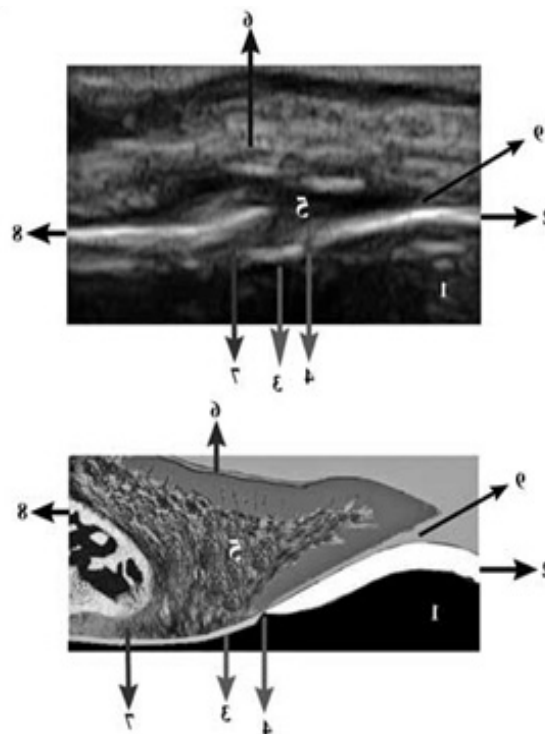


Figure 4. Dental and periodontal US anatomy - 40 MHz image (top) and anatomic sketch (bottom inspired by ref. [14]: 1 – dentin; 2 – enamel; 3 - cementum; 4 – cemento-enamel junction; 5 – supra crestal fibers; 6 – gingival epithelium; 7 – periodontal ligament; 8 – crest of alveolar bone; 9 – gingival sulcus. (drawings from our previous research).

All scans were performed by a single trained radiologist, at different moments of the orthodontic treatment. The US scans were performed at three different moments of OTM: before distalization (moment 1), after 2 days of 100 cN force delivery, when tooth displacement was expected (moment 2) and after 30 days to 60 days or the postlag stage (moment 3).

Paired sample t-test and Pearson's correlation test were used to compare recorded data between different moments of the OTM.

Results

All ultrasound measurements for D1, D2, D3 and D4 (mm) are presented in Table I.

An increase of D1 (sulcus depth) was observed in all three areas of the periodontium, immediately after force delivery, whereas at the end of tooth movement the distance slightly decreased. However, significant differences were observed only for the mesial (p=0.031) and middle areas (p=0.048). A strong correlation was also noted for D1 before and immediately after force delivery (r=0.945, p<0.05).

D2 (free gingival thickness) was the most stable measurement during OTM, the free gingival thickness slightly decreased from the initial moment, yet no statistically significant difference was observed between the measurements (p>0.05).

The distance between marginal gingiva and alveolar crest (D3) was strongly correlated before and immediately after force delivery only for the mesial area (r=0.828, p<0.05). Furthermore, a very strong inverse correlation was observed for the middle area between moment 2 and 3 (r=-0.998, p<0.05).

The width of the periodontal space (D4) increased immediately after force delivery on the mesial, middle and distal area. In the last stage, D4 had a tendency to return to its initial size. Nonetheless, no significant difference was found between the measurements, in none of the three moments evaluated (p>0.05).

Charts representing the evolution of periodontal structures for D1 (sulcus depth), D2 (free gingival thickness), D3 (distance between marginal gingiva and alveolar crest), D4 (width of the periodontal space in the most coronal position), on the mesial area (blue line), middle area (red line), distal area (green line), during OTM are presented in figures 5 to 8 (x- axis: moments of the US scans: m1- initial phase; m2-intermediary phase; m3- final phase; y-axis: dimensional changes in millimeters).

Table I. Ultrasound measurements for D1, D2, D3, D4 (mm).

	D1	D2	D3	D4
AB.1.13.MES	2.4	1.02	3.9	0.2
AB.1.13.MID	2.54	1.31	2.84	0.35
AB.1.13.DIS	2.18	0.89	2.31	0.25
L.N.1.13.MES	2.83	1.27	3.45	0.15
L.N.1.13.MID	2.51	1.53	3.59	0.34
L.N.1.13.DIS	3.15	1.09	4.05	0.24
L.P.1.13.MID	2.17	1.59	2	0.43
L.P.1.13.DIS	2.25	1.92	2.43	0.33
A.B.2.13.MES	2.72	1.2	3.25	0.23
A.B.2.13.MID	2.88	1.05	3.09	0.26
A.B.2.13.DIS	3.71	1.85	4.56	0.85
L.N.2.13. DIS	2.67	2.1	3.45	0.2
L.N.2.13 MID	2.45	1.55	2.76	0.3
L.N.2.13.MES	2.84	1.34	3.26	0.31
Z.P.1.13.MES	2.7	1.03	3.53	0.22
Z.P.1.13.MID	2.89	1.03	3.9	0.24
Z.P.1.13.DIS	3.7	1.08	4.41	0.15
Z.P.2.13.MES	3.13	1.92	3.43	0.61
Z.P.2.13.MID	4.19	2.57	4.39	0.88
Z.P.2.13.DIS	3.81	2.39	4.16	0.62
Z.P.1.23.MID	2.73	1.47	3.47	0.18
Z.P.1.23.DIS	2.78	1.37	3.52	0.28
Z.P.2.23.MES	4.15	1.95	4.49	0.35
Z.P.2.23.MID	3.97	2.47	4.22	0.42
Z.P.2.23.DIS	3.43	2.62	3.7	0.57
A.L.1.13.MES	4.48	1.44	5.57	0.41
A.L.1.13.MID	3.61	1.13	4.32	0.52
A.L.1.13.DIS	3.44	1.1	4.6	0.46
A.L.2.13.MES	4.58	1.39	5.19	0.44
A.L.2.13.MID	3.07	1.18	3.7	0.67
A.L.2.13.DIS	4.96	1.2	5.34	0.29
A.L.1.23.MES	4.98	1.08	5.71	0.23
A.L.1.23.DIS	5.06	1.06	6.21	0.23
A.L.2.23.MES	5.92	1.16	6.18	0.74
A.L.2.23.MID	5.2	1	5.52	0.55
A.L.2.23.DIS	3.26	0.91	4.08	0.45
L.P.1.23.DIS	2.03	1.07	2.42	0.2
L.P.2.13.MES	2.12	1.29	1.29	0.53
L.P.2.13.MID	2.87	1.28	3.51	0.52
L.P.2.13.DIS	2.04	1.09	2.44	0.21
L.P.2.23.MES	2.66	1.09	3.36	0.28
L.P.2.23.MID	2.48	1.14	2.79	0.23
L.P.2.23.DIS	2.83	1.6	2.92	0.76
L.N.3.13.DIS	2.74	1.32	3.77	0.39
Z.P.3.13.MES	3.33	1.05	3.95	0.42
Z.P.3.13.MID	2.61	1.18	2.84	0.47
Z.P.3.13.DIS	3.72	1.88	5.47	0.42
Z.P.3.23.MES	2.3	1.45	2.57	0.5
Z.P.3.23.MID	2.02	1.17	2.92	0.27
Z.P.3.23.DIS	3.95	1.39	5.03	0.13

First column: Initials of the patient. Moment of the ultrasound scanning (1- initial phase; 2- intermediary phase; 3- final phase). Tooth notation. Surface (MES- mesial; MID- middle; DIS- distal).

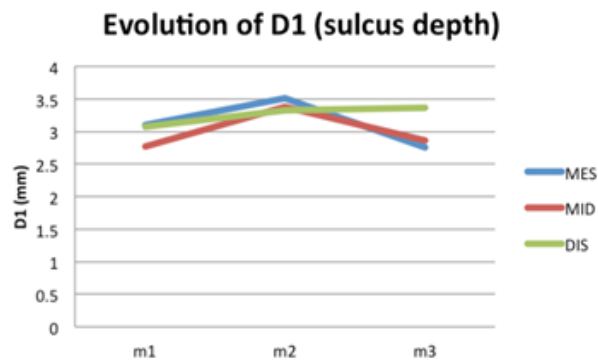


Figure 5. Chart representing the evolution of D1.

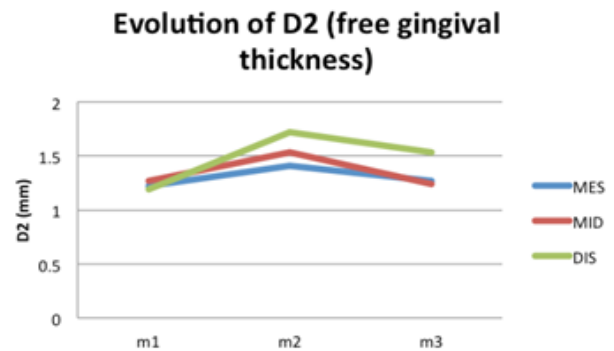


Figure 6. Chart representing the evolution of D2.

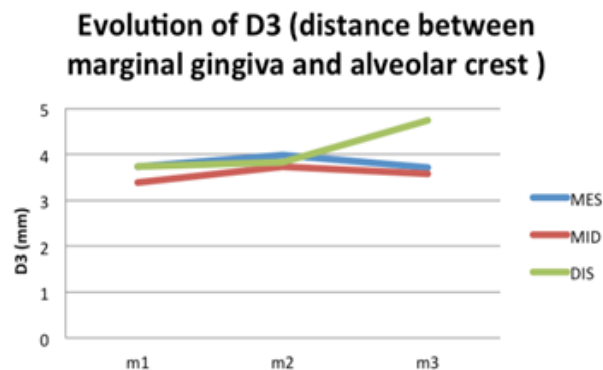


Figure 7. Chart representing the evolution of D3.

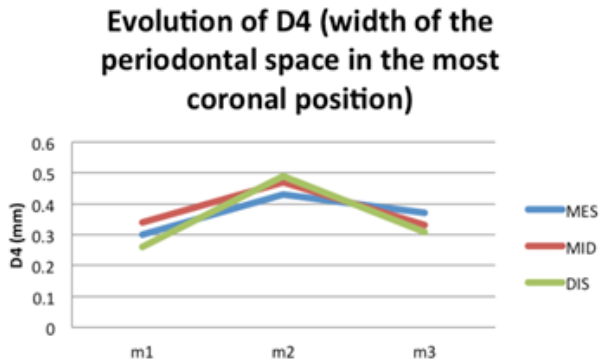


Figure 8. Chart representing the evolution of D4.

Discussion

The definition of orthodontic tooth movement by Proffit is the result of a biologic response to the interference in the physiological equilibrium of the dentofacial complex by an externally applied force [15].

Two main mechanisms are considered to be responsible for tooth movement—the application of pressure and tension to the PDL [16], and bending of the alveolar bone [17].

However, few studies focused on the real time changes induced by OTM in the area of marginal periodontium. In this study, we propose a novel approach for the clinical evaluation of the free gingiva, gingival sulcus, supracrestal fibers and position of the bone crest. High-resolution ultrasonography (40 MHz) was used, for a better visualization of the superficial periodontium. The null hypothesis of the study states that ultrasound imaging does not have the capacity to evaluate the changes, which appear during OTM.

In the present study, a standardized orthodontic force of approximately 100cN was applied to the canine. The period of time between the scans were deliberately chosen, according to the lag stages found in the literature [18]:

1. Initial stage (24–48h) represented by tooth displacement in the periodontal ligament space.

2. Lag stage lasts 20–30 days and is characterized by the formation of necrosis and hyalinization. In this lag stage there is little or no tooth movement.

3. Postlag stage, characterized by tooth movement mediated by bone remodeling through the agency of osteoclasts and osteoblasts on a background of neoangiogenesis.

The null hypothesis was rejected since significant changes in the periodontium were measured by US method after orthodontic tooth movements. The distance between marginal gingiva and alveolar crest (D3) was strongly correlated before and immediately after force delivery only for the mesial area ($r=0.828$, $p<0.05$). Furthermore, a very strong inverse correlation was observed for the middle area between moment 2 and 3 ($r=-0.998$, $p<0.05$).

An increase of D1 (sulcus depth) observed in all three areas of the periodontium, immediately after force delivery. However, significant differences were observed only for the mesial ($p=0.031$) and middle areas ($p=0.048$), on the opposite side of that of force delivery.

A recent study demonstrated that gingival inflammation and dental plaque increase during orthodontic treatment [19]. This might be one of the possible explanations for our findings, i.e. the increased sulcus depth measurement.

The thickness of human PDL is reported to be around

0.1–0.3 mm [20]. In our study, measurements of periodontal space in the most coronal position (D4) varied between 0.2 and 0.52, with an average value of 0.28 in the initial stage. The width of the periodontal space increased immediately after force delivery on all of the buccal areas: mesial, distal and middle. In the last stage, D4 had a tendency to return to its initial size. Nonetheless, no significant difference was found between the measurements, in none of the three moments evaluated ($p>0.05$).

Although D2 (free gingival thickness) was the most stable measurement during OTM, no statistically significant difference was observed between the measurements ($p>0.05$). The prevalence, extent, and severity of gingival recession were correlated with past orthodontic treatment [21]. Future studies will be carried out to see if there is a significant change in the thickness of the gingiva, in the last stage.

The limit of the study was the relative small sample of subjects (5 patients- with 8 canines to be distalized), one of them was lost during the research. Further assessment of the modifications in the width, thickness and height of the marginal peridontium is needed, on a larger group of patients.

Conclusions

1. Ultrasonographic measurements, with high resolution, detected changes in the anatomic landmark of periodontal tissues during orthodontic tooth movement.

2. Significant changes occurred immediately after force delivery on the middle and mesial area of the canine, for sulcus depth measurement and distance between marginal gingiva and alveolar crest.

References

1. Rygh P, Brudvik P. The histological responses of the periodontal ligament to horizontal orthodontic loads. In: Berkovitz BB, Moxham BJ, Newman HN, editors. *The periodontal ligament in health and disease*. St Louis: Mosby; 1995.
2. Roberts-Harry D, Sandy J. Orthodontics. Part 11: orthodontic tooth movement. *Br Dent J*. 2004;196:391–394; quiz 426.
3. Rody WJ Jr, King GJ, Gu G. Osteoclast recruitment to sites of compression in orthodontic tooth movement. *Am J Orthod Dentofacial Orthop*. 2001;120:477–489.
4. Cattaneo PM, Dalstra M, Melsen B. Moment-to-force ratio, center of rotation, and force level: a finite element study predicting their interdependency for simulated orthodontic loading regimens. *Am J Orthod Dentofacial Orthop*. 2008;133:681–689.
5. D'Apuzzo F, Cappabianca S, Ciavarella D, Monsurrò A, Silvestrini-Biavati A, Perillo L. Biomarkers of periodontal tissue remodeling during orthodontic tooth movement in mice and men: overview and clinical relevance. *Scientific World Journal*. 2013;105873, doi: 10.1155/2013/105873
6. Jones SJ, Boyde A. A study of human root cementum surfaces as prepared for and examined in the scanning electron microscope. *Z Zellforsch Mikrosk Anat*. 1972;130:318–337.
7. McCormack SW, Witzel U, Watson PJ, Fagan MJ, Gröning F. The biomechanical function of periodontal ligament fibres in orthodontic tooth movement. *PLoS ONE*. 2014 Jul 18;9(7):e102387. doi:10.1371/journal.pone.0102387
8. Jiang F, Xia Z, Li S, Eckert G, Chen J. Mechanical environment change in root, periodontal ligament, and alveolar bone in response to two canine retraction treatment strategies. *Orthod Craniofac Res*. 2015;18 Suppl 1:29-38.
9. Masella RS, Meister M. Current concepts in the biology of orthodontic tooth movement. *Am J Orthod Dentofacial Orthop*. 2006;129(4):458-468.
10. Sprogar S, Vaupotic T, Cör A, Drevensek M, Drevensek G. The endothelin system mediates bone modeling in the late stage of orthodontic tooth movement in rats. *Bone*. 2008;43:740–747.
11. Ru N, Liu SS, Zhuang L, Li S, Bai Y. In vivo microcomputed tomography evaluation of rat alveolar bone and root resorption during orthodontic tooth movement. *Angle Orthod*. 2013;83:402–409.
12. Zimbran A, Dudea S, Dudea D. Evaluation of periodontal tissues using 40 MHz ultrasonography. preliminary report. *Med Ultrason*. 2013;15(1):6-9.
13. Chifor R, Hedeşiu M, Bolfa P, Catoi C, Crişan M, Serbănescu A, et al. The evaluation of 20 Mhz ultrasonography, computed tomography scans as compared to direct microscopy of periodontal system assessment. *Med Ultrason*. 2011;13(2):120-126.
14. DoctorSpiller.Com. Tooth anatomy 2. Available from: http://doctorspiller.com/Tooth_Anatomy/tooth_anatomy_2.htm
15. Proffit WR. Biologic basis of orthodontic therapy. In: ProffitWR, Fields HW, editors. *Contemporary orthodontics*. 3rd ed. St Louis: Mosby; 2000.
16. Schwarz AM. Tissue changes incident to orthodontic tooth movement. *Int J Orthod*. 1932;18:331-352.
17. Baumrind S. A reconsideration of the property of the “pressure-tension” hypothesis. *Am J Orthod*. 1969;55:12-22.
18. Burstone CJ. The biomechanics of tooth movement. In: KrausBS, Riedel RA, editors. *Vistas in orthodontics*. Philadelphia: Lea&Febiger; 1962.
19. Boke F, Gazioglu C, Akkaya S, Akkaya M. Relationship between orthodontic treatment and gingival health: A retrospective study. *Eur J Dentistry*. 2014;8(3):373-380.
20. Cawson RA, Odell EW. *Cawson's Essentials of Oral Pathology and Oral Medicine*. Edinburgh, USA: Churchill Livingstone; 2008.
21. Slutzkey S, Levin L. Gingival recession in young adults: occurrence, severity, and relationship to past orthodontic treatment and oral piercing. *Am J Orthod Dentofacial Orthop*. 2008;134(5):652-656.