



Case Report

Indolent nonendemic central nervous system histoplasmosis presenting as an isolated intramedullary enhancing spinal cord lesion

Matthew J. Recker^{1,2}, Steven B. Housley^{1,2}, Lindsay J Lipinski^{1,2}

¹Department of Neurosurgery, Roswell Park Comprehensive Cancer Center, Buffalo, New York, United States, ²Department of Neurosurgery, Jacobs School of Medicine at the University at Buffalo, Buffalo New York, United States.



***Corresponding author:**

Lindsay J. Lipinski
Department of Neurosurgery,
Roswell Park Comprehensive
Cancer Center, Jacobs School
of Medicine at the University
at Buffalo, Buffalo, New York,
United States.

lindsay.lipinski@roswellpark.org

Received : 08 April 2021

Accepted : 08 July 2021

Published : 09 August 2021

DOI

10.25259/SNI_345_2021

Quick Response Code:



ABSTRACT

Background: *Histoplasma capsulatum* infection is largely seen in endemic regions; it results in symptomatic disease in <5% of those infected and is most often a self-limiting respiratory disease. Disseminated histoplasmosis is considered rare in the immunocompetent host. Central nervous system (CNS) dissemination can result in meningitis, encephalitis, and focal lesions in the brain and spinal cord, stroke, and hydrocephalus. An intramedullary spinal cord lesion as the only manifestation of CNS histoplasmosis has been rarely described.

Case Description: We present an atypical case of a 44-year-old man from a nonendemic region, on adalimumab therapy for ulcerative colitis who developed an isolated intramedullary spinal cord lesion in the setting of disseminated histoplasmosis. His course was initially indolent with vague systemic symptoms that led to consideration of several other diagnoses including sarcoidosis and lymphoma. Biopsies of several positron emission tomography positive lymph nodes revealed granulomatous inflammation, but no firm diagnosis was achieved. He was ultimately diagnosed with histoplasmosis after an acute respiratory infection in the setting of anti-tumor necrosis factor therapy. With appropriate antifungal therapy, the spinal cord lesion regressed. The previous systemic biopsies were re-reviewed, and rare fungal elements consistent with *H. capsulatum* were identified. A presumptive diagnosis of CNS histoplasmosis was made in the absence of direct laboratory confirmation in the setting of rapid and complete resolution on antifungal therapy.

Conclusion: Disseminated histoplasmosis should be considered in granulomatous disease, even if the patient resides in a nonendemic region. Furthermore, clinicians should be mindful that CNS histoplasmosis may present in an atypical fashion.

Keywords: Abscess, Central nervous system, Histoplasmosis, Intramedullary, Spinal cord

INTRODUCTION

Although infection with the fungus *Histoplasma capsulatum* is common – especially in the Ohio and Mississippi River Valleys, where the pathogen is endemic in the United States – histoplasmosis disease results in <5% of those infected.^[1,3] Histoplasmosis is most often characterized by a mild, self-limiting respiratory illness in approximately 95% of cases.^[4,8,10] Disseminated disease is possible but most often occurs in immunocompromised hosts and involves the central nervous system (CNS) in only 5–10% of cases.^[1,2] CNS histoplasmosis may result in meningitis, encephalitis, focal intraparenchymal lesions in the brain or spinal

This is an open-access article distributed under the terms of the Creative Commons Attribution-Non Commercial-Share Alike 4.0 License, which allows others to remix, tweak, and build upon the work non-commercially, as long as the author is credited and the new creations are licensed under the identical terms.

©2021 Published by Scientific Scholar on behalf of Surgical Neurology International

cord, stroke, and hydrocephalus and carries a high rate of morbidity and mortality.^[2,3,7,8,11] Making the diagnosis can be difficult because cerebrospinal fluid (CSF) cultures may be positive in only 25–65% of all patients with CNS dissemination. In immunocompetent hosts or in patients without exposure to endemic regions, CNS histoplasmosis may be overlooked as a possible diagnosis.^[8,11] To date and to the best of our knowledge, there are few reports of CNS histoplasmosis manifesting as only spinal cord lesions.^[2,5,9,10] Here, we present a patient who was ultimately diagnosed with disseminated histoplasmosis with CNS involvement being limited to an isolated intramedullary spinal cord lesion. Following treatment, his CNS and systemic disease responded well, and he returned to good health. This case illustrates how CNS histoplasmosis can manifest in a variety of ways, can occur in nonendemic areas, and has the potential to clinically and radiographically mimic other systemic diseases. Practitioners should include CNS histoplasmosis in the differential diagnosis for enhancing spinal cord masses, particularly in the setting of lymphadenopathy or a history of systemic granulomatous disease.

CASE DESCRIPTION

A previously healthy 44-year-old man from the Great Lakes region of the United States with a medical history remarkable for ulcerative colitis on adalimumab therapy presented a 3–4 month history of abdominal pain, weight loss, night sweats, and fatigue. Workup for evaluation of these symptoms included colonoscopy, which demonstrated areas of inflammation and ulceration. Colonic biopsies were interpreted as consistent with acute colitis. Approximately 1 month later, computed tomography of the abdomen and pelvis, which was performed due to ongoing and somewhat progressive symptoms, demonstrated abnormal mesenteric lymph nodes. Follow-up positron emission tomography (PET) imaging revealed low-grade metabolic activity in mesenteric, aortocaval, internal mammary, abdominal wall, and axillary nodes as well as heterogeneous uptake in the spleen consistent with “low-grade lymphoproliferative disease.” Additional hypermetabolic lesions were observed in the left lingual tonsil and within the spinal cord at the level of the third thoracic vertebra [Figure 1a-c]. Due to the findings

on PET imaging, the patient’s ongoing systemic symptoms, and therapy with an anti-tumor necrosis factor (TNF) agent, there was concern for low-grade lymphoma.

The patient subsequently underwent an ultrasound-guided biopsy of a PET-avid periumbilical abdominal wall mass, a PET-avid cervical node, and a PET-avid lingual tonsil, which all showed no evidence of malignancy on pathology but each contained granulomatous inflammation. Both necrotizing and non-necrotizing granulomas were identified in the specimens. Around this time, the patient developed clumsiness and numbness of his left-lower extremity. Magnetic resonance imaging (MRI) of the spine demonstrated a 9-mm expansile homogeneously enhancing intramedullary spinal cord mass at the T3 level with significant edema within the spinal cord above and below the lesion [Figure 2a-c]. CSF sampling demonstrated an essentially normal profile with mildly elevated protein and no malignant cells. Specific antigen and antibody testing were not performed. Due to the presence of a systemic process and the risk of morbidity associated with a spinal cord biopsy, neurosurgical intervention was deferred.

In the absence of a systemic diagnosis, the patient was referred to pulmonology for possible multisystem sarcoidosis, where he was treated with high-dose prednisone therapy. The patient continued this therapy for approximately 3 months during which time he reported improvements in his appetite, strength, night sweats, and chills. A repeat MRI was performed to follow the thoracic lesion, which showed significant improvement [Figure 3a].

Over the ensuing 3 months, his prednisone dose was slowly tapered down, and a course of intravenous infliximab was initiated for treatment of both presumed sarcoidosis and ulcerative colitis. Follow-up MRI of the thoracic lesion again showed significant reduction in size and patient reported continued improvement in strength and sensation of his left leg [Figure 3b]. Approximately 2 months into this treatment with infliximab, the patient developed a fever and shortness of breath. Chest X-ray revealed interstitial pneumonitis and bilateral pneumonia; he was admitted for treatment and required intubation. Due to his history of immunosuppression, fungal cultures were obtained from a

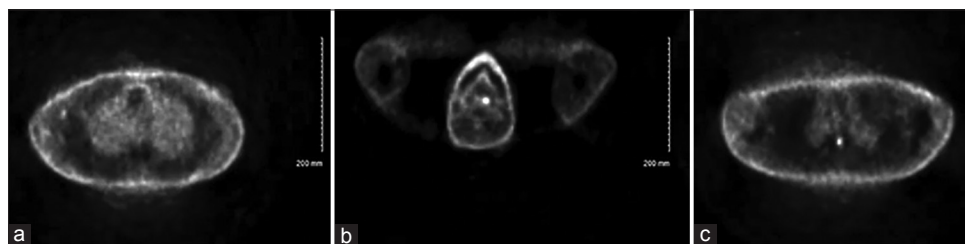


Figure 1: Fluorodeoxyglucose-positron emission tomography imaging demonstrates areas of hypermetabolism in the right subaxillary lymph nodes (a), left lingual tonsil (b), and T3 region of the spinal cord (c).

bronchoscopy specimen in addition to routine testing and ultimately resulted positive for *H. capsulatum*. Treatment with amphotericin B (5 mg/kg daily) and methylprednisolone (1 mg/kg daily) was initiated, and the patient gradually improved. He was discharged on oral itraconazole (200 mg twice daily) and prednisone (20 mg daily). MRI of the spine 4 weeks after discharge demonstrated complete resolution of the spine mass [Figure 3c] and significant improvement in the edema within the spinal cord [Figure 4]. In light of the fungal pneumonia, all previous tissue specimens were re-reviewed. Repeat tissue sectioning demonstrated rare fungal

elements in the previous colonic, abdominal wall, cervical lymph node, and tonsil specimens [Figure 5a-d], implying that indolent disseminated histoplasmosis was the cause of his systemic and gastrointestinal symptoms from the outset.

DISCUSSION

Histoplasmosis is most commonly a self-limited respiratory disease primarily seen in endemic regions. Disseminated disease is primarily seen in immunocompromised hosts and can involve the CNS. CNS involvement limited to the

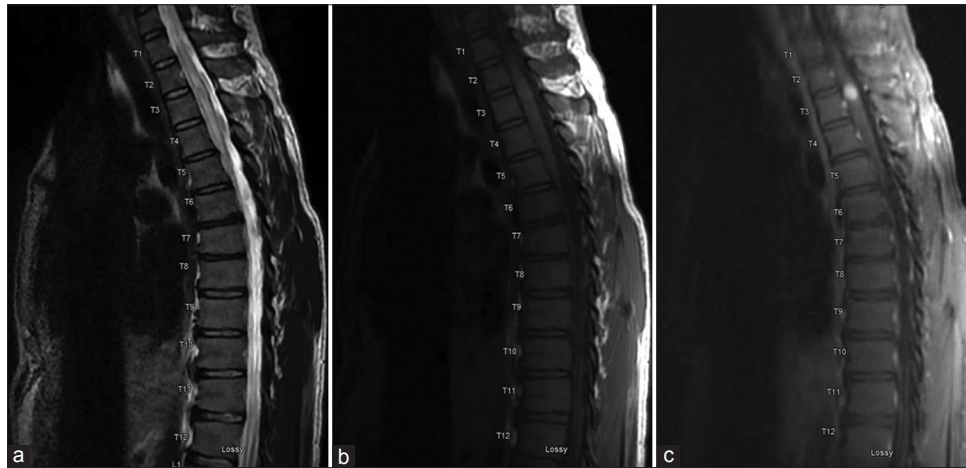


Figure 2: Initial magnetic resonance imaging of the thoracic spine demonstrates a 9-mm homogeneously-enhancing intramedullary spinal cord lesion with significant edema within the spinal cord above and below the lesion. Sagittal T2-weighted image (a), sagittal T1-weighted image without contrast (b), and sagittal T1-weighted image without contrast (c) are shown.

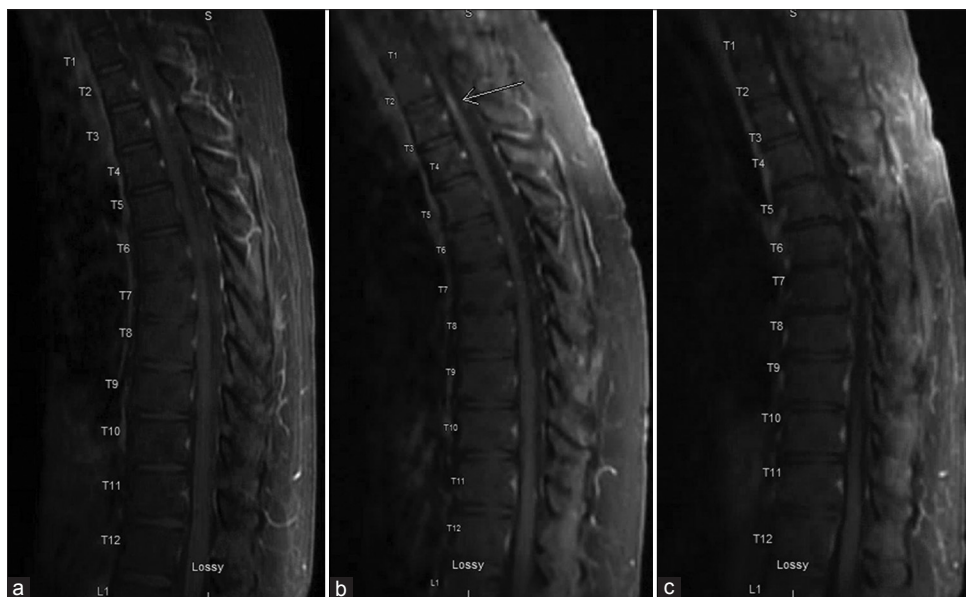

Figure 3: Follow up serial sagittal T1-weighted magnetic resonance imaging of the thoracic spine with contrast – 3 months (a), 6 months (b), and 10 months (c) from initial imaging [Figure 2c] – demonstrate interval regression and ultimate resolution of the enhancing intramedullary spinal cord lesion.

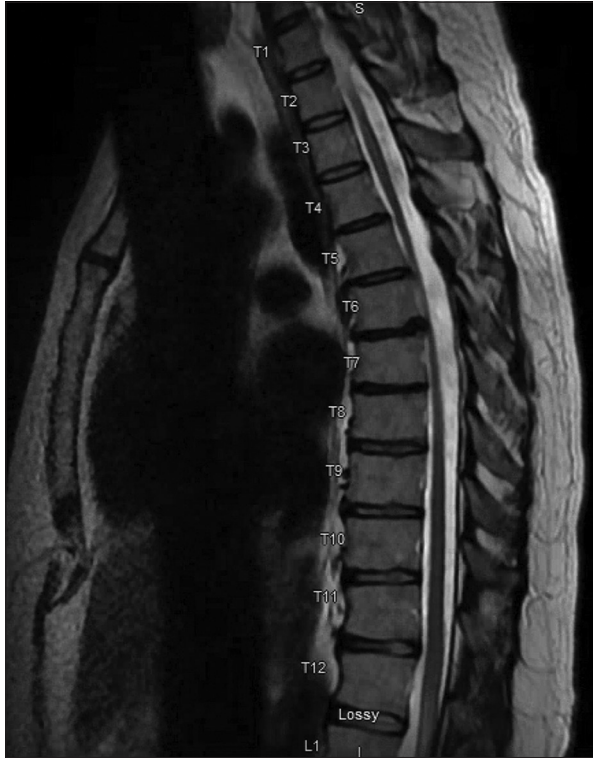

Figure 4: Follow-up sagittal T2-weighted MRI of the thoracic spine at 10 months. Significant improvement in spinal cord edema compared to initial imaging [Figure 2a].

spinal cord as an isolated lesion is rarely described. Spinal cord involvement of histoplasmosis has been described in case reports and series. The Table 1 outlines the available case reports, several of which involved challenging courses with delayed diagnoses.^[1-5,7,9,10] Only four cases had CNS involvement isolated to the spinal cord.^[2,5,9,10] Half of the cases reviewed reported an immunocompromised state,^[2,4,5,9] five of eight reported endemic exposure,^[1,2,4,7,9] and treatment was variable but all included amphotericin. Our patient's unique clinical course illustrates several valuable learning points.

The diagnosis of CNS histoplasmosis can be challenging; and delays in diagnosis as well as misdiagnoses such as lymphoma, sarcoidosis, and other systemic inflammatory diseases have been described.^[1,11] Our patient was ultimately diagnosed with disseminated histoplasmosis in a delayed fashion after having symptoms initially felt to be related to his ulcerative colitis. When his symptoms worsened, further workup led to a presumptive diagnosis of sarcoidosis after several biopsies revealed both necrotizing and non-necrotizing granulomas. The differential diagnosis for systemic granulomatous disease is broad.^[6] Especially in nonendemic regions, histoplasmosis may be overlooked in a differential diagnosis due to the low prevalence. As Wheat *et al.* discuss, the diagnosis of CNS histoplasmosis may be missed due to failure to consider the disease and suboptimal awareness of appropriate testing.^[11]

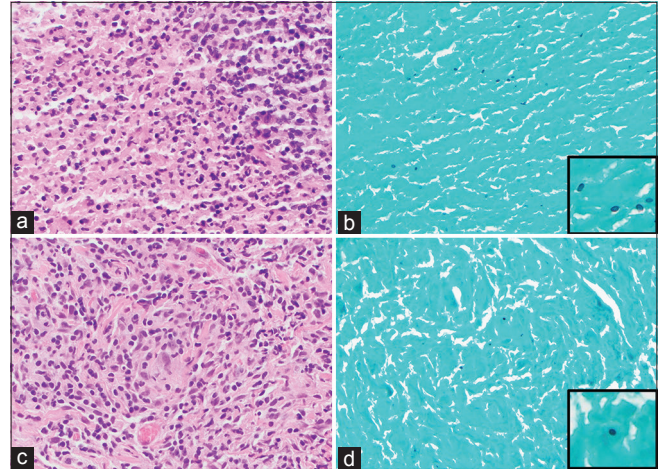


Figure 5: Hematoxylin and eosin (H&E) (a) and Grocott methenamine silver (GMS) special stain (b) ($\times 400$) of the necrotizing granuloma in the left tonsil. H&E (c) and GMS special stain (d) ($\times 400$) of the non-necrotizing granuloma in the abdominal wall. A few GMS-positive fungal microorganisms are identified that are morphologically consistent with histoplasma.

Our patient's CNS manifestation was unique in that CNS histoplasmosis uncommonly presents as an isolated spinal cord lesion.^[2,5,9,10] The radiographic features were also atypical in that a more characteristic, ring-enhancing abscess would be expected. After identification of the spinal cord lesion, basic CSF analysis, cultures, and cytology were sent for analysis, but neither fungal cultures nor more specific assays were included in the study. Even so, CSF fungal cultures are poorly sensitive in patients with CNS histoplasmosis and can take more than 2 weeks to become positive.^[8,11] In this patient, the early workup did not include *H. capsulatum* antigen nor anti-histoplasma antibody testing. At that time in his course, CNS histoplasmosis was not strongly considered. Ultimately, a presumptive diagnosis of CNS histoplasmosis was made based on his clinical course and response to antifungal therapy without direct laboratory confirmation of CNS involvement.

The indolent disease course in our patient should be noted. He was retrospectively found to have disseminated histoplasmosis at the time of the initial tissue biopsy from his colonoscopy, implying a prolonged infection that was slowly progressive even without antifungal therapy and while on immunosuppressive therapy. He was subsequently treated with a course of high-dose prednisone for presumed sarcoidosis, during which he radiographically and symptomatically improved from a neurologic standpoint. He was then prescribed a different anti-TNF agent which likely contributed to his ultimate development of acute pulmonary histoplasmosis. However, his pulmonary presentation occurred months into the therapy. Once the diagnosis of disseminated acute on chronic histoplasmosis was

Table 1: Summary of available detailed case reports of patients with intramedullary spinal cord histoplasmosis.

Authors, Year	Other CNS Involvement?	Immunocompromised State?	Endemic Exposure?	Surgical Intervention?	Treatment*
Voelker <i>et al.</i> , 1989 ^[3]	None reported	No	Not reported	Laminectomy, excision	Amphotericin B (2300 mg)
Livas <i>et al.</i> , 1995 ^[5]	Intraparenchymal brain lesions	Yes, azathioprine, prednisone for renal transplant	Yes	Brain biopsy	Amphotericin B (2500 mg)
Hott <i>et al.</i> , 2002 ^[2]	Intraparenchymal brain lesions	No	No	Brain biopsy, laminectomy, excision	Intrathecal amphotericin (0.2 mg 3 times/week), voriconazole (400 mg twice daily for 1 day, then 200 mg twice daily)
Rivierez <i>et al.</i> , 2002 ^[8]	Intraparenchymal brain lesions	No	Yes	Biopsy	Amphotericin B
Bollyky <i>et al.</i> , 2006 ^[6]	None reported	Yes, human immunodeficiency virus	Yes	Spinal cord biopsy	Liposomal amphotericin B
Manning <i>et al.</i> , 2006 ^[10]	No	Yes, human immunodeficiency virus	Not reported	Laminectomy, excision	Liposomal amphotericin B, then itraconazole
Tai <i>et al.</i> , 2010 ^[11]	Leptomeningeal, intraparenchymal brain lesion in medulla	No	Yes	Ventriculoperitoneal shunt	Amphotericin B added to rifampicin, isoniazid, pyrazinamide, and ofloxacin; then oral voriconazole
Simms <i>et al.</i> , 2020 ^[9]	No	Yes, methotrexate for rheumatoid arthritis	Yes	No	Liposomal amphotericin B, then oral itraconazole

*Formulation and dosing information provided if available.
CNS: Central nervous system

established, appropriate antifungal treatment was initiated, which led to complete radiographic resolution of the spinal cord lesion.

CONCLUSION

CNS histoplasmosis can be difficult to diagnose because atypical features can be common; it can closely mimic other systemic diseases, and the more sensitive diagnostic modalities are likely underutilized. CNS histoplasmosis should be considered even in nonendemic areas, with or without a history of immunosuppression, and even in the setting of an isolated enhancing spinal cord lesion. Clinicians must be mindful that histoplasmosis may appear radiographically similar to neurosarcoidosis and other systemic diseases and that treatment with immunosuppressive agents may unmask a previously indolent infection. Treatment with steroids may lead to clinical and radiographic improvement in CNS histoplasmosis. If granulomas are identified without clear etiology, fungal infection should be considered and a thorough search for fungal elements may be necessary.

Declaration of patient consent

The authors certify that they have obtained all appropriate patient consent.

Financial support and sponsorship

Nil.

Conflicts of interest

There are no conflicts of interest.

REFERENCES

- Bollyky PL, Czartoski TJ, Limaye A. Histoplasmosis presenting as an isolated spinal cord lesion. *Arch Neurol* 2006;63:1802-3.
- Hott JS, Horn E, Sonntag VK, Coons SW, Shetter A. Intramedullary histoplasmosis spinal cord abscess in a nonendemic region: Case report and review of the literature. *J Spinal Disord Tech* 2003;16:212-5.
- Livas IC, Nechay PS, Nauseef WM. Clinical evidence of spinal and cerebral histoplasmosis twenty years after renal transplantation. *Clin Infect Dis* 1995;20:692-5.
- Manning TC, Born D, Tredway TL. Spinal intramedullary histoplasmosis as the initial presentation of human immunodeficiency virus infection: Case report. *Neurosurgery* 2006;59:E1146; discussion E1146.
- Mehta AC, Ali SR. Mnemonic for the differential diagnosis of non-caseating granulomas. *Sarcoidosis Vasc Diffuse Lung Dis* 2017;34:200-7.
- Rivierez M, Heyman D, Brebion A, Landau-Ossondo M, Desbois N, Vally P. Spinal cord histoplasmoma. A case report.

- Neurochirurgie 2002;48:44-8.
7. Saccente M. Central nervous system histoplasmosis. *Curr Treat Options Neurol* 2008;10:161-7.
 8. Simms A, Kobayashi T, Endelman L, Sekar P. Disseminated histoplasmosis presenting as bilateral lower extremity paresis. *Int J Infect Dis* 2020;95:265-7.
 9. Tai YF, Kullmann DM, Howard RS, Scott GM, Hirsch NP, Revesz T, *et al.* Central nervous system histoplasmosis in an immunocompetent patient. *J Neurol* 2010;257:1931-3.
 10. Voelker JL, Muller J, Worth RM. Intramedullary spinal Histoplasma granuloma. Case report. *J Neurosurg* 1989;70:959-61.
 11. Wheat J, Myint T, Guo Y, Kemmer P, Hage C, Terry C, *et al.* Central nervous system histoplasmosis: Multicenter retrospective study on clinical features, diagnostic approach and outcome of treatment. *Medicine (Baltimore)* 2018;97:e0245.

How to cite this article: Recker MJ, Housley SB, Lipinski LJ. Indolent nonendemic central nervous system histoplasmosis presenting as an isolated intramedullary enhancing spinal cord lesion. *Surg Neurol Int* 2021;12:392.