



Modified Bosworth Technique for Medial Collateral Ligament Reconstruction of the Knee Using Semitendinosus Tendon Autograft

James Ohliger III, M.D., Andrew Haus, M.D., Rodney Fong, M.S., Sarah Lang, M.Ed., A.T.C., O.T.C., Brian B. Gilmer, M.D., F.A.A.O.S., F.A.A.N.A., and Christopher J. Wahl, M.D., F.A.A.O.S., F.A.A.N.A., F.A.O.S.S.M.

Abstract: The medial collateral ligament (MCL) is a major contributor to knee joint stability and is the most common ligament involved in knee injuries. When conservative management for high-grade MCL injuries fails, operative treatment is indicated. Various reconstruction techniques are described in the literature. The following report describes a reconstruction technique based on the modified Bosworth. We present a step-by-step technique for using autograft semitendinosus tendon as a double limb to reconstruct the MCL and if necessary, the posterior oblique ligament. The technique is versatile with respect to a spectrum of MCL injury patterns, isometric, incorporates techniques that are common to other knee reconstructions, and uses readily available autograft. It has been used extensively by the senior authors as an adjunct/augmentation to the repair of acute MCL injuries as well as in the reconstruction of chronic MCL laxity. The technique restores stability to rotation and valgus stress while maintaining the distal insertion of the semitendinosus intact.

Introduction

The medial collateral ligament (MCL) is a major contributor to the stability of the knee joint and the most common ligament involved in knee injury.^{1,2} It provides support for the medial aspect of the knee and stress from valgus forces, rotational forces, and anterior translational forces. The difference in injury severity differs and can be classified into 3 different grades (I, II, III). Most grade I/II MCL injuries can often be managed nonoperatively³⁻⁷; however, controversy remains

regarding nonoperative and operative treatment for grade III MCL tears, or grade II MCL tears in athletes who engage in sports with a high exposure to pivoting and side-to-side cutting. Typical indications for operative intervention include patients with chronic valgus instability who have not responded to nonsurgical treatment, those with associated multiligament knee injuries, and distal avulsion stener-type lesions.⁸ The purpose of this article is to describe the authors' approach to evaluation and treatment of the MCL and

From the Mammoth Orthopedic Institute, Mammoth Hospital, Mammoth Lakes, California (S.L., B.B.G.); University of Nevada, Reno School of Medicine, Reno, Nevada (R.F.); Barton Center for Orthopedics and Wellness, South Lake Tahoe, California (J.O., A.H.); and Proliance Orthopaedics and Sports Medicine, Issaquah, Washington (C.J.W.)

The authors report the following potential conflicts of interest or sources of funding: B.B.G. reports consulting fees from Arthrex; payment or honoraria for lectures, presentations, speakers' bureaus, manuscript writing, or educational events from Doximity; support for attending meetings and/or travel from Arthrex, Stryker, Smith & Nephew, Don Joy, Ossur, Mammoth Hospital, and Catalyst Ortho Science; Clinical Advisory Board of Smart Medical Devices; leadership or fiduciary role in other board, society, committee or advocacy group, paid or unpaid: AANA (committee), Arthroscopy (editorial board); stock or stock options from ROM3 and Doximity; research support from Arthrex, outside the submitted work; financial support for research and scholarly activities from Mammoth Orthopedic Institute; and medical

education from Reno Regenerative Medicine and Mammoth Sports Course. C.J.W. reports payment or honoraria for lectures, presentations, speakers' bureaus, manuscript writing, or educational events from Arthrex. Full ICMJE author disclosure forms are available for this article online, as [supplementary material](#).

Received May 6, 2022; accepted July 8, 2022.

Address correspondence to Brian Gilmer, M.D., Mammoth Orthopedic Institute, 85 Sierra Park Rd., Mammoth Lakes, CA 93546. E-mail: bbgilmer@gmail.com

© 2022 THE AUTHORS. Published by Elsevier on behalf of the Arthroscopy Association of North America. This is an open access article under the CC BY-NC-ND license (<http://creativecommons.org/licenses/by-nc-nd/4.0/>).

2212-6287/22605

<https://doi.org/10.1016/j.eats.2022.07.003>

to describe a durable, reproducible technique for MCL reconstruction/augmentation using a hamstring autograft—the modified Bosworth technique.

Evaluation

Athletes sustaining an MCL injury will frequently present with an acute onset of medial-sided knee pain and/or valgus instability/laxity following a valgus injury. Occasionally the patient will report a “pop” or “tearing” sensation. Localized pain along the medial knee is typical and in a short time may be accompanied by localized swelling. In isolated injuries, a joint effusion is rare; when present, the surgeon should have a high suspicion for concomitant injury.

Physical examination will reveal tenderness to palpation. Most commonly this is over the medial epicondyle but can alternatively be present on the proximal medial tibial plateau indicating a distal injury. Care should be taken to identify the area of injury, as distal injuries may have a lower propensity for healing without surgery. Hours to days after the MCL injury, patients may present with a decreased range of motion in terminal extension and flexion past 70° to 90°. Valgus stress testing should be performed in 0° of extension and 30° flexion. Clinical grading is highly subjective when the examiner attempts to estimate millimeters of opening. Extension opening to valgus stress >5 mm compared with the opposite side indicates the likelihood of an advanced (grade III) injury or combined injuries. Opening to valgus stress >5 mm at 30° but not full extension indicates at minimum intermediate (grade II or III) injury. The Swain test or alternatively the dial test (external rotation of the tibia with the knee flexed 90°) usually produces pain medially, and with high-grade and combined injuries anteromedial rotatory instability can be appreciated and must be distinguished from posterolateral instability in the multiply injured knee.

Imaging with radiographs and/or stress radiography is an adjunct to clinical examination. Valgus stress radiographs taken with the knee at 0° and 20° are compared with the uninjured extremity. Cadaveric studies have shown injuries to the superficial MCL can result in 3.2-mm increased opening versus upwards of 9.8-mm opening with disruption of both the superficial and deep fibers. Stress radiography is critical in the evaluation of MCL stability, particularly in the setting of revision anterior cruciate ligament (ACL) reconstruction when clinical suspicion of concomitant MCL laxity is present, because unaddressed persistence of MCL instability may play a role in ACL graft failures. Magnetic resonance imaging will be useful to identify the degree and location of MCL injury. This is important, particularly if surgery is considered, as it will allow the surgeon to plan for repair and augmentation.

When concomitant procedures are performed, arthroscopic stress examination is often useful. A 4-mm arthroscopy hook probe is used to measure medial compartment opening to valgus stress at 0° and 30° flexion. Opening in excess of 6 mm in full extension or greater than 9 to 10 mm in flexion may be relative indications for surgical management of the MCL.

Acute and Nonoperative Treatment

Ice, rest, nonsteroidal anti-inflammatory drugs, and a brief period of immobilization in extension will generally provide relief for the patient with an acute MCL injury. Early range of motion in a lockable, hinged knee brace should be instituted as soon as comfort allows, and weight-bearing is encouraged unless contraindicated by concomitant injuries. Once the diagnosis and grade of the MCL injury and the presence or absence of other injuries is known, an initial nonoperative approach is generally recommended except in cases where surgical treatment will be prudent. Weight bearing to tolerance in a well-fitted hinged knee brace is allowed and should be maintained until there is no tenderness to palpation present and no pain with valgus stress at 0°, 30°, and the Swain and dial tests are unremarkable. Once achieved, a progressive, straight-line running program is instituted. When tolerated, progression to lateral movement, jumping, landing, agility training and cutting maneuvers can be instituted. A well-fitted athletic knee brace may be considered at return to sport for contact athletes at risk for lateral impact or trauma for a period of 4 to 12 weeks to avoid reinjury.

Surgical Indications

While nonoperative treatment of isolated grade I and grade II injuries has shown excellent outcomes, there are circumstances in which operative treatment may be advisable. In the authors' experience, these include:

1. Isolated acute MCL injuries of the distal MCL insertion with gross laxity, particularly when a sterner lesion of the MCL (interposition of the pes anserine between the torn distal insertion and the tibia) is present.
2. High-grade clinical/radiographic acute MCL tears in persons with a high degree of physiologic valgus, where bracing and healing may be unpredictable with early weight-bearing.
3. MCL injuries demonstrating persistent clinical and stress-radiograph instability despite an adequate interval to allow for healing (>4 weeks' postinjury).
4. Multiple-ligament knee injuries (Schenck classification KD-3M or KD4), when either a 2-staged reconstruction (addressing medial and/or lateral injuries acutely) or single-stage reconstruction will be performed acutely.

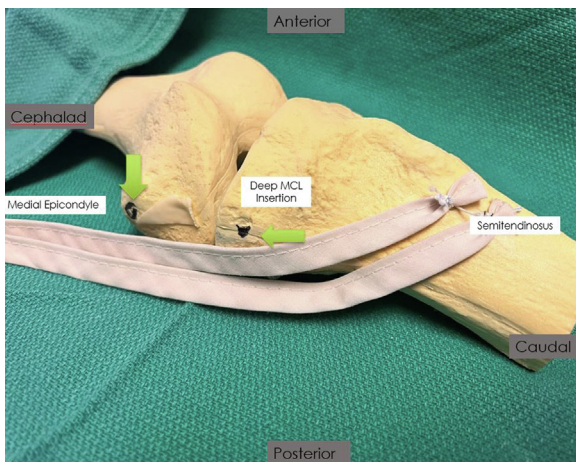


Fig 1. Model of left knee with the distal leg oriented to the right side of the image. The semitendinosus tendon is just distal to the smaller gracilis tendon at its insertion. The insertion is left intact distally at the pes. A “pigtail” open stripper or preferably a closeable atraumatic hamstring harvester is utilized to strip the semitendinosus from its muscle belly proximally, obtaining the longest possible graft for reconstruction. (MCL, medial collateral ligament.)

5. MCL injuries occurring concomitantly in the setting of ACL tears or posterior cruciate ligament (PCL) tears undergoing reconstruction, when an adequate interval for healing has elapsed, but demonstrable clinical, radiographic, or arthroscopic exam evidence of valgus instability persists.

It is critical if surgical reconstruction or revision of one or both cruciates is to be performed and a concern for valgus instability exists; the surgeon should counsel the patient as to the possibility of MCL repair and/or augmentation. Preoperative and/or intraoperative comparison stress fluoroscopic views and stress arthroscopic views before reconstruction of the central pivot should be strongly considered. There exists a high degree of inertia for a surgeon to address MCL injuries; untreated collateral ligament injury can be a contributing factor to ACL and PCL graft failure after reconstruction, or a clinical sense of continued instability of the joint. This MCL instability will not be apparent if immediately evaluated after reconstruction, because the reconstructed graft can participate in limiting valgus opening to stress acutely, but the reconstruction may not durably be able to resist the abnormal translation, axial, and valgus rotatory forces inherent to the MCL-deficient knee.

Surgical Technique: The Modified Bosworth Autograft Reconstruction/ Augmentation (With Video Illustration)

The surgical technique is demonstrated in [Video 1](#). When possible, it is the authors’ preference to use autograft tissues over allograft or synthetic grafts

because of the theoretical benefits of biologic incorporation, high strength, and lower potential infection risk. The semitendinosus tendon is an ideal autograft for many reasons: (1) it is of adequate diameter and tensile strength; (2) when properly harvested, the semitendinosus is long enough to make a 2-limbed reconstruction; and (3) the insertion can be left intact close to where tibial tunnel drilling for ACL or PCL reconstructions is performed and obviates the need to create a second (or third) tibial tunnel. In addition, many, if not the majority, of patients who undergo reconstruction of multiple ligaments will at some point progress to develop osteoarthritis of the knee or may have reinjuries requiring ligament revision. It is advantageous in the arthroplasty or revision settings if the knee is largely free of osseous voids, retained implants, and stress risers to metaphyseal bone surfaces. For this reason, it is the author’s opinion minimalist and fixation methods are preferable.

The presented modification of the original Bosworth technique addresses the fact the pes anserine is not located at the ideal anatomic insertion of the superficial MCL, the modification shortens the “working length” of the graft (theoretically improving the stiffness of the reconstruction), and it allows for a double-limb reconstruction technique, improving rotational stability and reconstruction of the posterior oblique fibers of the MCL. In addition, the procedure optimizes graft healing using low-profile, fixation methods.

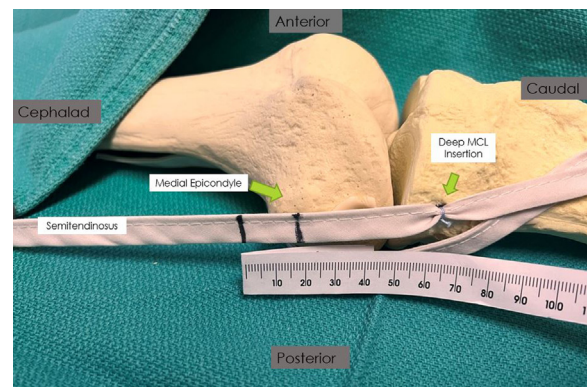


Fig 2. Model of left knee with the distal leg oriented to the right side of the image. An Arthrex knotless FiberTak anchor (Arthrex, Naples, FL) is deployed into the trough of the proximal medial plateau at the insertion of the deep MCL. The model shows 1 anchor, although 2 are typically used in clinical practice. The semitendinosus tendon is directed into the trough and secured close to the joint line. The semitendinosus is then run parallel to the superficial MCL fibers toward the medial epicondyle. The semitendinosus graft is then doubled over a passing suture with enough length to allow 20 mm of doubled tendon to enter the bone tunnel at the isometric position. (MCL, medial collateral ligament.)

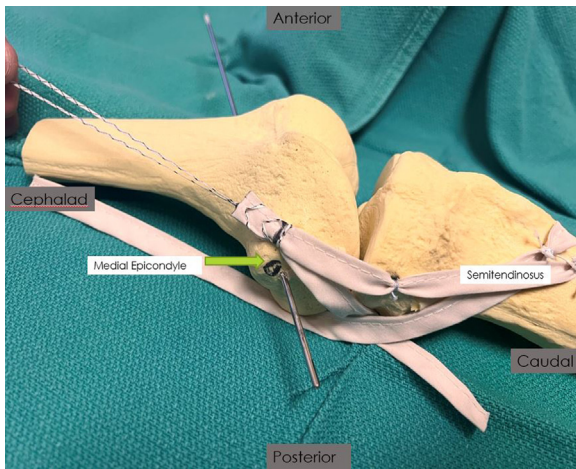


Fig 3. Model of left knee with the distal leg oriented to the right side of the image. A guide pin is used to identify the isometric point of insertion of the graft near the medial epicondyle. This location may vary, and the location in the model should not be used as an appropriate reference. Location should be based off anatomic and/or radiographic landmarks. Looping the semitendinosus tendon around the pin will define the isometric point where the femoral tunnel should be created. The hamstring is then looped over itself at a point approximately 20 mm distal to the point where the tendon is expected to enter the bone at the identified isometric point. This whip stitched portion will be dunked in the femoral tunnel.

Surgical Exposure and Autograft Harvest

An obliquely oriented incision is made from the medial joint line to a point just proximal to the pes insertion. The dissection is carried down to the fibrous superior border of the sartorius fascia, which is split in line with the fibers distally to the insertion to bone and proximally above the joint line. The distal fibers of the superficial MCL will be apparent, as will the zone of injury when the MCL disruption is distal. The sartorius is left intact at its insertion, and the gracilis and semitendinosus tendons can be easily palpated and identified distal to this upper border running along its undersurface. The semitendinosus is the more robust structure, running inferior to the smaller gracilis. The sartorius and gracilis are retracted away from the tibia surface, and the semitendinosus is retrieved into view using an arthroscopy probe or right-angle hemostat. The insertion is left intact distally at the pes anserine. Tension is placed on the semitendinosus while investments and accessory fascial insertions to the gastrocnemius and overlying fasciae are released using a dissecting scissor. A “pigtail” open stripper or preferably a closeable atraumatic hamstring harvester (Atraumatic Hamstring Harvester; Arthrex, Naples, FL) is used to strip the semitendinosus from its muscle belly proximally, obtaining the longest possible graft for reconstruction (Fig 1).

Restoration of a Stable Central Pivot

If indicated, reconstruction of the central pivot (ACL and/or PCL) is performed according to the surgeon's preference. Patellar tendon autograft, quadriceps tendon autograft, or contralateral hamstring autograft are the authors' preferred graft choices for multiple-ligament reconstructions in athletes.

MCL Repair

A primary repair of torn MCL fibers should be attempted when possible. A distal repair can be performed through the harvest/reconstruction/augmentation incision, and a proximal repair can be performed by either extending the medial incision proximally toward the medial epicondyle or creating a separate incision. We have used titanium, all-suture anchors, and PEEK (polyether ether ketone) anchors (Arthrex, Naples, FL) loaded with sliding, nonabsorbable braided repair sutures. They are all suitable and each has its limitations and merits. Even when the MCL is addressed within 4 to 6 weeks after injury, the zone of injury and repair is usually apparent with meticulous dissection. Once any remaining native MCL tissues have been reapproximated using suture anchors and locking stitches, attention is turned to reconstruction/augmentation using the semitendinosus.

Modified Bosworth MCL Reconstruction/Augmentation

The central portion of the superficial MCL is identified at a point 6 mm to 1.6 cm from the joint line. A small split parallel to the MCL fibers is made centrally, the MCL insertion undermined slightly, and a burr or bone-cutting arthroscopy shaver is then used to create a 4 mm wide × 15-20-mm long trough into cancellous

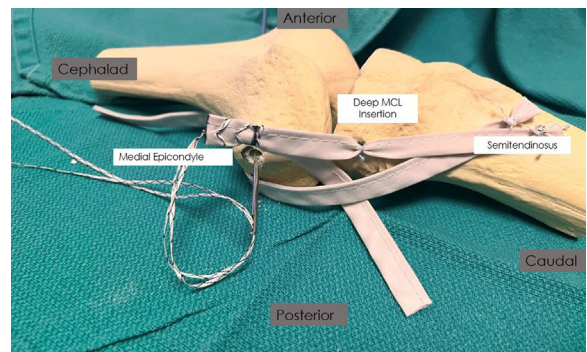


Fig 4. Model of left knee with the distal leg oriented to the right side of the image. The diameter of the doubled graft is measured, and an appropriate cannulated reamer is selected. A bone socket is reamed over the reamer guide pin to a depth adequate to tension the doubled semitendinosus graft into the socket while a varus force is applied to the knee—at least 25 mm. Passing sutures from the tendon are then loaded on the back of the guide pin, which is passed through the lateral distal femur. (MCL, medial collateral ligament.)

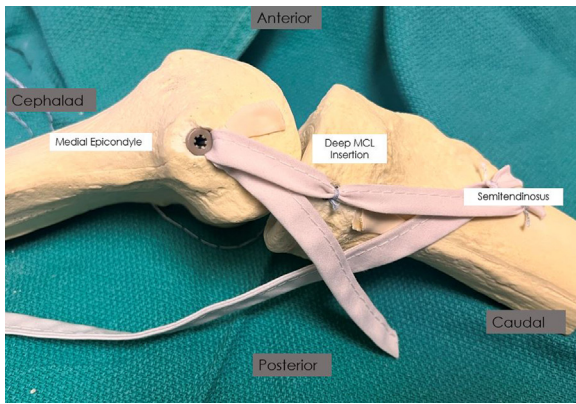


Fig 5. Model of left knee with the distal leg oriented to the right side of the image. An interference screw is then placed into the femoral socket. Screw diameter is typically the same or 1 mm larger than the reamed socket diameter. (MCL, medial collateral ligament.)

bone of the proximal medial tibial plateau. Two knotless 2.6-mm FiberTak anchors (Knotless FiberTak; Arthrex) are deployed onto the trough, one proximally and one distally. The semitendinosus tendon is directed into the trough, tensioned to remove slack between the native insertion and the trough, and secured close to the joint line at the 2 points of fixation. Use of knotless anchors assures a low-profile construct that will not be symptomatic. The semitendinosus is then run parallel to the superficial MCL fibers toward the medial epicondyle. Tension is relieved from the anchors by oversewing the split in the MCL back together, incorporating the graft tissue using #0 absorbable braided sutures (Fig 2).

A reamer guide pin (Beath pin) is used to identify the isometric point of insertion of the graft near the medial epicondyle. Based on anatomic and/or radiographic landmarks, the pin is placed provisionally in the expected position just proximal and posterior to the medial epicondyle. Isometry is assessed by looping the secured semitendinosus tendon around the pin, then marking the tendon in the location where it wraps around the pin. The knee is taken through a range of motion by an assistant while the surgeon monitors the mark on the tendon. A point too far posterior will cause the graft to loosen with knee flexion; the excess slack in the tendon will move towards the surgeon's hand and the free end of the graft indicating it is looser in flexion than in extension. By contrast, a point too far anterior will cause the graft to tighten with flexion with the result being the graft will be felt pulling away from the surgeon's hand and the mark will appear to move toward the fixed end of the graft. The pin position should be adjusted so the semitendinosus graft remains isometric throughout the full range of knee motion. This will be apparent when the tendon maintains an equal tension throughout a full range of motion and the mark

does not appear to move relative to the pin. Once the ideal pin position has been determined, the guide pin is directed anteriorly and proximally with care to avoid convergence with ACL/PCL reconstruction femoral tunnels and advanced bicortically to exit the lateral side of the knee (Fig 3).

The semitendinosus graft is then doubled over a passing suture with enough length to allow 20 mm of doubled tendon to enter the bone tunnel at the isometric position. This can be achieved by using the previous mark used for isometry and adding another mark 20 mm proximal to this point (Fig 4). A free suture is placed at this second mark and the tendon is then folded back over itself. The doubled graft can be whip-stitched using a nonabsorbable braided #2 suture creating a doubled graft over the 20 mm, which will be placed into the femur. The braided suture adds to the stiffness of the loop and may enhance pull-out stability from interference screw fixation (Fig 5). The diameter of the doubled graft is measured with a sizing block, and an appropriate cannulated reamer is selected. A bone socket is reamed over the reamer guide pin to a depth adequate to tension the doubled semitendinosus graft into the socket while a varus force is applied to the knee. If the proper isometric point has been chosen, the degree of knee flexion chosen during graft tensioning and fixation should not be critical, however, the authors typically tension the graft at 30° to 45° of knee flexion and place an interference screw equal or 1 mm larger than the tunnel diameter to firmly secure the graft proximally.

If adequate tendon is remaining, the free end of the doubled graft may be shuttled back distally to the

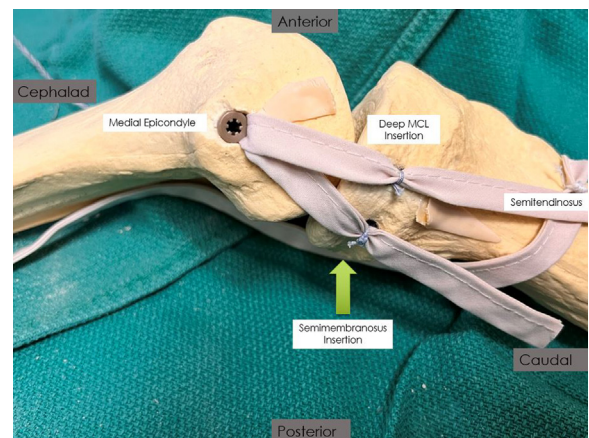


Fig 6. Model of left knee with the distal leg oriented to the right side of the image. If adequate tendon is remaining, the free end of the doubled graft can shuttle back distally to the posteromedial tibial plateau. A second bony trough can be developed using the burr or shaver and the tendon end secured into the trough using 1 or 2 knotless all-suture anchors, creating a posterior oblique limb of the reconstruction graft. (MCL, medial collateral ligament.)

Table 1. Pearl and Pitfalls**Pearls**

- This technique efficiently maximizes isometry of the ligament and reduces length change patterns.
- The harvesting of the hamstring tendon autograft is familiar for most surgeons
- The semitendinosus autograft reduces risk of potential disease transmission and lower failure rates compared with allograft use.

Pitfalls

- For combined ACL/MCL reconstruction, the hamstring tendons are common autograft sites for the ACL which will require the ACL graft source to be from a different location.
- Technique may not always provide adequate hamstring length to complete combined posterior oblique ligament reconstruction
- There is risk of tunnel convergence when there is PCL ligament reconstruction involved.

ACL, anterior cruciate ligament; MCL, medial collateral ligament; PCL, posterior cruciate ligament.

posteromedial tibial plateau. A second bony trough is created using the burr or shaver and the tendon end secured into the trough using 1 or 2 knotless all-suture anchors, restoring a posterior oblique limb of the reconstruction graft. Alternatively, the additional graft material may be shuttled back in line with the underlying reconstruction and secured to it with nonabsorbable suture (Fig 6).

Postoperative Management

Patients are placed in a double-hinged locking knee brace for 4 to 7 days to allow for soft tissue and incision healing. Partial weight-bearing is allowed immediately postoperatively, advancing to weight-bearing as tolerated after 7 days except in patients with significant valgus knee alignment, where a more prolonged period of minimized weight-bearing may be appropriate. Range of motion exercises are begun immediately with a low-repetition protocol, stressing the early return of full extension and progression of flexion to 90° as soon as tolerated. Flexion past 90° is allowed 4 weeks postoperatively. Running progression is allowed at 12 weeks, with lateral and agility training allowed after 16 weeks. Unlimited return to cutting and contact athletics is allowed at 5 to 6 months postoperatively.

Discussion

This surgical technique uses the semitendinosus autograft with the distal attachment remaining anatomically attached to the pes anserinus. This presents the additional advantage of identifying an isometric point placement in the femoral attachment to reduce changes in the length of the graft. This, in theory, results in overall lower postoperative knee stiffness due to overconstraint, or conversely, residual laxity

throughout the entire range of motion from flexion to extension. Kittl et al.⁹ emphasized the position of the femoral attachment site is more important for isometry and reduction to the change in ligament fiber length as opposed to the tibial attachment site for reconstruction of the MCL. Our technique eliminates the need to establish a tibial attachment site and avoids compromising the isometry of the reconstruction.

Much of the literature agrees on the conservative nonoperative treatment for most MCL injuries^{3,5,6,7}; however, when nonoperative treatment fails, patients can result in having debilitating and persistent medial instability, weakness, osteoarthritis, or increased risk of injury to associated ligamentous structures such as the ACL.¹⁰ MCL repair or reconstruction are the 2 options for operative treatment and the decision depends on the remaining quality of the native ligament. If the MCL is considered to be beyond repair, reconstruction is the obvious choice. For MCL reconstruction, surgeons and patients have a choice between allograft or autograft from a variety of location sources. While the potential risk of autografts includes donor-site morbidity and increase operating time, the potential risks and disadvantages of allografts include greater costs,¹¹ greater risk of disease transmission,¹² greater failure risk and subsequent graft rupture.¹³

There are several disadvantages we have identified with our technique. First, the hamstring tendon is a common autograft harvest site for the reconstruction of the ACL. Because our technique requires the distal attachment remain at the pes anserinus, it is best to identify a different graft site for the ACL to reduce the effect of donor-site morbidity. Second, variability in hamstring length may make it impossible to reliably have enough graft length to perform posterior oblique ligament reconstruction. Finally, reconstruction involving multiple concurrent ligaments of the knee have the potential risk of tunnel convergence and can result in reconstruction failure and a compromise of the integrity of the grafts.¹⁴ For the combined reconstruction of the MCL and PCL, this surgical technique presents a potential risk of femoral tunnel convergence. Camarda et al.¹⁵ reports this can be avoided by limiting the axial angulation of the MCL femoral tunnel between 20° and 40°. Surgeons must consider tunnel location and angulation to avoid femoral tunnel collision (Table 1).

Conclusions

The MCL is a major contributor to the stability of the knee joint in regard to valgus stress, anterior translation, and rotational control. The modified Bosworth MCL reconstruction technique as described herein

provides the surgeon with a reliable and reproducible tool that can be used when operative indications are met. This technique relies on native anatomy and isometry to provide a stable knee medial knee.

References

1. LaPrade RF, Engebretsen AH, Ly TV, Johansen S, Wentorf FA, Engebretsen L. The anatomy of the medial part of the knee. *J Bone Joint Surg Am* 2007;89:2000-2010.
2. Andrews K, Lu A, Mckean L, Ebraheim N. Review: Medial collateral ligament injuries. *J Orthop* 2017;14:550-554.
3. Wijdicks CA, Griffith CJ, Johansen S, Engebretsen L, LaPrade RF. Injuries to the medial collateral ligament and associated medial structures of the knee. *J Bone Joint Surg* 2010;92:1266-1280.
4. Edson CJ. Conservative and postoperative rehabilitation of isolated and combined injuries of the medial collateral ligament. *Sports Med Arthrosc Rev* 2006;14:105-110.
5. Kim C, Chasse PM, Taylor DC. Return to play after medial collateral ligament injury. *Clin Sports Med* 2016;35:679-696.
6. Encinas-Ullán CA, Rodríguez-Merchán EC. Isolated medial collateral ligament tears: An update on management. *EFORT Open Rev* 2018;3:398-407.
7. Kannus P. Long-term results of conservatively treated medial collateral ligament injuries of the knee joint. *Clin Orthop Relat Res* 1988;(226):103-112.
8. Elkin JL, Zamora E, Gallo RA. Combined anterior cruciate ligament and medial collateral ligament knee injuries: Anatomy, diagnosis, management recommendations, and return to sport. *Curr Rev Musculoskelet Med* 2019;12:239-244.
9. Kittl C, Robinson J, Raschke MJ, et al. Medial collateral ligament reconstruction graft isometry is affected by femoral position more than tibial position. *Knee Surg Sports Traumatol Arthrosc* 2021;29:3800-3808.
10. DeLong JM, Waterman BR. Surgical techniques for the reconstruction of medial collateral ligament and posteromedial corner injuries of the knee: A systematic review. *Arthroscopy* 2015;31:2258-2272. e1.
11. Mistry H, Metcalfe A, Colquitt J, et al. Autograft or allograft for reconstruction of anterior cruciate ligament: A health economics perspective. *Knee Surg Sports Traumatol Arthrosc* 2019;27:1782-1790.
12. Mroz TE, Joyce MJ, Steinmetz MP, Lieberman IH, Wang JC. Musculoskeletal allograft risks and recalls in the United States. *J Am Acad Orthop Surg* 2008;16:559-565.
13. Kaeding CC, Aros B, Pedroza A, et al. Allograft versus autograft anterior cruciate ligament reconstruction: Predictors of failure from a MOON prospective longitudinal cohort. *Sports Health* 2011;3:73-81.
14. Crawford MD, Kennedy MI, Bernholt DL, DePhillipo NN, LaPrade RF. Combined posterior cruciate ligament and superficial medial collateral ligament knee reconstruction: Avoiding tunnel convergence. *Arthrosc Tech* 2019;8:e929-e933.
15. Camarda L, Grassedonio E, Lauria M, Midiri M, D'Arienzo M. How to avoid collision between PCL and MCL femoral tunnels during a simultaneous reconstruction. *Knee Surg Sports Traumatol Arthrosc* 2016;24:2767-2772.