EJVES Vascular Forum (2023) 59, 2—7

ORIGINAL RESEARCH

Cephalic Vein Cut Down for Total Implantable Venous Access Ports: A Retrospective Review of a Single Institution Series

Ángel Barba Vélez

Department of Angiology and Vascular Surgery, IMQ Zorrotzaurre University Hospital, Ballets Olaeta Kalea, 4, Bilbao, Spain

Objective: The aim of this work was to describe the early and late success rates of cephalic vein cut down (CVC) in the implantation of totally implantable venous access ports (TIVAP) for chemotherapy treatment in oncological patients.

Methods: This was a retrospective study of 1 047 TIVAP performed in a private institution between 2008 and 2021. The CVC with pre-operative ultrasound (PUS) was the initial approach. All cephalic veins (CVs) were mapped pre-operatively with Doppler ultrasound, measuring their diameter and course in oncological patients who required a TIVAP. With a CV diameter $\geq$ 3.2 mm TIVAP was carried out by CVC; with CV diameter $<$ 3.2 mm, subclavian vein puncture (SVP) was performed.

Results: 1 047 TIVAPs were implanted in 998 patients. The mean age was 61.5 $\pm$ 11.5 years, 624 were women (65.5%). Male patients were significantly older and with a higher incidence of colonic, digestive system, and laryngeal cancer. Initially, TIVAP was indicated in 858 cases (82%) by CVC and 189 (18%) by SVP. The success rate was 98.5% for CVC and 98.4% for SVP. There were no complications for CVC (0%) but five early complications (2.5%) in the SVP group. The rates of late complications were 4.4% in the CVC group and 5.0% in the SVP group, foreign body infection being the most frequent (57.5% of the cases) ($p = .85$).

Conclusion: The CVC or SVP using PUS for TIVAP deployment, performed through a single incision, is a safe and effective technique. This open but minimally invasive technique should be considered in oncological patients.

Article history: Received 11 September 2022, Revised 16 March 2023, Accepted 5 April 2023,

Keywords: Complications, Cephalic Vein Cut down, Pre-operative ultrasound, Success rate, Totally implantable venous access ports

INTRODUCTION

Niederhuber *et al.*[1] performed the first totally implantable venous access port (TIVAP) in 1982 by cephalic vein cut down (CVC). Biffi *et al.*[2] reported how the technique evolved regarding ports and catheters, with increasing popularity of percutaneous access. Nowadays, many groups have adopted the percutaneous approach, despite success rates $<$ 90%, according to Hüttner *et al.*,[3] and the very low intra-operative morbidity of CVC.[4] In 2006 Chen *et al.*[5] promoted the CVC technique but using pre-operative ultrasound (PUS) to characterise the cephalic vein (CV), as well as its course and drainage into the AV prior to deploying the port, improving the success rate.

The $>$ 10 year experience with TIVAP implant through CVC is reported here.

PATIENTS AND METHODS

Between January 2008 and December 2021, all cancer patients attending the Department of Angiology and Vascular Surgery requiring TIVAP were assessed. All patients provided signed informed consent for the procedure.

Generally, the left side was chosen except for left handed patients, previous breast surgery on the left side with and without lymphadenectomy, and previous TIVAP or pacemaker insertion.

With the patient in supine position the CV was displayed by means of a 7.5 — 10 MHz probe of MyLab50 (Esaote, Florence, Italy) Doppler ultrasound at the level of the deltopectoral fold, registering its diameter, course, and the patency of the CV to axillary vein (AV) junction. The CV was considered suitable if it was patent throughout its course up to the AV and its diameter was $\geq$ 3.2 mm. A NuPort HP* (PHS Medical, Watertown, SD, USA) device with a single chamber titanium port and silicone catheter with an external diameter of 9.6F ($\approx$ 3.2 mm) was used. In patients with $<$ 3.2 mm CV, the implant was performed via subclavian vein puncture (SVP) through the same incision.

E-mail address: angel@barbaeguskiza.com (Ángel Barba Vélez).

https://doi.org/10.1016/j.ejvsvf.2023.04.002

The procedure by CVC was performed in the operating room. Through a 3 − 4 cm incision in the deltopectoral fold, the CV is dissected and controlled with vessel loops, a longitudinal venotomy is made, and the catheter is introduced with the help of the pic vein, without a guidewire or a sheath, until its distal end is lodged in the cava-atrial confluence confirmed by radiological control with a BV Bracelet C arm (Philips, Amsterdam, The Netherlands), visualising the track of the catheter. The catheter is fixed by vein ligation proximal to the venotomy, to avoid retrograde bleeding and possible subsequent displacement. The port is lodged in a preformed subcutaneous pocket anterior to the pectoralis major muscle. Reflux is checked through the Huber needle, the system is sealed, and the incision is closed in a standard fashion.

For implantation by SVP, the Seldinger technique was used, with anatomical landmarks as references, with the same single incision as for the CVC, unlike the regular percutaneous technique, which requires two incisions and tunnelling, and using a micropuncture set (AngioDynamics) with a 21 gauge needle, a 0.035 inch guidewire, and a split sheath. The rest of the technique was the same as described above, except that the catheter was fixed to the muscular plane to avoid subsequent displacements.

The success rate was defined as the percentage of the number of successful functioning implants and the number of implants attempted.

The patients were followed until their death or end of the study (31 March 2022). Data were collected by reviewing the medical records and annual telephone calls. No patients were lost to follow up during the study.

All PUS scans, and surgical and percutaneous interventions were performed by the same vascular surgeon.

Statistical analysis

Qualitative and quantitative variables were reported using number and percentage, mean ± standard deviation (SD). Chi-square, Fisher's exact test, the and t-test were used for analysis. A p value $< .05$ was considered statistically significant. All statistical analyses were performed with SAS 9.4 for Windows statistical software, (SAS Institute, Inc., Cary, NC).

RESULTS

From January 2008 to December 2021, 1 000 patients were assessed in the Department. Two patients were excluded due to an intrathoracic tumour that rendered either technique impossible. Therefore, the present study includes 998 patients: mean age 61.5 ± 11.5 years, and 624 (62.5%) women. Table 1 details the clinical characteristics. Men were significantly older and had a higher incidence of colonic, digestive and laryngeal cancers (Table 1). In 46 patients (4.6%) more than one TIVAP was needed due to tumour recurrence or appearance of new neoplasms.

Table 1. Demographics and characteristics of the 998 implanted totally implantable venous access ports, comparing male and female patients.

	Male	Female	*p*
Gender	374 (37.5)	624 (62.5)	
Age − y, mean	65.2 ± 10.8	59.3 ± 11.4	<.001
Neoplasms			
Breast	1 (0.3)	309 (49.5)	-
Colorectal	155 (41.4)	139 (22.3)	<.001
Lung	54 (14.4)	50 (8)	<.001
Digestive*	99 (26.5)	55 (8.8)	<.001
Genito-urinary	33 (8.8)	54 (8.7)	<.001
Larynx	13 (3.5)	2 (0.2)	<.0001
Haematological	14 (3.7)	11 (1.8)	<.001
Other	5 (1.3)	4 (0.6)	<.001

Data are presented as *n* (%) or mean ± standard deviation.
* Pancreas, oesophagus, stomach, liver.

The PUS findings showed an average diameter of 3.6 ± 0.9 mm. Eight hundred and fifty-eight (82.0%) had a diameter ≥ 3.2 mm, suitable for TIVAP by CVC. In 54 cases (5.2%) the CV was absent. In 128 cases (12.2%) the diameter was < 3.2 mm, and in seven (0.6%) there was no continuity with AV, consequently SVP was required. In 890 cases (85.0%) the left side was selected and in 157 patients (15.0%) the right side: 90 cases (57.3%) because of breast surgery with and without left axillary lymphadenectomy, 45 cases (28.7%) due to previous left implant of pacemakers or TIVAP, 19 (12.1%) were left handed patients and in three (0.2%) for other reasons. Figure 1 shows the general distribution of implants observing that in 13 cases (1.5%) the CV had a diameter < 3.5 mm and the catheter could not be inserted by CVC, due to venous spasm, thus the TIVAP was made by SVP.

The success rate for CVC was 98.5%, similar for left (98.6%) and right (96.8%) CV ($p = .11$). In three cases of SVP the catheter could not be inserted due to critical stenosis of superior vena cava secondary to an intrathoracic tumour or an arterial injury. The port was implanted via the great saphenous vein of the right lower extremity or via the right internal jugular vein. Thus, SVP success rate was 98.4%. No differences were found between procedures ($p = .49$). On the 13 occasions that the technique had to be reversed from CVC to SVP the operating time increased by 4.5 ± 2.6 minutes.

There were five (0.5%) early complications, all of them after SVP: four pneumothorax, one requiring pleural drainage, and an arterial lesion that required endovascular repair and subsequent TIVAP via the internal jugular vein. Thus, SVP showed higher complication rate than CVC ($p <$ .001). There was no intra-operative death for either technique. There were 47 late complications (4.5%), with device infection being the main cause in 21 cases (44.7%), and deep venous thrombosis in 12 (25.5%). There were no catheter dislocations or pinch off syndrome. Again, no

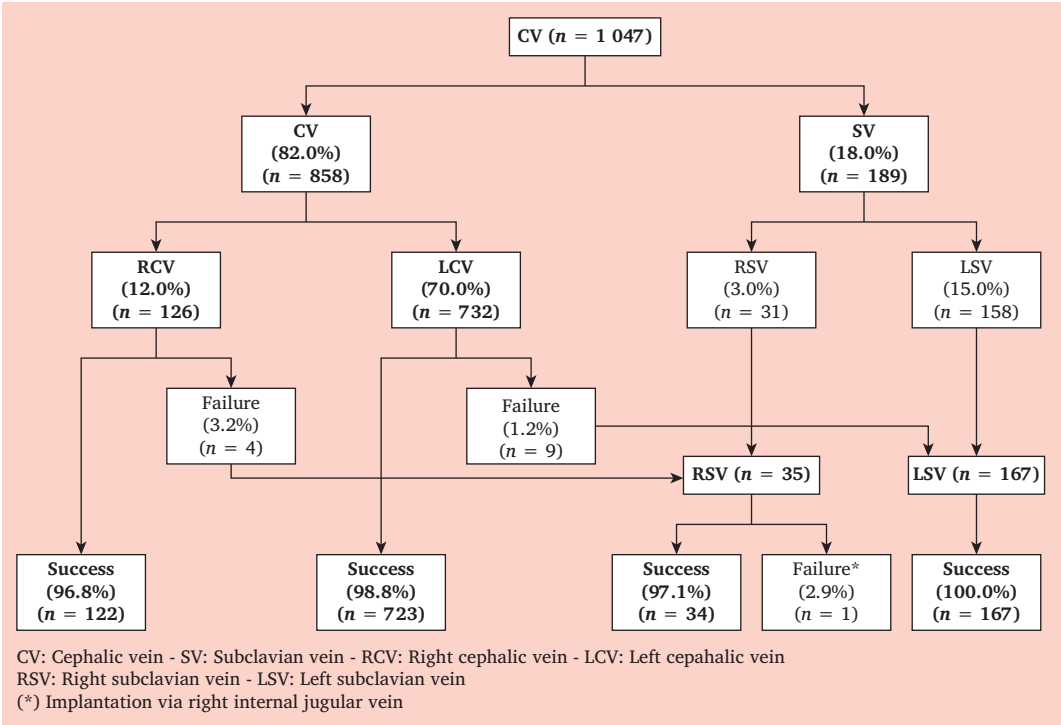

Figure 1. Flow chart describing the technique used for totally implantable venous access port implant and outcomes. CV = cephalic vein; SV= subclavian vein; RCV = right cephalic vein; LVC = left cephalic vein; RSV = right subclavian vein; LSV = left subclavian vein. *Implantation via right internal jugular vein.

statistically significant differences were found between techniques ($p = .85$) (Table 2).

DISCUSSION

This study highlights the good outcomes with very low complication rates of single incision cephalic cut down or SVP for implantation of TIVAP.

This technique is simple, safe, avoids the second incision and the tunnelling required for the percutaneous approach, and has comparable technical success, with even lower early complication rates. PUS helps improve the selection of the technique and the outcome. The widespread use of percutaneous techniques with loss of classic surgical skills[6] is an increasing concern in current training, and simple cephalic cut down procedures should be taught and discussed with the patient, alongside endovascular options.

The main limitation for CVC is CV diameter variability at the deltopectoral fold. The average diameter of the CV is 3.1 — 3.9 mm;[7,8] in this series the average diameter was 3.6 mm. Furthermore, the CV is absent in 2.5 — 18%;[9,10] in this

Table 2. Surgical outcomes of the 998 implanted totally implantable venous access ports, comparing cephalic vein cutdown with subclavian vein puncture.

	CVC ($n = 846$)	SVP ($n = 201$)	p value
CV diameter — mm	3.9 ± 2.6	2.1 ± 1.3	<.001
Time of surgery — mo	24.4 ± 3.2	23.7 ± 3.3	<.001
Success rates	98.4	99.5	<.001
Complications			
Early	0	5 (2.5)	<.001
Pneumothorax	—	4 (2.0)	
Arterial injury	—	1 (0.5)	
Nerve injury	—	—	
Late	37 (4.4)	10 (5.0)	<.001
Deep venous thrombosis	10 (1.2)	2 (1.0)	
Catheter or port infection	17 (2.0)	4 (2.0)	
Catheter obstruction	8 (0.9)	2 (1.0)	
Skin erosion	1 (0.1)	—	
Flip over	—	1 (0.5)	
Others	1 (0.1)	1 (0.5)	

CVC = cephalic vein cut down; SV = subclavian vein puncture; CV = cephalic vein; SD = standard deviation.

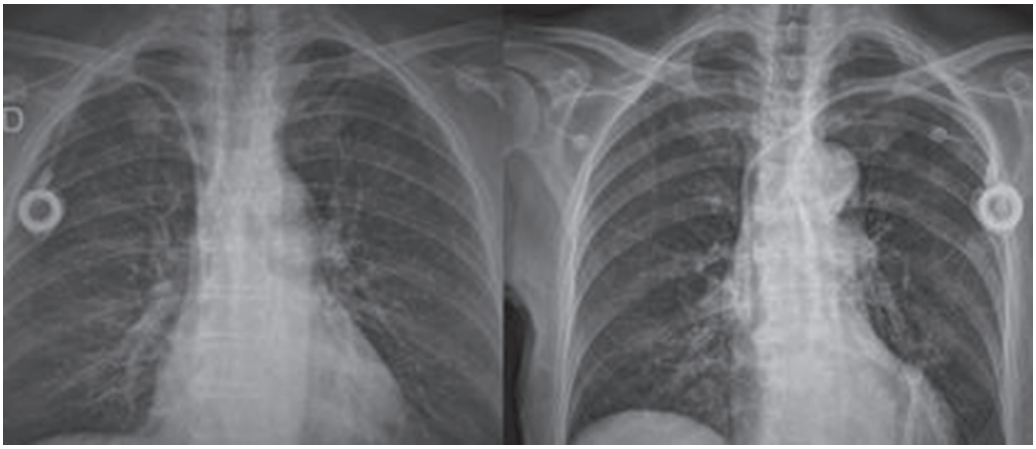

Figure 2. Control chest Xrays after totally implantable venous access port implant showing less curvature of the catheter on the left side.

study the CV was absent in 5.2% of patients. The CV diameter considered too small or as a threshold for indication or contraindication varies in the literature from < 3.0 mm[9,11,12] to < 3.2 mm;[8] the latter was considered in the indication for one or another technique but can vary in other centres.

CV cutdown is the first choice because it uses an anatomical pathway avoiding possible venous puncture complications (pneumo/haemothorax, arterial or nerve injury). This route is supported by Fan *et al.*[13] and Granziera *et al.*,[14] and by two meta-analyses by Atti *et al.*[15] and Benz *et al.*[16] with more than 35,000 patients, which concluded that CVC is the best access for deploying pacemakers, which can be transferred to TIVAP. The left side is chosen as most people are right handed and the continuous movement of the right shoulder joint and the passage of the catheter through the costoclavicular space may cause some lesions;[17] in addition, on the left side, the angles are smoother than on the right side[18] (Figure. 2). The right side is mandatory for patients with previous left breast surgery, although there are authors such as Isom *et al.*,[19] who suggest that SVP could be performed without increasing complications.

The use of PUS for TIVAP by CVC has increased its success rate from 71.0%[20] to 97.2%.[11] The success rate was 98.5%. Toro *et al.*[21] in a review of 17 496 procedures concluded that the CVC, even without PUS, remains the only technique without early complications. CV spasm according to some authors[22] was the cause of failure in 7.5% of patients, however it was only experienced in 1.7% of the cases in this series. Moreover, if CVC has an initial failure, SVP can be performed through the same incision achieving 99.8% success as Di Carlo and Toro[23] demonstrated.

Success rates using SVP have also varied from 80.9%[24] to 96.3%.[25] When using intra-operative ultrasound, rates range from 95.0%[26] to 99.7%[14] or 100.0%.[27] It is suggested that the CVC approach plus PUS equates to SVP regardless of intra-operative ultrasound. Table 3 shows the success rates published in the last 10 years by authors using both techniques.

In the literature review, peri-operative complications by CVC range from 0% — 5.0%.[11,14,20,28,29,30] Early complications of SVP varied from 1.1%[3] — 16.6%.[14,31] When PUS is added, the percentages are not only reduced but, in some cases, negligible.[32,33]

Table 3. Success rates of totally implantable venous access ports published between 2011—2020 using cephalic vein and subclavian vein access.

First author	Year	CV — %	SV — %
Hüttner[3]	2020	75.6	87.5
Ertel[28]	2017	90.1	92.3
Matiotti-Neto[39]	2017	86.0	96.3
Hsu[40]	2016	80.0	84.0
Otsubo[11]	2016	93.7*	n/a
Klaiber[41]	2015	80.0	90.0
Granziera[14]	2014	85.3	93.8
Biffi[2]	2014	79.0	99.3†
Dauser[42]	2012	87.1	94.6
Knebel[43]	2011	85.0	99.0†
Current study		98.5*	99.5

CV = cephalic vein; SV = subclavian vein; n/a= not available
* Pre-operative ultrasound.
† Intra-operative ultrasound.

Table 4. Complication rates of totally implantable venous access ports published between 2011—2020 comparing cephalic vein and subclavian vein access.

First author		CV		SV	
	Year	EC — %	LC — %	EC — %	LC — %
Pérez[44]	2020	1.3	15.4	3.9	8.0
Matiotti[39]	2017	4.1	4.6	5.3	5.7
Alsfasser[45]	2016	2.0	4.9	2.0	9.6
Granziera[14]	2014	0	13.7	16.6	10.8
Biffi[2]	2014	1.5	0	8.0	10.5
Dauser[42]	2012	0	1.2	3.7	3.3
Knebel[43]	2011	0	15.1	6.1	18.4
Current study		0	4.4	2.5	5.0

CV= cephalic vein; SV = subclavian vein; EC = early complication (<30 days); LC = late complication (≥30 days).

In the CVC group there were 4.4% late complications in this study. Previous literature reports late complication rates of 1.9% to 15.7%.[34,35] In the SVP group late complications vary between 2.7 and 15.0%.[36–38] In the present study late complications were 5%. Device infection was the main complication in most studies.[37] Table 4 details the complication rates reported in the last decade.

This study has some limitations. It was a retrospective single centre one arm cohort study, and all procedures were performed by the same surgeon, so external validity may be limited. Perhaps the main strength lies in the high number of patients assessed and the complete follow up of the cohort.

Conclusion

The CVC or SVP, using PUS for TIVAP deployment, performed through a single incision, is a safe and effective technique, and should be considered in oncological patients.

CONFLICT OF INTEREST

None.

FUNDING

None.

REFERENCES

1 Niederhuber JE, Ensminger W, Gyves JW, Liepman M, Doan K, Cozzi E. Totally implanted venous and arterial access system to replace external catheters in cancer treatment. *Surgery* 1982;**92**:706–12.
2 Biffi R, Toro A, Pozzi S, Di Carlo I. Totally implantable vascular access devices 30 years after the first procedure. What has changed and what is still unsolved? *Support Care Cancer* 2014;**22**:1705–14.
3 Hüttner FJ, Bruckner T, Hackbusch M, Weitz J, Bork U, Kotschenreuther P, et al. Primary open versus closed implantation strategy for totally implantable venous access ports: the multicentre randomized controlled PORTAS-3 trial (DRKS 00004900). *Ann Surg* 2020;**272**:950–60.
4 Tabatabaie O, Kasumova GG, Eskander MF, Critchlow JF, Tawa NE, Tseng JF. Totally implantable venous access devices: a review of complications and management strategies. *Am J Clin Oncol* 2017;**40**:94–105.
5 Chen JY, Chang KC, Lin KH, Lin YC, Lee JD, Huang SK. Ultrasonographic predictors of unsuccessful cephalic vein approach during pacemaker or defibrillator lead implantation. *Pacing Clin Electrophysiol* 2006;**29**:706–11.
6 Zhang KC, Chen L. Chinese expert consensus and practice guideline of totally implantable access port for digestive tract carcinomas. *World J Gastroenterol* 2020;**26**:3517–27.
7 Rhu J, Jun KW, Song BJ, Sung K, Cho J. Cephalic vein approach for the implantable central venous access: a retrospective review of the single institution's experiences; Cohort Study. *Medicine (Baltimore)* 2019;**98**:e18007.
8 Yalniz A, Cam I, Bozyel S. Ultrasound guided percutaneous cephalic venipuncture for implantation of cardiac implantable electronic devices. *J Vasc Access* 2021;**24**:1–6.
9 Koketsu S, Samesima S, Yoneyama S, Okada T, Tomozawa S, Horikoshi H, et al. Outcome of cephalic vein cut-down approach: a safe and feasible approach for totally implantable venous access device placement. *Oncol Lett* 2010;**1**:1029–31.
10 Su TW, Wu CF, Fu JY, Ko PJ, Yu SY, Kao TC, et al. Deltoid branch of thoracoacromial vein: a safe alternative entry vessel for intravenous port implantation. *Medicine (Baltimore)* 2015;**94**:e728.
11 Otsubo R, Hatachi T, Shibata K, Yoshida T, Watanabe H, Oikawa M, et al. Evaluation of totally implantable central venous access devices with the cephalic vein cut-down approach: usefulness of preoperative ultrasonography. *J Surg Oncol* 2016;**113**:114–9.
12 Ayadi S, Ksantini R, Maghrebi H, Daghfous A, Ayadi M, Fteriche F, et al. Impact thérapeutique de l'utilisation de la veine céphalique pour la mise en place des chambres implantables pour chimiothérapie [Totally implantable venous access ports by cephalic vein cut-down for patients receiving chemotherapy]. *Tunis Med* 2011;**89**:699–702.
13 Fan WC, Wu CH, Tsai MJ, Tsai YM, Chang HL, Hunget JY, et al. Risk factors for venous port migration in a single institute in Taiwan. *J Surg Oncol* 2014;**12**(15):1–6.
14 Granziera E, Scarpa M, Ciccarese A, Filip B, Cagol M, Manfredi V, et al. Totally implantable venous access devices: retrospective analysis of different insertion techniques and predictors of complications in 796 devices implanted in a single institution. *BMC Surg* 2014;**14**:27.
15 Atti V, Turagam MK, Garg J, Koerber S, Angirekula A, Gopinathannair R, et al. Subclavian and axillary vein access versus cephalic vein cutdown for cardiac implantable electronic device implantation: a meta-analysis. *JACC Clin Electrophysiol* 2020;**6**:661–71.
16 Benz AP, Vamos M, Erath JW, Hohnloser SH. Cephalic vs. subclavian lead implantation in cardiac implantable electronic devices: a systematic review and meta-analysis. *Europace* 2019;**21**:121–9.
17 Seo TS, Song MG, Kang EY, Lee CH, Yong HS, Doo K. A single-incision technique for placement of implantable venous access ports via the axillary vein. *J Vasc Interv Radiol* 2014;**25**:1439–46.
18 Jan HC, Chou SJ, Chen TH, Lee CI, Chen TK, Lou MA. Management and prevention of complications of subcutaneous intravenous infusion port. *Surg Oncol* 2012;**21**:7–13.
19 Isom C, Bream Jr P, Gallagher K, Walia S, Ahmed R, Kauffmann R. Placement of subcutaneous central venous ports in breast cancer patients: does side Matter? *J Surg Res* 2019;**244**:296–301.
20 Nocito A, Wildi S, Rufibach K, Clavien PA, Weber M. Randomized clinical trial comparing venous cutdown with the Seldinger technique for placement of implantable venous access ports. *Br J Surg* 2009;**96**:1129–34.
21 Toro A, Schembari E, Fontana EG, Di Saverio S, Di Carlo I. Forty years after the first totally implantable venous access device (TIVAD) implant: the pure surgical cut-down technique only avoids immediate complications that can be fatal. *Langenbecks Arch Surg* 2021;**406**:1739–49.
22 Steckiewicz R, Świętoń EB, Bogdańska M, Stolarz P. Vasoconstrictive responses of the cephalic vein during first-time cardiac implantable electronic device placement. *Folia Morphol (Warsz)* 2018;**77**:464–70.
23 Di Carlo I, Toro A. The totally implantable venous access device with occurrence of pneumothorax still remains an issue. *World J Surg* 2017;**41**:1398.
24 Tsai YF, Ku YH, Chen SW, Lu CC, Tsao C. Right and left subclavian vein Port-a-Cath systems: comparison of complications. *Eur Surg Res* 2012;**49**:66–72.

25 Ma LI, Liu Y, Wang J, Chang Y, Yu L, Geng C. Totally implantable venous access port systems and associated complications: a single-institution retrospective analysis of 2,996 breast cancer patients. *Mol Clin Oncol* 2016;**4**:456—60.

26 Mudan S, Giakoustidis A, Morrison D, Iosifidou S, Raobaikady R, Neofytou K, et al. 1000 Port-A-Cath ® placements by subclavian vein approach: single surgeon experience. *World J Surg* 2015;**39**:328—34.

27 Hemmati H, Delshad MSE, Barzegar MR, Jandaghi AB, Najafi B, Asgary MR, et al. Ultrasound guided Port-A-Cath implantation. *Surgical Sci* 2014;**5**:159—63.

28 Ertel AE, McHenryZD Venkatesan VK, Hanseman DJ, Wima K, RSet al Hoehn. Surgeon, not technique, defines outcomes after central venous port insertion. *Surgery* 2017;**209**:220—6.

29 Bestetti V, Zeller R, Wenning AS, Mouton KT, Mouton WG. Pneumothorax and subclavian vein thrombosis in patients with venous access device implantation. *Int Surg* 2017;**102**:382—6.

30 Wu CF, Fu JY, Wen CT, Chiu CH, Hsieh MJ, Liu YH, et al. Long-term results of a standard algorithm for intravenous port implantation. *J Personalized Med* 2021;**11**:344.

31 Lenz H, Myre K, Draegni T, Dorph E. A five-year data report of long-term central venous catheters focusing on early complications. *Anesthesiol Res Pract* 2019;**2019**:6769506.

32 Pezhman F, Zahra O, Roozbeh Ch. Complications of chemotherapy port catheters (CPC) in patients with cancer, A 5-year follow up study. *Eur J Mol Clin Med* 2021;**8**:2957—63.

33 Bai XM, Wang J, Zhou Y, Sun XW, Cheng L, Gu XS, et al. Totally implantable venous access devices: the supraclavicular percutaneous approach and early complications. *J Cancer Res Ther* 2020;**16**:1575—81.

34 Cavallaro G, Sanguinett A, Iorio O, D'Ermo G, Polistena A, Avenia N, et al. Ultrasound-guided vein puncture versus surgical cut-down technique in totally implantable venous access devices (TIVADS): a prospective comparative study on safety, efficacy and complications. *Int Surg* 2014;**99**:475—8.

35 Schreckenbach T, Münch I, El Youzouri H, Bechstein WO, Habbe N. The safety level of total central venous access port implantation performed by residents. *J Surg Educ* 2019;**76**:182—92.

36 Yıldırım İ, Tütüncü AÇ, Bademler S, Özgür İ, Demiray M, Karanlık H. Does the real-time ultrasound guidance provide safer venipuncture in implantable venous port implantation? *J Vasc Access* 2018;**19**:297—302.

37 Lin WY, Lin CP, Hsu CH, Lee YH, Lin YT, Hsu MC, et al. Right or left? Side selection for a totally implantable vascular access device: a randomised observational study. *Br J Cancer* 2017;**117**:932—7.

38 Rai G, Kumara V, Bishnoi AK. Combined approach for Port-a-Cath implantation -a dependable alternative. *Sri Lankan J Anaesthesiol* 2020;**28**:108—13.

39 Matiotti-Neto M, Eskander MF, Tabatabaie O, et al. Percutaneous versus cut-down technique for indwelling port placement. *Am Surg* 2017;**83**:1336—42.

40 Hsu CC, Kwan GN, Evans-Barns H, Rophael JA, van Driel ML. Venous cutdown versus the Seldinger technique for placement of totally implantable venous access ports. *Cochrane Database Syst Rev* 2016;**8**:CD008942.

41 Klaiber U, Grummich K, Jensen K, Saure D, Contin P, Hüttner FJ, et al. Closed cannulation of subclavian vein vs open cut-down of cephalic vein for totally implantable venous access port (TIVAP) implantation: protocol for a systematic review and proportional meta-analysis of perioperative and postoperative complications. *Syst Rev* 2015;**4**:53.

42 Dauser B, Stopfer J, Ghaffari S, Herbst F. Subclavian vein puncture vs. surgical cut-down to the cephalic vein for insertion of totally implantable venous access ports. *Eur Surg* 2012;**44**:331—5.

43 Knebel P, Lopez-Benitez R, Fischer L, Radeleff BA, Stampfl U, Bruckner T, et al. Insertion of totally implantable venous access devices: an expertise-based, randomized, controlled trial (NCT00600444). *Ann Surg* 2011;**253**:1111—7.

44 Pérez J, Valls J, Crusellas O, Petrone P. Comparative study of access routes for Port-A-Cath® implantation. *Cir Esp (Engl Ed)* 2020;**98**:79—84.

45 Alsfasser G, Neumann A, Klar E. Venous access port implantation is an ideal teaching operation — an analysis of 1423 cases. *Zentralbl Chir* 2016;**141**:183—9.