

Effect of infliximab against cisplatin-induced nephrotoxicity

Erkan Cure, MD, PhD, Aynur Kirbas, MD, PhD, Levent Tumkaya, MD, PhD, Medine C. Cure, MD, PhD, Osman Z. Şabin, MD, PhD, Yildiray Kalkan, MD, PhD, Suleyman Yuçe, MD, Durdu Altuner, MD, PhD.

ABSTRACT

الأهداف: التحقق في ما إذا كان انفليكسيماب – مثبط عامل نخر الورم ألفا (TNF- α) – يمنع السمية الكلوية الناتجة عن استخدام سيسبلاتين.

الطريقة: تم إجراء الدراسة في قسم الأمراض الباطنية في جامعة رجب طيب اردوغان، ريزة، تركيا خلال الفترة من 1 نوفمبر 2012م إلى 10 مايو 2013م. تم تقسيم 30 ذكراً من الجرذان البيضاء ويستار إلى 3 مجموعات. تم حقن الحيوانات في مجموعة سيسبلاتين بجرعة واحدة (7 ملغ/كغ) من سيسبلاتين عن طريق الغشاء البريتوني. تم حقن الحيوانات في مجموعة سيسبلاتين+ انفليكسيماب بجرعة واحدة (7 ملغ/كغ) قبل 72 ساعة من حقنهم سيسبلاتين.

النتائج: مستويات TNF- α ، انترلوكين 1 بيتا (IL-1 β)، وأكسيد النيتريك (NO) ونازعة أمين الأدينوزين (ADA) في مجموعة سيسبلاتين كانت أعلى من كل من المجموعة الضابطة TNF- α ($p<0.001$)، IL-1 α ($p<0.001$)، NO ($p<0.001$) و ADA ($p<0.001$) ومجموعة سيسبلاتين + انفليكسيماب و TNF- α ($p<0.001$)، IL-1 β ($p<0.001$) و NO ($p<0.001$) و ADA ($p=0.003$). كشف فحص الأنسجة أضرار واسعة النطاق في مجموعة سيسبلاتين بينما كانت أقل في مجموعة سيسبلاتين+ انفليكسيماب. بينما كان مستوى الكربونيك الأنهيداز الثاني (CA-II) في مجموعة سيسبلاتين أقل من المجموعتين، المستوى كان متشابهاً بين المجموعة الضابطة ومجموعة سيسبلاتين+ انفليكسيماب.

الخلاصة: انفليكسيماب يعمل بقوة ضد السمية الكلوية الناتجة عن استخدام سيسبلاتين بواسطة التثبيط القوي لTNF- α ، بالإضافة إلى ذلك، فإن الجمع بين هذين العقارين لا يغير من مستوى CA-II.

Objectives: To investigate whether infliximab (Ib), an inhibitor of tumor necrosis factor alpha (TNF- α), prevents cisplatin (Cis)-induced nephrotoxicity.

Methods: The study was performed in the Department of Internal Medicine, Recep Tayyip Erdogan University, Rize, Turkey, between November 2012 and May 2013. Thirty male Wistar albino rats were divided into 3 groups, a control group, a Cis group, and a Cis+Ib group. The animals of the Cis group were injected with a single dose (7 mg/kg) of Cis intraperitoneally. The animals of the Cis+Ib group were injected with a single dose (7 mg/kg) of Ib 72 hours prior to Cis injection.

Results: The TNF- α , interleukin-1 beta (IL-1 β), nitric oxide (NO) and adenosine deaminase (ADA) levels of the Cis group were higher than both the control group TNF- α ($p<0.001$), IL-1 α ($p<0.001$), NO ($p<0.001$) and ADA ($p<0.001$), and the Cis+Ib group TNF- α ($p<0.001$), IL-1 β ($p<0.001$), NO ($p<0.001$), and ADA ($p=0.003$). Histopathological examination revealed extensive damage in the Cis group, while the damage in the Cis+Ib group was lower. While the carbonic anhydrase II (CA-II) level of the Cis group was lower than both groups, it was similar in the Cis+Ib and the control groups.

Conclusion: Infliximab acts against Cis-induced nephrotoxicity by a strong inhibition of TNF- α . Additionally, the combination of these 2 drugs does not obviously change the level of CA-II.

Saudi Med J 2014; Vol. 35 (9): 953-958

From the Departments of Internal Medicine (Cure E, Yuçe), Biochemistry (Kirbas, Cure M), Histology & Embryology (Tumkaya, Kalkan), Nephrology (Şabin), and Pharmacology (Altuner), School of Medicine, Recep Tayyip Erdogan University, Rize, Turkey.

Received 30th April 2014. Accepted 16th July 2014.

Address correspondence and reprint request to: Assistant Professor Erkan Cure, Department of Internal Medicine, School of Medicine, Recep Tayyip Erdogan University, Rize 53100, Turkey. Tel. +90 (464) 2130491 Ext. 1859. Fax. +90 (464) 2170364. E-mail: erkancure@yahoo.com

Disclosure. Funding for this study was received from RTEU Bilimsel Arastirmalar Proje Birimi (BAP), Project No. 2012.106.01.5.

Cisplatin (Cis) is an antineoplastic drug used to treat solid tumors. Although it is used in most chemotherapy regimens, its nephrotoxic effect is a common problem. The mechanisms for Cis-induced nephrotoxicity have been attributed to renal cell apoptosis, oxidative stress, and inflammation.^{1,2} Cisplatin leads to the formation of reactive oxygen species (ROS) by increasing the release of pro-inflammatory cytokines such as tumor necrosis alpha (TNF- α), stimulating apoptosis through the direct effect of the cytokines, and increasing inflammation.³ Moreover, it causes nephrotoxicity by increasing the turnover of purine metabolism to its metabolites.⁴ Cisplatin induced nephrotoxicity is one of the important side effects that limit the use of Cis. Therefore, effective treatment is still sought to prevent it. Infliximab (Ib) is a potent TNF- α inhibitor that can safely be used to treat many chronic diseases with inflammation.⁵ Previous studies have shown that Ib prevents organ damage,^{6,7} and decreases nitric oxide (NO) and ROS formation.⁸ It has no nephrotoxic effect and can be used in patients with renal impairment.⁹ Carbonic anhydrase II (CA-II), which is a zinc metalloenzyme, catalyzes the reversible hydration reaction of carbon dioxide form carbonic acid. It is found in many tissues, mainly the kidneys.¹⁰ Over-expression of CA-II is observed in many cancers, including renal cell cancer.¹¹ This condition leads to cancer cell growth and invasion. On the contrary, the suppression of CA-II or its deficiency leads to metabolic acidosis.¹² In this study, we aimed to investigate whether Ib could prevent cis-induced nephrotoxicity, and whether this combination would affect the CA-II enzyme.

Methods. This was an experimental study conducted in the Department of Internal Medicine, Recep Tayyip Erdogan University, Rize, Turkey, between November 2012 and May 2013. We used 30 male Wistar albino rats that were 12-15 weeks old and weighed 250-300 g. We randomly divided the rats into 3 groups: control group (n=10), Cis group (n=10), and Cis+Ib group (n = 10). We performed every stage of this research according to the Guide for the Care and Use of Laboratory Animals (NIH, 1985), and the local ethical committee approved the study. The study design was based on research that could serve as models. We searched for experimental studies on cis-induced renal toxicity, and those related to Ib in the Index Medicus database. Cis begins to show its toxic effect starting from half an hour to 7 days; particularly, it occurs from one hour to 3 days.¹³ The effects of Ib start one hour after administration, reaches the Cmax level after nearly one day, and lasts

for approximately 8 weeks.⁵ In previous ischemia-reperfusion studies, scarification is usually performed after 3 days of Ib administration.⁷ However, as there is a lack of studies on Ib toxicity, we designed this study to consider the pharmacologic effects of both drugs.

Intraperitoneal injection of isotonic saline solution with the same volume of Cis was performed. A single dose of 7 mg/kg Cis (Cisplatinum Ebewe, EBEWE Pharma Ges.m.b.H Nfg.KG, Unterach, Austria, 0.5 mg/ml) was given intraperitoneally to the animals of the cis group before they were sacrificed after 5 days.¹⁴ Before 72 hours of Cis injection, one dose of 7 mg/kg Ib (Remicate, Schering-Plough (Brinny) Company, Innishannon, Ireland) was given to the rats of the Cis+Ib group.¹⁵ The rats were sacrificed 5 days after the injection of 7 mg/kg cis given as a single dose. All the rats were sacrificed using ketamine hydrochloride (50 mg/kg intramuscularly; Ketalar, Parke-Davis Eczacibasi, Istanbul, Turkey). After their removal from all the rats, the kidney tissues were immediately stored at -80°C until analysis. Blood samples of 10 ml were drawn from all the rats to be biochemically evaluated. After standing at room temperature for 15 minutes, the blood samples were centrifuged at 3,000 rpm for 10 minutes. Serum blood urea nitrogen (BUN) and creatinine were analyzed in the serum using commercial kits (ARCHITECT c16000, Abbott Laboratories, Green Oaks, IL, USA). The tissue samples were homogenized in phosphate buffered saline (PBS) with pH 7.4 and then centrifuged at 10,000 rpm for 20 minutes. Aliquots of the supernatant were placed inside tubes and frozen at -80°C. A turbidimetric procedure was used for protein assay of the tissues by applying benzethonium chloride to denature the proteins. The fine suspension of proteins was measured by a turbidimetric procedure at 404 nanometers (ARCHITECT c16000, Abbott Laboratories, City, IL, USA). The TNF- α level was measured by using rat TNF- α (eBioscience, Vienna, Austria) and interleukin-1 beta (IL-1 β) enzyme-linked immunosorbent assay (ELISA) kit (eBioscience, Vienna, Austria). The limit of detection (LOD) for the TNF- α assay was 11 pg/ml, and that for the IL-1 β assay was 4 pg/ml. We used a commercially available adenosine deaminase (ADA) ELISA kit (Cusabio Biotech Co., Hubei, P.R. China). The LOD for the ADA assay was 0.39 mIU/ml. The NO concentration was measured using a colorimetric assay method (Cayman Chemical Company, Ann Arbor, MI, USA). The levels of NO were presented as μ M (μ mol/l). The LOD for the NO assay was 2.5 μ M.

Sections of 3-4 μ m in thickness were prepared for immunohistochemical staining. These sections were put in xylene for 20 minutes before the alcohol series

(50-100%) was applied. They were kept for 10 minutes in H₂O₂ solution. The sections were washed by PBS and then heated in a citrate buffer solution at 800 W power for 4-5 minutes. They remained for 20 minutes in a secondary blocker substance. Before staining by anti-CA-II (cod: ab124687, Abcam Plc, Cambridge, UK), each slide was kept for 75 minutes in different dilutions of a primary antibody (CA-II 1/250-1/500). We used diaminobenzidine solution as an achromogen, and Mayer's hematoxylin as a counterstain for 3-5 minutes. We used PBS as a negative control. The preparations were photographed after they were covered with a suitable covering material. After immunohistochemical staining, the preparations were divided into 4 categories according to the percentage of immunopositive reaction areas of the tissues: mild (+), moderate (++), severe (+++), and very severe (++++). The blocked tissues were cut into 4-5 µm-thick sections and then stained by hematoxylin and eosin (H&E) to prepare them for histopathological examination. The regions suitable for histopathological evaluation were photographed. All the preparations were blindly evaluated by 2 histologists. We considered the results of the statistical comparisons of all the information obtained during, between, and within group evaluations.

The results were expressed as the mean ± standard deviation. We analyzed the data using the Statistical Package for Social Sciences for Windows, version 13 (SPSS Inc., Chicago, IL, USA). The biochemical parameters were analyzed using ANOVA and then by Bonferroni analyses. The Mann-Whitney U test was used for 2 by 2 comparisons of the groups according to histopathological parameters. *P*-values of <0.05 were regarded as statistically significant.

Results. The BUN (*p*<0.001) and creatinine (*p*<0.001) levels of the cis group, and the BUN (*p*=0.006) and creatinine (*p*=0.021) levels of the Cis+Ib group were significantly higher than those of the control group. The

BUN (*p*=0.021) and creatinine (*p*=0.041) levels of the Cis+Ib group were significantly lower than those of the Cis group. The TNF-α, IL-1β, NO, and ADA levels of the cis group were significantly higher than the TNF-α (*p*<0.001), IL-1β (*p*<0.001), NO (*p*<0.001), and ADA (*p*<0.001) levels of the control group; and the TNF-α (*p*<0.001), IL-1β (*p*<0.001), NO (*p*<0.001), and ADA (*p*=0.003) of the Cis+Ib group. The TNF-α (*p*=0.762), IL-1β (*p*=0.774), NO (*p*=0.642), and ADA (*p*=0.353) levels of the Cis+Ib group were similar to those of the control group. All biochemical results are shown in Table 1.

Immunohistochemical results. No pathologic disorders of the kidney tissues of the control group stained by H&E were found in the proximal tubules, distal tubules, glomerular parietal layer, and basement membrane that could damage cell structures and tissue integrity. As low lymphocytic cell infiltration was found at the border of the cortex-medulla region, no histopathological cellular degeneration occurred (Figure 1A). Pathologic deformation was found in the epithelial structures of the proximal and distal tubules of the kidney tissues of the Cis group stained by H&E. Intensive degenerative structures, general tubular dilatations, and fluid accumulation related to the edema of epithelial structures of proximal tubules surrounding glomerulus were found (Figure 1B). The glomeruli lost their normal morphologic structures because of the dilatation of Bowman's space. Although connective tissue and edema in the cortex-medulla border increased, only focal infiltrative regions and an elevated amount of leucocytes in the cortex were found. The tubules lumens were dilated because of the deformation and shedding of the distal tubules epithelium. Although the dilatation of Bowman's space and the edema of Bowman's capsule and visceral cells was observed, the filtration space was wider than that of the control group. In some kidney tissues, Bowman's capsule and the basement membrane of the renal tubules were observed to have intensive thickness.

Table 1 - Tumor necrosis factor alpha, interleukin 1 beta, nitric oxide, adenosine deaminase, BUN, and creatinine levels of 3 groups.

Parameters	Cis	Cis+Ib	Control	F-value
BUN (mg/dl)	89.2 ± 39.9 ^{‡,¥}	30.1 ± 26.5 [§]	24.9 ± 3.7	14.8*
Creatinine (mg/dl)	1.0 ± 0.4 ^{‡,€}	0.7 ± 0.2 [¥]	0.4 ± 0.04	10.6*
TNF-α (pg/mg protein)	750.1 ± 201.2 ^{‡,§}	449.5 ± 60.0 ^{‡‡}	431.6 ± 86.1	18.6*
IL-1β (pg/mg protein)	356.9 ± 62.3 ^{‡,§}	272.5 ± 37.7 ^{§§}	266.3 ± 38.3	11.3*
Nitric oxide (µmol/gr protein)	9.9 ± 1.3 ^{‡,§}	6.8 ± 1.5 ^{††}	6.5 ± 1.6	14.8*
ADA (mIU/mg protein)	40.6 ± 9.2 ^{‡,€}	31.5 ± 3.1 ^{**}	28.8 ± 4.4	10.0 [†]

BUN - blood urea nitrogen, F - F-ANOVA test, TNF-α - tumor necrosis alpha, IL-1β - interleukin 1 beta, NO - nitric oxide, ADA - adenosine deaminase. **p*<0.001, †*p*=0.001 for ANOVA. ‡*p*<0.001, §*p*=0.006, ***p*=0.353, ††*p*=0.642, ‡‡*p*=0.762, §§*p*=0.774 versus control group. †*p*<0.001, €*p*=0.003, ¥*p*=0.021, ‡*p*=0.041 versus Cis+Ib group

In the deformation of the proximal tubules, cells were observed to be eosinophilic. Some tubules in the lumens had cystic mass structures similar to hyalinization (Figure 1B). Tissues of the Cis+Ib group stained by H&E had lower tissue and cellular deformities than those of the cis group (Figure 1C). Although glomeruli with kidney inclusion bodies improved toward normal properties, their damage was not completely improved. The epithelial cells of the proximal tubules had a lower degeneration, but their nuclei were stained slightly basophilic. Tubular dilatation and tubular cell injury in the Cis+Ib group were observed to be lower than those in the Cis group. Although the lymphocytic infiltration regions decreased, they did not completely disappear. Despite the decrease in the distal tubule dilatation, they were wider than those in the control group and had scattered edematous fluid. Despite the mild increase in connective tissue in the cortex-medulla, the amount of lymphocytes extensively decreased. Although swelling and extensive loss of cells in the tubular epithelium decreased in the Ib group, they did not completely disappear. Extensive deformation was observed to continue, especially in the outer cortex region (Figure 1C).

The CA-II enzyme activities in the Cis group were significantly lower than those in both the control group ($p=0.006$) and the Cis+Ib group ($p=0.001$). All histopathological results are shown in Table 2.

Discussion. The results showed that the serum levels of BUN and creatinine as well as the levels of TNF- α , IL-1 β , NO, and ADA in the kidney tissues of the Cis group were higher than those of the Ib and control groups. Histopathological investigation of the kidney tissue in the Cis group revealed more extensive cellular loss, edema, tubular degeneration, and dilatation accompanied with lymphocytic infiltration than those in the other 2 groups. Interestingly, the CA-II level in the Cis group was significantly lower than that in the control and Ib groups. Lower histopathological damage was detected in the Ib group than in the Cis group. The CA-II level in the Ib group was similar to that in the control group. The serum levels of BUN and creatinine in the Ib group were significantly lower than those in the Cis group. Moreover, tissue levels of TNF- α , IL-1 β , NO, and ADA were similar to those of the control group. These findings indicate that Cis-induced nephrotoxicity can be decreased by Ib treatment.

Renal injury induced by Cis has been associated with oxidative stress, inflammation, and apoptosis. Tumor necrosis factor-alpha and IL-1 β are the major pro-inflammatory cytokines. Elevated levels of these cytokines increase inflammation and lead to oxidative stress and ROS formation. Increased ROS leads to renal injury. Moreover, TNF- α leads to apoptosis by activating the caspases enzyme system. Previous studies

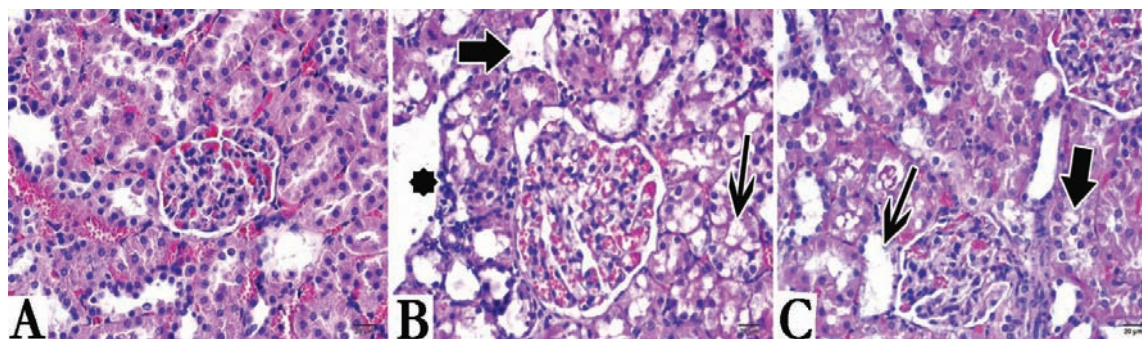


Figure 1 - The investigation of infliximab's (Ib) protective effect against Cisplatin (Cis)-induced nephrotoxicity in kidney tissues stained by Hematoxylin & Eosin in: A) control group; B) Cis applied group; and C) Cis and Ib applied group. Thin arrows - vacuolization, thick arrows - edema, star - dilatation.

Table 2 - Histopathological examination of kidney tissue.

Groups	Cell degeneration	Edema	Lymphocyte infiltration	Tubular defect	Tubular dilatation	CA-II
Control	0.4 ± 0.5	0.4 ± 0.5	1.2 ± 0.4	0.2 ± 0.4	1.2 ± 0.4	3.1 ± 0.5
Cis	3.1 ± 0.5* [§]	3.2 ± 0.6 ^{‡,§}	3.1 ± 0.5 ^{‡,§}	3.2 ± 0.4 ^{†,§}	3.0 ± 0.0 ^{‡,‡}	2.2 ± 0.6 ^{††}
Cis+Ib	2.2 ± 0.6 [§]	2.2 ± 0.4 [§]	2.2 ± 0.4 [§]	2.2 ± 0.6 [§]	2.2 ± 0.6 ^{**}	3.2 ± 0.4 [‡]

CA II - carbonic anhydrase-II, * $p<0.001$, [†] $p=0.001$, [‡] $p=0.002$ versus Cisplatin (Cis)+ infliximab (Ib) group

[§] $p<0.001$, ^{**} $p=0.002$, ^{††} $p=0.006$, ^{‡‡} $p=0.689$ versus control group

have shown that the release of TNF- α and IL-1 β causes nephrotoxicity,^{16,17} and the administration of Cis-induced nephrotoxicity in experimental models lead to the release of TNF- α and IL-1 β that damaged renal tissues.^{1,18} Infliximab is known to inhibit TNF- α and decrease the pro-inflammatory cytokine levels in the medium. Therefore, it decreases tissue injury by blocking the direct effect of these cytokines and their stimulation to oxidative stress. Infliximab has been reported to decrease renal injury by decreasing oxidative stress.¹⁹ Our study presented Cis-induced nephrotoxicity by increasing TNF- α and IL-1 β levels. However, Ib treatment can be used to decrease nephrotoxicity by suppressing these 2 cytokines.

Previous studies have shown Cis to induce nephrotoxicity by increasing the NO level.²⁰ An elevated NO level is known to cause renal tubular damage. Peroxynitrite is the main product of the reaction between NO and superoxide anion.²¹ It is a potent cellular oxidant especially for DNA. Infliximab prevents the elevation of NO level by suppressing NO synthetase expression.²² In our study, although NO clearly increased in the Cis group, its level was similar to that in both the Ib and control groups. Infliximab has been shown to have a protective effect against Cis-induced nephrotoxicity by preventing excessive NO increase. However, some studies have reported an increase in renal blood flow and glomerular filtration after the administration of NO inhibitor, thus prolonging the renal injury induced by Cis.²⁰ In our study, although the NO level in the Cis group was excessively elevated, it was similar to that in the Cis+Ib and control groups. This similarity shows that, although Ib prevents excessive NO formation, it does not lower its level below the basal level. Therefore, renal blood flow and glomerular filtration are maintained.

The ADA enzyme catalyzes the conversion reaction of both adenosine to inosine and deoxyadenosine to deoxyinosine.²³ The ADA levels have been shown to increase in Cis-induced nephrotoxicity.²⁴ Elevated ADA levels also indirectly increase purine metabolites, such as adenosine, hypoxanthine, inosine, and ROS.^{25,26} In Cis-induced toxicity, superoxide radicals increase as a result of high cell turnover. Aside from the elevation of the ADA level, adenosine may also cause mesangial and vascular contractions in the kidney, leading to a reduction in renal blood flow and glomerular filtration rate.²⁷ In the current study, ADA obviously increased in the Cis group, indicating an increase in both purine metabolites and ROS levels in the Cis group. Infliximab may prevent Cis-induced renal damage by decreasing the acceleration of purine metabolism.

The CA-II, which catalyzes the reversible reaction between carbon dioxide and bicarbonate ($H^+ + HCO_3^- \leftrightarrow H_2CO_3 \leftrightarrow H_2O + CO_2$), is abundant in the kidneys.²⁸ The kidneys maintain a normal acid-base balance using 2 major mechanisms: reabsorption of filtered HCO_3^- from the proximal tubule and excretion of net protons (H^+) as titratable acid and ammonium in the distal nephron.²⁹ In fact, CA-II over-expression may lead to excess bicarbonate, which may increase tumor growth.^{30,31} Therefore, the suppression of CA-II by Cis is a desired effect. The suppression of the CA-II level by Cis in therapeutic doses is a desired effect for cancer treatment. However, our data are limited in this subject.

In this study, the CA-II level of the Cis group was suppressed in comparison with that of the control group. The suppression of this enzyme may lead to metabolic acidosis by preventing renal H^+ excretion.^{32,33} This metabolic acidosis may further increase renal injury. The similarity of the CA-II level in the Ib group and the control group may indicate that Ib may decrease renal injury by preventing Cis-induced CA-II inhibition, which leads to the decrease in metabolic acidosis formation. Moreover, the similarity of the CA-II level in the Cis+Ib group and the control group may indicate that these 2 drugs may be combined in cancer treatment. Further studies are needed on this subject.

Study limitations. In future studies, the bicarbonate level, aside from CA-II activities, can be measured to support our results. Measuring the urinary PH and blood gas can also give additional information. Excessive cytokine release that induces nephrotoxicity was evaluated in our study. Aside from these parameters, the measurement of oxidative stress parameters can also be performed. As we measured the NO level only, the malondialdehyde and antioxidant enzyme levels can be measured as well. Our study is a pilot study; therefore, further studies on this topic are needed. In this study, 7 mg/kg of Cis and Ib was used. New studies may use different dosages, and the preventive effect of other dosages may be investigated. As the interval of this study is short, new studies with long intervals are needed to investigate whether the preventive effect of Ib decreases or increases with increasing time.

In conclusion, Cis-induced nephrotoxicity can occur not only by increasing pro-inflammatory cytokines and ROS formation, but also by accelerating purine metabolism. It may lead to metabolic acidosis by inhibiting the CA-II enzyme, which accelerates renal injury. Infliximab, which is a potent TNF- α inhibitor, may partially prevent Cis-induced renal injury by cytokine inhibition and maintenance of purine metabolism. However, Cis-induced nephrotoxicity

limits the use of Cis or may lead to the cessation of its treatment in practice. This study shows that Ib can prevent Cis-induced nephrotoxicity, making Cis safe to use in practice. However, as this study is a pilot one, further studies with more details and a long follow-up period are needed.

References

- Chang WW, Liu JJ, Liu CF, Liu WS, Lim YP, Cheng YJ, et al. An extract of *Rhodobacter sphaeroides* reduces cisplatin-induced nephrotoxicity in mice. *Toxins (Basel)* 2013; 5: 353-365.
- Ademiluyi AO, Oboh G, Agbebi OJ, Akinyemi AJ. Anthocyanin - rich red dye of hibiscus *Sabdariffa* Calyx modulates cisplatin-induced nephrotoxicity and oxidative stress in rats. *Int J Biomed Sci* 2013; 9: 243-248.
- Sahu BD, Kuncha M, Sindhura GJ, Sistla R. Hesperidin attenuates cisplatin-induced acute renal injury by decreasing oxidative stress, inflammation and DNA damage. *Phytomedicine* 2013; 20: 453-460.
- Söğüt S, Kotuk M, Yilmaz HR, Ulu R, Ozyurt H, Yildirim Z. In vivo evidence suggesting a role for purine-catabolizing enzymes in the pathogenesis of cisplatin-induced nephrotoxicity in rats and effect of erdoesteine against this toxicity. *Cell Biochem Funct* 2004; 22: 157-162.
- Ma X, Xu S. TNF inhibitor therapy for rheumatoid arthritis. *Biomed Rep* 2013; 1: 177-184.
- Guzel A, Kanter M, Guzel A, Pergel A, Erbogga M. Anti-inflammatory and antioxidant effects of infliximab on acute lung injury in a rat model of intestinal ischemia/reperfusion. *J Mol Histol* 2012; 43: 361-369.
- Pergel A, Kanter M, Yucel AF, Aydin I, Erbogga M, Guzel A. Anti-inflammatory and antioxidant effects of infliximab in a rat model of intestinal ischemia/reperfusion injury. *Toxicol Ind Health* 2012; 28: 923-932.
- Güzel A, Günaydin M, Güzel A, Alaçam H, Murat N, Gacar A, et al. Infliximab attenuates activated charcoal and polyethylene glycol aspiration-induced lung injury in rats. *Exp Lung Res* 2012; 38: 147-156.
- Hammoudeh M. Infliximab treatment in a patient with rheumatoid arthritis on haemodialysis. *Rheumatology (Oxford)* 2006; 45: 357-359.
- Sun X, Soleimani M, Petrovic S. Decreased expression of Slc26a4 (Pendrin) and Slc26a7 in the kidneys of carbonic anhydrase II-deficient mice. *Cell Physiol Biochem* 2008; 21: 95-108.
- Yoshiura K, Nakaoka T, Nishishita T, Sato K, Yamamoto A, Shimada S, et al. Carbonic anhydrase II is a tumor vessel endothelium-associated antigen targeted by dendritic cell therapy. *Clin Cancer Res* 2005; 11: 8201-8207.
- Lotan D, Eisenkraft A, Jacobsson JM, Bar-Yosef O, Kleta R, Gal N, et al. Clinical and molecular findings in a family with the carbonic anhydrase II deficiency syndrome. *Pediatr Nephrol* 2006; 21: 423-426.
- Gautier JC, Riefke B, Walter J, Kurth P, Mylecraine L, Guilpin V, et al. Evaluation of novel biomarkers of nephrotoxicity in two strains of rat treated with Cisplatin. *Toxicol Pathol* 2010; 38: 943-956.
- Al-Majed AA. Carnitine deficiency provokes cisplatin-induced hepatotoxicity in rats. *Basic Clin Pharmacol Toxicol* 2007; 100: 145-150.
- Mahmoud MF, El Shazly SM, Barakat W. Inhibition of TNF- α protects against hepatic ischemia-reperfusion injury in rats via NF- κ B dependent pathway. *Naunyn Schmiedeberg Arch Pharmacol* 2012; 385: 465-471.
- Rodrigues FA, Prata MM, Oliveira IC, Alves NT, Freitas RE, Monteiro HS, et al. Gingerol fraction from *Zingiber officinale* protects against gentamicin-induced nephrotoxicity. *Antimicrob Agents Chemother* 2014; 58: 1872-1878.
- Jia Z, Wang N, Aoyagi T, Wang H, Liu H, Yang T. Amelioration of cisplatin nephrotoxicity by genetic or pharmacologic blockade of prostaglandin synthesis. *Kidney Int* 2011; 79: 77-88.
- Ramesh G, Reeves WB. Salicylate reduces cisplatin nephrotoxicity by inhibition of tumor necrosis factor- α . *Kidney Int* 2004; 65: 490-499.
- Tasdemir C, Tasdemir S, Vardi N, Ates B, Parlakpınar H, Kati B, et al. Protective effect of infliximab on ischemia/reperfusion-induced damage in rat kidney. *Ren Fail* 2012; 34: 1144-1149.
- Moslemi F, Nematbakhsh M, Eshraghi-Jazi F, Talebi A, Nasri H, Ashrafi F, et al. Inhibition of nitric oxide synthase by L-NAME promotes cisplatin-induced nephrotoxicity in male rats. *ISRN Toxicol* 2013; 2013: 242345.
- Jung M, Hotter G, Vinas JL, Sola A. Cisplatin upregulates mitochondrial nitric oxide synthase and peroxynitrite formation to promote renal injury. *Toxicol Appl Pharmacol* 2009; 234: 236-246.
- Di Paola R, Genovese T, Impellizzeri D, Ahmad A, Cuzzocrea S, Esposito E. The renal injury and inflammation caused by ischemia-reperfusion are reduced by genetic inhibition of TNF- α 1: a comparison with infliximab treatment. *Eur J Pharmacol* 2013; 700: 134-146.
- Kowalczyk E, Kopff M, Kowalski J, Kopff A, Mikhailidis DP, Barylski M, et al. Effect of cardiovascular drugs on adenosine deaminase activity. *Angiology* 2008; 59: 740-744.
- Gulec M, Iraz M, Yilmaz HR, Ozyurt H, Temel I. The effects of ginkgo biloba extract on tissue adenosine deaminase, xanthine oxidase, myeloperoxidase, malondialdehyde, and nitric oxide in cisplatin-induced nephrotoxicity. *Toxicol Ind Health* 2006; 22: 125-130.
- Iraz M, Ozerol E, Gulec M, Tasdemir S, Idiz N, Fadillioglu E, et al. Protective effect of caffeic acid phenethyl ester (CAPE) administration on cisplatin-induced oxidative damage to liver in rat. *Cell Biochem Funct* 2006; 24: 357-361.
- Uzar E, Sahin O, Koyuncuoglu HR, Uz E, Bas O, Kilbas S, et al. The activity of adenosine deaminase and the level of nitric oxide in spinal cord of methotrexate administered rats: protective effect of caffeic acid phenethyl ester. *Toxicology* 2006; 218: 125-133.
- Vallon V, Miracle C, Thomson S. Adenosine and kidney function: potential implications in patients with heart failure. *Eur J Heart Fail* 2008; 10: 176-187.
- Purkerson JM, Schwartz GJ. The role of carbonic anhydrases in renal physiology. *Kidney Int* 2007; 71: 103-115.
- Lee Hamm L, Hering-Smith KS, Nakhoul NL. Acid-base and potassium homeostasis. *Semin Nephrol* 2013; 33: 257-264.
- Neri D, Supuran CT. Interfering with pH regulation in tumours as a therapeutic strategy. *Nat Rev Drug Discov* 2011; 10: 767-777.
- Liu LC, Xu WT, Wu X, Zhao P, Lv YL, Chen L. Overexpression of carbonic anhydrase II and Ki-67 proteins in prognosis of gastrointestinal stromal tumors. *World J Gastroenterol* 2013; 19: 2473-80.
- Sh Ali AA, Al-Mashta SA. Cerebral calcification, osteopetrosis and renal tubular acidosis: is it carbonic anhydrase-II deficiency? *Saudi J Kidney Dis Transpl* 2013; 24: 561-565.
- Mirza NS, Alfirevic A, Jorgensen A, Marson AG, Pirmohamed M. Metabolic acidosis with topiramate and zonisamide: an assessment of its severity and predictors. *Pharmacogenet Genomics* 2011; 21: 297-302.