

Anterior migration of intravitreal fluocinolone acetonide (Iluvien®) implant in a pseudophakic eye with intact posterior capsule

Manal Alzaabi^{a,*}, Abdel Hakim Taguri^a, Ahmed Elbarky^{a,b}

^a Sheikh Khalifa Medical City, Abu Dhabi, United Arab Emirates

^b Assistant Professor of Ophthalmology in Benha Faculty of Medicine, Egypt

ARTICLE INFO

Keywords:

Iluvien® implant
Diabetic macular edema

ABSTRACT

Purpose: To describe a case of spontaneous anterior migration of intravitreal fluocinolone acetonide (Iluvien®) implant in a pseudophakic eye with intact posterior capsule.

Observation: A 60-year old woman with proliferative diabetic retinopathy underwent uneventful pars plana vitrectomy and phacoemulsification with posterior chamber intraocular lens (PCIOL) implants in both eyes. She developed diabetic macular edema (DME) in her right eye which failed to respond to repeated intravitreal injections of Aflibercept 2mg/0.05ml (Eylea®). The patient received an intravitreal Iluvien® implant to treat the recalcitrant DME after she showed a favorable temporary response to dexamethasone intravitreal implant (Ozurdex™). Six months later she presented with pain in the right eye due to elevated intraocular pressure (IOP). The Iluvien® implant was found to be dislodged into the anterior chamber (AC) in the presence of an intact posterior capsule and stable PCIOL implant. The migrated Iluvien implant was removed and IOP was controlled with a glaucoma drainage valve as it failed to respond to maximum anti-glaucoma medication.

Conclusions and Importance: Intravitreal Iluvien® implant could migrate into the AC in a previously vitrectomized eyes in the presence of an intact posterior capsule.

1. Introduction

Iluvien® implant (Alimera Sciences Inc., Alpharetta, GA, USA) is a sustained release biodegradable implant which provides a therapeutic intravitreal concentration of fluocinolone acetonide for up to 36 months.^{1,2}

The implant is an established treatment modality for DME as well as macular edema secondary to retinal vein occlusion and uveitis.³

Anterior migration of intravitreal corticosteroid implants such as Iluvien® and Ozurdex™ implants has been reported in aphakic patients and in eyes with a defect in the capsule due to complicated cataract surgery.⁴⁻⁶

We report a case of anterior migration of Iluvien® implant in a previously vitrectomized pseudophakic eye with intact posterior capsule and stable PCIOL implant.

2. Case report

A sixty year old female presented to the eye clinic in 2014 with proliferative diabetic retinopathy. She received 2 injections of

intravitreal ranibizumab (0.5 mg) followed by 2 sessions of pan retinal laser photocoagulation. The patient was lost to follow up, then presented 2 years later with loss of vision due to bilateral vitreous hemorrhage and cataract. She underwent bilateral consecutive pars plana vitrectomy and phacoemulsification surgeries with PCIOL implantation.

The procedures were uneventful and her corrected distant visual acuity (CDVA) improved from hand motion preoperatively in both eyes to 20/30 in the left eye and 20/200 in the right eye. Her IOP remained in the mid-teens with no evidence of rubeosis iridis in either eye. Optical Coherence Tomography (OCT) confirmed DME in the right eye with central macular thickness of 544 μm (Fig. 1). The patient received 2 intravitreal injections of Eylea® with no improvement in CDVA or central macular thickness.

She then received an intravitreal Ozurdex™ implant which resulted in a temporary improvement of CDVA to 20/150 for 4 months. As there was no effect on IOP following Ozurdex™ implant, we opted for intravitreal Iluvien® implant to achieve a prolonged improvement of vision. The patient had a very good response to Iluvien® implant with further improvement of CDVA to 20/100 and reduction in central macular thickness to 174 μm (Fig. 2).

* Corresponding author.

E-mail addresses: Manal_90@live.com, m.alsuwaiji@gmail.com (M. Alzaabi).

<https://doi.org/10.1016/j.ajoc.2020.100922>

Received 2 May 2020; Received in revised form 28 August 2020; Accepted 2 September 2020

Available online 11 September 2020

2451-9936/© 2020 Published by Elsevier Inc. This is an open access article under the CC BY-NC-ND license (<http://creativecommons.org/licenses/by-nc-nd/4.0/>).

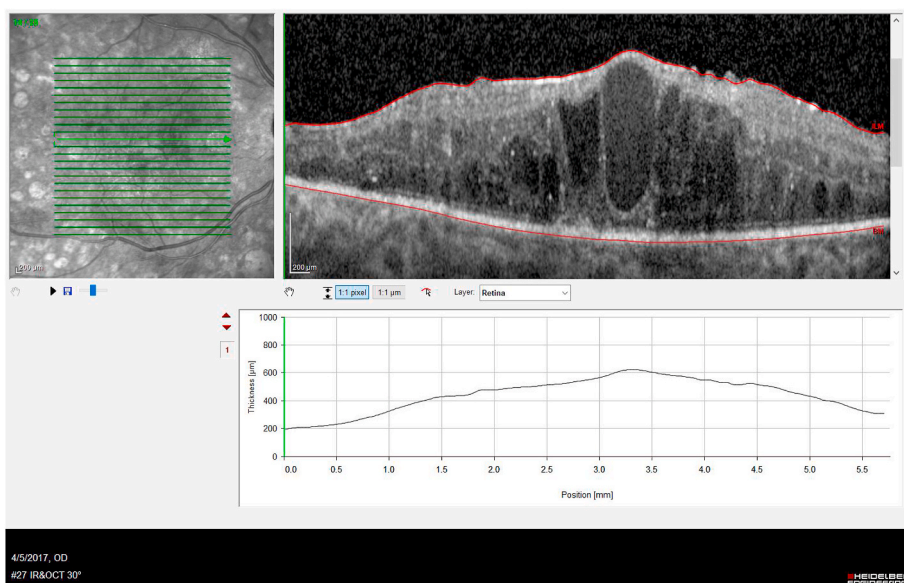


Fig. 1. Right eye OCT prior to intravitreal Iluvien™ implant
 Description: OCT of the right macula prior to intravitreal Iluvien implant showing significant macular edema with Outer retinal hyper-reflective foci, and disturbance in the integrity and intensity of Ellipsoid zone (EZ).

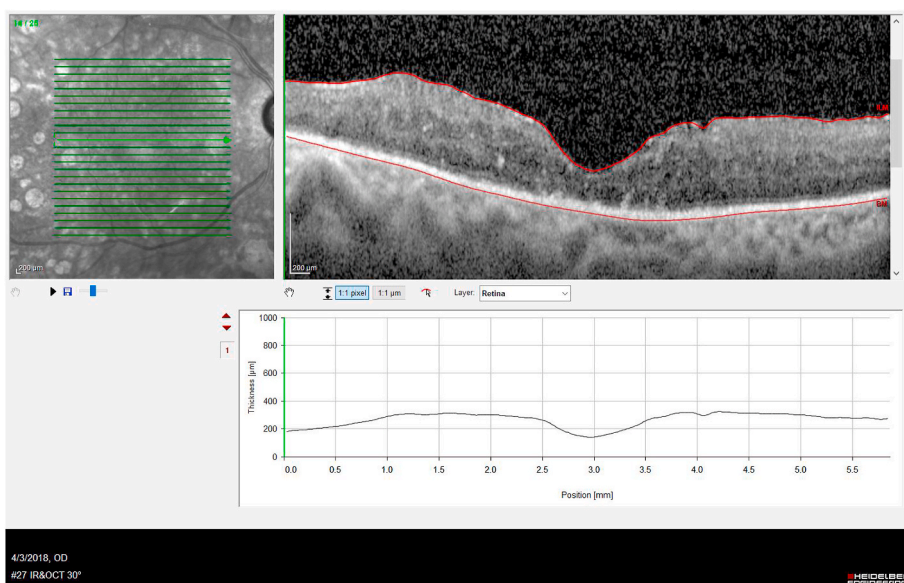


Fig. 2. Right eye OCT 8 months after intravitreal Iluvien™ implant showing significant reduction in central macular thickness.

However, she presented 6 months later with right eye pain and raised IOP to 40 mmHg. Slit-lamp examination showed clear cornea and quiet anterior chamber with no evidence of rubeosis iridis (Fig. 3). Gonioscopic examination revealed that the Iluvien® implant has migrated into the AC and was lodged in the inferior angle (Fig. 4). There was no pseudophacodensis noted and the posterior capsule was intact. The patient denied any history of trauma.

Intraocular pressure remained elevated above 30 mmHg despite 3 topical anti-glaucoma medications and oral acetazolamide. Hence, we proceeded with surgical removal of the displaced Iluvien® implant via anterior approach with insertion of Ahmed glaucoma shunt. Post-

operatively, IOP remained well controlled without anti-glaucoma medication and CDVA stabilized at 20/100 with no further deterioration of DME.

3. Discussion

Iluvien™ intravitreal implants were found to be effective in achieving substantial and prolonged improvement of vision in patients with DME, including cases recalcitrant to previous anti-vascular endothelium growth factor therapy.^{1,2}

The most common reported complications of Iluvien™ implants

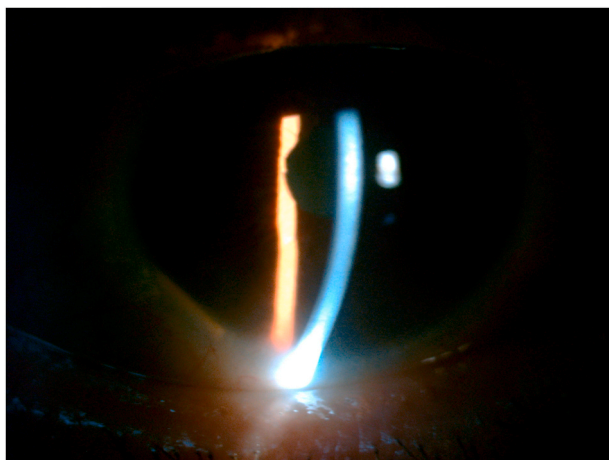


Fig. 3. Slit-lamp cornea picture right eye. Right eye slit-lamp picture showing clear cornea with no signs of endothelial decompensation.

include cataract formation in 80% of phakic eyes and raised IOP in 34% of patients.^{3,7}

Migration of an Iluvien™ implant into the AC, however, is a rather uncommon complication which has been reported in aphakic eyes and in patients with defective posterior lens capsules following previous complicated cataract surgery.^{4,5}

Likewise, anterior migration of intravitreal Ozurdex™ implant has only been reported in cases with deficient posterior lens capsules.^{6,8}

Anterior migration of the intravitreal implant can lead to serious complications. Ozurdex™ implants can cause corneal edema. Endothelial decompensation can happen either due to chemical toxicity of the active component of the Ozurdex™ implant (dexamethasone, lactic acid or glycolic acid), or from mechanical trauma by rubbing on the corneal endothelium. As a result, the implant requires urgent removal or repositioning to avoid corneal decompensation and keratoplasty.⁸

However, corneal edema after anterior migration of the intravitreal Iluvien™ implant is not as common as with Ozurdex™ implants because it is not toxic to the corneal endothelium but can cause corneal endothelial damage due to repetitive mechanical trauma by eye



Fig. 4. Gonioscopic picture of right eye. Gonioscopic picture showing dislodged Iluvien™ implant in the inferior angle (red arrow head). (For interpretation of the references to colour in this figure legend, the reader is referred to the Web version of this article.)

movements.¹⁰

In addition, migration of an intravitreal Iluvien™ implant into the anterior chamber can result in elevation of the concentration of the medication at the trabecular meshwork, increasing the risk of steroid-induced glaucoma similarly to our case.¹⁰ Surgical removal of the implant was done to our case after medical treatment failed to maintain normal intraocular pressure.

In our case, an Iluvien™ implant has migrated into the AC in the presence of an intact posterior capsule. Although the pars plana vitrectomy procedure was uneventful in our case, disruption of peripheral zonular fibrils during the procedure could not be ruled out.⁹

Hence, we suggest that migration of an Iluvien™ implant could have happened through a small peripheral zonular dehiscence inadvertently caused during a previous pars plana vitrectomy procedure. It is likely that the presumed zonular dehiscence in our case was small enough to prevent migration of the previous Ozurdex™ implant, given its larger size compared to an Iluvien™ implant (6 mm × 0.46 mm vs. 3.5 mm × 0.37 mm).

4. Conclusions

We report a case of an anteriorly migrated intravitreal Iluvien™ implant in a patient who had uneventful consecutive pars plana vitrectomy and phacoemulsification with PCIOL implant.

This case raised the possibility of anterior migration of intravitreal Iluvien™ implants in the presence of an intact posterior capsule and clinically stable PCIOL implant.

We suggested that an Iluvien™ implant has migrated through a small zonular dehiscence possibly caused by previous pars plana vitrectomy procedure.

Being smaller in size than Ozurdex™ implants, the Iluvien™ implant would be more likely to migrate through a small area of compromised zonules in post vitrectomized eyes.

In our case there was no sign of localized corneal endothelial decompensation at the site of the migrated Iluvien™ implant. Hence, we suggest to perform careful gonioscopy in patients with Iluvien™ implants presenting with secondary glaucoma even in the presence of clinically intact capsule-zonules complex.

Patient consent

Consent to publish the case report was obtained in writing. This report does not contain any personal information that could lead to the identification of the patient.

Funding

No funding or grant support.

Authorship

All authors attest that they meet the current ICMJE criteria for Authorship.

Declaration of competing interest

All authors have no financial disclosures.

Acknowledgements

None.

References

- Hatz Katja, Ebnetter Andreas, Tuerksever Cengiz, Prunte Christian. Martin zinkernagel repeated dexamethasone intravitreal implant for the treatment of

- diabetic macular oedema unresponsive to anti-VEGF therapy: outcome and predictive SD-OCT features *ophthalmologica*. 2018;239(4):205–214.
2. Fusi-Rubiano William, Blow Rebecca R, Lane Mark, Morjaria Rupal, Alastair K. Denniston Iluvien™ (fluocinolone acetonide 0.19 mg intravitreal implant) in the treatment of diabetic macular edema. *Rev. Ophthalmol Ther*. 2018;7(2):293–305.
 3. Syed YY. Fluocinolone acetonide intravitreal implant 0.19 mg (ILUVIEN®): a review in diabetic macular edema. *Drugs*. 2017;77(5):575–583.
 4. El-Ghrably IA, Saad A, Dinah C. A novel technique for repositioning of a migrated ILUVIEN® (fluocinolone acetonide) implant into the anterior chamber. *Ophthalmol Ther*. 2015;4(2):129–133.
 5. Papastavrou VT, Zambarakji H, Dooley I, Eleftheriadis H, Jackson TL. Observation: fluocinolone acetonide (iluvien) implant migration into the anterior chamber. *Retin Cases Brief Rep*. 2017;11(1):44–46.
 6. Kishore SA, Schaal S. Management of anterior chamber dislocation of dexamethasone implant. *Ocul Immunol Inflamm*. 2013;21(1):90–91.
 7. Massa H, Nagar AM, Vergados A, Dadoukis P, Patra S, Panos GD. Intravitreal fluocinolone acetonide implant (ILUVIEN®) for diabetic macular oedema: a literature review. *J Int Med Res*. 2018;47(1):31–43.
 8. Khurana RN, Appa SN, Mccannel CA, et al. Dexamethasone implant anterior chamber migration. *Ophthalmology*. 2014;121(1):67–71.
 9. Fenberg MJ, Hainsworth KJ, Rieger FG, Hainsworth DP. Vitrectomy as a risk factor for complicated cataract surgery. *Missouri Med J*. 2016;113(1):44–47.
 10. Tabandeh H, Rezaei K. Scleral fixation of fluocinolone acetonide implant. *Am J Ophthalmol Case Reports*;19:100775.