

Generalized lymphadenopathy secondary to isolated extramedullary hematopoiesis as an initial manifestation of primary myelofibrosis

Mansour S. Aljabry,¹ Shuaa Asiri,²
Tayseer Elsafi,³ Ghaleb Elyamany²

¹Department of Pathology, Hematology Unit, King Khalid University Hospital, King Saud University; ²Department of Central Military Laboratory and Blood Bank, Prince Sultan Military Medical City, Riyadh; ³Department of General Medicine, Prince Sultan Military Medical City, Riyadh, Kingdom of Saudi Arabia

Abstract

Extramedullary hematopoiesis (EMH) is a presence of hematopoietic activity in the extramedullary sites. EMH can occur in both benign and malignant hematologic diseases. The liver and spleen are the most common sites, but may also occur infrequently at other sites. EMH often occurs in more than one site and quite rare in an isolated organ. In this study we describe an unusual case of generalized lymphadenopathy secondary to isolated extramedullary hematopoiesis as an initial manifestation of primary myelofibrosis. Computed tomography revealed generalized lymphadenopathy including mediastinal, abdominal and pelvic lymph nodes with extensive ill-defined sclerotic lesions throughout the skeletal system suggestive of lymphoma/leukemia. Lymph node biopsy showed no evidence of malignancy or granuloma, however, large abnormal cells with multilobated nuclei were seen scattered in the lymph nodes. These abnormal cells were proved to be megakaryocytes. Granulocytic precursors were less obvious on the H&E section. The diagnosis was determined as EMH in the lymph node. Bone marrow (BM) examination showed hypercellular marrow for patient's age with granulocytic and megakaryocytic proliferation with increase in BM fibrosis and reported as a myeloproliferative neoplasm, consistent with primary myelofibrosis. In summary, although EMH is not always a malignant process; it is important to stress that the patient should be investigated for underlying hematological disorders, when it is noted elsewhere.

Introduction

Extramedullary hematopoiesis (EMH) is the appearance of hematopoietic tissue outside of the bone marrow.¹ Usually two or three cell lineages are present in EMH. It can be seen in both benign and malignant hematologic diseases and occur in any tissue that can support the proliferation of hematopoietic progenitors. The liver and spleen are the most common sites, but lymph nodes, kidney, adrenal glands, and lungs may be involved.^{2,3} EMH often manifests in more than one site and quite rarely identified in an isolated organ. It usually reflects a pathologic state and is rarely seen in adults under physiologic circumstances. Furthermore, EMH is an uncommon complication of myeloproliferative and myelodysplastic disorders, most commonly seen in primary myelofibrosis (PMF).^{4,5} EMH in lymph nodes was previously reported, but a clinically significant lymphadenopathy is very rarely reported.^{3,6}

In this study we describe an unusual case presented by constitutional symptoms and severe generalized lymphadenopathy secondary to isolated EMH in lymph nodes as an initial manifestation of PMF.

Case Report

A 63-year old woman presented with fever, night sweating, weight loss and generalized lymphadenopathy since 9 months. She had a history of hypertension and hypothyroidism on treatment. The patient had no history of a hematologic illness and no family history of any hematologic disease. The patient had been investigated in different hospitals without any definitive diagnosis. On physical examination: She was stable, both chest and heart were clinically free, generalized lymphadenopathy including cervical, axillary and superficial inguinal lymphadenopathy were noted and abdominal examination showed hepatosplenomegaly. On admission, CBC: WBC $5.2 \times 10^9/L$, hemoglobin 11.2 g/dL, and platelets $286 \times 10^9/L$ and no abnormal cells were detected in the peripheral blood smear. Liver function tests were normal. Hepatitis and tumor markers were negative. The work up for tuberculosis and other infectious diseases were negative. Computed tomography (CT) of the chest, abdomen and pelvis revealed generalized lymphadenopathy including mediastinal, abdominal and pelvic lymph nodes. The largest lymph node measured about 2 cm in short axis. The liver and spleen were enlarged; measured about 24 and 16 cm in

Correspondence: Mansour S. Aljabry, Pathology Department, King Khalid University Hospital, King Saud University, P.O. Box 2925, Riyadh 11461, Kingdom of Saudi Arabia.
Tel.: +96.6114671812.
E-mail: m.aljabry4210@gmail.com, maljabry@ksu.edu.sa

Key words: Lymph node, extramedullary hematopoiesis, myelofibrosis.

Contributions: the authors contributed equally.

Conflict of interest: the authors declare no potential conflict of interest.

Funding: none.

Received for publication: 24 January 2018.

Revision received: 3 May 2018.

Accepted for publication: 7 May 2018.

This work is licensed under a Creative Commons Attribution-NonCommercial 4.0 International License (CC BY-NC 4.0).

©Copyright M.S. Aljabry et al., 2018
Licensee PAGEPress, Italy
Hematology Reports 2018; 10:7588
doi:10.4081/hr.2018.7588

length respectively; also an extensive ill-defined sclerotic lesions throughout the included skeletal system were noted (Figure 1A).

The impression of CT scan findings was suggestive of lymphoma/leukemia along with the extensive skeletal involvement. Accordingly, lymph node and liver biopsy were done and later on BM examination was performed.

Lymph node biopsy showed no evidence of malignancy or granuloma, however, large abnormal cells with multilobated, hyperchromatic nuclei and abundant cytoplasm were seen scattered in the lymph nodes. These abnormal cells were proved to be megakaryocytes by morphological assessment and immunohistochemical stains for CD61 and FVIII. Some megakaryocytes showed abnormal morphology and nuclear atypia. In addition, granulocytic precursors were clearly illustrated by myeloperoxidase (MPO) stain, and no erythroid precursors detected (Figure 1B-D). The diagnosis was determined as EMH in the lymph node, primarily consisting of megakaryopoiesis and granulopoiesis. Liver biopsy was negative for malignancy or granuloma and showed grade I inflammation and stage II fibrosis with no evidence of EMH (Figure 1E).

Based on the lymph node result, the

patient underwent bone marrow (BM) examination. It revealed a hypercellular marrow for patient's age with granulocytic and megakaryocytic proliferation while erythroid precursors were markedly reduced. Megakaryocytes showed an atypical morphology with hyperchromatic and hyperlobated forms (Figure 1F). No morphologic evidence of increase in blast cells or presence of abnormal lymphoid cells. Reticulin stain revealed increased of BM fibrosis, MF-1 on grading system proposed by Thiele *et al.*⁷ Flow cytometry confirmed no evidence of BM involvement by acute leukemia or lymphoma.

Molecular studies using real-time PCR were positive for *JAK2* V617F mutation and negative for *BCL-ABL1* fusion gene. Conventional cytogenetic studies showed normal karyotype (46, XX); Fluorescence *in situ* hybridization studies (FISH) was negative for BCR/ABL1 as well. The final patient's diagnosis was reported as myeloproliferative neoplasm (MPN), consistent with PMF.

The patient's prognostic risk category according to International Prognostic Scoring System (IPSS) was intermediate-1 due to presence of constitutional symptoms at diagnosis. Initially, he was started on Hydroxyurea 500 mg daily which resulted in mild improvement of symptoms with poor control of lymphadenopathy and splenomegaly despite escalating of the dose to 1 g daily. Eventually Ruxolitinib 10 mg twice daily was administered resulting in a dramatic symptomatic response and marked reduction of spleen size and lymph nodes. Unfortunately, the patient lost the follow up after 3 months of Ruxolitinib treatment.

Discussion

EMH has been reported in almost all body sites, including lymph nodes; often manifests in more than one site and quite rarely seen in an isolated organ; most cases were hepatosplenic-EMH. However, rare

cases were reported as isolated non hepatosplenic EMH.^{3,8,9} It can occur in a number of conditions, including benign and malignant hematologic diseases as well as non-hematologic disorders.¹⁰

EMH in lymph nodes was previously reported but clinically significant lymphadenopathy is extremely rare reported.^{3,6} In the current case, the lymph nodes are the only organ involved without hepatosplenic involvements which are the common sites of EMH.

EMH in a lymph node is a potential diagnostic pitfall in such case as it could be mistaken for metastatic cancer, in such case the differential diagnosis of megakaryocytes in lymph nodes should include multinucleated histiocytes and metastatic malignant cells.^{2,11} Immunostains are helpful for distinguishing megakaryocytes (reactive for CD61 and nonreactive with CD68) from macrophages/histiocytes (reactive with CD68 but not for CD61) and from metastatic carcinoma which are nonreactive with both CD61 and CD68 but reactive with

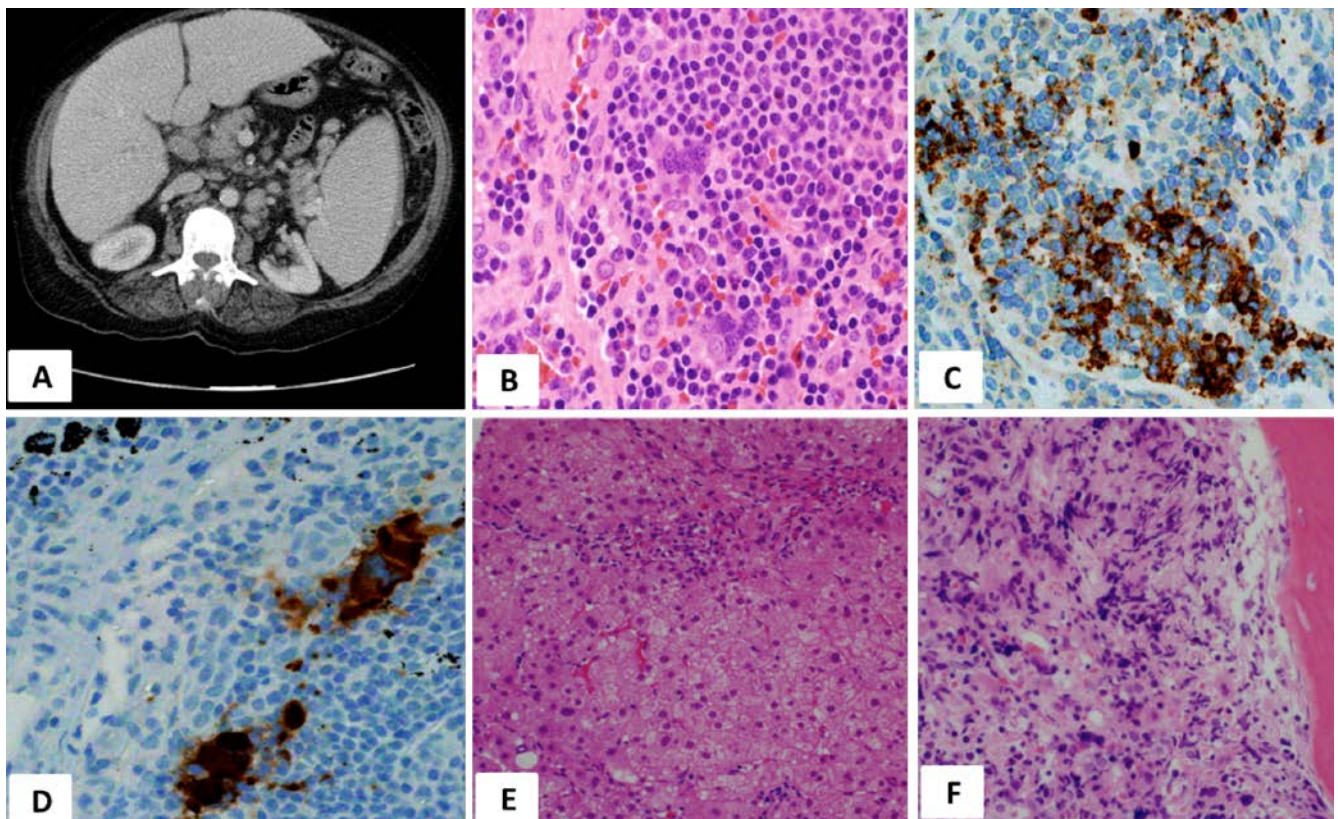


Figure 1. A) Contrast-enhanced computed tomography of the chest and abdomen showed multiple enlarged mediastinal and retroperitoneal lymph nodes with hepatosplenomegaly. B) Magnified view of the megakaryocytes in the lymph node (hematoxylin-eosin; H&E) have multilobed hyperchromatic nuclei and abundant cytoplasm. C) Granulocytic precursors in lymph node are highlighted by myeloperoxidase. D) CD61-positive megakaryocytes in lymph node. E) Liver biopsy is negative for malignancy or granuloma with no evidence of extramedullary hematopoiesis. F) H&E bone marrow trephine biopsy shows hyper cellular bone marrow with abnormal megakaryocytes.

cytokeratin. Misidentification of megakaryocytes as metastatic cancer cells in lymph node was previously reported.^{12,13} Furthermore, presence of EMH can be problematic especially when evaluating lymph nodes during frozen section where morphology is frequently less than optimal.¹⁴⁻¹⁶

Interesting finding in our case is a generalized lymphadenopathy secondary to EMH was the initial manifestation of PMF. The presence of bone marrow elements in a lymph node should prompt a hematologic evaluation, especially in adults with unknown hematologic disorder and should be examined for BM evaluation, as this could be the first clue in diagnosing bone marrow disorder.^{4,17} In our case, CT patterns showing enlarged lymph nodes in various anatomical districts indicated a systemic disorder. The absence of nodular parenchymal masses in the liver, spleen and other organs that are frequent sites for EMH and the absence of fatty component in the extramedullary hematopoiesis masses are the features of this unusual presentation.

As evident in our case, the megakaryocytes are the most conspicuous element on microscopic examination of EMH. The difficulty in our case was also, compounded by the absence of significant other hematopoietic precursor which typically found at most sites of EMH. It is reported that megakaryocytes might mimic metastatic carcinoma cells which make the morphological diagnosis is challenging in some occasions.²

Conclusions

In summary, it is important to stress that although EMH is not always a malignant process, the patient should be examined for underlying hematological disorders when it is noted elsewhere as this could be the first clue in diagnosing of underlying bone marrow disorder.

References

1. Coyne JD. Extramedullary hematopoiesis. *J Clin Pathol* 2005;58:448.
2. Hoda SA, Resetkova E, Yusuf Y, et al. Megakaryocytes mimicking metastatic breast carcinoma. *Arch Pathol Lab Med* 2002;126:618-20.
3. Koch CA, Li CY, Mesa RA, Tefferi A. Nonhepatosplenic extramedullary hematopoiesis: associated diseases, pathology, clinical course, and treatment. *Mayo Clin Proc* 2003;78:1223-33.
4. Kaygusuz G, Kuzu I, Akpınar E, Uysal A. Akselere faz kronik myeloid lösemili hastada aksiller lenf nodülünde ekstrameduller hematopoezis. Extramedullary hematopoiesis in the axillary lymph node in a patient with an accelerated phase of chronic myeloid leukemia. *Turk J Hematol* 2009;26:40-1.
5. Haniffa MA, Wilkins BS, Blasdale C, Simpson NB. Cutaneous extramedullary hemopoiesis in chronic myeloproliferative and myelodysplastic disorders. *J Am Acad Dermatol* 2006;55:S28-31.
6. Williams ME, Innes DJ, Hutchison WT, Hess CE. Extramedullary hematopoiesis. A cause of severe generalized lymphadenopathy in agnogenic myeloid metaplasia. *Arch Intern Med* 1985;145:1308-9.
7. Thiele J, Kvasnicka HM, Facchetti F, et al. European consensus on grading bone marrow fibrosis and assessment of cellularity. *Haematologica* 2005;90:1128-32.
8. O'Malley DP, Kim YS, Perkins SL, et al. Morphologic and immunohistochemical evaluation of splenic hematopoietic proliferations in neoplastic and benign disorders. *Mod Pathol* 2005;18:1550-61.
9. Sohawon D, Lau KK, Lau T, Bowden DK. Extramedullary haematopoiesis: a pictorial review of its typical and atypical locations. *J Med Imag Radiat Oncol* 2012;56:538-44.
10. O'Malley DP. Benign extramedullary myeloid proliferations. *Mod Pathol* 2007;20:405-5.
11. Chiu A, Hoda RS, Hoda SA. Pseudomicrometastasis in sentinel lymph node: multinucleated macrophage mimicking micrometastasis. *Breast J* 2001;7:440-1.
12. Weeks DA, Beckwith JB, Mierau GW. Benign nodal lesions mimicking metastases from pediatric renal neoplasms: a report of the National Wilms' Tumor Study Pathology Center. *Hum Pathol* 1990;21:1239-44.
13. Colby TV, Yousem SA. Lungs. In: Sternberg SS, ed. *Histology for Pathologists*. 2nd ed. Philadelphia: Lippincott-Raven; 2000. pp 451-452.
14. Millar EKA, Inder S, Lynch J. Extramedullary haematopoiesis in axillary lymph nodes following neoadjuvant chemotherapy for locally advanced breast cancer—a potential diagnostic pitfall. *Histopathology* 2009;54:622-3.
15. Prieto-Granada C, Setia N, Otis CN. Lymph node extramedullary hematopoiesis in breast cancer patients receiving neoadjuvant therapy: a potential diagnostic pitfall. *Int J Surg Pathol* 2013;21:264-6.
16. Takhar AS, Ney A, Patel M, Sharma A. Extramedullary haematopoiesis in axillary lymph nodes following neoadjuvant chemotherapy for locally advanced breast cancer. *BMJ Case Rep* 2013:bcr2013008943.
17. Bowen JM, Perry AM, Quist E, Akhtari M. Extramedullary hematopoiesis in a sentinel lymph node as an early sign of chronic myelomonocytic leukemia. *Case Rep Pathol* 2015;2015:594970.