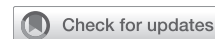

Video-assisted transarterial modified Konno procedure with concurrent myectomy for hypertrophic obstructive cardiomyopathy



Hiroyuki Suzuki, MD,^a Yasuhiro Kotani, MD, PhD,^a Shunji Sano, MD, PhD,^b and Shingo Kasahara, MD, PhD,^a Okayama and Tokyo, Japan

From the ^aDepartment of Cardiovascular Surgery, Okayama University, Okayama, Japan; and ^bDivision of Pediatric Cardiac Surgery, Pediatric Heart Disease & Adult Congenital Heart Disease Center, Showa University Hospital, Tokyo, Japan.

Received for publication Sept 14, 2023; revisions received Oct 5, 2023; accepted for publication Oct 9, 2023; available ahead of print Oct 20, 2023.

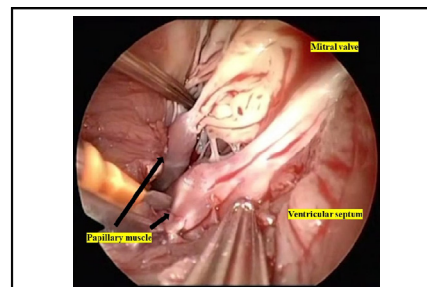
Address for reprints: Yasuhiro Kotani, MD, PhD, Department of Cardiovascular Surgery, Okayama University, 2-5-1, Shikata-cho, Kita-ku, Okayama, 700-8558, Japan (E-mail: yasuhiro.kotani@cc.okayama-u.ac.jp).

JTCVS Techniques 2023;22:261-4

2666-2507

Copyright © 2023 The Author(s). Published by Elsevier Inc. on behalf of The American Association for Thoracic Surgery. This is an open access article under the CC BY-NC-ND license (<http://creativecommons.org/licenses/by-nc-nd/4.0/>).

<https://doi.org/10.1016/j.xjtc.2023.10.013>



Endoscopy provided clear visualization to enable adequate release of the obstruction.

CENTRAL MESSAGE

Adequate and safe septal myectomy at the mid-LV level can be achieved with video-assisted transarterial modified Konno procedure without ventriculotomy.

▶ Video clip is available online.

Transaortic septal myectomy is the gold-standard treatment for patients with hypertrophic obstructive cardiomyopathy. However, under particular conditions, such as severe and diffuse left ventricular outflow tract (LVOT) obstruction, the procedure is challenging and often results in inadequate muscle resection using only the transaortic approach, thus leading to residual stenosis. The modified Konno procedure is an effective alternative to relieve mid-left ventricle (LV)-

level obstruction in such patients.¹ However, this procedure requires right ventriculotomy, which potentially causes right ventricular outflow tract (RVOT) obstruction and arrhythmia. We describe a novel technique for the modified

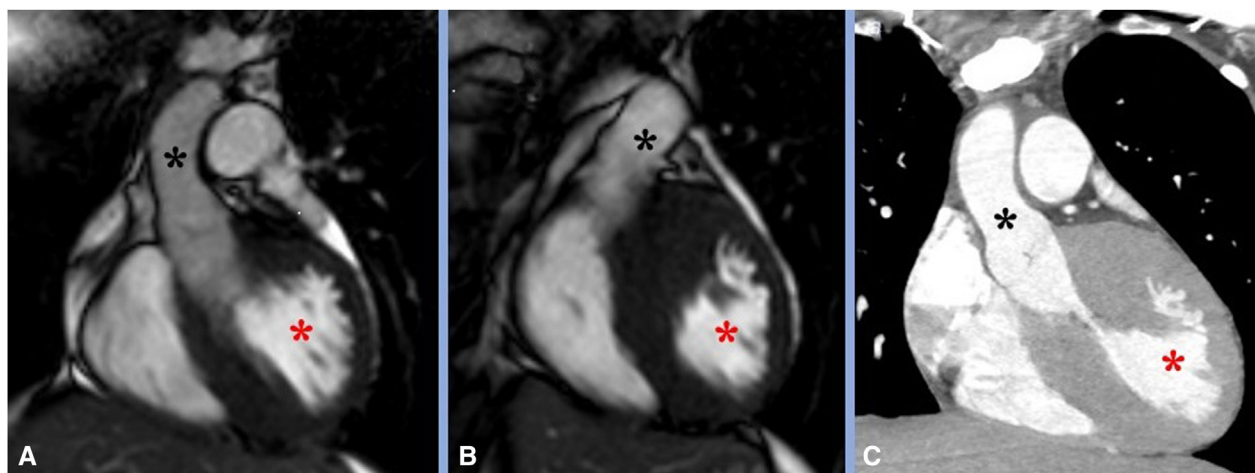
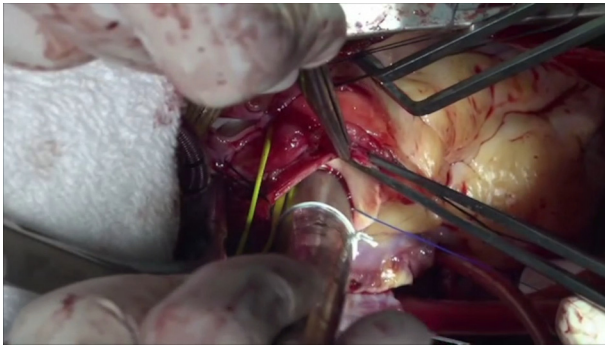


FIGURE 1. Preoperative cardiac magnetic resonance (A, B) and computed tomography (C) indicate long-regional left ventricular outflow tract obstruction. Red asterisk: left ventricle, black asterisk: aorta.



VIDEO 1. This movie shows the video-assisted transarterial modified Konno procedure. Video available at: [https://www.jtcvs.org/article/S2666-2507\(23\)00393-0/fulltext](https://www.jtcvs.org/article/S2666-2507(23)00393-0/fulltext).

Konno procedure via aortotomy and pulmonary arteriotomy combined with endoscopy without incision of the left ventricle or right ventricle (IRB/ERBCRB6180001, March 23, 2020; written patient consent was obtained for publication of this case report).

CLINICAL SUMMARY

A 15-year-old girl (body weight: 45 kg, body surface area: 1.41 m²) presented with a systolic heart murmur. Echocardiography revealed a mean pressure gradient of 40 mm Hg across the LVOT (Figure E1). Computed tomography and cardiac magnetic resonance imaging revealed long regional hypertrophied ventricular septum >25 mm thick (Figure 1). Given that the stenosis was tunnel-like and hypertrophy was severe, the modified Konno procedure was chosen. The surgery was performed via median sternotomy with cardiopulmonary bypass. After cardiac arrest, aortotomy was performed, followed by the main pulmonary

arteriotomy. First, septal myectomy was performed through the aortic valve in the standard fashion. A ventricular septal defect (VSD) was cautiously created at the LVOT so as not to compromise the conduction system and, through the pulmonary valve, the VSD was enlarged. Additional myectomy was performed toward the apex at the level of the midportion. Abnormal tissues, including secondary chordae between the papillary muscle and septum, were excised. During the procedure deeper inside the ventricle, endoscopy provided clear visualization to enable adequate release of the obstruction due to hypertrophied muscle and abnormal chordae (Video 1, Figure E2). The VSD was closed using an expanded polytetrafluoroethylene patch. Postoperative echocardiography revealed a mean pressure gradient across the LVOT of 7 mm Hg, with no aortic or pulmonary valve regurgitation, whereas cardiac magnetic resonance imaging revealed a wide-open LVOT (Figure 2). The patient has not experienced atrioventricular block or life-threatening arrhythmia. The follow-up period is projected to be 5 years; currently, she has not experienced recurrence of stenosis and her symptoms are stable, with New York Heart Association functional class I.

DISCUSSION

Hypertrophic obstructive cardiomyopathy is a standard criterion for transaortic septal myectomy. However, under specific conditions, such as severe and diffuse LVOT obstruction or small-size aortic annulus, the procedure often results in inadequate exposure of the LVOT, which results in inadequate resolution of the obstruction. This may lead to insufficient myectomy and unexpected injury to valves and the conduction system. In these situations, additional left ventriculotomy at the apex cannot avoid the possibility of damage to other structures as well.

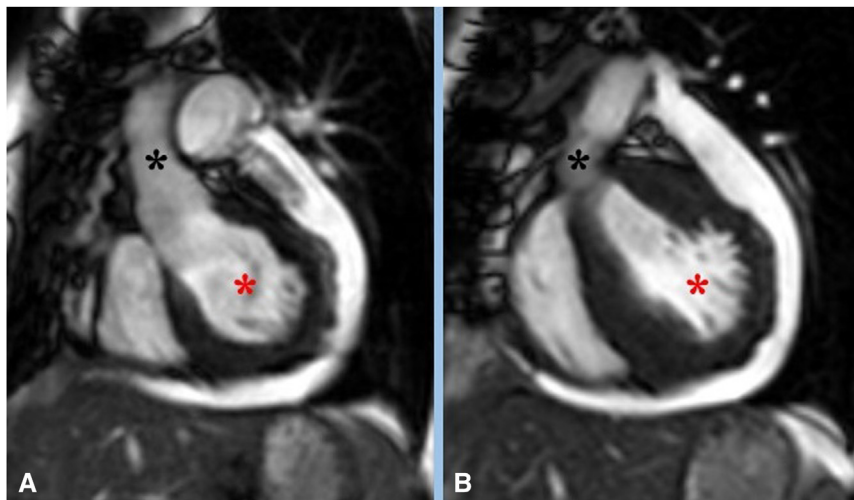


FIGURE 2. Postoperative cardiac magnetic resonance (A, B) shows the release of left ventricular tract obstruction. Red asterisk: left ventricle, black asterisk: aorta.

Cho and colleagues² reported that inadequate muscle resection causes residual or recurrent stenosis, which accounts for 84% of reoperations. In such situations, Laredo and colleagues³ reported on the efficacy of the modified Konno procedure and its favorable long-term results in high-risk patients with LVOT obstruction. However, the modified Konno procedure requires incision of the right ventricle, and we believe this is unnecessary for patients without RVOT obstruction. With the use of endoscopy, only the transaortic and pulmonic approaches are sufficient to achieve adequate myectomy at the mid-left ventricle level, in addition to the modified Konno procedure without right or left ventriculotomy. It potentially prevents RVOT obstruction and late arrhythmia caused by scar tissue. In addition to the aforementioned, combining the direct field of view with endoscopy avoids valve and papillary muscle injuries.

Conflict of Interest Statement

The authors reported no conflicts of interest.

The *Journal* policy requires editors and reviewers to disclose conflicts of interest and to decline handling or reviewing manuscripts for which they may have a conflict of interest. The editors and reviewers of this article have no conflicts of interest.

References

1. Cooley DA, Garrett JR. Septoplasty for left ventricular outflow obstruction without aortic valve replacement: a new technique. *Ann Thorac Surg*. 1986;42:445-8.
2. Cho YH, Quintana E, Schaff HV, Nishimura RA, Dearani JA, Abel MD, et al. Residual and recurrent gradients after septal myectomy for hypertrophic cardiomyopathy—mechanisms of obstruction and outcomes of reoperation. *J Thorac Cardiovasc Surg*. 2014;148:909-16.
3. Laredo M, Khraiche D, Raisky O, Gaudin R, Bajolle F, Maltret A, et al. Long-term results of the modified Konno procedure in high-risk children with obstructive hypertrophic cardiomyopathy. *J Thorac Cardiovasc Surg*. 2018;156:2285-94.e2.

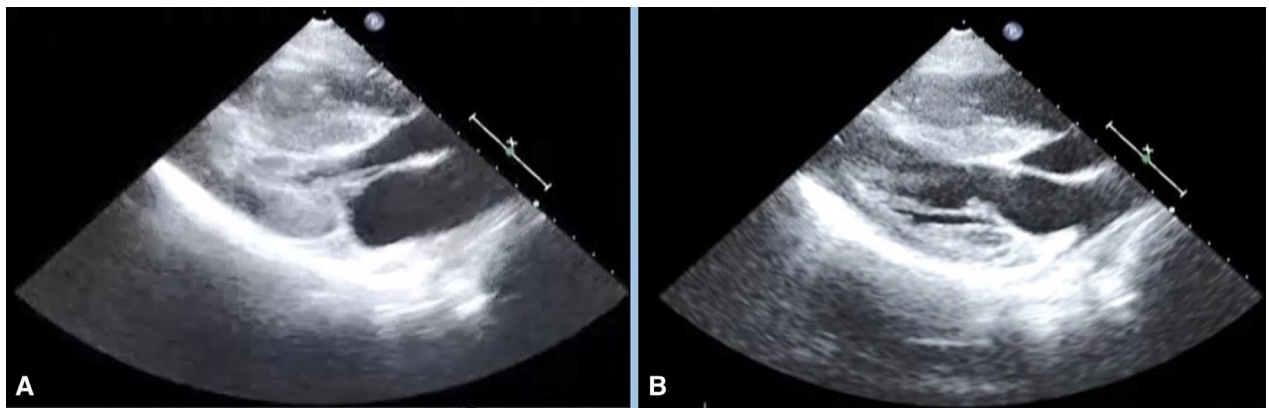


FIGURE E1. Echocardiography revealed that mean pressure gradient of 40 mm Hg across the left ventricular outflow tract. A, systolic period, B, diastolic period.

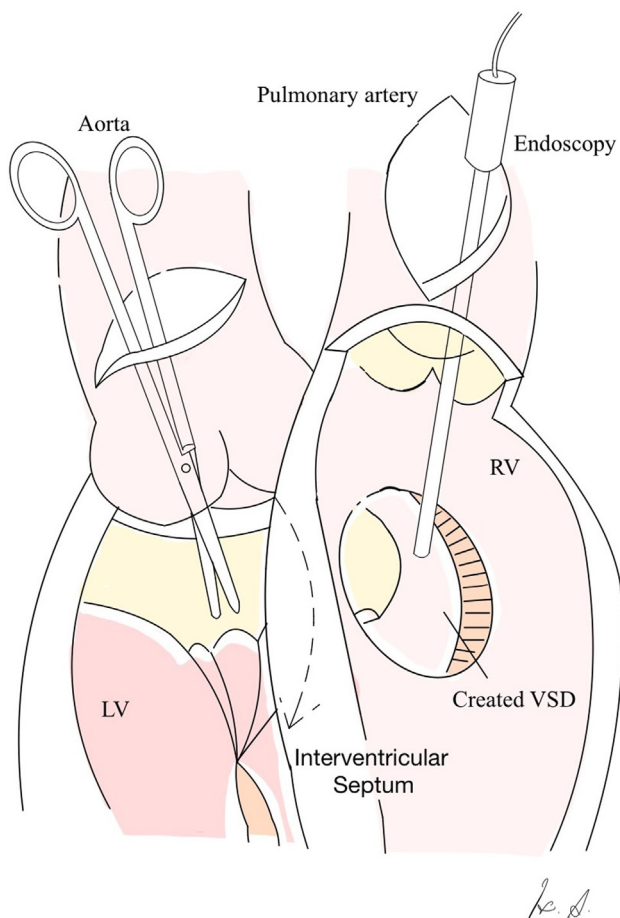


FIGURE E2. This schema depicts the video-assisted transarterial modified Konno procedure with concurrent myectomy without additional LV or RV incisions. LV, Left ventricle; RV, right ventricle; VSD, ventricular septal defect.